

UCLA

UCLA Previously Published Works

Title

Modified robot-assisted nephroureterectomy with ureteral catheterization for radical resection of the distal ureter: Procedures and short-term outcomes.

Permalink

<https://escholarship.org/uc/item/7016b1w8>

Journal

Vaccine Reports, 10(8)

ISSN

2405-8440

Authors

Ji, Hao

Wu, Qikai

Ji, Jianbo

et al.

Publication Date

2024-04-30

DOI

10.1016/j.heliyon.2024.e29198

Peer reviewed



Research article

Modified robot-assisted nephroureterectomy with ureteral catheterization for radical resection of the distal ureter: Procedures and short-term outcomes

Hao Ji ^{a,1}, Qikai Wu ^{a,1}, Jianbo Ji ^{a,b,1}, Yuhang Qian ^c, Lingkai Cai ^a, Kexin Bai ^a, Qiang Cao ^a, Xiao Yang ^a, Yongke Cao ^d, Qiang Lv ^{a,**}, Pengchao Li ^{a,e,*}

^a Department of Urology, The First Affiliated Hospital of Nanjing Medical University, Nanjing, PR China

^b Department of Urology, Yancheng Third People's Hospital, Yancheng Clinical Medical College, Nanjing Medical University, Yancheng, PR China

^c Department of Epidemiology, Fielding School of Public Health, University of California, Los Angeles, CA, USA

^d Department of English, Nanjing Medical University, Nanjing, PR China

^e Department of Urology, The Affiliated Suqian First People's Hospital of Nanjing Medical University, Suqian, PR China

ARTICLE INFO

Keywords:

Bladder cuff excision
Robot-assisted nephroureterectomy
Upper urinary tract urothelial carcinoma
Ureteral catheterization
Ureteral orifice

ABSTRACT

Objectives: To describe a bladder cuff excision method modified with ureteral catheterization to better visualize the ureteral orifice during robot-assisted nephroureterectomy (RANU).

Methods: We retrospectively analyzed 66 patients with upper urinary tract urothelial carcinoma of the renal pelvis and/or upper-mid ureter treated between January 2020 and January 2023. Among them, 32 patients (group A) underwent RANU supported by ureteral catheterization, and the remaining patients (group B) received routine transperitoneal RANU. Postoperative cystoscopy was performed routinely to compare the rates of residual ureteral orifice between the two groups.

Results: Surgeries were completed uneventfully in all 66 patients, without blood transfusion or conversion to open procedures. The operative time, estimated blood loss, and postoperative length of hospital stay were similar between both groups. However, the mean time required for BCE in group A was shorter than that in group B (9.5 min vs. 16.0 min, $p = 0.006$). Cystoscopy at postoperative three months showed no ipsilateral ureteral orifice in group A, but residual ureteral orifice was found in 23.5% of patients in group B. During a short follow-up period of 16 months, no patients in group A experienced bladder tumor recurrence. However, two patients (5.9%) in group B developed bladder tumor recurrence, with one experiencing local tumor recurrence at the level of the ureteral stump.

Conclusions: Our novel technique enables complete ureteral retrieval, accurate and rapid bladder cuff excision, which makes the procedure less invasive and safely reproducible during robot-assisted nephroureterectomy.

* Corresponding author. Department of Urology, The First Affiliated Hospital of Nanjing Medical University, 300 Guangzhou Road, Nanjing, Jiangsu Province, 210029, PR China

** Corresponding author. Department of Urology, The First Affiliated Hospital of Nanjing Medical University, 300 Guangzhou Road, Nanjing, Jiangsu Province, 210029, PR China

E-mail addresses: doctorlvqiang@sina.com (Q. Lv), superkulian@aliyun.com (P. Li).

¹ These authors contributed equally to this paper.

<https://doi.org/10.1016/j.heliyon.2024.e29198>

Received 8 November 2023; Received in revised form 28 March 2024; Accepted 2 April 2024

Available online 4 April 2024

2405-8440/© 2024 The Authors. Published by Elsevier Ltd. This is an open access article under the CC BY-NC license (<http://creativecommons.org/licenses/by-nc/4.0/>).

1. Introduction

Radical nephroureterectomy (RNU) with bladder cuff excision (BCE) is a standard therapy for high-risk non-metastatic upper urinary tract urothelial carcinoma (UTUC) [1]. Laparoscopic or robotic RNU has been established as a minimally invasive alternative to open procedures [2,3]. During minimally invasive BCE, however, a small incision is just made on the bladder wall; only a cephalic vision is provided; and the ureteral orifice is sheltered by the bladder wall; all these make it difficult to mimic procedures of open BCE. Without repositioning the patient, BCE in a flank position shows certain limitations, such as easy misidentification of the ureteral orifice and accidental transection of the ureter in separating along the ureter, which may result in incomplete resection of the ureteral orifice and residual intramural segment of the ureter. Incomplete distal ureterectomy is relevant to adverse oncological outcomes, such as poor overall survival, cancer-specific survival, and recurrence-free survival [4]. Even without a positive surgical margin, the rate of recurrence in the ureteric stump may rise to 33%–75% among patients with the distal ureter mismanaged [5,6].

To date, many methods have been explored to manage the bladder cuff, including transvesical, extravesical, and endoscopic approaches, with each having its pros and cons [7–9]. The transvesical approach is the standard for exposing the ureteral orifice, but may result in large cystic trauma that allows for tumor implantation [10,11]. The endoscopic technique is easily manipulated, but may lead to tumor cell spillage and incomplete ureteral excision, ultimately increasing the risk of intravesical recurrence [7,9]. The extravesical approach can maintain a closed urinary system, but offers poor visualization and inaccessibility to the distal ureter, potentially causing incomplete ureteral removal and contralateral ureteral orifice injury [10,12]. In the laparoscopic stapling technique, a cystoscopically appreciable remnant of the resected ureteral orifice is noted in 50% of the patients [13]. Besides, clinical use of certain laparoscopic forceps, such as bulldog clamps [14], is limited by their blind placement. This technique relies heavily on the surgeon's experience, rather than a direct vision, making it difficult to confirm the complete removal of the affected ureteral orifice. Robot-assisted nephroureterectomy (RANU) addresses some of the challenges that surgeons face during laparoscopic BCE [15], but cannot provide a sufficient visualization of the ureteral orifice with a small bladder incision. The residual ureteral orifice is detected in 6.6% of patients who have undergone RANU [4].

Accurate visualization of the ureteral orifice during BCE is crucial to ensure complete removal of the distal ureter. Inadequate BCE may leave a remnant ureter, and excessive BCE could increase the risk of tumor seeding and contralateral ureteral orifice damage (see Fig. 1A and B). In this study, we described our modified technique of RANU, which is supported by ureteral catheterization, for precise management of the bladder cuff (see Fig. 1C). Using this technique, the ureteral orifice could be accurately identified, facilitating the determination of the resection range. In addition, for those with distal ureteral transection, the radical resection of the ureteral orifice and the intramural segment of the ureter could be achieved by slightly expanding the resection scope under the guidance of the ureteral catheter.

2. Patients and methods

2.1. Patients

From January 2020 to January 2023, a total of 66 patients with urothelial carcinomas in the renal pelvis and/or upper-mid ureter were included. In group A, 32 patients underwent RANU with ureteral catheterization; in group B, 34 patients underwent routine transperitoneal RANU. All patients received surgeries performed by the same team, including two urologists with the title of associate chief physician or above, both of whom have more than 2 years of experience in robotic surgery. Data from both groups were retrospectively analyzed. All tumors were staged by the 2017 TNM classification of malignant tumors [16], and graded based on the 2016 World Health Organization classification [17]. Table 1 presents patients' characteristics in our study. The study was approved by the institutional review board approval from the ethical committee of the hospital. Participants consented to have their images published.

2.2. Surgical techniques

Surgeries were performed using the Da Vinci Xi® surgical system. Cystoscopy examination was performed in both groups to

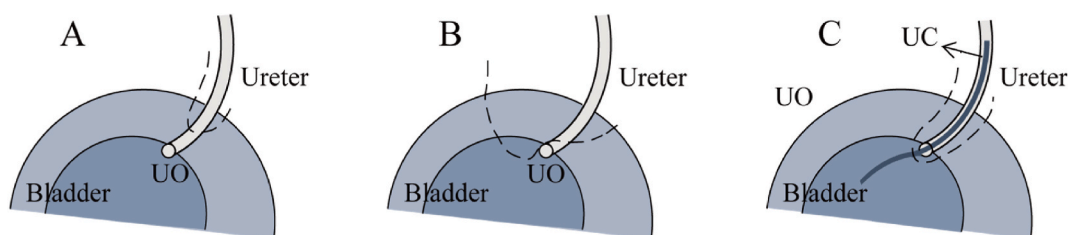


Fig. 1. Diagrams of different excision scopes of the bladder cuff from a cephalic vision (the dotted line indicates the excision scope). (A, B) Inadequate excision scope with the intramural segment of the ureter retained; (C) Proper excision scope under direct visualization of the ureteral orifice. UC = ureteral catheter; UO = ureteral orifice.

exclude the concurrent bladder tumors. In group A, during the cystoscopy procedure, a ureteral catheter was inserted into the affected ureter by 5–10 cm (distal to the tumor location), followed by the placement of a Foley urethral catheter. To facilitate urine drainage and decrease the risk of urine spillage in the modified flank position, 5 ml of water was injected into the urethral catheter sac. In both groups, the patient was placed in a modified flank position (60° oblique) with a 15° Trendelenburg tilt. After establishing a pneumoperitoneum, six ports were introduced into the sites described as below (see Fig. 2). An 8-mm camera port was placed at the border of the ipsilateral rectus muscle superior to the level of the umbilicus. An 8-mm robotic port was placed superior to the level of the symphysis, followed by a 12-mm assistant port between the camera and the robotic port. Next, an 8-mm robotic port was placed subcostal in the midclavicular line, and an identical robotic port was placed medial to the anterior superior iliac spine. A 12-mm assistant port was placed between the camera and the cranial robotic port.

A routine robotic transperitoneal nephrectomy was performed in both groups, meanwhile keeping the ureter intact. Once the ureter was recognized, a Hem-o-loc clip was placed distal to the tumor location and proximal to the tip of the ureteral catheter, to decrease the risk of tumor seeding into the bladder. Renal vessels were occluded with Hem-o-loc clips, and then divided. A template-based lymph node dissection was performed, according to the risk stratified by the European Association of Urology Guidelines [1,18].

Group B received standard procedures of bladder cuff excision reported in the literature [19]. In group A, after full mobilization of the kidney, the dissection was performed caudally to the ureterovesical junction. Special care was taken in ligating and dividing the uterine artery in females. The distal ureter and the bladder cuff were adequately dissected, and the ureter was retracted in the cranial and lateral directions, till the bladder mucosa was tented. The tent-shaped bladder mucosal cuff was incised very close to the ureter, and the ipsilateral ureteral orifice was visualized through the previously inserted ureteral catheter (see Fig. 3A and B). The anterior wall of the ureteral orifice was incised clockwise from 8 to 4 o'clock, and then the ureteral catheter was removed. Subsequently, the distal ureter along with the bladder cuff was circumferentially excised (see Fig. 3C). In males, the vas deferens was carefully dissected and then distanced by the forceps to make an approach for easier bladder cuff dissection (see Fig. 3D). In the case of ureteral transection, the resection scope was slightly expanded along the distal ureter to ensure total resection of the ureteral orifice and the intramural segment of the ureter. The vesical defect was then closed in a running manner using a 3-0 barbed suture. The time from dissociation at the ureterovesical junction to bladder wall suturing was recorded as the BCE time. After retrieval of the specimen, the ureteral catheter was inserted into the specimen to examine the presence of the bladder mucosa around the ureteral orifice (see Fig. 4A).

2.3. Follow-up

The Foley catheter was retained for two weeks. For T3 patients with a glomerular filtration rate greater than 50 ml/min, adjuvant systemic chemotherapy with gemcitabine plus cisplatin was administered postoperatively, along with intravesical instillation of 50 mg epirubicin per week for six times. All patients were followed up with regular cystoscopy to confirm complete resection of the ipsilateral ureteral orifice (see Fig. 4B). Other follow-up strategies included postoperative urine cytology, abdominal enhanced computed tomography (CT), pelvic magnetic resonance imaging, and chest CT.

2.4. Data analysis

The data collected in this study involved patients' age, sex, body mass index (BMI), tumor location, TNM classification, grade, operative time, postoperative hospital stay, perioperative complications according to Dindo-clavien classification [20], residual

Table 1
Demographics and pathologic data of patients.

Characteristics	Group A (n = 32)	Group B (n = 34)	P value
Age, years ^a	67.5 (57.0–71.8)	68.0 (58.8–76.2)	0.329
Sex, n (%)			
Males	20 (62.5)	20 (58.8)	0.760
Females	12 (37.5)	14 (41.2)	
BMI, kg/m ^{2a}	24.0 (21.5–27.4)	25.4 (23.3–27.4)	0.323
Side, n (%)			
Right	18 (56.2)	17 (50.0)	0.611
Left	14 (43.8)	17 (50.0)	
Tumor location, n (%)			
Renal pelvis	22 (68.8)	21 (61.8)	0.552
Upper-mid ureter	10 (31.2)	13 (38.2)	
TNM staging, n (%)			
pT1	7 (21.9)	9 (26.5)	0.855
pT2	3 (9.4)	2 (5.9)	
pT3	22 (68.8)	23 (66.6)	
Grade, n (%)			
Low grade	5 (15.6)	7 (20.6)	0.601
High grade	27 (84.4)	27 (79.4)	

BMI = body mass index.

^a Continuous variables were expressed as medians (interquartile ranges).

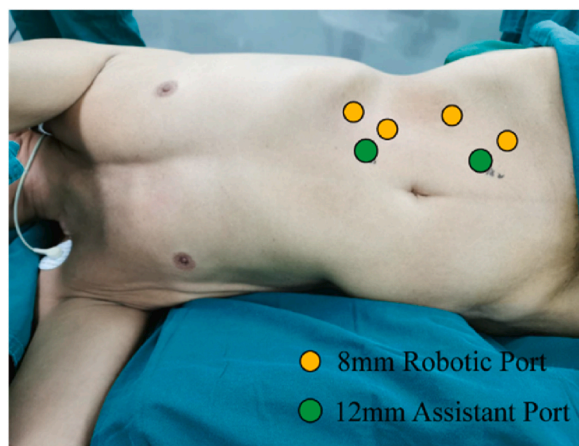


Fig. 2. Patient positioning and port placement for RANU performed by da Vinci Xi® Surgical System (eg, left side).

ureteral orifice, and bladder tumor recurrence. The operative time referred to the robotic console time. Statistical analyses were conducted using the software SPSS (IBM Corporation, Armonk, NY, USA). Continuous variables were compared using Mann-Whitney *U* test, and categorical variables using Chi-square or Fisher's exact test. Significance was set at $p < 0.05$.

3. Results

The distributions of sex, age, and BMI were similar between the two groups (Table 1). The two groups were homogenous in terms of tumor side, location, TNM classification, and grade (all $p > 0.05$).

Surgeries went smoothly without blood transfusion or conversion to open procedures in all 66 patients. Perioperative outcomes and follow-up data are shown in Table 2. The mean time required for cystoscopy examination was 7 min, whereas group A requires an additional average time of 3 min for ureteral catheterization. No statistically significant differences were observed in median operative time, median estimated blood loss, and median postoperative length of hospital stay between the two groups (all $p > 0.05$). However, BCE in group A was faster than that in group B (9.5 min vs. 16.0 min, $p = 0.006$). No intraoperative or postoperative complications, such as urinary fistula, lymphatic leakage, hemorrhage, intestinal obstruction, or infection, were noted in either group.

During the first follow-up cystoscopy, which was routinely conducted three months after surgery, it was found that group A had no residual ipsilateral ureteral orifice. In contrast, residual ureteral orifice was observed in eight cases (23.5%) of group B ($p = 0.005$). This indicates that our modified robotic technique achieved a 100% complete ureteral resection rate. Over the median follow-up period of 16 months (range 3–40 months), none of the patients in group A experienced bladder tumor recurrence. However, bladder tumor recurrence developed in two patients (5.9%) in group B, including one case of simultaneous local tumor recurrence of the ureteral stump. The patient with simultaneous local tumor recurrence of the ureteral stump suffered a T1 bladder tumor, which was treated by transurethral resection of bladder tumors (TURBT) and resection of the residual ureteral stump. The other recurrent patient experienced a Ta tumor and was treated by TURBT.

4. Discussion

Regardless of its location, high-risk nonmetastatic UTUC is routinely treated with RNU combined with BCE [1]. However, with a high reported rate of retained ureteral stump [4,13], BCE remains to be improved during minimally invasive RNU [21]. Robots, especially the Da Vinci Xi® system, with their 3D high-definition images and enhanced dexterity and precision, promise to mitigate the limitations of conventional laparoscopic techniques [15,22]. In a routine robotic surgery, BCE needs to be accomplished by en bloc resection of the distal ureter along with the bladder cuff around the ureteral orifice, after the bladder cuff has been adequately mobilized and shown a characteristic tapered appearance [23,24]. However, the presence of the tent-shaped bladder cuff structure seems insufficient to ensure complete resection of the intramural segment of the ureter (see Fig. 1A and B). Surgeons may have different interpretations of the tapered appearance of the bladder cuff, and their experience plays a significant role in selecting the resection range. Insufficient resection leaves a remnant ureter, while excessive resection brings about massive bladder trauma and an increased risk of tumor seeding. Without reliable anatomical markers, there is a risk of inadvertently transecting the intramural segment of the ureter. Consequently, the limited visibility provided by a small incision on the bladder wall makes it difficult to remove the distal stump of the ureter, which also increases the risk of ureteral stump tumor recurrence.

Here, we proposed a novel method for adequate bladder cuff retrieval using ureteral catheterization during RANU. Through our modified robotic BCE, the ureteral orifice can be fully visualized, which overcomes the inherent drawbacks of traditional robotic BCE. Unlike the traditional RANU method that relies on the surgeon's experience, this method, guided by the ureteral catheter, saves time in locating the ureteral orifice and can achieve BCE more quickly. By completely removing the intramural segment of the ureter and

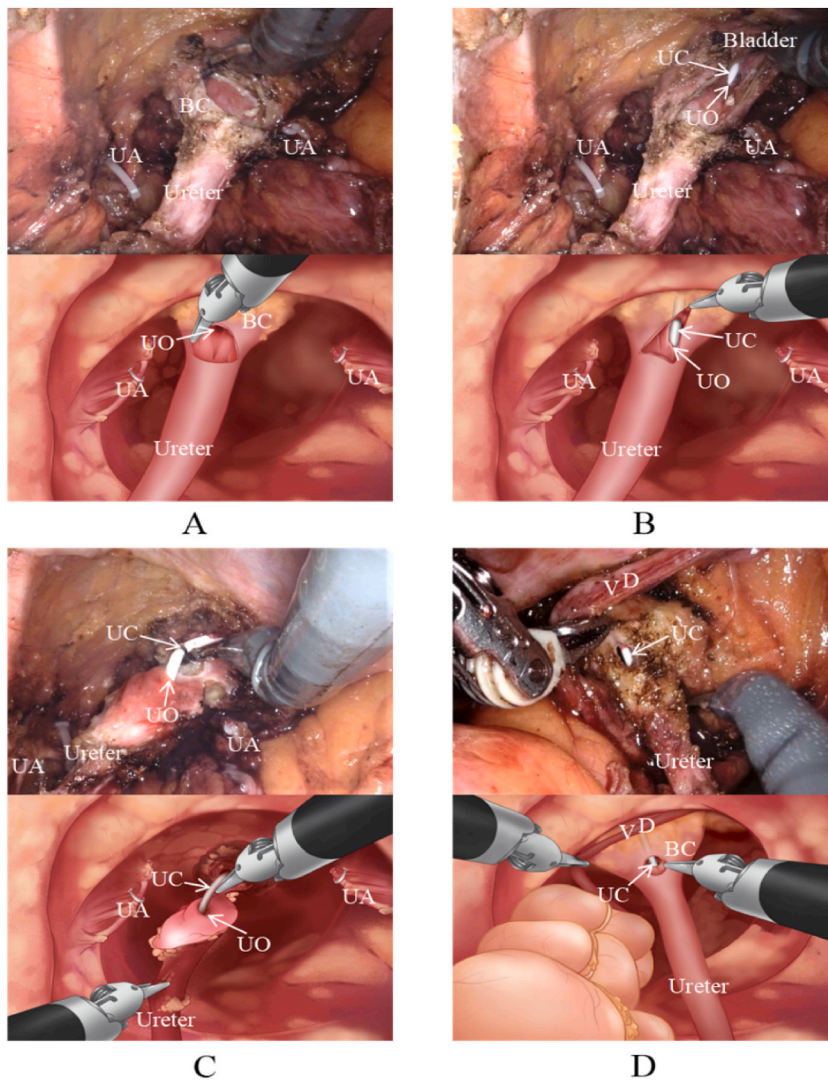


Fig. 3. Procedures in modified BCE (the corresponding schematic diagrams are shown as below). (A) The tent-shaped bladder mucosal cuff is incised, and the ureteral orifice tends to be sheltered by the bladder mucosa. (B) Guided by a ureteral catheter, the sheltered ureteral orifice is visualized clearly. (C) The bladder cuff is circumferentially excised around the ureteral orifice. (A, B, and C) The uterine artery is ligated and divided to facilitate bladder cuff excision in females. (D) In males, the vas deferens is carefully dissected and then distanced by the forceps to make an easier approach for bladder cuff dissection. BC = bladder cuff; UA = uterine artery; UC = ureteral catheter; UO = ureteral orifice; VD = vas deferens.

ureteral orifice, this method can eliminate ureteral stump tumor recurrence, which is often associated with local progression or distal metastasis. In addition to complete excision of the ureter, the modified method enables accurate and minimal BCE, thus avoiding damage to the contralateral ureteral orifice and reducing the risk of urine extravasation. Less water is injected into the urethral catheter sac (just 5 ml in our study), which facilitates urine drainage and decreases the risk of urine extravasation into the peritoneal cavity in the modified flank position. The Da Vinci Xi® robotic system allows for quick water-tight closure of the bladder wall under direct vision, thus reducing the risk of postoperative urinary fistula. With the reduced risk of urine spillage, our novel method potentially minimizes the risk of intraperitoneal tumor seeding.

In summary, one of the main benefits of this technique is its ability to provide complete visualization of the ureteral orifice during RANU, which facilitates BCE procedures and ensures complete removal of the ureter, thereby eliminating the risk of ureteral stump tumor recurrence. The precise BCE achieved through this technique can potentially minimize the risk of tumor seeding. However, it may not be suitable for distal ureteral tumors, as the inserted ureteral catheter may come into contact with the tumor, increasing the risk of intravesical recurrence. Compared to the laparoscopic approach, the flexibility of robotic arms during this surgical technique provides significant advantages in exposing the renal vessels and dissecting the distal ureter, especially in the more precise process of bladder cuff excision and bladder defect suturing. Consequently, this ensures that the distal ureter is completely resected in 100% of the cases, much higher than the 50% achieved by laparoscopic stapling technique [13]. Our minimally invasive method may avoid

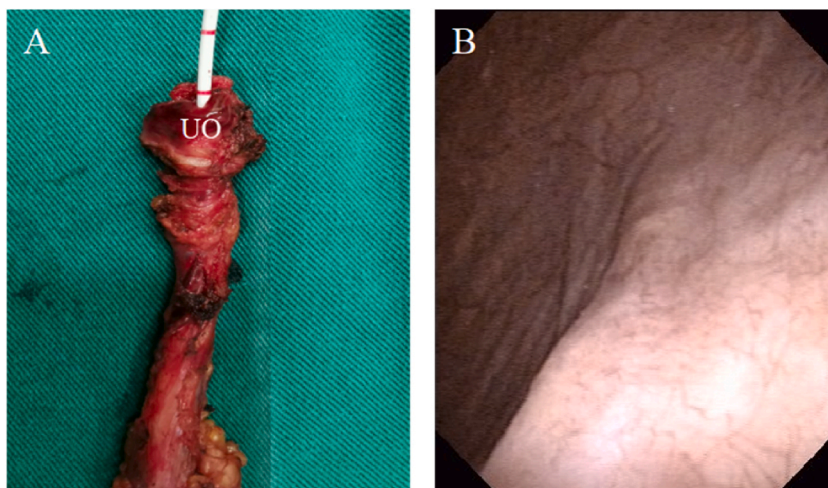


Fig. 4. Two ways to evaluate the completeness of the ureteral orifice resection. (A) Insertion of the ureteral catheter into the specimen to examine the presence of the bladder mucosa around the ureteral orifice. (B) Follow-up cystoscopy to confirm complete resection of the ipsilateral ureteral orifice. UO = ureteral orifice.

Table 2

Perioperative parameters and follow-up data.

Parameters	Group A	Group B	P value
Operative time, minutes ^{a,b}	144.5 (129.2–159.8)	152.0 (135.5–172.0)	0.223
Time for BCE, minutes ^b	9.5 (7.0–13.0)	16.0 (8.8–24.0)	0.006
Estimated blood loss, ml ^b	110.0 (90.0–150.0)	120.0 (87.5–160.0)	0.576
Postoperative hospital stay, days ^b	3.5 (2.0–5.0)	4.0 (3.0–5.0)	0.311
Complications, n (%)	0	0	1.000
Visible UO in follow-up, n (%)	0	8 (23.5)	0.005
Intravesical recurrences, n (%)	0	2 (5.9)	0.493
Recurrences at ureteric stump, n (%)	0	1 (2.9)	1.000

BCE = bladder cuff excision; UO = ureteral orifice.

^a Operative time refers to the robotic console time.

^b Continuous variables were expressed as medians (interquartile ranges).

extensive trauma by utilizing a small incision on the bladder wall compared to the open approach. In the open approach, excision of the ureter by tenting up was inadequate, with 28% of patients retaining the ureteral orifice and intramural segment of the ureter [25]. In contrast, our technique achieves complete distal ureterectomy in 100% of cases.

We used two ways to evaluate the completeness of the ureteral orifice resection. First, we inserted a ureteral catheter into the specimen after its retrieval, and checked the presence of the bladder mucosa around the ureteral orifice. Second, cystoscopy was routinely performed to confirm complete resection of the ipsilateral ureteral orifice. We reported a complete ureteral resection rate of 100% among patients undergoing our modified RANU by specimen examination and routine cystoscopy during follow-up. Together, our modification is simple, and can be easily mastered by urologists.

The limitations of this study included a small patient size and a short follow-up period. In addition, this is a single-center, retrospective study, which may bring about selection bias. To verify the better outcomes of this modified technique, prospective studies with larger patient cohorts and longer follow-up periods are required.

5. Conclusion

Our modified RANU with ureteral catheterization can provide a full visualization of the ureteral orifice to facilitate BCE procedures, thereby achieving complete ureter retrieval and reducing the risk of ureteral stump tumor recurrence. This method allows for accurate and minimal BCE, which makes the management of the bladder cuff less invasive and safely reproducible during RANU.

Ethics statement

This study was reviewed and approved by the Ethics Committee of The First Affiliated Hospital of Nanjing Medical University, with the approval number: 2023-SR-017. All participants provided informed consent to participate in the study.

Funding statement

This work was supported by Outstanding Young and Middle-aged Talents Support Program of the First Affiliated Hospital with Nanjing Medical University (Jiangsu Province Hospital), Jiangsu Province Hospital (the First Affiliated Hospital with Nanjing Medical University) Clinical Capability Enhancement Project, Suqian Sci&Tech Program (Grant No. KY202301).

Data availability statement

Data included in article/supp. material/referenced in article.

CRediT authorship contribution statement

Hao Ji: Writing – original draft, Formal analysis, Data curation. **Qikai Wu:** Investigation, Data curation. **Jianbo Ji:** Methodology, Investigation. **Yuhang Qian:** Writing – review & editing. **Lingkai Cai:** Data curation. **Kexin Bai:** Data curation. **Qiang Cao:** Project administration. **Xiao Yang:** Project administration. **Yongke Cao:** Writing – review & editing. **Qiang Lv:** Supervision, Conceptualization. **Pengchao Li:** Writing – review & editing, Supervision, Conceptualization.

Declaration of competing interest

The authors declare that they have no known competing financial interests or personal relationships that could have appeared to influence the work reported in this paper.

Acknowledgments

The authors thank the entire staff of the Department of Urology, The First Affiliated Hospital of Nanjing Medical University.

Abbreviations

BCE	Bladder cuff excision
BMI	Body mass index
CSM	Cancer-specific mortality
CT	Computed tomography
IQR	Interquartile range
RANU	Robot-assisted nephroureterectomy
RNU	Radical nephroureterectomy
UTUC	Upper urinary tract urothelial carcinoma

References

- [1] M. Roupert, et al., European association of urology Guidelines on upper urinary tract urothelial carcinoma: 2020 update, *Eur. Urol.* 79 (1) (2021) 62–79.
- [2] R.V. Clayman, et al., Laparoscopic nephroureterectomy: initial clinical case report, *J. Laparoendosc. Surg.* 1 (6) (1991) 343–349.
- [3] K. Rose, et al., Robotic assisted retroperitoneoscopic nephroureterectomy – first experience and the hybrid port technique, *Int. J. Clin. Pract.* 60 (1) (2006) 12–14.
- [4] R.A. Pathak, A.K. Hemal, Fate of residual ureteral stump in patients undergoing robot-assisted radical nephroureterectomy for high-risk upper tract urothelial carcinoma, *Transl. Androl. Urol.* 9 (2) (2020) 856–862.
- [5] D.W. Strong, H.D. Pearse, Recurrent urothelial tumors following surgery for transitional cell carcinoma of the upper urinary tract, *Cancer* 38 (5) (1976) 2173–2183.
- [6] A. Kapoor, et al., The impact of method of distal ureter management during radical nephroureterectomy on tumour recurrence (11–12), *Can Urol Assoc J* (8) (2014). E845–52.
- [7] E. Xylinas, et al., Impact of distal ureter management on oncologic outcomes following radical nephroureterectomy for upper tract urothelial carcinoma, *Eur. Urol.* 65 (1) (2014) 210–217.
- [8] L.A.N. Bragayrac, et al., Transvesical laparoendoscopic single-site management of distal ureter during laparoscopic radical nephroureterectomy, *J. Endourol.* 35 (5) (2021) 745–748.
- [9] B. Ubrig, et al., Transurethral approach to the distal ureter in nephroureterectomy: transurethral extraction vs. "pluck" technique with long-term follow-up, *Eur. Urol.* 46 (6) (2004) 741–747.
- [10] S. Morriss, H. Zargar, B.H. Dias, Management of the distal ureter during nephroureterectomy for upper tract urothelial carcinoma: a comprehensive review of literature, *Urol. J.* 18 (6) (2021) 585–599.
- [11] L.M. Krabbe, et al., Surgical management of the distal ureter during radical nephroureterectomy is an independent predictor of oncological outcomes: results of a current series and a review of the literature, *Urol. Oncol.* 32 (1) (2014) 54, e19–26.
- [12] A. Ghazi, et al., A novel approach for a complete laparoscopic nephroureterectomy with bladder cuff excision, *J. Endourol.* 24 (3) (2010) 415–419.
- [13] C.R. Ritch, et al., Comparison of distal ureteral management strategies during laparoscopic nephroureterectomy, *J. Endourol.* 25 (7) (2011) 1149–1154.
- [14] P. Liu, et al., A novel and simple modification for management of distal ureter during laparoscopic nephroureterectomy without patient repositioning: a bulldog clamp technique and description of modified port placement, *J. Endourol.* 30 (2) (2016) 195–200.
- [15] A.E. Braun, et al., Controversies in management of the bladder cuff at nephroureterectomy, *Transl. Androl. Urol.* 9 (4) (2020) 1868–1880.

- [16] J.D. Brierley, M.K. Gospodarowicz, C. Wittekind, John Wiley & Sons, TNM classification of malignant tumours (2017).
- [17] P.A. Humphrey, et al., The 2016 WHO classification of tumours of the urinary system and male genital organs-Part B: prostate and bladder tumours, *Eur. Urol.* 70 (1) (2016) 106–119.
- [18] S.F. Matin, et al., Patterns of lymphatic metastases in upper tract urothelial carcinoma and proposed dissection templates, *J. Urol.* 194 (6) (2015) 1567–1574.
- [19] A. Veccia, et al., *Single-stage Xi(R) robotic radical nephroureterectomy for upper tract urothelial carcinoma: surgical technique and outcomes.* *Minerva Urol Nephrol* 74 (2) (2022) 233–241.
- [20] D. Dindo, N. Demartines, P.A. Clavien, Classification of surgical complications: a new proposal with evaluation in a cohort of 6336 patients and results of a survey, *Ann. Surg.* 240 (2) (2004) 205–213.
- [21] A.S. Tamhankar, et al., Robot-assisted radical nephroureterectomy with extended template lymphadenectomy for upper tract urothelial carcinoma: an outcome analysis, *Indian J. Urol* 34 (3) (2018) 212–218.
- [22] L.A. McGuinness, B. Prasad Rai, Robotics in urology, *Ann. R. Coll. Surg. Engl.* 100 (6_sup) (2018) 38–44.
- [23] Z. Lee, et al., The technique of single stage pure robotic nephroureterectomy, *J. Endourol.* 27 (2) (2013) 189–195.
- [24] H. Zargar, et al., Robotic nephroureterectomy: a simplified approach requiring no patient repositioning or robot redocking, *Eur. Urol.* 66 (4) (2014) 769–777.
- [25] D.W. Strong, et al., The ureteral stump after nephroureterectomy, *J. Urol.* 115 (6) (1976) 654–655.