

UC Davis

Dermatology Online Journal

Title

Angioedema-like allergic contact dermatitis related to black henna

Permalink

<https://escholarship.org/uc/item/70q1j375>

Journal

Dermatology Online Journal, 20(2)

Authors

Gokalp, Hilal
Kaya, Kismet

Publication Date

2014

License

<https://creativecommons.org/licenses/by-nc-nd/4.0/> 4.0

Peer reviewed

Photo Vignette

Angioedema-like allergic contact dermatitis related to black henna

Hilal Gokalp MD, Kismet Kaya MD

Dermatology Online Journal 20 (20): 16

Department of Dermatology, Ministry of Health. Malatya Government Hospital, Malatya, Turkey

Correspondence:

Hilal Gokalp MD
Department of Dermatology, Ministry of Health. Malatya Government Hospital
Hastane cad, 44300, Malatya, Turkey
E-mail: hilalgklp@gmail.com

Abstract

Allergic contact dermatitis related to para-phenylenediamine (PPD) from temporary black henna tattoos and hair dyes has become an epidemic in recent years. Several cases of adverse skin reactions to PPD have been reported in the literature. Herein, we present a case of angioedema-like allergic contact dermatitis related to hair coloring with henna.

Introduction

Henna, an extract of the plant *Lawsonia inermis*, has been used for centuries in Islamic and Hindu cultures as a hair coloring and as a dye for decorating the nails or making temporary skin tattoos [1]. It is used alone or in combination with chemical coloring agents, diaminobenzenes, such as para-phenylenediamine (PPD) and/or diaminotoluenes to enhance the coloring effect and to shorten the time of application required [2]. Actually, it is rare to develop an allergic reaction to pure henna. PPD is known to be a potent skin sensitizer and it is responsible for most of the complications reported after the application of henna dyes and tattoos, which include contact dermatitis, scars, and temporary or permanent dyspigmentation. Less commonly, type 1 hypersensitivity reactions such as urticaria, angioedema, or anaphylaxis have been reported [3]. We present a case of allergic contact dermatitis with massive facial swelling owing to hair coloring with henna/PPD after sensitization from a black henna tattoo.

Case synopsis

A 23-year-old man with a history of asthma and allergic rhinitis was admitted to the emergency service because of fever, dyspnea and edema of his mouth, eyelids, and tongue that occurred one day after application of hair coloring with black henna. The patient's history was significant for a mild contact allergy to a black henna tattoo 3 years prior. Dermatological examination revealed erythematous, edematous, papulopustular, and infiltrated skin of the scalp with massive swelling of the face, lips, eyelids, and tongue (Figures 1,2). The symptoms resolved completely with systemic corticosteroids, antibiotics, and antihistamines in 2 weeks.

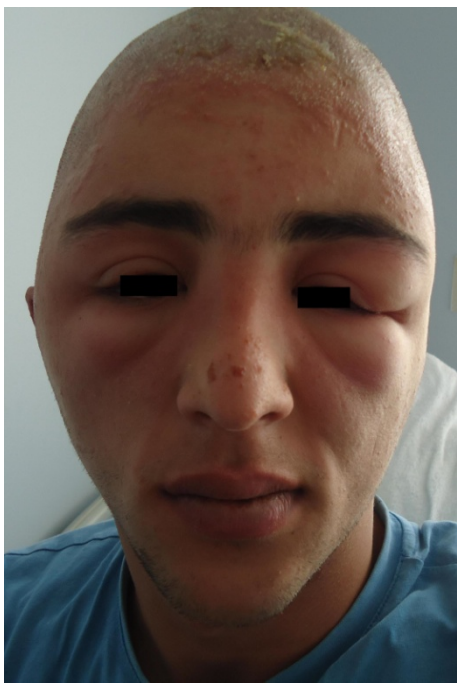

Figure 1. Massive swelling on the face, lips, and eyelids

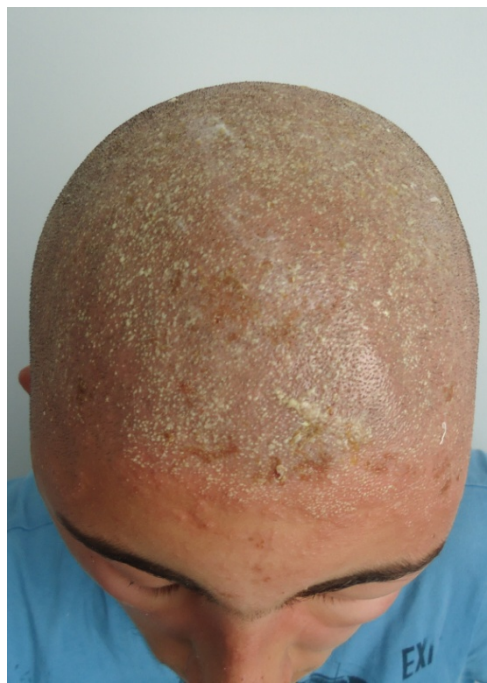

Figure 2. Erythematous, edematous, papulopustular and infiltrated skin on scalp

Following informed consent, patch tests were performed with the European Standard Series and pure henna after 4 weeks. The results of patch tests were evaluated after 48 and 72 hours. At 72 h, a strong reaction (+++) to PPD characterized by intense erythema, infiltration, and vesicles was noted. In addition, a weak reaction (+) to benzocaine, black rubber mix, and thiuram mix was documented. A negative reaction to pure henna was observed (Figure 3).

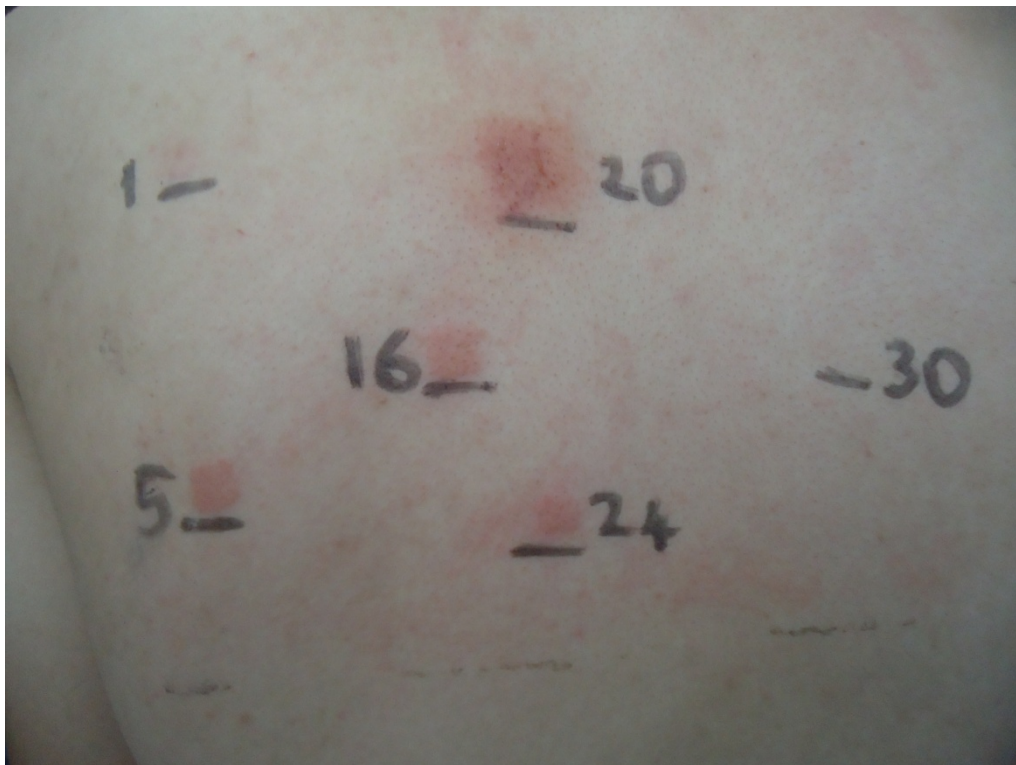


Figure 3. The results of patch tests: A strong reaction (+++) to PPD (20) and a weak reaction (+) to benzocaine (5), black rubber mix (16), thiuram mix (24)- a negative reaction to pure henna (30)

Discussion

Henna is a greenish powder made from the leaves of *Lawsonia inermis (alba)*. The active dye agent of henna is 2-hydroxy-1,4-naphthoquinone. It has been used to dye skin and hair especially in Islamic and Hindu cultures for 9000 years. However, in the last few years, temporary henna tattoos have become more popular as a safe and cheap alternative to permanent tattoos among American and European teenagers [4,5]. In contrast to permanent tattooing, there is no skin penetration, no pain, and no risk of infective agent contamination with the temporary ones.

Henna is used alone or more often mixed with other substances. Allergic reaction to pure henna is rare. Henna is commonly mixed with PPD, also known as black henna. PPD condenses the dark color, speeds up the tattooing process, and makes the tattoo last longer [5,6]. PPD is known to be a potent skin and respiratory tract sensitizer and believed to cause the majority of contact dermatitis reported with henna [7,8]. Prolonged skin contact and high concentrations of PPD increase the risk of sensitization. Despite the directive of the European Community, which allows a maximum concentration of 6% for PPD as hair dye only, it is often present in henna at high concentrations (15.7%). FDA regulations prohibit PPD skin applications in USA as well [4].

Allergic contact dermatitis, a type IV delayed hypersensitivity reaction, has been increasingly reported owing to PPD in henna since the late 1990s. The presentation can be severe, including edema of the face, scalp, and ears, which can be mistaken for angioedema [9,10]. Female gender and history of atopic diathesis are known risk factors. Face and neck areas are most commonly affected. Nevertheless, type I hypersensitivity reactions, such as urticaria, angioedema, or anaphylaxis have been reported less commonly [3,10,11]. Recently, leukoderma caused by PPD has been found to be difficult to treat, especially in the context of skin types III and IV [8,12].

Patch testing for PPD usually shows a strongly positive (+++) response and must be performed at a diluted concentration (0.01% in vaseline) to avoid exaggerated reactions and sensitization to PPD [13]. PPD sensitization can cause either direct or indirect allergic reactions. There is a significant cross-reactivity between PPD and other para-amino compounds, such as other hair dyes, textile dyes, azo dyes, local anaesthetics (benzocaine and procaine), p-amino benzoic acid sunscreen, isopropyl-para-phenylenediamine, sulfa drugs, and aminoazobenzene [4,8]. Hence, patients who test positive to PPD should use semi-permanent hair dyes, which are PPD free [9].

Conclusion

PPD is a common cause of allergic contact dermatitis especially in atopic diathesis. The risk of contact dermatitis from black henna is well known. However, practitioners should be aware of the possibility of severe reactions, similar to angioedema, as in our patient.

References

1. Almeida PJ, Borrego L, Pulido-Melián E, González-Díaz O. Quantification of p-phenylenediamine and 2-hydroxy-1,4-naphthoquinone in henna tattoos. *Contact Dermatitis* 2012;66(1):33-7. [PMID:21972791] [PubMed]
2. Le Coz CJ, Lefebvre C, Keller F, Grosshans E. Allergic contact dermatitis caused by skin painting (pseudotattooing) with black henna, a mixture of henna and p-phenylenediamine and its derivatives. *Arch Dermatol* 2000;136(12):1515-7. [PMID:11115163] [PubMed]
3. Kluger N, Raison-Peyron N, Guillot B. [Temporary henna tattoos: Sometimes serious side effects]. *Presse Med* 2008;37(7-8):1138-42. [PMID:18329233] [PubMed]
4. Corrente S, Moschese V, Chianca M, Graziani S, Iannini R, La Rocca M, et al. Temporary henna tattoo is unsafe in atopic children. *Acta Paediatr* 2007;96(3):469-71. [PMID:17407484] [PubMed]
5. Wolf R, Wolf D, Matz H, Orion E. Cutaneous reactions to temporary tattoos. *Dermatology Online Journal* 2003;9(1):3-7. [PMID:12639461] [PubMed]
6. Redlick F, DeKoven J. Allergic contact dermatitis to paraphenylenediamine in hair dye after sensitization from black henna tattoos: a report of 6 cases. *CMAJ* 2007;176(4):445-6. [PMID:17296954] [PubMed]
7. Uzuner N, Olmez D, Babayigit A, Vayvada O. Contact dermatitis with henna tattoo. *Indian Pediatr* 2009;46(5):423-4. [PMID:19478355] [PubMed]
8. Kazandjieva J, Grozdev I, Tsankov N. Temporary henna tattoos. *Clin Dermatol* 2007;25(4):383-87. [PMID:17697921] [PubMed]
9. LaBerge L, Pratt M, Fong B, Gavigan G. A 10-year review of p-phenylenediamine allergy and related para-amino compounds at the Ottawa Patch Test Clinic. *Dermatitis* 2011;22(6):332-4. [PMID:22653006] [PubMed]
10. Jasim ZF, Darling JR, Handley JM. Severe allergic contact dermatitis to paraphenylene diamine in hair dye following sensitization to black henna tattoos. *Contact Dermatitis* 2005;52(2):116-7. [PMID:15725300] [PubMed]
11. Broides A, Sofer S, Lazar I. Contact dermatitis with severe scalp swelling and upper airway compromise due to black henna hair dye. *Pediatr Emerg Care* 2011;27(8):745-6. [PMID:21822086] [PubMed]
12. Mendiratta V. Acquired leukoderma after henna tattoo in an Indian girl. *JEADV* 2009;23:582-3. PMID:19054253 [PubMed]
13. Spornraft-Ragaller P, Schnuch A, Uter W. Extreme patch test reactivity to p-phenylenediamine but not to other allergens in children. *Contact Dermatitis* 2011;65(4):220-6. [PMID:21595701] [PubMed]