

UC Irvine

Clinical Practice and Cases in Emergency Medicine

Title

Bowel Perforation in the Emergency Department Related to Bevacizumab Therapy and Recurrent Ovarian Cancer

Permalink

<https://escholarship.org/uc/item/71c686bc>

Journal

Clinical Practice and Cases in Emergency Medicine, 4(2)

Authors

Ostby, Stuart A.
Olushoga, Michael
Leath III, Charles A.
[et al.](#)

Publication Date

2020

DOI

10.5811/cpcem.2020.1.45374

Copyright Information

Copyright 2020 by the author(s). This work is made available under the terms of a Creative Commons Attribution License, available at <https://creativecommons.org/licenses/by/4.0/>

Peer reviewed

Bowel Perforation in the Emergency Department Related to Bevacizumab Therapy and Recurrent Ovarian Cancer

Stuart A. Ostby, MD*
 Michael Olushoga, MD†
 Charles A. Leath III, MD‡
 Samuel L. Burleson, MD†

*University of Alabama at Birmingham, Department of Obstetrics and Gynecology, Birmingham, Alabama

†University of Alabama at Birmingham, Department of Emergency Medicine, Birmingham, Alabama

‡University of Alabama at Birmingham, Department of Obstetrics and Gynecology, Division of Gynecologic Oncology, Birmingham, Alabama

Section Editor: Rick A. McPheeters, DO

Submission history: Submitted October 5, 2019; Revision received December 20, 2019; Accepted January 28, 2020

Electronically published March 27, 2020

Full text available through open access at http://escholarship.org/uc/uciem_cpem

DOI: 10.5811/cpcem.2020.1.45374

Case Presentation: We describe the presentation to the emergency department of a patient with recurrent ovarian cancer treated with bevacizumab with the complication of bowel perforation.

Discussion: We review the frequency and outcomes of bevacizumab-related bowel perforation. We also report the patient's imaging findings, including the radiologic presentation of free intraperitoneal air and portal venous gas, both indicative of bowel perforation and the need for emergent surgical evaluation. Our case also illustrates the potentially catastrophic side effects of bevacizumab and other targeted oncologic therapies of which emergency physicians may not be aware. [Clin Pract Cases Emerg Med. 2020;4(2):227–229.]

Keywords: *bevacizumab; oncologic emergency; bowel ischemia.*

CASE PRESENTATION

A 69-year-old, African-American female with recurrent stage IIIC ovarian carcinoma treated with bevacizumab presented to the emergency department (ED) with abdominal pain, distention, vomiting, and hypotension. After initial stabilization, an upright abdominal radiograph (Image 1) revealed peritoneal free air and portal venous gas concerning for bowel perforation, which was confirmed by computed tomography (CT) of the abdomen and pelvis (Images 2 and 3).

The patient was admitted to the gynecology oncology service and maintained on crystalloids and antibiotics. She had minimal symptoms. In accordance with her wishes, no further aggressive intervention was pursued, and she died on hospital day three.

DISCUSSION

Bevacizumab is a monoclonal antibody targeting the vascular endothelial growth factor receptor used in multiple

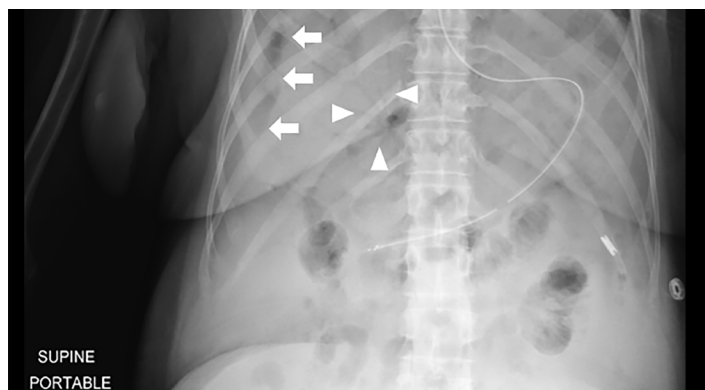


Image 1. Upright abdominal radiograph revealing free air along the lateral margin of the liver (arrows) and branching gas in the liver (triangles), concerning for portal venous gas.

cancer types, including ovarian.^{1,2} Complications include bowel perforation and gastrointestinal (GI) bleeding.³ The

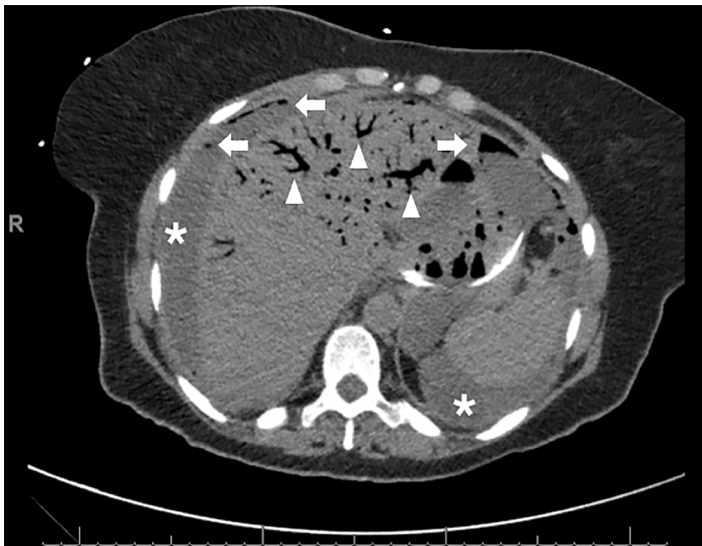


Image 2. Computed tomography scan of the abdomen revealing extensive ascites (*), intraperitoneal free air (arrows), and extensive branching portal venous gas (triangles), indicative of bowel ischemia, necrosis, and perforation.

incidence of bowel perforation in ovarian cancer treated with bevacizumab is estimated to be 2-3%,⁴ with a relative risk of 2.57 compared to ovarian cancer alone.⁵ Bowel perforation and other severe GI pathologies are seen with other commonly-used targeted therapies such as sunitinib, sorafenib, everolimus, and temsirolimus.⁶ This patient had

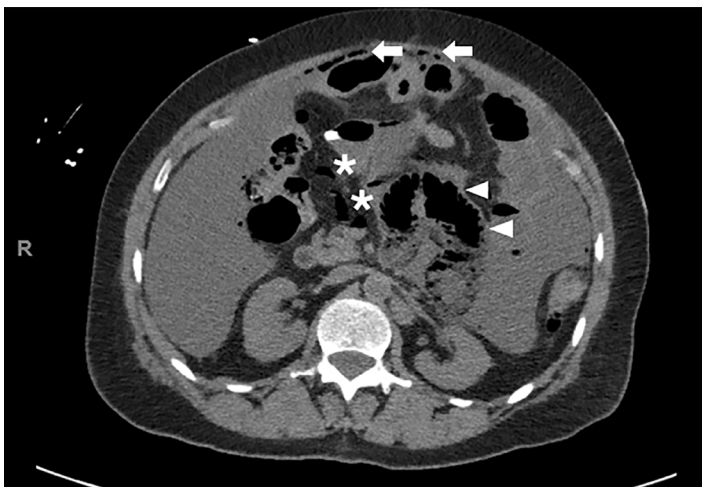


Image 3. Computed tomography of the abdomen revealing intraperitoneal free air (arrows), bowel wall pneumatosis (triangles), and air in the mesenteric vasculature (*).

CPC-EM Capsule

What do we already know about this clinical entity?

Bevacizumab is an increasingly used targeted chemotherapeutic agent with infrequent, severe complications including gastrointestinal perforation.

What is the major impact of the image(s)?

Severe ischemic bowel related to bevacizumab therapy and widespread diagnostic findings of mesenteric ischemia, portal venous gas, and free air are demonstrated.

How might this improve emergency medicine practice?

Early recognition and diagnosis for bowel perforation in patients on bevacizumab is essential to allow prompt surgical evaluation and therapy.

other independent risk factors for perforation including bowel resection-reanastomosis, peritoneal carcinomatosis, and partial small bowel obstructions.

Bowel perforation secondary to bevacizumab has an estimated 60-day mortality of 25%.² The diagnosis is confirmed by radiographs or CT of the abdomen demonstrating intraperitoneal free air, pneumatosis intestinalis, or portal venous gas. While management is generally surgical, supportive care, including antibiotics, parenteral nutrition, and fluid resuscitation, has been successful in poor surgical candidates.

In summary, we report a case of bowel perforation related to bevacizumab therapy. This case demonstrates the potentially life-threatening side effects of bevacizumab and other frequently-used, targeted therapies requiring ED diagnosis and resuscitation, and the complex imaging findings associated with the diagnosis of bowel perforation in a patient with recurrent ovarian cancer.

The documented Institutional Review Board Policy has been obtained and filed for publication of this case report.

Address for Correspondence: Samuel Burleson, MD, University of Alabama at Birmingham, Department of Emergency Medicine, Old Hillman Building Suite 251, 619 19th St. S, Birmingham, AL 35249. Email: slburleson@uabmc.edu.

Conflicts of Interest: By the CPC-EM article submission agreement, all authors are required to disclose all affiliations, funding sources and financial or management relationships that could be perceived as potential sources of bias. The authors disclosed none.

Copyright: © 2020 Ostby et al. This is an open access article distributed in accordance with the terms of the Creative Commons Attribution (CC BY 4.0) License. See: <http://creativecommons.org/licenses/by/4.0/>

REFERENCES

1. Liu FW, Cripe J, Tewari KS. Anti-angiogenesis therapy in gynecologic malignancies. *Oncology (Williston Park)*. 2015;29;350-60.
2. Badgwell BD, Camp ER, Feig B, et al. Management of bevacizumab-associated bowel perforation: a case series and review of the literature. *Ann Oncol* 2007. 19;577-82.
3. Bamias A, Gibbs E, Khoon Lee C, et al. Bevacizumab with or after chemotherapy for platinum-resistant recurrent ovarian cancer: exploratory analyses of the AURELIA trial. *Ann Oncol*. 2017;28;1842-8.
4. Han E and Monk B. What is the risk of bowel perforation associated with bevacizumab therapy in ovarian cancer? *Gynecol Oncol*. 2007;105;3-6.
5. Burger RA, Brady MF, Bookman MA, et al. Risk factors for GI adverse events in a phase III randomized trial of bevacizumab in first-line therapy of advanced ovarian cancer: a gynecologic oncology group study. *J Clin Oncol*. 2014;32;1210-7.
6. Thornton E, Howard SA, Jagannathan J, et al. Imaging features of bowel toxicities in the setting of molecular targeted therapies in cancer patients. *Br J Radiol*. 2012;85(1018):1420-6.