

UC Davis

Dermatology Online Journal

Title

Lipoid Proteinosis: a case report in two siblings

Permalink

<https://escholarship.org/uc/item/72c3461z>

Journal

Dermatology Online Journal, 21(3)

Authors

Ranjan, Rashmi
goel, khushbu
sarkar, rashmi
[et al.](#)

Publication Date

2015

Supplemental Material

<https://escholarship.org/uc/item/72c3461z#supplemental>

License

<https://creativecommons.org/licenses/by-nc-nd/4.0/> 4.0

Peer reviewed

Photo Vignette

Lipoid Proteinosis: a case report in two siblings

Rashmi Ranjan MD, Khushbu Goel MD, Rashmi Sarkar MD MNAMS, Vijay K Garg MD MNAMS

Dermatology Online Journal 21 (3): 20

Department of Dermatology, Maulana Azad Medical College and Lok Nayak Hospital, New Delhi, India

Correspondence:

Dr. Rashmi Sarkar
Professor
Department of Dermatology,
Maulana Azad Medical College
Lok Nayak Hospital, New Delhi
Email : rashmisarkar@gmail.com

Abstract

Lipoid proteinosis was first reported by Urbach and Wiethe in 1929. It is also known as hyalinosis cutis et mucosae or Urbach-Wiethe disease. It is a rare autosomal recessive disorder and characterized by the infiltration of hyaline material in the skin, oral cavity, larynx, and internal organs. Lipid proteinosis presents early in life. Hoarseness develops in infancy. The classic sign is beaded eyelid papules along the lid margin, also known as 'Moniliform Blepherosis'. In India about 30 cases have been reported to date. We report the following case because of its rarity in the Indian literature.

Keywords: Lipoid proteinosis, Urbach-Wiethe disease, Moniliform blepherosis

Introduction

Lipoid proteinosis is also known as hyalinosis cutis et mucosae or Urbach-Wiethe disease. The condition was first reported by Urbach and Wiethe in 1929. It is a rare autosomal recessive disorder. It is characterized by the infiltration of hyaline material in the skin, oral cavity, larynx, and internal organs. The exact pathogenesis of this disease is unknown [1,2]. It usually presents in infancy with hoarseness of voice. Beaded eyelid papules are the classical finding [3]. It is diagnosed clinically and by histopathological examination, but has no effective treatment.

There are only about 300 cases that have been reported in the literature. Occurrence of lipoid proteinosis in siblings is also rare. In India there are about 30 reported cases. We report the following patient because of its rarity in the Indian literature.

Case synopsis

A 16-year-old girl presented to our department with chief complaints of multiple raised lesions over neck and bilateral dorsum of hands, along with multiple raised yellowish papules over the lid margins since 2 years of age. She also complained of hoarseness of voice since infancy.

Her sister also had similar complaints since infancy and a similar clinical appearance. There was no history of seizures and her intelligence was normal.

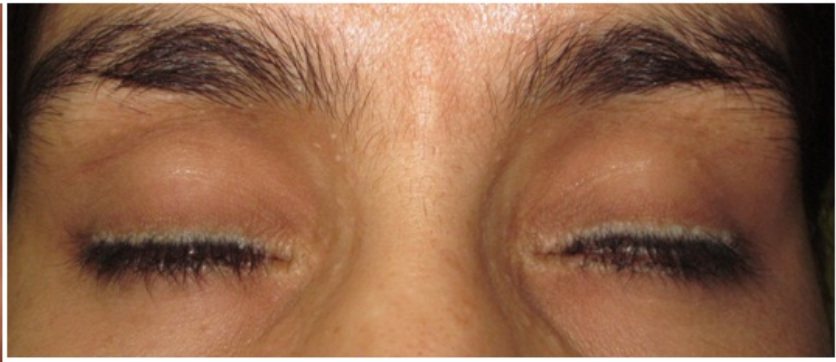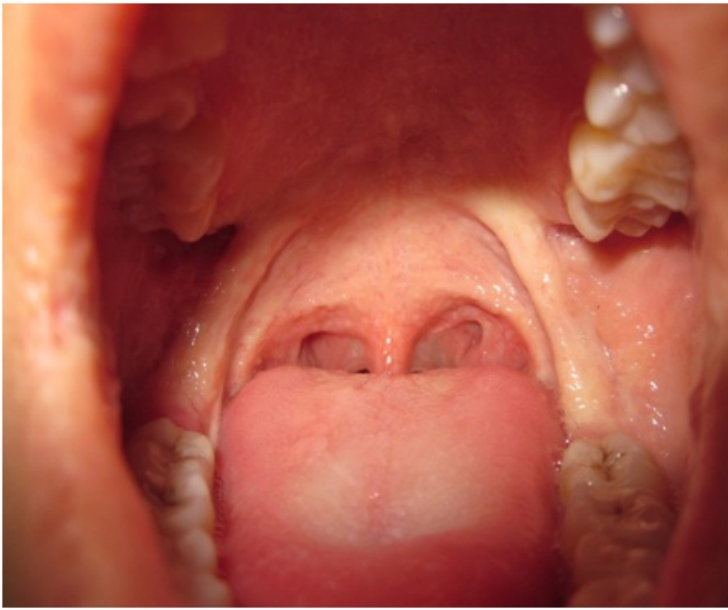


Figure 1. Multiple well defined, skin colored to waxy yellowish, beaded papules, arranged in linear pattern were seen over bilateral eyelid margins. **Figure 2.** Thickening of the frenulum of tongue and waxy yellow -white infiltration present over the anterior and posterior pillar of tonsils and soft palate

On examination multiple well defined, skin colored to waxy yellowish, beaded papules, linearly arranged were seen over bilateral eyelid margins. Also multiple waxy yellowish to skin colored papules of pin point to 0.5x0.5 cm in size were present over the neck and dorsum of hands. The patient also exhibited a few pock-like scars over the face.

Oral cavity examination revealed thickening of the frenulum of the tongue; the patient was not able to protrude the tongue completely. There was waxy yellow-white infiltration present over the anterior and posterior pillar of tonsils and soft palate.

Fiberoptic examination of the larynx showed whitish yellowish deposition over the palate, epiglottis, and bilateral false vocal cord above arytenoids.

Eye examination and all blood investigations were normal.

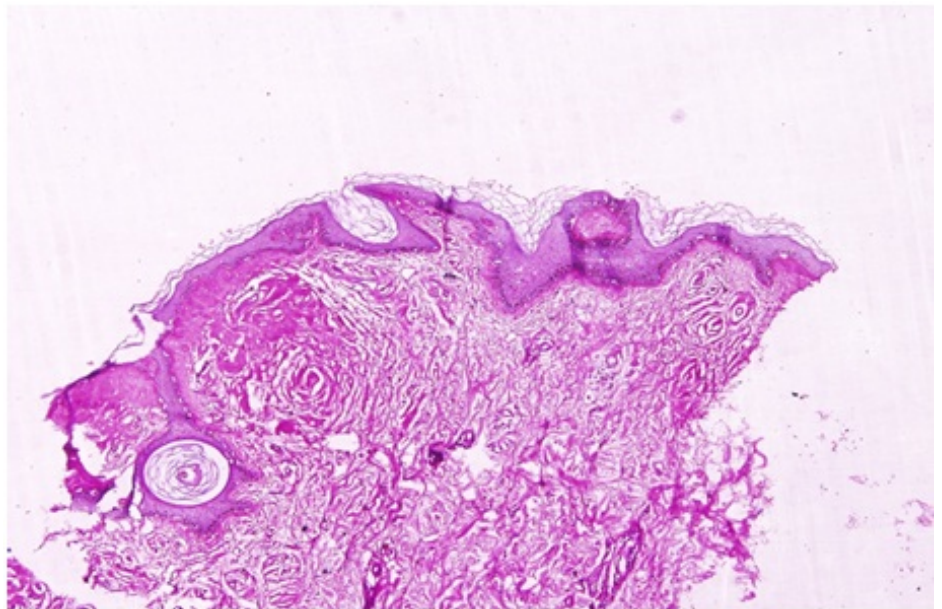
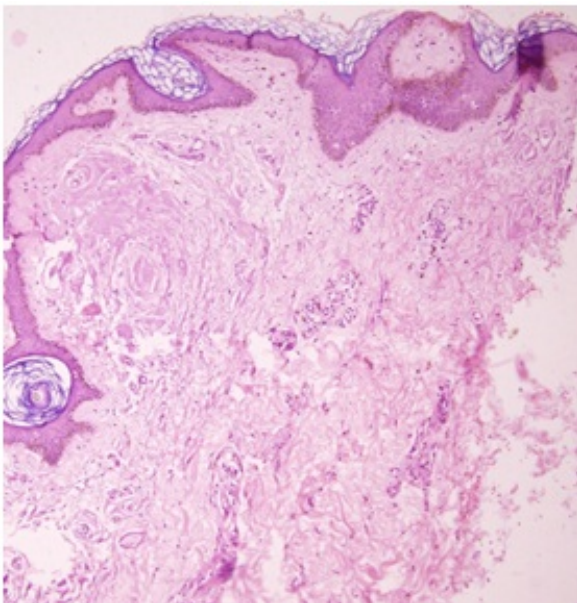


Figure 3: Histopathological examination (H&E) showed that epidermis was mildly hyperkeratotic. Upper dermis showed amorphous hyaline deposition in extracellular space. **Figure 4:** PAS positive eosinophilic amorphous hyaline deposition in extracellular space in dermis. Hyaline deposit was also present around perivascular region with thickening of vessel wall

Histopathological examination showed that the epidermis was mildly hyperkeratotic. The upper dermis showed a PAS positive eosinophilic amorphous hyaline deposition in the extracellular space. Hyaline deposit was also present around the perivascular region with thickening of the vessel wall. Congo red stain was negative.

An X-ray of the skull was taken but no calcification was seen.

On the basis of examination findings and biopsy, a diagnosis of lipid proteinosis was made.

Discussion

Lipoid proteinosis (Urbach-Wiethe disease) is a rare, chronic, autosomal recessive disorder characterized by papules, indurated plaques, and sometimes ulcerated lesions healing with pock-like scarring. This condition appears to be more common in Europeans, with both sexes being affected equally. It primarily involves the skin and mucous membranes. The lesions are produced by accumulation of hyaline-like material in various connective tissue sites [1- 5].

The disorder has recently been shown to result from loss-of-function mutations in the extracellular matrix protein 1 gene on chromosome 1q21. The function of the protein extracellular matrix protein 1 gene is still unclear [3]. Lipid proteinosis presents early in life. Hoarseness develops in infancy and becomes prominent within the first few years of life. It is caused by infiltration of the laryngeal mucosa. The mucosae of the pharynx, tongue, and lips soon develop firm, yellow-white infiltrates. The frenulum of the tongue becomes infiltrated and thickened, which leads to tongue-tying. Skin changes become prominent in early life with the development of yellow-brown papules and nodules on the face and lips. These lesions may ulcerate and heal with acne-like scars that may be seen on the face as well as on non-acne prone regions of the body. The classic and most recognizable sign is the beaded eyelid papules along the lid margin, also known as 'moniliform blepharosis'. Translucent, verrucous, keratotic papules are seen on the elbows and knees.

In classic cases the most characteristic radiological findings are bilateral, fairly dense, para-cellular, symmetrical, and regular calcifications. Fifty percent of cases may have oval symmetrical intracranial calcification of the hippocampal gyri [3]. No specific laboratory finding is seen in lipid proteinosis.

On histopathology, the epidermis shows hyperkeratosis and irregular acanthosis. The dermis is thickened with deposition of extracellular, homogenous, hyaline material seen in the upper half. The hyaline material is at first deposited along the course of capillaries, in arrector pili muscles, and concentrically around sweat coils. Hyaline material stains strongly with PAS stain. Surrounding the blood vessels, there is reduplication of basal laminae in an 'onion skin' arrangement. It is suggested that there is overproduction of basement membrane collagens (Type IV and V) by the endothelial cells of blood vessels and underproduction of fibrous collagens (Type I and II) [1-5].

The disease must be differentiated from erythropoietic porphyria. In the latter, the lesions are found mainly in the sun-exposed areas and the mucous membranes are not involved. Other diseases in the differential diagnosis to be ruled out histologically are amyloidosis, lichen myxedematosus, and xanthomatosis.

As the exact pathogenesis of this disease is unknown, there is presently no effective therapy for lipid proteinosis. Various treatment modalities including dimethyl sulfoxide, etretinate, acitretin, penicillamine, surgical procedures, carbon dioxide laser, and dermabrasion have been used with variable results [6 -10]. Conservative treatment only has been given to our patient. Generally, lipid proteinosis is benign and patients have normal life expectancy.

Table 1. Lipoid proteinosis case reports from India

| Serial No. | Authors and journals | Publication type | Age / Sex | Additional findings |
|------------|---|------------------|--------------|----------------------------|
| | Ranjan et al, Ophthalmic Genet. 2013 ¹¹ | Case report | 8 y / female | |
| | Ravi Prakash et al Saudi Dent J. 2013 April ¹² | Case report | 32 y / male | |
| | Kachewar et al, J Clin Diagn Res. 2012 November ¹³ | Case report | 52 y /male | Intracranial calcification |
| | Parmar et al, Indian J Dermatol Venereol Leprol. | Case report | 6 y / male | |

| | | | | |
|--|---|-------------|--|----------------------|
| | 2013 ¹⁴ | | | |
| | Gutte et al, Indian Dermatol Online J. 2012 May-Aug ¹⁵ | Case report | 3.5 y / female | |
| | Nayak et al, Indian Dermatol Online J. 2012 Jan ¹⁶ | Case report | 6 y / female | |
| | Kuchabal et al, Int J Dermatol. 2011 Aug ¹⁷ | Case report | 5 patients | |
| | Mainali et al, J Indian Soc Pedod Prev Dent. 2011 Jan-Mar ¹⁸ | Case report | 12 y / female | |
| | Sainani et al, Int Ophthalmol. 2011 Apr ¹⁹ | Case report | One patient | |
| | Naha et al, Australas Med J. 2011 ²⁰ | Case report | 19 y / male | |
| | Rao et al, J Oral Maxillofac Pathol. 2009 Jul ²¹ | Case report | 62 y / male | |
| | Srivalli et al, Indian J Otolaryngol Head Neck Surg. 2009 January ²² | Case report | 2 siblings 12 y / female 5 y / male | |
| | Batra et al, Ear Nose Throat J. 2008 Sep ²³ | Case report | 12 y / female | |
| | Rao et al, Dermatol Online J. 2008 Jul ²⁴ | Case report | 2 y / female | |
| | Venkatesh et al, J Cataract Refract Surg. 2007 Aug ²⁵ | Case report | One patient | B/L lens subluxation |
| | Yadava et al, Pathology. 2006 Dec ²⁶ | Case report | One patient | |
| | Kini et al, Dermatol Online J. 2006 Jan ²⁷ | Case report | 12 y / male | |
| | Vedamurthy et al, Dermatol Online J. 2003 Dec ²⁸ | Case report | 2 siblings 16 y / female 11 y / female | |
| | Shivaswamy et al, Dermatol | Case report | 6 y / female | |

| | | | | |
|--|--|-------------|-------------|--|
| | Online J.2003 Dec ²⁹ | | 9 y / male | |
| | Sethuraman et al, J Dermatol. 2003 Jul ³⁰ | Case report | 2 siblings | |
| | Shah et al, Indian J Dermatol Venereol Leprol.1996 Nov-Dec ³¹ | Case report | 20 y / male | |
| | Singh et al, Int J Dermatol.1988 Jun ³² | Case report | One patient | |
| | Ramanan et al, Indian J Dermatol.1983 Oct ³³ | Case report | One patient | |

References

1. Dogramaci AC, Celik MM, Celik E, Bayarogullari H. Lipoid proteinosis in the eastern Mediterranean region of Turkey. Indian J Dermatol Venereol Leprol 2012;78:318-22. [PMID:22565431]
2. Kuchabal SD. Lipoid proteinosis in two families. Int J Dermatol. 2011 Aug;50(8):972-5. [PMID:21781070]
3. Hamada T. Lipoid proteinosis. Clin Exp Dermatol. 2002 Nov;27(8):624-9.[PMID:12472532]
4. Topkarci Z, Yazganoglu KD, Azizlerli G, Baykan B. Lipoid proteinosis: a case series From Istanbul. Int J Dermatol. 2007 Oct;46(10):1011-6.[PMID:17910705]
5. Galadari I, and Al-Kuwaiti R. Lipoid proteinosis: a case report. International Journal of Dermatology 2004, 43, 368-370. [PMID:15117370]
6. Wong CK, Lin CS. Remarkable response of lipoid proteinosis to oral dimethyl sulphoxide. Br J Dermatol. 1988 Oct;119(4):541-4.[PMID:3191019]
7. Kaya TI, Kokturk A, Tursen U, Ikizoglu G, Polat A. D-penicillamine treatment for lipoid proteinosis. Pediatr Dermatol. 2002 Jul-Aug;19(4):359-62.[PMID:12220287]
8. Gruber F, Manestar D, Stasic A, Grgurevic Z. Treatment of lipoid proteinosis with etretinate. Acta Derm Venereol 1996;76:154-5.[PMID:8740275]
9. Toosi S, Ehsani AH. Treatment of lipoid proteinosis with acitretin: a case report. J Eur Acad Dermatol Venereol. 2009 Apr;23(4):482-3.[PMID:18808438]
11. Buchan NG, Kemble JV. Successful surgical treatment of lipoid proteinosis. Br J Dermatol 1974;90:561-6. [PMID:4833793]
12. Ranjan P, Mishra D, Pelsec T, Pratap VB, Singh AD. Familial Moniliform Blepharosis: Clinical, Histopathological and Genetic Correlation.Ophthalmic Genet. 2013 Sep 30. [PMID:24079542]
13. Ravi Prakash SM, Verma S, Sumalatha MN, Chattopadhyay S. Oral manifestations of lipoid proteinosis: A case report and literature review. Saudi Dent J. 2013 Apr;25(2):91-4.[PMID:23960561]
14. Kachewar SG, Kulkarni DS. A novel association of the additional intracranial calcification in lipoid proteinosis: a case report. J Clin Diagn Res. 2012 Nov;6(9):1579-81. [PMID:23285466]
15. Parmar NV, Krishna CV, De D, Kanwar AJ, Saikia UN. Papules, pock-like scars, and hoarseness of voice. Lipoid proteinosis. Indian J Dermatol Venereol Leprol. 2013 Jan-Feb;79(1):136.[PMID:23254755]
16. Gutte R, Sanghvi S, Tamhankar P, Khopkar U. Lipoid proteinosis: Histopathological characterization of early papulovesicular lesions. Indian Dermatol Online J. 2012 May;3(2):148-9.
17. Nayak S, Acharjya B.Lipoid proteinosis in a six-year-old child. Indian Dermatol Online J. 2012 Jan;3(1):25-7. [PMID:23130256]
18. Kuchabal SD, Kuchabal DS, Lipoid proteinosis in two families. Int J Dermatol. 2011 Aug;50(8):972-5.[PMID:21781070]
19. Mainali S, Nayak R, Gaur S. Oral findings in a child with lipoid proteinosis: a case report and review. J Indian Soc Pedod Prev Dent. 2011 Jan-Mar;29(1):62-7.[PMID:21521922]
20. Sainani MP, Muralidhar R, Parthiban K, Vijayalakshmi P. Lipoid proteinosis of Urbach and Weithe: case report and a brief review of the literature. Int Ophthalmol. 2011 Apr;31(2):141-3.[PMID:21267630]
21. Naha K, Shastry AB, Saravu K, Bhatia S. Lipoid proteinosis mimicking congenital immunodeficiency: a case report. Australas Med J. 2011;4(3):155-9.[PMID:23390465]
22. Rao RS, Betkerur SS, Babu C, Sudha V. Lipoid proteinosis. J Oral Maxillofac Pathol. 2009 Jul;13(2):81-4. [PMID:21887007]

23. Srivalli M, Qaiyum HA, Moorthy PN. Lipoid proteinosis of the larynx in siblings: exploring new modalities of treatment. *Indian J Otolaryngol Head Neck Surg.* 2009 Jan;61(Suppl 1):59-61.[PMID:23120672]
24. Batra K, Safaya A, Aggarwal K. Lipoid proteinosis (Urbach-Wiethe disease): a case report from India. *Ear Nose Throat J.* 2008 Sep;87(9):531-2.[PMID:18800328]
25. Rao R, Prabhu SS, Sripathi H, Gupta S. Vesicubullous lesions in lipoid proteinosis: a case report. *Dermatol Online J.* 2008 Jul 15;14(7):16.[PMID:18718200]
26. Mandal S, Dutta P, Venkatesh P, Sinha R, Kukreja M, Garg S. Bilateral lens subluxation in a case of lipoid proteinosis. *J Cataract Refract Surg.* 2007 Aug;33(8):1469-70.[PMID:17662444]
27. Yadava U, Khurana N, Mehta S. Lipoid proteinosis: a case report. *Pathology.* 2006 Dec;38(6):600-2.[PMID:17394000]
28. Kini S, Jain A, Shet TM, Bansode S, Vora IM, Ghorpade K. Lipoid proteinosis in a 12-year-old child: a report from west India. *Dermatol Online J.* 2006 Jan 27;12(1):10. [PMID:16638378]
29. Vedamurthy M. Lipoid proteinosis in siblings. *Dermatol Online J.* 2003 Dec;9(5):13 [PMID:14996386]
30. Shivaswamy KN, Thappa DM, Laxmisha C, Jayanthi S. Lipoid proteinosis in two siblings: a report from south India. *Dermatol Online J.* 2003 Dec;9(5):12.[PMID:14996385]
31. Sethuraman G, Tejasvi T, Khaitan BK, Handa KK, Rao S, Singh MK, Sirka C, Sharma VK. Lipoid proteinosis in two siblings: a report from India. *J Dermatol.* 2003 Jul;30(7):562-5. [PMID:12928549]
32. Shah MK, Shah PP, Rawal RC, Bilimoria FE. Lipoid proteinosis. *Indian J Dermatol Venereol Leprol.* 1996 Nov-Dec;62(6):375-6.[PMID:20948132]
33. Singh G, Misra D. Lipoid proteinosis, *Int J Dermatol.* 1988 Jun;27(5):344-5.[PMID:3391730]
34. Ramanan C, Nandi BN, Iqbal MS. Lipoid proteinosis. A case report. *Indian J Dermatol.* 1983 Oct;28(4):183-8. [PMID:6671707]