

Darier-White disease

Mitalee P. Christman, MD, Evan Rieder, MD, Randie H. Kim, MD PhD, Nooshin Brinster, MD, Alisa Femia, MD, Miriam Keltz Pomeranz, MD

Ronald O. Perelman Department of Dermatology, NYU School of Medicine, NYU Langone Medical Center

Abstract

We present a 58-year-old woman with bipolar disorder and with a longstanding history of yellow-brown, hyperkeratotic papules in a seborrheic distribution and nail changes. Her father and paternal grandmother had similar eruptions and also had psychiatric disease. Histopathologic examination showed acantholysis and dyskeratosis, which was consistent with Darier-White disease. Darier-White disease is a rare, hereditary disorder that is inherited in an autosomal dominant manner and that usually presents in adolescence or early adulthood due to mutations in the SERCA2 calcium pump. The resultant alterations in calcium homeostasis affect desmosome assembly and lead to acantholysis and apoptosis, which creates the characteristic eruption. Genetic linkage analysis of affected families shows that a susceptibility locus for bipolar disorder co-segregates with genetic markers that are found in the Darier-White disease region. Treatments, which include topical emollients, mild keratolytics, and topical or oral retinoids, are aimed at improving the appearance of skin, relieving symptoms, and preventing or treating infectious complications.

Case Presentation

PATIENT: 58-year-old woman

DURATION: Since adolescence

DISTRIBUTION: Chest, back, intertriginous areas, and arms

HISTORY: A 58-year-old woman with a history of bipolar disorder presented with pruritic, erythematous and hyperkeratotic papules on her chest, back, and arms, intertriginous areas that

emerged during adolescence. The lesions were occasionally pruritic and malodorous. The symptoms were worsened by heat, friction, and sweat. In the preceding years, the patient had been treated for bacterial superinfection of her inframammary folds with intravenous antibiotics and also for cutaneous herpes simplex virus infection with oral acyclovir. Social history included alcohol abuse. The family history included a similar eruption in her father and paternal grandmother, both of whom also had undiagnosed psychiatric diseases.

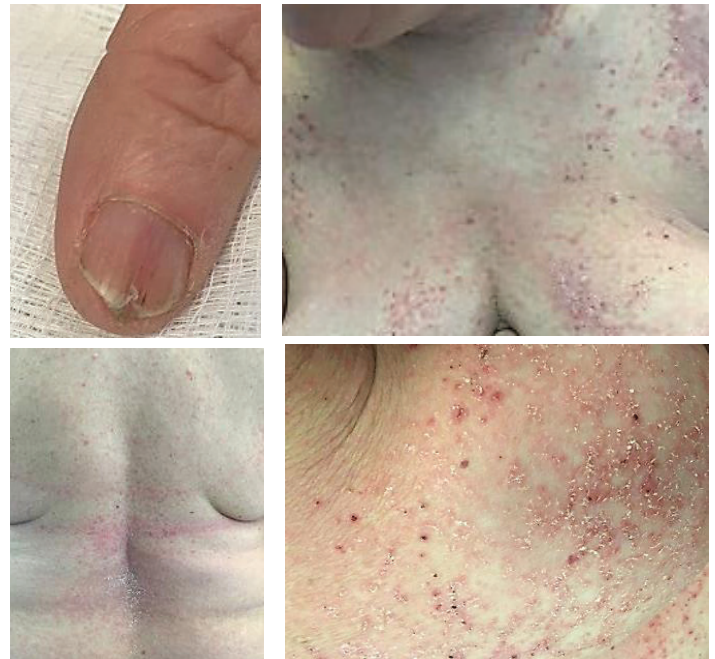

Figure 1. Fingernail with v-shaped notch along the free margin and parallel red bands. Torso with erythematous papules and yellow-to-flesh-colored, crusted keratotic papules coalescing into plaques.

PHYSICAL EXAMINATION: On the chest, lower back, and upper arms, there were erythematous papules and yellow-to-flesh-colored, crusted keratotic papules that coalesced into plaques. The axillae and inframammary folds had macerated

plaques. The palms had a few pits. Some fingernails had thin nail plates, chips, cracks, v-shaped notches along the free margins, and parallel red bands (**Figure 1**).

LABORATORY DATA: None

HISTOPATHOLOGY: Within the epidermis, there are multiple foci of suprabasilar acantholysis with dyskeratosis of keratinocytes (**Figure 2**).

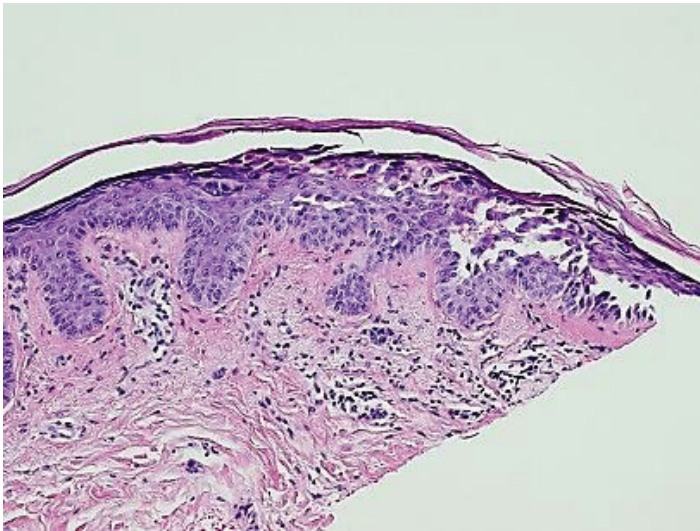


Figure 2. Multiple foci of suprabasilar acantholysis with dyskeratosis of keratinocytes within the epidermis.

DIAGNOSIS: Darier-White disease

Discussion

Darier-White disease is a rare, hereditary disorder that is inherited in an autosomal dominant manner and that usually presents in adolescence or early adulthood. The condition is caused by mutations in the ATP2A2 gene on chromosome 12q23-24.1 that encodes the sarcoplasmic/endoplasmic reticulum calcium-ATP isoform 2 protein (SERCA2), which is a calcium pump [1]. One proposed theory is that this mutation probably results in imbalances in calcium homeostasis, which leads to improper desmosome assembly, abnormal keratinocyte adhesion, acantholysis, and apoptosis of keratinocytes [2,3].

The disease presents with a hyperkeratotic, papular eruption in a seborrheic distribution. The lesions are frequently pruritic and characterized by greasy, crusted, keratotic, yellow-brown papules and plaques that are found particularly on the

seborrheic areas of the body – the scalp, forehead, ears, nasolabial folds, upper chest, back, and supraclavicular fossae [4]. These lesions may be induced or exacerbated by stress, heat, sweating, and maceration, and in the intertriginous areas they may be vegetative, malodorous, and often secondarily infected with bacterial, dermatophyte, and viral infections [5, 6, 7]. Additional features include pits and punctate keratosis on the palms and soles. Nail changes include painful splits, subungual hyperkeratosis, and, most characteristically, longitudinal white or red streaks, some of which terminate in a v-shaped notch on the free margin [4, 8]. Oral lesions may consist of small white papules on the hard palate.

Mood disorders, epilepsy and mental impairment have been reported in association with Darier-White disease [9, 10]; however, it is unclear whether mutations in ATP2A2 are associated with these disorders. A recent, matched cohort study from Swedish national registries showed that individuals with Darier-White disease had a four times higher risk of a bipolar disorder and a two times higher risk of schizophrenia [11]. Genetic linkage analysis in families with concurrence of Darier-White disease and psychiatric diseases suggests that a susceptibility locus for bipolar disorder cosegregates with genetic markers found in the Darier-White disease region but is distinct from the gene for Darier-White disease [12, 13].

As there is no cure for Darier-White disease, the goal of treatment is improvement of the appearance of skin, relief of symptoms, and prevention or treatment of any infectious complications. Topical retinoids, such as tretinoin, adapalene, or tazarotene may be used; however, irritation is common and may lead to erosions. Irritation may be treated with low-to-medium potency topical glucocorticoids. Systemic retinoids, such as isotretinoin or acitretin, may be used to decrease hyperkeratosis and reduce odor in patients with severe or generalized disease. This patient has declined treatment with isotretinoin owing to her psychiatric comorbidities and also declined acitretin after being counseled about the risks and benefits. She is undergoing treatment with emollients and mild topical keratolytics.

References

1. Sakuntabhai A, et al. Mutations in ATP2A2, encoding a Ca²⁺ pump, cause Darier disease. *Nat Genet* 1999; 21: 271
2. Dhitavat J, et al. Calcium pumps and keratinocytes: lessons from Darier's disease and Hailey-Hailey disease. *Br J Dermatol* 2004; 150: 821
3. Dhitavat J, et al. Impaired trafficking of the desmoplakins in cultured Darier's disease keratinocytes. *J Invest Dermatol.* 2003; 121: 1349
4. Burge S, Wilkinson JD: Darier-White disease: a review of the clinical features in 163 patients. *J Am Acad Dermatol* 1992; 27: 40
5. Burge SM, et al. Darier's disease: a focal abnormality of cell adhesion. *J Cutan Pathol* 1990; 17:160
6. Tatnall FM, et al. Darier's disease: a large family tree with two unusual complications. *Br J Dermatol* 1983; 109 (Suppl 24):49
7. Wheeland RG, et al. Localized Darier's disease of the scalp complicated by *Trichophyton tonsurans* infection. *Arch Dermatol* 1985; 121:905
8. Burge SM. Darier's disease – the clinical features and pathogenesis. *Clin Exp Dermatol* 1994; 19:193
9. Gordon-Smith K, et al. The neuropsychiatric phenotype in Darier disease. *Br J Dermatol* 2010; 163:515
10. Dodiuk-Gad R, et al. Learning disabilities in Darier's disease patients. *J Eur Acad Dermatol Venereol* 2014; 28:314
11. Cederlof M, et al. The association between Darier disease, bipolar disorder, and schizophrenia revisited: a population-based family study. *Bipolar Disorders* 2015; 17: 340
12. Jones I, et al. Evidence for familial cosegregation of major affective disorder and genetic markers flanking the gene for Darier's disease. *Mol Psychiatry* 2002; 7:424
13. Green E, et al. Localization of bipolar susceptibility locus by molecular genetic analysis of the chromosome 12q23-q24 region in two pedigrees with bipolar disorder and Darier's disease. *Am J Psychiatry* 2005; 162:35