

UCSF

UC San Francisco Previously Published Works

Title

Acute Respiratory Distress Syndrome in a Preterm Pregnant Patient With Coronavirus Disease 2019 (COVID-19).

Permalink

<https://escholarship.org/uc/item/7973h0wc>

Journal

Obstetrics and Gynecology, 136(1)

ISSN

1099-3630

Authors

Blauvelt, Christine A
Chiu, Catherine
Donovan, Anne L
et al.

Publication Date

2020-07-01

DOI

10.1097/aog.0000000000003949

Peer reviewed

Case Report

Acute Respiratory Distress Syndrome in a Preterm Pregnant Patient With Coronavirus Disease 2019 (COVID-19)

Christine A. Blauvelt, MD,
Catherine Chiu, MD,
Anne L. Donovan, MD,
Mary Prah, MD,
Thomas K. Shimotake, MD,
Ronald B. George, MD, FRCPC,
Brian S. Schwartz, MD,
Naghma A. Farooqi, MD,
Syed S. Ali, MD,
Arianna Cassidy, MD,
Juan M. Gonzalez, MD, PhD,
and Stephanie L. Gaw, MD, PhD

BACKGROUND: Data suggest that pregnant women are not at elevated risk of acquiring severe acute respiratory syndrome coronavirus 2 (SARS-CoV-2) infection or developing severe disease compared with nonpregnant patients. However, management of pregnant patients

From the Department of Obstetrics, Gynecology, & Reproductive Sciences, the Divisions of Critical Care Medicine and Obstetric Anesthesia, Department of Anesthesia and Perioperative Care, the Divisions of Pediatric Infectious Diseases and Neonatology, Department of Pediatrics, the Division of Infectious Diseases, Department of Medicine, and the Division of Maternal-Fetal Medicine, Department of Obstetrics, Gynecology, & Reproductive Sciences, University of California, San Francisco, San Francisco, California.

Each author has confirmed compliance with the journal's requirements for authorship.

Corresponding author: Stephanie L. Gaw, MD, PhD, Department of Obstetrics, Gynecology and Reproductive Sciences, University of California, San Francisco, San Francisco, CA; email: Stephanie.Gaw@ucsf.edu.

Financial Disclosure

Anne L. Donovan disclosed that funding was provided to her institution from the Network for the Investigation of Delirium: Unifying Scientists (Pilot Grant Funding). Money was paid to her from the Agency for Healthcare Research and Quality (paid consultancy). Mary Prah disclosed that in the article, the case involves a pregnant woman who received compassionate use remdesivir. Her spouse is employed at the company that makes remdesivir. Her role in this case was solely confined to the management of the neonate, and she had no involvement or influence in management of woman who received the compassionate use drug. The other authors did not report any potential conflicts of interest.

© 2020 by the American College of Obstetricians and Gynecologists. Published by Wolters Kluwer Health, Inc. All rights reserved.
ISSN: 0029-7844/20

Teaching Points

1. Management of critically ill pregnant patients with coronavirus disease 2019 (COVID-19) infection requires balancing maternal and fetal well-being, as well as minimizing undue risk to health care professionals.
2. In pregnant patients with moderate-to-severe acute respiratory distress syndrome requiring positive-pressure ventilation, early delivery can decrease maternal oxygen requirements and improve respiratory mechanics, which may improve maternal outcomes under the appropriate clinical circumstances.
3. Preterm neonates may be at particular risk for perinatal COVID-19 infection owing to the fetal environment and immature passive immunity and skin integrity, and additional testing and isolation measures may be warranted in the exposed premature neonate requiring ongoing hospitalization.

who are critically ill with coronavirus disease 2019 (COVID-19) infection is complicated by physiologic changes and other pregnancy considerations and requires balancing maternal and fetal well-being.

CASE: We report the case of a patient at 28 weeks of gestation with acute respiratory distress syndrome (ARDS) from COVID-19 infection, whose deteriorating respiratory condition prompted delivery. Our patient's oxygenation and respiratory mechanics improved within hours of delivery, though she required prolonged mechanical ventilation until postpartum day 10. Neonatal swabs for SARS-CoV-2 and COVID-19 immunoglobulin (Ig) G and IgM were negative.

CONCLUSION: We describe our multidisciplinary management of a preterm pregnant patient with ARDS from COVID-19 infection and her neonate.

(*Obstet Gynecol* 2020;136:46–51)

DOI: 10.1097/AOG.0000000000003949

Coronavirus disease 2019 (COVID-19) has rapidly become a pandemic, and approximately 5% of those with infection develop critical illness including respiratory failure.¹ Pregnant women have been at higher risk for severe morbidity and mortality during prior epidemic respiratory illnesses, with data from seasonal influenza, the 2009 H1N1 pandemic, and the severe acute respiratory syndrome epidemic showing higher rates of intensive care unit admission, intubation, and death compared with nonpregnant patients.^{2,3} Limited data on COVID-19 infection in pregnancy shows largely mild disease and



good outcomes with third-trimester infections (Chen L, Li Q, Zheng D, Jiang H, Wei Y, Zou L, et al. Clinical characteristics of pregnant women with Covid-19 in Wuhan, China [letter]. *N Engl J Med* 2020 Apr 17.).⁴⁻⁶

We report the case of a critically ill patient at 28 weeks of gestation with severe COVID-19 infection and acute respiratory distress syndrome (ARDS) and describe the multidisciplinary care of the patient and her neonate. The patient provided written informed consent for publication of this report and accompanying images.

CASE

At 28 4/7 weeks of gestation, a 34-year-old woman, G6P3113, presented to her local hospital with a 4-day history of malaise, fever, myalgias, cough, and shortness of breath. Her medical history was significant for moderate asthma, A2 gestational diabetes mellitus, class II obesity, and three prior cesarean deliveries. She reported no uterine contractions, leakage of fluid, vaginal bleeding, or decreased fetal movement. She worked as a medical assistant but had no known exposures to severe acute respiratory syndrome coronavirus 2 (SARS-CoV-2) and reported no tobacco use.

On arrival, her vital signs were as follows: temperature 37.4°C, blood pressure 142/69 mm Hg, heart rate 103 beats per minute, respiratory rate 18/min, and SpO₂ 98% on room air. Fetal status was reassuring. Chest radiography showed bilateral opacities in the lower lobes concerning for pneumonia. Lower extremity duplex ultrasound scan did not show deep venous thrombosis. Transthoracic echocardiogram was within normal limits. Laboratory test results showed lymphopenia and elevated lactate, D-dimer, and C-reactive protein levels (Table 1). Nasopharyngeal swab testing was positive for SARS-CoV-2 by real-time reverse transcriptase polymerase chain reaction and negative for influenza and other common respiratory viruses.

The patient was started on hydroxychloroquine, azithromycin, and ceftriaxone. On hospital day 2 (illness day 6), she developed a fever (38.7°C) and respiratory distress. Supplemental oxygen was increased to a non-rebreather mask at 15 L/min, with ongoing hypoxemia (pH 7.41, PaCO₂ 26 mm Hg, PaO₂ 64 mm Hg, HCO₃ 16 mmol/L). Given maternal acuity and fetal gestational age, the patient was transferred to a tertiary care referral center with a labor and delivery unit and a level IV neonatal intensive care unit. She received betamethasone for fetal lung maturity before transfer.

On transfer, the patient was admitted directly to a negative-pressure intensive care unit room. Vital signs were as follows: temperature 36.9°C, blood pressure 117/66 mm Hg, heart rate 110 beats per minute, respiratory rate 30–40/min, and SpO₂ 93% on non-rebreather mask at 15 L/min. She was transitioned to high-flow nasal cannula, which can provide up to 50 L/min of oxygen, and was uptitrated to 30 L/min

with FiO₂ 100% with no improvement in her saturation or work of breathing. Given concern for impending respiratory decompensation, the patient was intubated. Her hemodynamics and oxygen levels remained stable during intubation. Initial PaO₂/FiO₂ ratio was 163 (normal greater than 300), plateau pressure was 15 cmH₂O, static compliance was 80 mL/cmH₂O (normal greater than 100), and calculated dead space fraction was 42% (normal approximately 25–30%) (Fig. 1A).

The patient was started on compassionate use remdesivir 22 hours after admission. Hydroxychloroquine was discontinued owing to new prolonged QTc (506 ms) and access to remdesivir. Antibiotics were discontinued owing to low concern for bacterial pneumonia. Over the subsequent 12 hours, the patient required deep sedation to tolerate lung-protective ventilation. Despite implementing low tidal volume 400 mL (based on predicted body weight 57 kg) and incremental titration of positive end-expiratory pressure (PEEP) from 10 to 16 cmH₂O, her FiO₂ requirement remained high at 80% and her static compliance (a measure of lung stiffness) worsened (Fig. 1A). No further oxygenation benefit was seen with neuromuscular blockade. Fetal status was reassuring throughout, and an ultrasound scan revealed an appropriate-for-gestational-age sized fetus with an estimated weight of 1,920 g. A multidisciplinary group agreed to proceed with cesarean delivery for maternal benefit.

The patient received her second dose of betamethasone and was started on magnesium sulfate for fetal neuroprotection and a continuous insulin infusion for A2 gestational diabetes mellitus. Before transfer to the operating room, her ventilator was transitioned to a portable model, FiO₂ was increased to 100%, and inhaled nitric oxide was initiated at 20 ppm to temporarily improve oxygenation perioperatively. Her PaO₂ improved to 159 mm Hg (from 94 mm Hg).

Following a safety protocol to minimize exposure (Appendix 1, available online at <http://links.lww.com/AOG/B896>), the patient was transported to the designated COVID-19 obstetric operating room and underwent an uncomplicated repeat cesarean delivery at 28 6/7 weeks of gestation of an 1,880-g liveborn male neonate. Delayed cord clamping was not performed to reduce neonatal exposure to maternal anesthesia and SARS-CoV-2. The 1- and 5-minute Apgar scores were 4 and 8, respectively. Amniotic fluid was clear. The patient received oxytocin and methergine for uterine atony, with estimated blood loss of 600 mL. With the same ventilator settings, her oxygenation remained stable (SpO₂ 95–98%) and plateau pressure decreased slightly after delivery (Fig. 1B).

The patient's PaO₂/FiO₂ ratio improved over the following several days, and lung mechanics remained relatively stable (Fig. 1 C and E). She required deep sedation and, at times, neuromuscular blockade to maintain ventilator synchrony. Prednisone was given for persistently poor expiratory flow despite inhaled bronchodilators. Ertapenem was given for an extended-spectrum-beta-lactamase-producing



Table 1. Maternal Clinical Laboratory Results Through the First Postoperative Week

Measure	Reference Range	Day 1	Day 2	Day 3, POD1	Day 4, POD2	Day 5, POD3	Day 6, POD4	Day 7, POD5	Day 8, POD6	Day 9, POD7
Hemoglobin (g/dL)	12.0–15.5	13.0	12.0	10.0	9.3	8.4	9.0	10.0	9.8	9.6
White blood cell count ($\times 10^9/L$)	3.4–10.0	8.3	14.7	19.5	17.0	9.8	13.2	14.7	15.0	14.2
Lymphocyte count ($\times 10^9/L$)	1.0–3.4	0.8	0.44	1.81	NA	NA	NA	NA	NA	NA
Platelet count ($\times 10^9/L$)	140–450	124	141	179	212	199	269	303	305	347
C-reactive protein (mg/L)	Less than 7.5	108	NA	151.8	NA	140.9	NA	173.6	NA	300.5
Procalcitonin (micrograms/L)	Less than 0.26	0.3	0.24	0.17	NA	0.09	NA	0.05	NA	0.07
Troponin (micrograms/L)	Less than 0.05	NA	NA	Less than 0.02	NA	Less than 0.02	NA	Less than 0.02	Less than 0.02	Less than 0.02
Creatinine (mg/dL)	0.55–1.02	0.66	0.55	0.64	0.67	0.54	0.53	0.57	0.52	0.50
Aspartate transaminase (units/L)	5–44	32	32	23	19	39	27	22	13	13
Alanine transaminase (units/L)	10–61	38	35	25	21	22	24	24	14	14
Alkaline phosphatase (units/L)	38–108	71	71	61	72	75	69	77	76	74
Prothrombin time (sec)	11.7–15.1	NA	12.6	12.3	12.5	12.6	13.4	13.7	14.9	15.6
Ferritin (micrograms/L)	12–160	NA	NA	187	NA	216	NA	178	NA	224
Lactate dehydrogenase (units/L)	102–199	NA	NA	226	NA	280	NA	307	NA	319
Fibrin D-dimers (ng/mL)	Less than 500	870	NA	1,908	808	NA	881	NA	NA	1,788
Respiratory viral panel*	Negative	Negative	NA	NA	NA	NA	NA	NA	NA	NA

POD, postoperative day; NA, not applicable.

* Included testing for influenza A and B, adenovirus, metapneumovirus, rhinovirus, and parainfluenza 1–4.

Escherichia coli urinary tract infection. She was extubated on postoperative day 10 (illness day 17) and discharged home in good condition on postoperative day 15.

The newborn was resuscitated by the neonatal team and intubated for respiratory distress. Chest radiography showed diffuse bilateral granular and hazy opacities concerning for mild edema or evolving respiratory distress syndrome (Appendix 2, available online at <http://links.lww.com/AOG/B896>); a dose of surfactant was given. Laboratory test results showed leukopenia, neutropenia, lymphopenia, mild acidosis, and normal lactate (Appendix 3, available online at <http://links.lww.com/AOG/B896>). Within hours of birth, the neonate was extubated and placed on continuous positive airway pressure ventilation. Oral and nasopharyngeal swabs (at 24 hours, 48 hours, and 14 days) and rectal swab (at 48 hours) were negative for SARS-CoV-2. Coronavirus disease 2019 immunoglobulin (Ig) G and IgM serologies drawn on day of life 5 were negative. Placental pathology showed acute chorioamnionitis, with no funisitis or histologic evidence of other placental infections,

such as syphilis, toxoplasmosis, rubella, cytomegalovirus, or herpes simplex virus. At 16 days of life, the neonate was clinically stable on high-flow nasal cannula at 3 L/min and 21% FiO₂, at full nasogastric tube feeds, and had normal findings on neurologic examination.

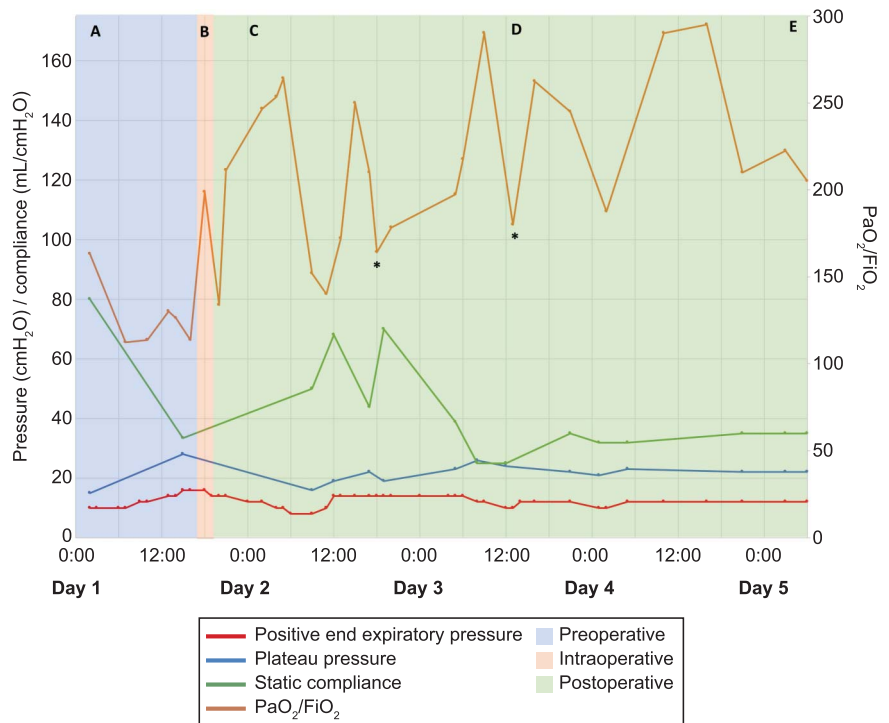
DISCUSSION

Here we describe our multidisciplinary approach to the care of this patient. Standard management of ARDS, including lung-protective ventilation (low tidal volume, limited plateau pressure, higher PEEP, permissive hypercapnia)⁷ and supportive therapies (conservative fluid management, prone positioning, neuromuscular blockade, inhaled vasodilators, and extracorporeal life support),^{8,9} has not been rigorously studied in COVID-19 infection. Our case is consistent with some reports of ARDS from COVID-19 infection, suggesting that severe hypoxemia can occur in



Fig. 1. Ventilator flowsheet during maternal hospitalization. **A.** Time of intubation: 02:00. **B.** Time of transport to operating room, FiO₂ at 100% and inhaled nitric oxide at 20 ppm: 18:45; end of cesarean delivery: 19:45; inhaled nitric oxide at 10 ppm: 20:45. **C.** Inhaled nitric oxide off. **D.** Paralysis initiated. **E.** Paralysis weaned and spontaneous mode ventilator initiated. *Periods of desaturation with ventilator dyssynchrony.

Blauvelt. *Acute Respiratory Distress Syndrome in a Pregnant Patient With COVID-19.* *Obstet Gynecol* 2020.



the setting of relatively preserved lung compliance (ie, lung stiffness) and dead space (ie, amount of lung not participating in gas exchange)—which may reflect heterogeneity in the disease or a divergence from classic ARDS (Gattinoni L, Coppola S, Cressoni M, Busana M, Rossi S, Chiumello D. Covid-19 does not lead to a “typical” acute respiratory distress syndrome [letter]. *Am J Respir Crit Care Med* 2020 Mar 30 [Epub ahead of print].).¹⁰ The patient met criteria for moderate ARDS, but initial lung compliance after intubation was nearly normal. With usual ventilator management for ARDS, including upward PEEP titration, we saw the unexpected effect of lung overdistension, evidenced by decreased lung compliance and worsened hypercarbia indicating increased dead space.

Management of ARDS from COVID-19 infection is further complicated by pregnancy considerations.¹¹ Normal physiologic changes in pregnancy, namely increased minute ventilation, reduced functional residual capacity, upward displacement of the diaphragm, increased chest wall compliance, and increased oxygen consumption, complicate management of these patients^{12,13} (see Table 1 in American College of Obstetricians and Gynecologists Practice Bulletin No. 211)¹³ Additionally, maternal hypoxemia and changes to uteroplacental blood flow may cause fetal hypoxia. Although prone positioning and extracorporeal life support have been described in preg-

nant patients, there are technical and anatomic challenges.¹⁴ These factors are compounded by infectious risks to health care professionals caring for critically ill patients with COVID-19 infection.

Early delivery in ARDS has been described as a therapeutic option for deteriorating patients, with possible benefit from changes in cardiopulmonary physiology.^{15,16} In one series of 10 patients intubated for respiratory failure, delivery resulted in reduced FiO₂ within 24 hours but unchanged PEEP and plateau pressure.¹⁶ Rationale for early delivery in our case included: 1) the patient’s rapid deterioration over less than 24 hours, 2) the lack of improvement in oxygenation on 80–100% FiO₂ despite optimization of ventilator settings and supportive therapies, 3) the opportunity to safely transport the patient to the operating room, and 4) the understanding that delivery may decrease maternal oxygen consumption and improve lung mechanics.

Our patient remained stable intraoperatively and, within 12 hours postpartum, had an improved PaO₂/FiO₂ ratio (as high as 260) and static compliance (from 33 to 50 mL/cmH₂O) (Fig. 1C). Lung volumes also significantly improved (Fig. 2). Little information exists on ARDS in pregnancy, particularly from COVID-19 infection, and the risks and benefits of early delivery should be individualized in each case, prioritizing maternal stability over acute fetal status.



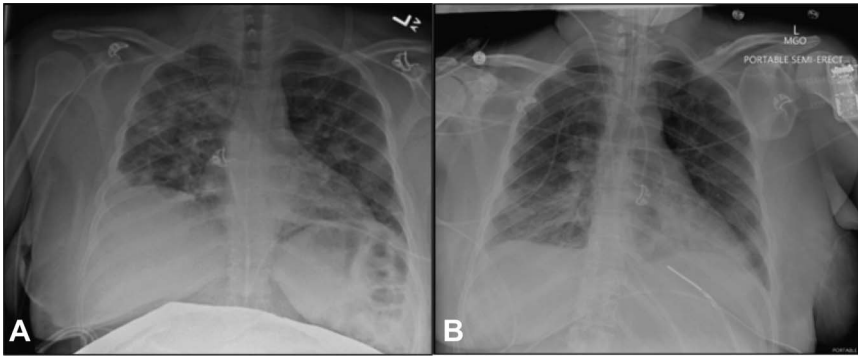


Fig. 2. Maternal chest radiography. **A.** Imaging on admission showed multifocal consolidations and reduced lung volumes. **B.** Repeat imaging on postoperative day 3 showed improved lung volumes and decreasing bilateral opacities.

Blauvelt. Acute Respiratory Distress Syndrome in a Pregnant Patient With COVID-19. Obstet Gynecol 2020.

Concerns have been raised about worse COVID-19 outcomes with prolonged steroid therapy in the nonpregnant population.¹⁷ However, the course of antenatal corticosteroids for fetal lung maturity is of short duration and is recommended in patients at less than 34 weeks of gestation at risk for preterm birth. Antenatal corticosteroids can be given in patients with diabetes after full consideration of the potential risks and benefits. In our patient, we felt that the benefits outweighed the risks given her very preterm gestation; she did develop hyperglycemia after antenatal corticosteroid administration (as high as 279 mg/dL), subsequently controlled with increasing insulin doses. Similarly, magnesium sulfate for fetal neuroprotection should be considered even in women with respiratory symptoms, though evidence is limited on how to monitor these patients for toxicity. Oxygen saturation and respiratory rate should be followed closely and dosage and volume adjustments made for patients with renal dysfunction or pulmonary edema. Care must be individualized, balancing known fetal benefits of antenatal corticosteroids and magnesium against hypothetical risks to the mother.^{18,19}

The most effective treatment for COVID-19 infection is unknown. At our institution, hospitalized adults with COVID-19 infection are enrolled in the Adaptive COVID-19 Treatment Trial (ClinicalTrials.gov, NCT04280705); however, pregnant patients are excluded. Therefore, we obtained and administered compassionate use remdesivir for this patient after reviewing internal data shared by Gilead Sciences on the safety of remdesivir in pregnancy. Hydroxychloroquine is considered safe in pregnancy and has been used to treat COVID-19 infection,⁵ although its efficacy is unknown and there is increasing data on cardiotoxicity.²⁰ In this patient, hydroxychloroquine was initiated before transfer but later discontinued owing to QTc prolongation, a known side effect. Convalescent plasma was considered but not available.

Considerable uncertainty remains regarding vertical transmission of SARS-CoV-2, which has been detected in maternal sputum, pharyngeal, nasopharyngeal, and stool specimens but not in maternal blood, amniotic fluid, vaginal mucus, placenta, or breast milk.^{21–23} Reports exist of neonates positive for SARS-CoV-2 by oral and nasopharyngeal swabs within 36–48 hours after caesarean delivery and of neonates producing SARS-CoV-2-specific IgM.^{23,24}

Preterm neonates may be at particular risk for perinatal COVID-19 infection. The fetus is primed toward immunologic tolerance in a semi-allogeneic uterine environment and may not mount effective inflammatory responses to infection.²⁵ Additionally, passive transfer of protective maternal immunoglobulins does not reach maximum until term, with 28–30-week neonates having about 50% of maternal IgG levels.²⁶ The immature skin integrity of preterm neonates may also be a risk factor for perinatal transmission.

The neonate in our case had swabs for SARS-CoV-2 and COVID-19 IgG and IgM that were negative. Although placental pathology showed acute chorioamnionitis, we could find no clinical evidence of this in the mother or the neonate. Given the paucity of data on COVID-19 infection in preterm neonates at less than 30 of gestation, this neonate was kept under novel respiratory isolation measures until 14 days of life. Further research is needed on risk factors and prevention of perinatal COVID-19 infection, including infection-control measures during delivery and in exposed premature neonates requiring ongoing hospitalization.

There are few reports of pregnant women with severe COVID-19 infection, particularly in the very preterm period. Our patient's condition decompensated quickly, and, after multidisciplinary consideration, we proceeded with urgent delivery with acceptable maternal and fetal outcomes. We highlight our perspectives on this complex patient, for whom decision making required balancing maternal and fetal well-being, as well as minimizing undue risk to



health care professionals. We also advocate for early discussions with patients regarding designating a medical proxy and goals of care for herself and the fetus, particularly in a time of widespread hospital visitor restrictions and potential for rapid clinical deterioration from COVID-19 infection.

REFERENCES

1. Wu Z, McGoogan JM. Characteristics of and important lessons from the coronavirus disease 2019 (COVID-19) outbreak in China: summary of a report of 72 314 cases from the Chinese center for disease control and prevention. *JAMA* 2020 Feb 24 [Epub ahead of print].
2. Siston AM, Rasmussen SA, Honein MA, Fry AM, Seib K, Callaghan WM, et al. Pandemic 2009 influenza A(H1N1) virus illness among pregnant women in the United States. *JAMA* 2010;303:1517–25.
3. Lam CM, Wong SF, Leung TN, Chow KM, Yu WC, Wong TY, et al. A case-controlled study comparing clinical course and outcomes of pregnant and non-pregnant women with severe acute respiratory syndrome. *BJOG* 2004;111:771–4.
4. Mullins E, Evans D, Viner RM, O'Brien P, Morris E. Coronavirus in pregnancy and delivery: rapid review. *Ultrasound Obstet Gynecol* 2020 Mar 17 [Epub ahead of print].
5. Breslin N, Baptiste C, Gyamfi-Bannerman C, et al. COVID-19 infection among asymptomatic and symptomatic pregnant women: two weeks of confirmed presentations to an affiliated pair of New York City hospitals. *Am J Obstet Gynecol* 2020 Apr 9 [Epub ahead of print].
6. Liu D, Li L, Wu X, Zheng D, Wang J, Yang L, et al. Pregnancy and perinatal outcomes of women with coronavirus disease (COVID-19) pneumonia: a preliminary analysis. *AJR Am J Roentgenol* 2020 Mar 18 [Epub ahead of print].
7. Acute Respiratory Distress Syndrome Network, Brower RG, Matthay MA, Morris A, Schoenfeld D, Thompson BT. Ventilation with lower tidal volumes as compared with traditional tidal volumes for acute lung injury and the acute respiratory distress syndrome. *N Engl J Med* 2000;342:1301–8.
8. National Heart, Lung, and Blood Institute Acute Respiratory Distress Syndrome (ARDS) Clinical Trials Network, Wiedemann HP, Wheeler AP, Bernard GR, Thompson BT, Hayden D, et al. Comparison of two fluid-management strategies in acute lung injury. *N Engl J Med* 2006;354:2564–75.
9. Guérin C, Reignier J, Richard JC, Beuret P, Gacouin A, Boulain T, et al. Prone positioning in severe acute respiratory distress syndrome. *N Engl J Med* 2013;368:2159–68.
10. Bhatraju PK, Ghassemieh BJ, Nichols M, Kim R, Jerome KR, Nalla AK, et al. Covid-19 in critically ill patients in the Seattle region—case series. *N Engl J Med* 2020 Mar 30 [Epub ahead of print].
11. Bandi VD, Munnur U, Matthay MA. Acute lung injury and acute respiratory distress syndrome in pregnancy. *Crit Care Clin* 2004;20:577–607.
12. Miller RD. Anesthesia for obstetrics. In: Miller's anesthesia. 8th ed. Philadelphia, PA: Elsevier Saunders; 2014.
13. Critical care in pregnancy. ACOG Practice Bulletin No. 211. American College of Obstetricians and Gynecologists. *Obstet Gynecol* 2019;133:e303–19.
14. Moore SA, Dietl CA, Coleman DM. Extracorporeal life support during pregnancy. *J Thorac Cardiovasc Surg* 2016;151:1154–60.
15. Tomlinson MW, Caruthers TJ, Whitty JE, Gonik B. Does delivery improve maternal condition in the respiratory-compromised gravida? *Obstet Gynecol* 1998;91:108–11.
16. Catanzarite V, Willms D. Adult respiratory distress syndrome in pregnancy. *Obstet Gynecol Surv* 1997;52:381–92.
17. Russell CD, Millar JE, Baillie JK. Clinical evidence does not support corticosteroid treatment for 2019-nCoV lung injury. *Lancet* 2020;395:473–5.
18. Society for Maternal-Fetal Medicine, Society for Obstetric Anesthesia and Perinatology. Labor and delivery COVID-19 considerations. Available at: [https://s3.amazonaws.com/cdn.smfm.org/media/2277/SMFM-SOAP_COVID_LD_Considerations_3-27-20_\(final\)_PDF.pdf](https://s3.amazonaws.com/cdn.smfm.org/media/2277/SMFM-SOAP_COVID_LD_Considerations_3-27-20_(final)_PDF.pdf). Retrieved April 7, 2020.
19. American College of Obstetricians and Gynecologists. COVID-19 FAQs for obstetrician-gynecologists, obstetrics. Available at: <https://www.acog.org/clinical-information/physician-faqs/covid-19-faqs-for-ob-gyns-obstetrics>. Retrieved April 11, 2020.
20. Mercurio NJ, Yen CF, Shim DJ, Maher TR, McCoy CM, Zimetbaum PJ, et al. Risk of QT interval prolongation associated with use of hydroxychloroquine with or without concomitant azithromycin among hospitalized patients testing positive for coronavirus disease 2019 (COVID-19). *JAMA Cardiol* 2020 May 1 [Epub ahead of print].
21. Chen H, Guo J, Wang C, Luo F, Yu X, Zhang W, et al. Clinical characteristics and intrauterine vertical transmission potential of COVID-19 infection in nine pregnant women: a retrospective review of medical records. *Lancet* 2020;395:809–15.
22. Wang X, Zhou Z, Zhang J, Zhu F, Tang Y, Shen X. A case of 2019 novel coronavirus in a pregnant woman with preterm delivery. *Clin Infect Dis* 2020 Feb 28 [Epub ahead of print].
23. Zeng L, Xia S, Yuan W, Yan K, Xiao F, Shao J, et al. Neonatal early-onset infection with SARS-CoV-2 in 33 neonates born to mothers with COVID-19 in Wuhan, China. *JAMA Pediatr* 2020 Mar 26 [Epub ahead of print].
24. Zeng H, Xu C, Fan J, Tang Y, Deng Q, Zhang W, et al. Antibodies in infants born to mothers with COVID-19 pneumonia. *JAMA* 2020 Mar 26 [Epub ahead of print].
25. Mold JE, Michaëlsson J, Burt TD, Muench MO, Beckerman KP, Busch MP, et al. Maternal alloantigens promote the development of tolerogenic fetal regulatory T cells in utero. *Science* 2008;322:1562–5.
26. Malek A, Sager R, Kuhn P, Nicolaidis KH, Schneider H. Evolution of maternofetal transport of immunoglobulins during human pregnancy. *Am J Reprod Immunol* 1996;36:248–55.

PEER REVIEW HISTORY

Received April 16, 2020. Received in revised form April 23, 2020. Accepted April 29, 2020. Peer reviews and author correspondence are available at <http://links.lww.com/AOG/B897>.

