

UCSF

UC San Francisco Previously Published Works

Title

Overexpression of MMPs in Corneas Requiring Penetrating and Deep Anterior Lamellar Keratoplasty

Permalink

<https://escholarship.org/uc/item/7fr6c4hn>

Journal

Investigative Ophthalmology & Visual Science, 60(5)

ISSN

0146-0404

Authors

Wolf, Marie
Clay, Selene M
Oldenburg, Catherine E
[et al.](#)

Publication Date

2019-04-25

DOI

10.1167/iovs.18-25961

Peer reviewed

Overexpression of MMPs in Corneas Requiring Penetrating and Deep Anterior Lamellar Keratoplasty

Marie Wolf,¹ Selene M. Clay,¹ Catherine E. Oldenburg,^{1,2} Jennifer Rose-Nussbaumer,^{1,2} David G. Hwang,^{1,2} and Matilda F. Chan^{1,2}

¹Department of Ophthalmology, University of California, San Francisco, California, United States

²Francis I. Proctor Foundation, University of California, San Francisco, California, United States

Correspondence: Matilda F. Chan, Department of Ophthalmology, Francis I. Proctor Foundation, Surgical Research Laboratory, Box 1302, San Francisco, CA 94143-1302, USA; matilda.chan@ucsf.edu.

Submitted: October 21, 2018
Accepted: March 25, 2019

Citation: Wolf M, Clay SM, Oldenburg CE, Rose-Nussbaumer J, Hwang DG, Chan MF. Overexpression of MMPs in corneas requiring penetrating and deep anterior lamellar keratoplasty. *Invest Ophthalmol Vis Sci*. 2019;60:1734-1747. <https://doi.org/10.1167/iovs.18-25961>

PURPOSE. Matrix metalloproteinases (MMPs) comprise a family of zinc-dependent endopeptidases involved in wound healing processes, including neovascularization and fibrosis. We assessed MMP protein expression levels in diseased corneas of patients requiring penetrating and deep anterior lamellar keratoplasty. The purpose of this study was to test the hypothesis that upregulation of MMPs in diseased corneas is positively associated with clinical levels of corneal neovascularization and fibrosis.

METHODS. Protein expression levels of nine individual MMPs were quantified simultaneously in human corneal lysates by using the Bio-Plex Pro Human MMP 9-Plex Panel and the MAGPIX technology. Measurements of MMP1, MMP2, MMP3, MMP7, MMP8, MMP9, MMP10, MMP12, and MMP13 were performed on diseased specimens from 21 patients undergoing corneal transplantation (17 for penetrating keratoplasty and 4 for deep anterior lamellar keratoplasty) and 6 normal control corneas.

RESULTS. Luminex-based expression analysis revealed a significant overexpression of four of the nine MMPs tested (MMP2, MMP8, MMP12, and MMP13) in patient samples compared to control. Significant overexpression of MMP1, MMP2, MMP8, MMP12, and MMP13 was observed in diseased corneas with neovascularization compared with diseased corneas without neovascularization. Overexpression of MMP1, MMP2, MMP8, MMP12, and MMP13 also corresponded with the levels of corneal fibrosis. Finally, reduced expression of MMP3 was detected in keratoconus patients.

CONCLUSIONS. Multiple MMPs are expressed in the corneas of patients with chronic disease requiring keratoplasty even when the pathologic process appears to be clinically inactive. In particular, the expression of several MMPs (MMP2, MMP8, MMP12, and MMP13) is positively associated with increased levels corneal fibrosis and neovascularization.

Keywords: cornea, matrix metalloproteinases, penetrating keratoplasty, deep anterior lamellar keratoplasty

Matrix metalloproteinases (MMPs) comprise a family of zinc-dependent endopeptidases involved in extracellular matrix (ECM) remodeling during development or following disease or injury.¹⁻³ Extensive ECM remodeling processes occur during wound healing, including neovascularization and fibrosis. MMP substrates⁴ encompass a large variety of ECM components involved in maintaining healthy tissue² and repairing diseased tissue.⁵ Individual MMPs have been described to have either a protective or destructive effect in animal and in vitro models of organ injury, including the eye.⁶ Although MMPs have been found to be expressed in all eye tissues,⁷ our understanding of their individual roles in vivo continues to evolve.^{8,9}

Because the cornea is the outermost layer of the eye, it is prone to injury and infections that may lead to scarring and loss of clarity.¹⁰ Once vision is compromised from corneal opacification, few nonsurgical treatment options are available, and replacement of the diseased cornea with healthy donor tissue is the standard treatment. Corneal transplantation techniques have evolved from the traditional full-thickness, penetrating keratoplasty (PKP) prior to the mid-1990s to the

more recently developed partial-thickness keratoplasty, in which only the diseased layer or layers are replaced. PKP is now primarily performed in patients with significant stromal scarring, extensive corneal distension such as in keratoconus, and corneal ulceration with or without a history of infection.¹¹ Deep anterior lamellar keratoplasty (DALK) is a partial-thickness keratoplasty procedure in which the corneal epithelium and stroma are replaced and the host corneal endothelium and Descemet's membrane are left intact.¹² A major advantage of DALK over PKP procedures is the reduced risk of corneal endothelial cell immune rejection.¹³

Diseased corneas requiring transplantation may display increased MMP expression as part of the host response to the underlying disease process. In other diseased human tissues, including lung, brain, aorta, and skin, increased MMP expression and activity has been reported.¹⁴⁻¹⁹ Aberrant corneal MMP expression patterns have been noted in corneas of patients with diabetes and keratoconus.^{20,21} Keratoconus, a progressive corneal degeneration leading to corneal thinning and bulging, can result in blurred and distorted vision. Although this disorder has been characterized as noninflammatory due to



the lack of neovascularization, recent studies have shown the presence of immune cells in the stroma of keratoconic corneas and increased cytokine production in keratoconus corneal cells *in vitro*.²² Several groups have reported overexpression of various MMPs in the tear film²³⁻²⁷ or immunostained corneal tissue^{28,29} of patients with keratoconus.

The purpose of this study was to test the hypothesis that upregulation of MMPs in diseased corneas is positively associated with clinical levels of corneal neovascularization and fibrosis. We used Luminex technology that allows the quantification of nine individual MMPs in a single-well, multiplex format to compare MMP levels in cornea lysates. MMP protein expression levels were measured in diseased corneas of patients requiring PKP or DALK and were compared with levels in healthy donor corneas. We identified the differential expression of specific MMPs that were positively associated with clinical findings of corneal fibrosis and neovascularization and that may serve as biomarkers of these disease processes.

MATERIALS AND METHODS

Ethical Compliance

Institutional review board/ethics committee approval was obtained from the University of California, San Francisco Human Research Protection Program (study number 11-07020). Informed consent was obtained from all participants. Protected health information was masked according to Health Insurance Portability and Accountability Act privacy standards, and the patient database was managed securely in Research Electronic Data Capture. All of the described research adhered to the tenets of the Declaration of Helsinki.

Subjects and Selection Criteria

Corneal samples were collected from all patients ($n = 25$) undergoing PKP ($n = 20$) or DALK ($n = 5$) by two surgeons (D.G.H. and J.R.N.) at the University of California, San Francisco between March 2014 and November 2015. Patient information (age, sex, affected eye, neovascularization, scarring, and prior graft) was collected with patient consent from electronic medical documentation of the clinical examination by using slit-lamp biomicroscopy from the last visit prior to their surgery. Neovascularization and scarring scores were taken from the most recent office visit prior to the surgical procedure. Corneal neovascularization was defined as the presence of any blood vessel ingrowth into the cornea from the limbus into previously avascular regions of the cornea. Superficial neovascularization was defined as vessel ingrowth into the epithelial and anterior stromal cornea. Deep neovascularization was defined as vessel ingrowth into the posterior stromal layer of the cornea. Corneal scarring was defined as the presence of any opacification and lack of corneal clarity. Scarring density was defined as mild if iris structures could be observed behind the scar and as dense if iris structures were obscured by the scar tissue. Clinical notes were also used to estimate the time for scarring to transplant. Study participants had no previous consumption of systemic immunomodulatory medications or medications with known effects on MMP expression. Age- and sex-matched control eye bank donor corneas ($n = 6$) were obtained from the San Diego Eye Bank from donors who had consented to the use of their corneas for research purposes. Control samples were processed in the same manner as the patient samples. Patient samples were stored at -80°C on the day of collection, and all samples were processed simultaneously together as described below.

Sample Preparation and Luminex Assay

Control and diseased corneal samples were thawed on ice, placed in 400 μL of lysis buffer (Bio-Rad cell lysis kit; Bio-Rad, Hercules, CA, USA) and sonicated 10 times for 10 seconds. Lysates were incubated at 4°C under gentle agitation for 2 hours. Protein concentration was measured by BCA assay (Thermo Scientific Pierce, Rockford, IL, USA). Lysates with a concentration between the range of 0.1 to 1.1 mg/mL were selected ($n = 21$; PKP, $n = 17$; DALK, $n = 4$) and further processed using the Bio-Plex Pro Human MMP Panel, 9-Plex (Bio-Rad) following the manufacturer's instruction. Briefly, lysates were incubated with specific anti-MMP antibodies, each type of which was covalently linked to uniquely colored, fluorescently labeled magnetic beads. Beads were washed three times to remove unbound proteins, incubated with a specific anti-MMP biotinylated detection antibody, washed again, and incubated with a streptavidin-phycoerythrin conjugate serving as a reporter. Fluorescent signals from both the beads and phycoerythrin were measured in the multiplex suspension using MAGPIX technology and compared to standards of known concentrations. Lower limits of detection for MMP1, 2, 3, 7, 8, 9, 10, 12, and 13 were 35, 450, 116, 5.4, 1.5, 24, 1.6, 1, and 4.9 pg/mL, respectively. Standard curves were run in duplicate, and all quality control reagents were within range. Minimal disparity was measured between the duplicates that all passed the manufacturer's internal quality control test before being processed by the calculation algorithm. Results were analyzed using Bio-Plex Data Analysis software (Bio-Rad) and the concentration of each individual MMP per corneal sample was calculated and normalized per milligram of total protein.

Statistical Analysis

All samples were processed and analyzed in duplicate. Wilcoxon rank sum tests were used to analyze MMP expression and clinical variables (sex, age, history of corneal graft, level of corneal neovascularization, level of corneal fibrosis, and presence of keratoconus). Fisher's exact test was used to test age as a dichotomous variable by using 50 as the age cutoff because of the small sample size. Spearman correlation coefficients with bootstrapped 95% confidence intervals were used to present age as a continuous variable per MMP to assess if there is any linear correlation. All statistical analyses were performed using Prism7 (GraphPad Software Inc, La Jolla, CA, USA). P values less than 0.05 were considered statistically significant for all analyses.

RESULTS

Eight MMPs Were Consistently Detected and Four MMPs Were Overexpressed in Diseased Human Corneal Samples

This study included corneas from 21 patients undergoing PKP ($n = 17$) or DALK ($n = 4$) and 6 nondiseased control eye bank corneas (Table 1). Patient and control groups did not differ in age ($P = 0.52$, Wilcoxon rank sum test with age as a continuous variable; $P = 0.37$, Fisher's exact test treating age as a dichotomous variable) or sex ($P > 0.99$). Patients were classified based on the presence of neovascularization, amount of scarring, and history of prior graft or keratoconus (Table 2). Out of the 21 study participants, 13 (62%) had corneal neovascularization, 12 (57%) had dense scarring, and 5 (24%) had mild scarring. Eleven patients (52%) had a history of a prior corneal graft and four (19%) had a diagnosis of keratoconus.

TABLE 1. Study Subjects and Control Summary

	Control (n = 6)	Patient (n = 21)
Age (SD)	61 (15)	56 (19)
Age range	46-76	19-94
Sex, n (%)		
Male	4 (67)	14 (67)
Female	2 (33)	7 (33)
Procedure, n (%)		
PKP	6 (100)	17 (81)
DALK	0 (0)	4 (19)
Neovascularization, n (%)		
Absent	6 (100)	8 (38)
Present	0 (0)	13 (62)
Scarring, n (%)		
Absent	6 (100)	4 (19)
Mild	0 (0)	5 (24)
Dense	0 (0)	12 (57)
History of prior graft, n (%)		
Yes	N/A	11 (52)
No	N/A	10 (48)

Age, sex and procedure information for controls and patients. Summary of clinical characteristics of neovascularization, scarring, and history of prior graft for controls and patients. N/A, not applicable.

Table 2 presents detailed clinical information for the enrolled patients.

All tested MMPs, except for MMP9, were consistently detected at various levels in the corneas harvested from patients undergoing transplantation, indicating that MMP overexpression was a feature of these diseased corneas (Fig. 1; samples 7-27). Only 2 patient samples and none of the normal control samples showed concentrations of MMP9 within the measurable range, suggesting that either our assay was out of range for this specific analyte or that MMP9 is not expressed in chronic corneal disease. All MMPs except for MMP3 were expressed at basal levels in control corneas (Fig. 1; samples 1-6). In contrast, a wide range of MMP expression levels was observed among patient samples (Fig. 1; samples 7-27).

The majority of patients had chronic stable disease and lacked evidence of active inflammation at the time of corneal transplantation. Despite their disease inactivity, most patients still expressed a few individual MMPs and had higher MMP levels compared with the control samples (Fig. 1). This result indicates that MMPs may still be expressed even when the pathologic process appears to be clinically inactive.

Patients 8 and 16 had both acute and chronic disease with evidence of active inflammation at the time of corneal transplantation. Patient 8 had a history of a recent Salleras procedure for a chronically painful and irritated eye due to a failed and edematous PKP graft. The failed corneal graft resulted in chronic edema, inflammation, and painful epithelial bullae. The Salleras procedure used corneal cautery to create a reticular pattern of subepithelial scarring to prevent further epithelial bullous formation. This cornea, therefore, had sequelae of both chronic corneal graft failure and scarring as well as acute active inflammation and neovascularization induced by therapeutically applied electrocautery. Patient 16 had a history of acute allograft rejection of a previous PKP graft performed for a prior parasitic (*Acanthamoeba*) infection, clinical signs of active and chronic disease processes, and large vessels in a hazy graft. Interestingly, the acute disease activity for patients 8 and 16 resulted in an MMP expression profile that was distinct from the other patients in the cohort and displayed high levels of all measured MMPs (Fig. 1). This result indicates that MMPs are highly expressed during active corneal

inflammation and are likely expressed by infiltrating neutrophils and macrophages.

Individual MMP expression levels were next compared between patient and control corneas (Fig. 2). MMP2 ($P = 0.04$), MMP8 ($P = 0.03$), MMP12 ($P = 0.02$), and MMP13 ($P = 0.004$) were significantly overexpressed in corneas of patients undergoing keratoplasty when compared to controls, whereas MMP1, MMP3, MMP7, and MMP10 were not. However, we observed individual variations for each analyte measured. Various factors could explain a wide range of expression, including age, sex, previous graft status, presence of neovascularization and scarring, and inflammation levels.

MMP Expression and Patient Sex, Age, and History of Prior Graft

Because sex has been shown to affect MMP expression levels in human plasma,⁵⁰ patients were classified based on sex, and individual MMP expression levels were compared (Fig. 3A). There was no significant difference between the two groups for any MMP, indicating that sex does not have an effect on MMP expression in diseased corneas (Fig. 3B). Patient age has also been shown to affect serum MMP levels,^{31,32} so we compared MMP expression levels in corneal tissue obtained from younger (<50 years old) versus older (>50 years old) patients (Fig. 4A). Out of the eight MMPs studied, only MMP12 was differentially expressed based on this age cutoff with higher MMP12 expression levels in diseased corneas of patients over the age of 50 years when compared to younger patients (Fig. 4B; $P = 0.04$). We also analyzed age as a continuous variable per MMP to assess if there is any linear correlation (Spearman correlation coefficients with bootstrapped 95% confidence intervals; Fig. 4C). This additional analysis using age as a continuous variable identified a significant correlation between MMP2 and MMP3 expression and age (Fig. 4C). Because tears of patients with corneal graft failure have been shown to have abnormally high levels of MMPs,³³ we also compared MMP expression levels in corneas from primary grafts with MMP levels in corneas that were a regrant from a prior corneal transplant (Fig. 5A). We found that although levels of seven MMPs were similar between the two groups, MMP3 was overexpressed in corneal graft failure (Fig. 5B).

MMP Expression and Corneal Neovascularization

We previously found that MMP12 inhibits corneal neovascularization following chemical injury in a mouse model through altered cleavage of plasminogen and expression of VEGF.³⁴ Other MMPs, including MMP2, MMP9, and MMP14, have been shown to have an opposite effect on corneal neovascularization and promote its development following injury by regulating VEGF expression.³⁵⁻³⁸ To examine how MMP expression corresponds to corneal neovascularization in patient corneas, MMP expression levels were compared between control corneas and diseased corneas with or without neovascularization (Fig. 6). Of the eight MMPs that were consistently detected, MMP2, MMP8, MMP12, and MMP13 were significantly overexpressed in diseased corneas with corneal neovascularization as compared to both control corneas (Fig. 6B; $P = 0.005$, $P = 0.0009$, $P = 0.0003$, and $P = 0.0003$, respectively) and diseased corneas without neovascularization ($P = 0.007$, $P = 0.007$, $P = 0.01$, and $P = 0.001$, respectively). MMP1 was significantly overexpressed in corneas with neovascularization when compared to control corneas ($P = 0.02$). To determine how the acute inflammation in patients 8 and 16 may be contributing to the MMP expression levels, we performed a subanalysis that excluded

Investigative Ophthalmology & Visual Science

TABLE 2. Clinical Data of Corneal Samples

Sample	Sex	Age	Procedure	Eye	Pachymetry, μm	Corneal Vessels	Scarring	Scarring to Surgery	History of Prior Graft	Ocular History
1	M	76								Control
2	F	46								Control
3	M	49								Control
4	F	46								Control
5	M	71								Control
6	M	75								Control
7	F	65.4	PKP	OS	>900	Yes - diffuse, deep, stromal	Yes - deep stromal infiltrate	>11 months	Yes - prior PKP	Failed PKP and recent <i>Streptococcus viridans</i> keratitis
8	M	60.8	PKP	OD	865	Yes - vessels into graft	Yes - multiple cautery burns	30 months	Yes - prior PKP	Recent Salleras procedure and graft wound dehiscence
9	M	61.2	PKP	OD	>900	Yes	Yes - old LASIK scar	3 months	No	Endothelial dysfunction (silicone oil keratopathy) and previous LASIK
10	F	33.9	DALK	OS	400	No	Yes - mild anterior stromal scar	3 months	No	Keratoconus
11	M	71.2	PKP	OS	725	No	Yes - dense central anterior and mid stromal scar	>18 months	No	Scar from infectious keratitis (wood chip trauma)
12	M	63.7	PKP	OS	608	Yes - superficial	No	N/A	Yes - prior PKP	Graft rejection
13	M	74	PKP	OS	>900	Yes - deep vessels into graft	Yes - failed graft	>6 months	Yes - prior PKP	Graft failure
14	M	34.4	PKP	OS	Never measured	Yes - diffuse	Yes - central scar	>2 months	No	Conjunctivalized neurotrophic cornea and recent epithelial defect
15	F	66.1	PKP	OS	>900	Yes - deep	Yes - dense	>1 year	No	Stromal scar from a corneal ulcer
16	M	34	PKP	OS	899	Yes - large vessels	Yes - hazy graft	>57 months	Yes - prior PKP	Acute graft rejection; prior PKP for <i>Acanthamoeba</i> keratitis
17	F	23.1	DALK	OD	558	No	Yes - apical scar	>11 months	No	Keratoconus
18	M	71.3	PKP	OS	>900	No	Yes - failed graft	20 months	Yes - prior PKP and DSAEK	Graft failure; history of trauma as a child
19	M	66.1	PKP	OD	989	Yes - minimal	Yes - failed graft	35 months	Yes - prior PKP	Graft failure
20	F	58.5	PKP	OD	934	Yes - deep	Yes - failed graft	29 months	Yes - prior PKP	History of alkali burn, explanted Kpro for perforated corneal ulcer, and failed PKP
21	M	73	PKP	OS	558	No	No	N/A	Yes - prior PKP	History of PKP for keratoconus with anterior bulging of graft
22	F	94.3	PKP	OS	>900	Yes	Yes	>1 month	Yes - prior PKP	Graft failure
23	M	33.8	DALK	OD	unable (>900)	No	Yes - anterior and paracentral stromal scar	>17 months	No	Keratoconus
24	F	19.6	PKP	OD	300	No	Yes - anterior stromal scar	>29 months	No	Keratoconus
25	M	54.8	PKP	OS	658	No	No	N/A	Yes - prior PKP	History of PKP for keratoconus with borderline endothelial function and cataract
26	M	67.1	PKP	OD	>900	Yes - deep, stromal	No	N/A	No	Severe corneal edema with history of glaucoma tube shunt procedure
27	M	54.3	DALK	OD	Never measured	Yes - thin vessels	Yes - full thickness scar	>39 months	No	Corneal scar from welding accident, remote recurrent infections

Pachymetry, neovascularization, and scarring were assessed during clinic visits prior to the procedure.

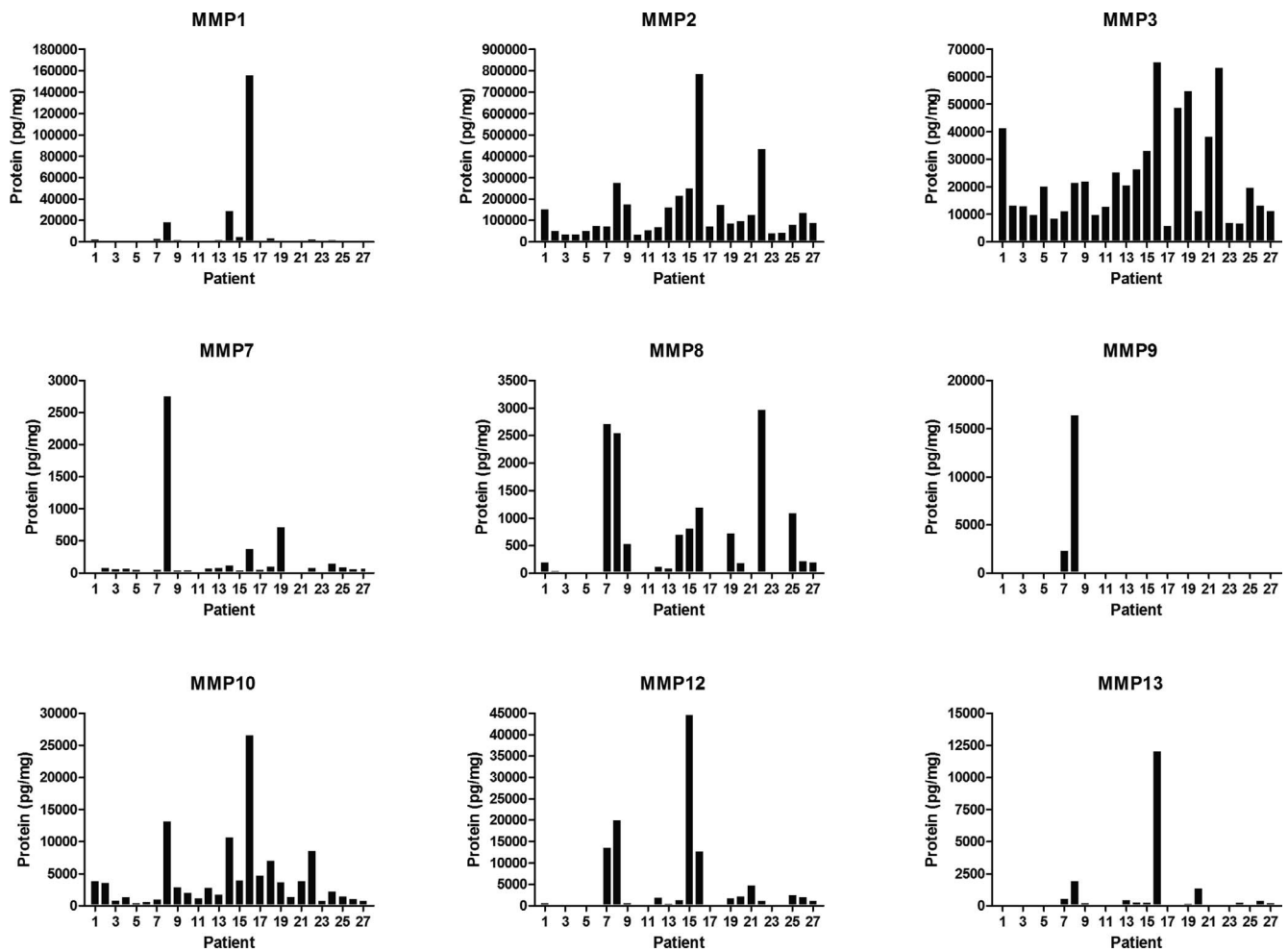


FIGURE 1. Expression levels of individual MMPs in control and diseased cornea samples. Individual MMP levels (pg/mg of total protein) in corneal analytes were measured by Luminex assay. Patients 1 to 6 are control corneas, and patients 7 to 27 are diseased patient corneas as described in Table 2.

these patients (Fig. 6C). We confirmed the overexpression of MMP2, MMP8, MMP12, and MMP13 in neovascularized corneas of patients with chronic inflammation. Taken together, these results demonstrate that corneas with neovascularization have upregulated expression of MMP1, MMP2, MMP8, MMP12, and MMP13.

MMPs are expressed by neutrophils (MMPs 1, 8, 9, and 10) and macrophages (MMPs 1, 2, 3, 7, 8, 9, 10, 12, and 13) and can be blood-borne. If vascularization constitutes a confounding variable by causing an artefactual increase in MMP level, then it would be expected that patient samples with neovascularization should consistently have higher levels of MMP expression compared with patient samples lacking neovascularization. Our results did not find this to always be the case. Patients 12 and 13 had neovascularization but showed low levels of MMPs (Table 2; Fig. 1). Conversely, patients 21 and 25 did not have neovascularization, but patient 21 had a high level of MMP12 expression, and patient 25 had a high level of MMP8 expression (Table 2; Fig. 1).

MMP Expression and Corneal Fibrosis

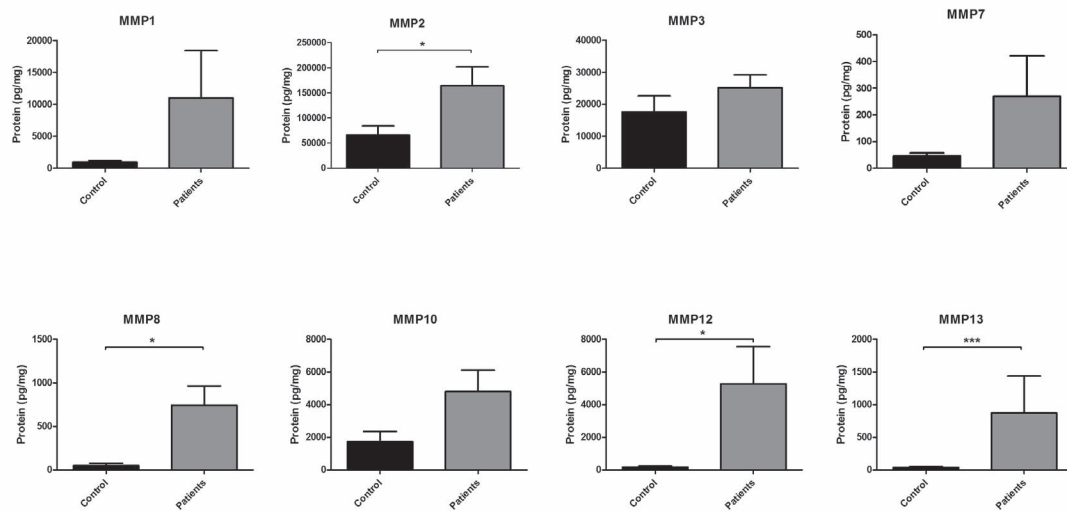
MMP overexpression has been linked to fibrosis in various organs and tissues.^{14,39,40} Patient corneas were grouped based on the level of scarring (dense, mild, or no scarring). MMP expression levels were compared among these three groups

and the control corneas (Fig. 7A). MMP1 ($P = 0.03$), MMP2 ($P = 0.005$), MMP8 ($P = 0.01$), MMP12 ($P = 0.0008$), and MMP13 ($P = 0.0004$) were significantly overexpressed in corneas with dense scarring when compared to controls. MMP2 ($P = 0.03$), MMP3 ($P = 0.009$), MMP12 ($P = 0.004$), and MMP13 ($P = 0.04$) were significantly more expressed in corneas with dense scarring compared with corneas with mild scarring (Fig. 7B). MMP12 levels were higher in corneas with no scarring compared to controls ($P = 0.009$) or in corneas with dense scarring compared to corneas with mild scarring ($P = 0.01$). These observations held true when we performed a subanalysis excluding patients showing signs of acute inflammation (patients 8 and 16) (Fig. 7C). These results show that MMP1, MMP2, MMP8, MMP12, and MMP13 expression was positively associated with the increased levels of corneal fibrosis.

MMP Expression and Keratoconus

Altered expression of several MMPs has been associated with keratoconus.^{41,42} We, therefore, compared MMP expression levels of keratoconic corneas to controls and nonkeratoconic corneas (Fig. 8A). MMP1 ($P = 0.03$), MMP2 ($P = 0.005$), MMP8 ($P = 0.006$), MMP12 ($P = 0.0002$), and MMP13 ($P = 0.0006$) were significantly overexpressed in nonkeratoconic diseased corneas when compared to controls (Fig. 8B); MMP2 ($P = 0.002$), MMP8 ($P = 0.02$), and MMP12 ($P = 0.0007$) were also

A.



B.

	Control n=6 (Mean)	Patients n=21 (Mean)	P-value
MMP1	944	11003	0.06
MMP2	66208	164361	0.04*
MMP3	17557	25077	0.44
MMP7	46	270	0.11
MMP8	50	743	0.03*
MMP10	1735	4799	0.09
MMP12	168	5275	0.02*
MMP13	39	873	0.004***

FIGURE 2. MMP expression levels in control and diseased corneas. (A) Protein expression levels (means \pm SEM) of individual MMPs in control and patient corneas. (B) Summary of MMP expression levels (means) and Wilcoxon rank sum analysis: * $P < 0.05$, ** $P < 0.005$, *** $P < 0.001$.

overexpressed in nonkeratoconic diseased corneas when compared to keratoconic corneas. Interestingly, MMP3 levels were significantly lower in keratoconic corneas compared to both control ($P = 0.04$) and nonkeratoconic diseased corneas ($P = 0.0003$). Taken together, these results show that keratoconus corneas do not overexpress MMPs and, in fact, have reduced MMP3 expression.

DISCUSSION

Luminex bead-based assays are highly sensitive and are increasingly used for biomarker discovery and detection in clinical samples.⁴³ In this study, we used the Luminex technology to demonstrate the overexpression of several MMPs (MMPs 2, 8, 12, and 13) in corneas from patients requiring keratoplasty. Although mouse corneas have been used previously,^{44,45} to our knowledge this is the first time human corneas were used in a Luminex-based assay to simultaneously ascertain the expression of multiple MMPs. Although MMPs were expressed at a basal level in control samples, patient corneas displayed a wide range of individual MMP expression. In particular, higher expression levels of

MMPs 1, 2, 8, 12, and 13 were observed in corneas with neovascularization and fibrosis, indicating a critical role of these MMPs in these repair processes. These findings are consistent with studies linking MMP expression levels and severity of corneal disease.^{46,47}

Corneal fibrosis takes weeks to months to develop, and corneal transplantation is typically postponed until the level of fibrosis has stabilized to reduce the risk of potential graft rejection that is more likely occur with active corneal inflammation. Consistent with this clinical protocol, only 2 of the 21 diseased corneal samples had evidence of active inflammation, whereas the majority of patient samples had chronic stable disease. Despite the cessation of the active pathologic process, and likely resolution of associated chronic inflammation, our results demonstrate that specific MMPs (MMPs 1, 2, 8, 12, and 13) can still be expressed in clinically inactive disease.

The observation of MMP12 overexpression in human corneas is novel. MMP12 has been shown to be protective against neovascularization and fibrosis while promoting repair in a corneal wound healing mouse model,^{34,48} but its role in human corneal repair remains uncertain. In this study, the

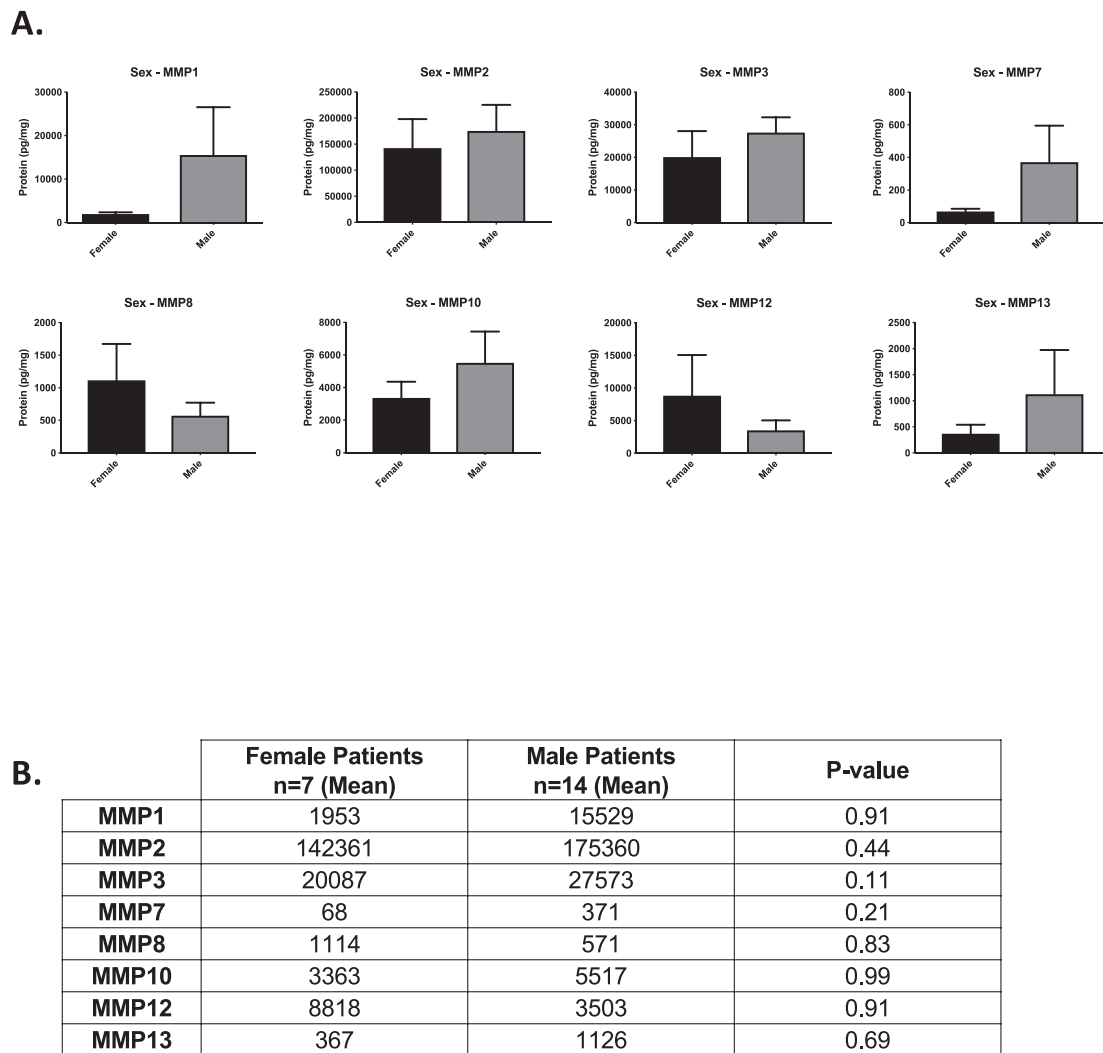


FIGURE 3. Comparison of MMP expression levels in corneas according to patient sex. (A) Protein expression levels (means \pm SEM) of individual MMPs in corneas from female and male subjects. (B) Summary of MMP expression levels (means) and Wilcoxon rank sum analysis.

observed overexpression of MMP12 noted in corneas with high levels of fibrosis and neovascularization was surprising. It is possible that the proangiogenic effects of MMPs 1, 2, 8, and 13 offset the antiangiogenic effect of MMP12. Further studies are needed to elucidate the underlying mechanisms that may explain this result.

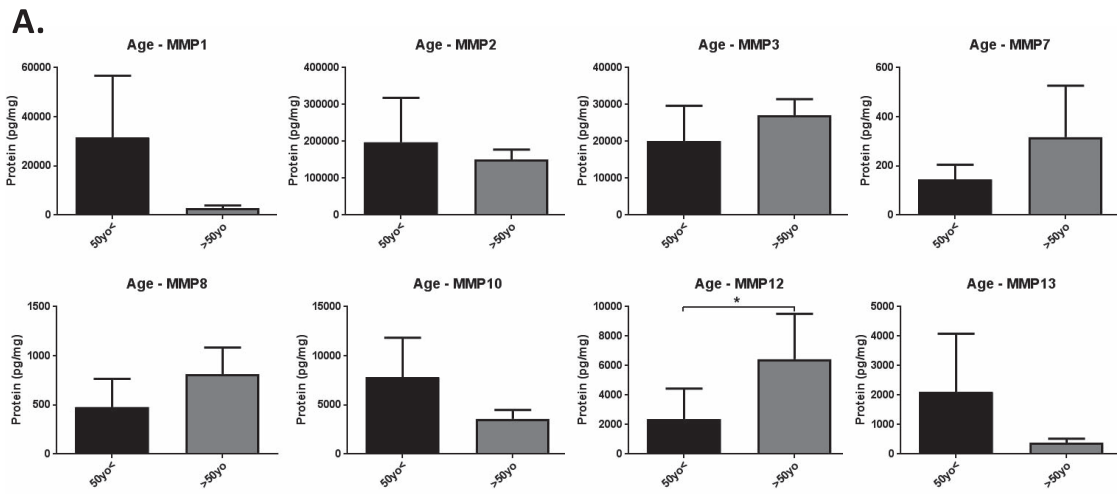
MMPs have long been described as destructive during ECM remodeling but they may have individual roles in different physiologic pathways.⁴⁹ MMP protective roles have been described in different tissues and have been extensively characterized in various disease models, including cancer^{50,51} and spinal cord injury.^{52,53} Because individual MMPs may have opposite and subtle effects in repair processes, broad-spectrum MMP inhibitors have done poorly in clinical trials,^{54,55} suggesting a rationale for further study of specifically targeted inhibitors or enhancers of MMP expression.

Although other studies have described enhanced MMP9 expression in diseased corneas,⁵⁶⁻⁵⁸ we only detected MMP9 expression in two patient samples in our assay. This finding was unexpected because activated macrophages have been shown to induce corneal neovascularization through the expression of MMP9 and VEGF in macrophages in a rat corneal neovascular assay.³⁶ Our low detection of MMP9 may be due to technical issues with this specific analyte, although all internal

controls were within detection range. Another explanation may be that the majority of patients had chronic, inactive disease resulting in the samples having low levels of active inflammation and, therefore, undetectable levels of MMP9. Consistent with this possibility is that patient 8 had high MMP9 expression and this patient had acute inflammation from a recent Salleras procedure.

We did not observe any influence of sex on MMP expression. By using 50 as a cutoff, we found that only MMP12 was slightly overexpressed in corneas of older patients. Most patients under the age of 50 had keratoconus, and none of them had detectable MMP12 expression. Whether this finding is significant or the result of a bias in the enrolled patients will be addressed in further studies. Additionally, using age as a continuous variable, we identified a significant correlation between MMP2 and MMP3 expression and age.

Interestingly, we measured an elevated level of MMP3 expression in corneas of patients undergoing a regrant when compared to corneas of patients receiving a primary graft. We also demonstrated that patients with keratoconus had reduced levels of MMP3 when compared to both controls and patients without keratoconus. This result is consistent with a recent keratoconus corneal proteome study that found decreased levels of MMP3 in diseased tissue.²¹ MMP3 is a secretory



B.

	Patients <50yo n=6 (Mean)	Patients >50yo n=15 (Mean)	P-value
MMP1	31537	2790	0.79
MMP2	197561	151080	0.27
MMP3	20095	27070	0.13
MMP7	145	318	0.57
MMP8	480	813	0.47
MMP10	7801	3599	0.42
MMP12	2374	6435	0.04*
MMP13	2100	382	0.68

C.

	Correlation Coefficient	95% CI	P-value
MMP1	0.06	-0.36 to 0.48	0.77
MMP2	0.4	0.05 to 0.75	0.03*
MMP3	0.5	0.10 to 0.90	0.02*
MMP7	-0.3	-0.72 to 0.12	0.16
MMP8	0.08	-0.37 to 0.54	0.71
MMP10	-0.02	-0.42 to 0.37	0.91
MMP12	0.29	-0.10 to 0.69	0.14
MMP13	0.001	-0.40 to 0.40	0.99

FIGURE 4. Comparison of MMP expression levels and patient age. (A) Comparison of MMP expression levels (means \pm SEM) in corneas from patients >50 years old and <50 years old. (B) Summary of MMP expression levels (means) and Wilcoxon rank sum analysis: * $P < 0.05$. (C) Spearman correlation coefficients with bootstrapped 95% confidence intervals for each MMP using age as a continuous variable: * $P < 0.05$.

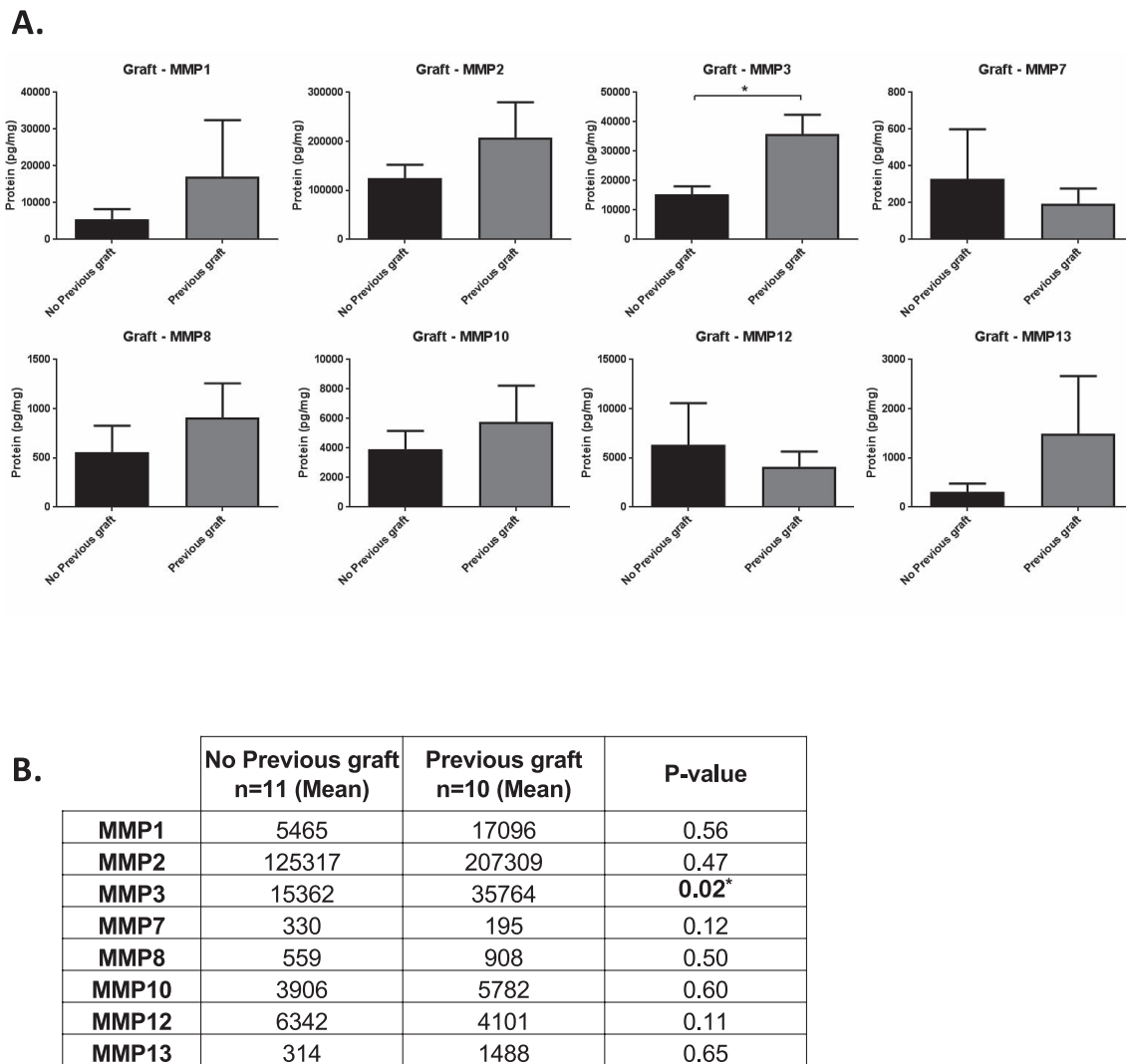


FIGURE 5. Comparison of MMP expression levels and previous graft failure. **(A)** Comparison of MMP expression levels (means \pm SEM) in corneas of patients undergoing their first corneal transplant versus corneas of patients with a history of a prior graft. **(B)** Summary of MMP expression levels (means) and Wilcoxon rank sum: * $P < 0.05$.

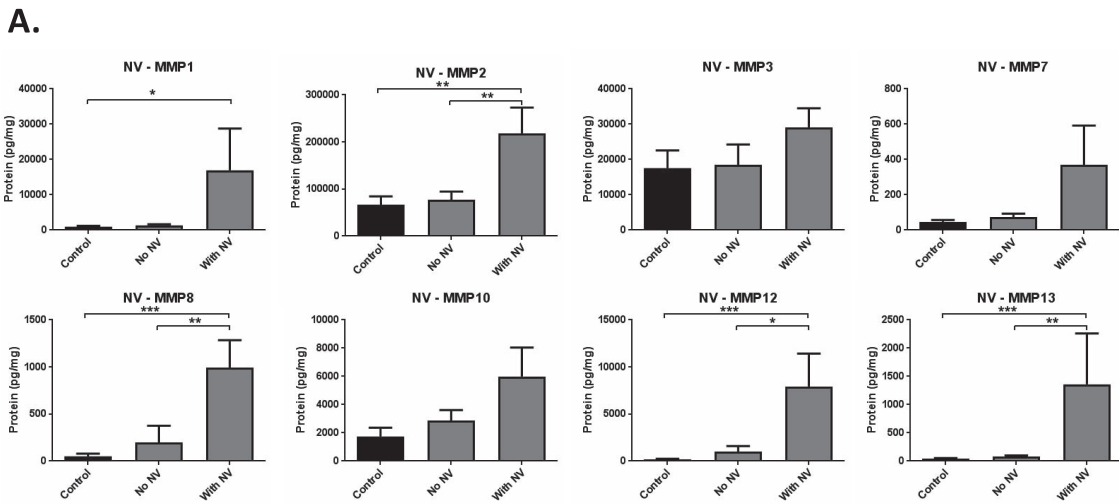
enzyme with a broad substrate range.^{59,60} Similar to MMP12,⁶¹ MMP3 not only acts as a protease but also functions as a transcription factor and mediates tumor progression and arthritis-related tissue remodeling.^{62,63} In different models and tissues, MMP3 overexpression has been linked to antiapoptotic effects,⁶⁴ tumor progression,⁶⁵ and neurodegenerative diseases.⁶⁶ In the eye, MMP3 expression is reduced in the aqueous humor of glaucoma patients.⁶⁷ Interestingly, MMP3 is involved in corneal epithelial cell migration during wound healing.^{68,69} Our findings support further mechanistic studies of the role of MMP3 in corneal pathophysiology and make MMP3 an exciting potential target in patients with keratoconus or in situations of graft rejection.

We measured overexpression of MMP2, 3, 8, and 12 in patients without keratoconus when compared to patients with the disease and overexpression of MMP1, 2, 8, 12, and 13 in patients without keratoconus versus controls. Although MMPs have been suspected to have a role in keratoconus development,⁷⁰ these findings are consistent with earlier studies suggesting that keratoconus is associated with limited inflammation and the finding of generally normal MMP levels in keratoconic corneas.⁴¹ Other groups described mild differential patterns of MMP expression in keratoconic corneas that we

did not detect in our assay, such as slight MMP1 and MMP13 overexpression and MMP8 repression.^{28,71}

One limitation of our study is the absence of MMP14, a key proangiogenic MMP, in our Luminex panel. MMP14 overexpression has been linked to keratoconus^{29,41} and is associated with several molecular mechanisms regulating neovascularization in the cornea following injury.⁷² Entire collected patient corneal samples were used to generate the corneal lysates for the Luminex assay, so we were unable to confirm the presence of MMP14 or the absence of MMP9 by using additional assays. Another limitation is that the Luminex assay does not distinguish between active and inactive MMPs. Future studies will specifically aim at studying the expression of MMP14 and MMP9 in the context of human diseased cornea, as well as classical MMP activity assays, such as zymograms, by using similarly diseased corneas to refine our findings.

Although our study is mostly descriptive, our findings in diseased patient samples favor further mechanistic studies focused on individual MMPs and their regulation of signaling pathways in the context of specific corneal disease processes. Our results support additional mechanistic analyses of MMPs 2, 8, 12, and 13 on corneal neovascularization and fibrosis pathways and MMP3 regulation of keratoconus pathogenesis



B.

	Control n=6 (Mean)	No Neovascularization n=8 (Mean)	With Neovascularization n=13 (Mean)	P-value (Control vs Neovascularization)	P-value (No Neovascularization vs Neovascularization)
MMP1	944	1345	16947	0.02*	0.12
MMP2	66209	77267	217956	0.005**	0.007**
MMP3	17557	18521	29112	0.11	0.08
MMP7	46	73	368	0.08	0.55
MMP8	50	198	994	0.0009***	0.007**
MMP10	1735	2858	5994	0.09	0.60
MMP12	168	984	7915	0.0003***	0.01*
MMP13	39	80	1361	0.0003***	0.001**

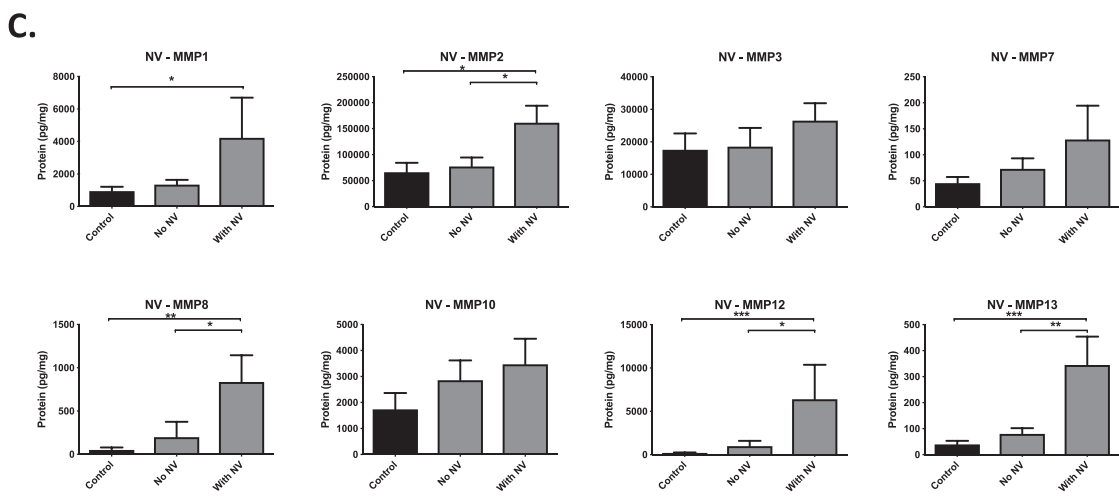
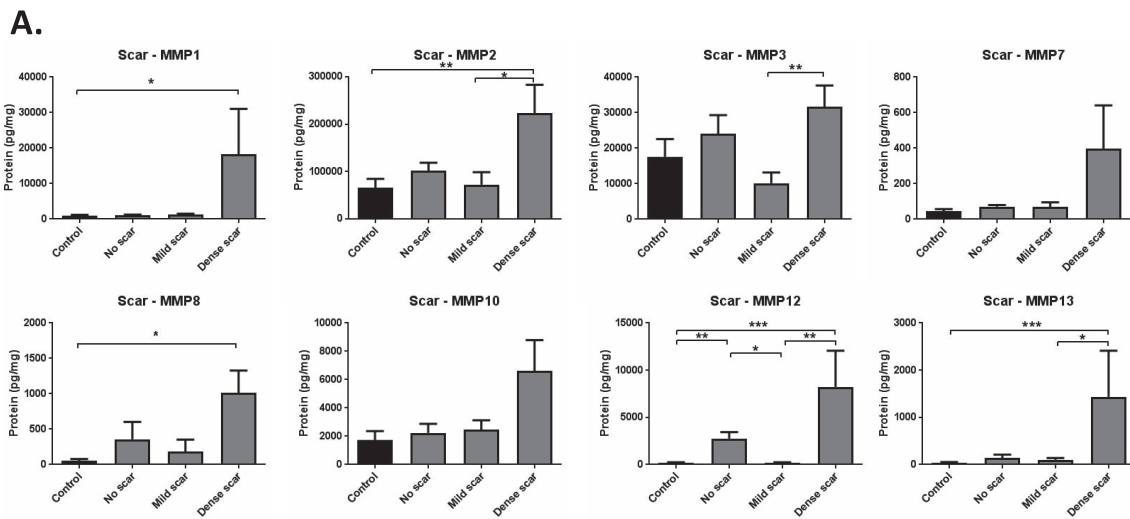


FIGURE 6. MMP expression levels in corneas with varying levels of neovascularization (NV). **(A)** Protein expression levels (means ± SEM) of individual MMPs in control corneas, patient corneas without neovascularization, and patient corneas with neovascularization. **(B)** Summary of MMP expression levels (means) and Wilcoxon rank sum analysis: **P* < 0.05, ***P* < 0.005. **(C)** Subanalysis of **(A)** excluding patients with acute corneal inflammation (patients 8 and 16).



B.

	Control n=6 (Mean)	No scar n=4 (Mean)	Mild scar n=5 (Mean)	Dense scar n=12 (Mean)	P-value (Control vs No scar)	P-value (Control vs Mild scar)	P-value (Control vs Dense scar)	P-value (No scar vs Mild scar)	P-value (No scar vs Dense scar)	P-value (Mild scar vs Dense scar)
MMP1	944	1190	1273	18329	0.26	0.54	0.03*	0.90	0.13	0.13
MMP2	66208	101629	72317	223623	0.17	0.93	0.005**	0.29	0.21	0.03*
MMP3	17557	24024	10177	31637	0.26	0.18	0.15	0.06	0.86	0.009**
MMP7	46	71	69	397	0.26	0.94	0.06	0.40	0.66	0.34
MMP8	50	358	185	1010	0.07	0.99	0.01*	0.40	0.52	0.10
MMP10	1735	2245	2478	6618	0.48	0.43	0.05	0.90	0.45	0.51
MMP12	168	2768	161	8241	0.009**	0.43	0.0008***	0.01*	0.52	0.004**
MMP13	39	137	103	1439	0.11	0.18	0.0004***	0.90	0.10	0.048*

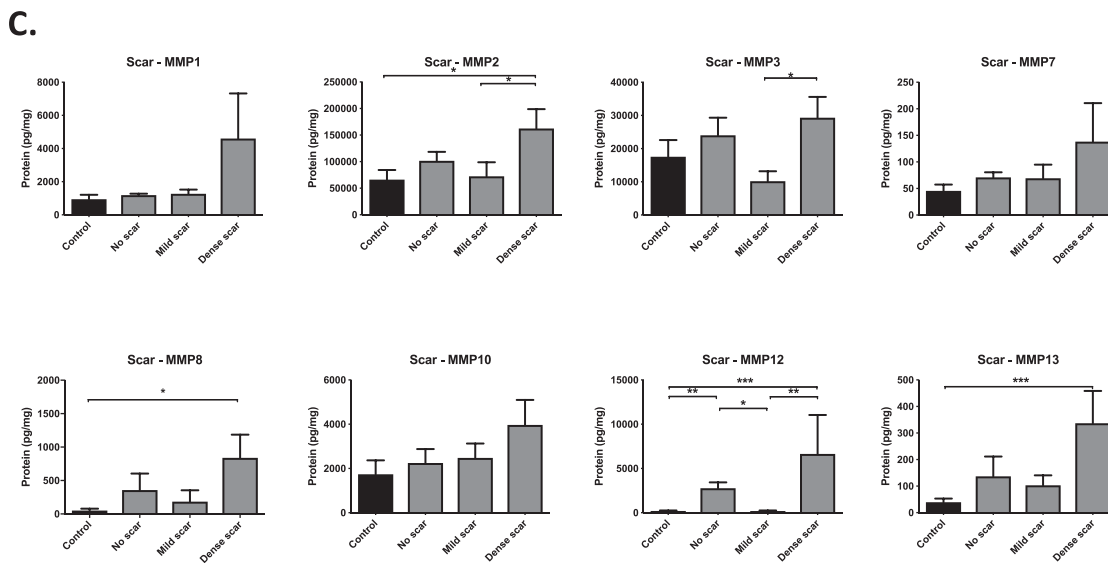


FIGURE 7. MMP expression in corneas with varying levels of fibrosis. (A) Protein expression levels (means ± SEM) of individual MMPs in control corneas and diseased corneas with no, mild, or dense scarring. (B) Summary of MMP expression levels (means) and Wilcoxon rank sum: * $P < 0.05$, ** $P < 0.005$, *** $P < 0.001$. (C) Subanalysis of (A) excluding patients with acute corneal inflammation (patients 8 and 16).

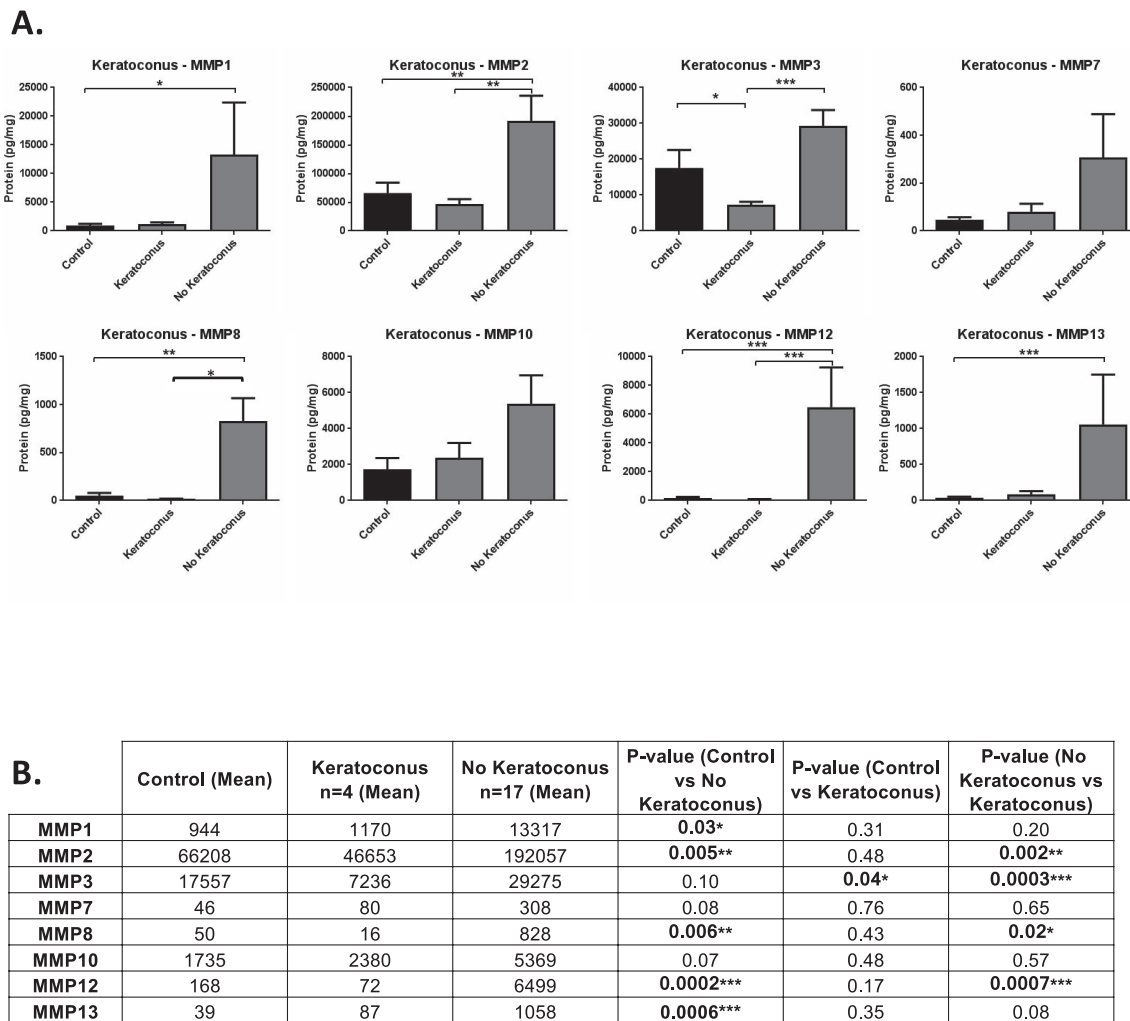


FIGURE 8. MMP expression levels and keratoconus. (A) Protein expression levels (means \pm SEM) of individual MMPs in control corneas and patient corneas with or without keratoconus. (B) Summary of MMP expression levels (means) and Wilcoxon rank sum: * $P < 0.05$, ** $P < 0.005$, *** $P < 0.001$.

and graft rejection. Our prior studies have demonstrated the protective effects of MMP12 on corneal neovascularization, inflammation, and fibrosis through its effects on C-C motif chemokine ligand 2 (CCL2), VEGFA, and plasminogen expression.³⁴ MMPs 2, 8, and 13 have been shown to have an opposite effect and promote corneal neovascularization and fibrosis. A mouse model of inflammation-related corneal neovascularization found a significant delay of neovascularization in MMP2-deficient mice.⁷³ MMP2 is secreted as pro-MMP2 in a complex with tissue inhibitor of metalloproteinase-2. MMP14 cleaves pro-MMP2 and releases activated MMP2, and the intercellular transfer of MMP14 and MMP2 between corneal fibroblasts and endothelial cells may occur during angiogenesis and other biological processes.⁷⁴ The anti-inflammatory effects of dexamethasone have been shown to be mediated through MMP8 via decreased IL-1 β and chemokine (C-X-C motif) ligand 1 (CXCL1) expression in a concomitant dry eye and corneal alkali burn murine model.⁷⁵ Corneal keratocytes express MMP13 through the induction of VEGF α and VEGFr3 and directly degrade type I collagen to create spaces convenient for neovessel growth.³⁵ Notably, expression of tissue inhibitors of matrix metalloproteinases (TIMPs) and extracellular matrix metalloproteinase inducer (EMMPRIN) have been associated with MMP expression inhibition⁷⁶ and induction,⁷⁷ respectively. From a therapeutic

viewpoint, understanding the pathways leading to MMP expression and regulating neovascularization and fibrosis is critical to the identification of novel targets.

In summary, our study has identified individual MMPs that are upregulated in diseased human corneas and whose increased expression corresponds to higher clinical levels of neovascularization and fibrosis. Further mechanistic analysis of the specific roles of these individual MMPs in various corneal diseases, as well as the development of noninvasive methods for measuring MMP levels in vivo, will be critical to improving our understanding of the role of MMPs in the pathophysiology of specific corneal diseases and for identifying potential therapeutic targets.

Acknowledgments

The authors thank Paul Pease and Christian Giddens (Bio-Rad) and Jennifer Legac and Philip Rosenthal (University of California, San Francisco [UCSF]) for their excellent technical support with the Luminex assay.

Supported by grants from the National Institutes of Health (R01 EY022739 to MFC and NIH-NEI EY002162, Core Grant for Vision Research), Research to Prevent Blindness (RPB; Physician-Scientist Award to MFC and an RPB unrestricted grant to the UCSF Department of Ophthalmology), and That Man May See Foundation (to MFC).

Disclosure: **M. Wolf**, None; **S.M. Clay**, None; **C.E. Oldenburg**, None; **J. Rose-Nussbaumer**, None; **D.G. Hwang**, None; **M.F. Chan**, None

References

- Lu P, Takai K, Weaver VM, Werb Z. Extracellular matrix degradation and remodeling in development and disease. *Cold Spring Harb Perspect Biol*. 2011;3:a005058.
- Page-McCaw A, Ewald AJ, Werb Z. Matrix metalloproteinases and the regulation of tissue remodeling. *Nat Rev*. 2007;8:221-233.
- Cui N, Hu M, Khalil RA. Biochemical and biological attributes of matrix metalloproteinases. *Prog Mol Biol Transl Sci*. 2017;147:1-73.
- Schlage P, auf dem Keller U. Proteomic approaches to uncover MMP function. *Matrix Biol*. 2015;44-46:232-238.
- Mott JD, Werb Z. Regulation of matrix biology by matrix metalloproteinases. *Curr Opin Cell Biol*. 2004;16:558-564.
- Ljubimov AV, Saghizadeh M. Progress in corneal wound healing. *Prog Retin Eye Res*. 2015;49:17-45.
- Sivak JM, Fini ME. MMPs in the eye: emerging roles for matrix metalloproteinases in ocular physiology. *Prog Retin Eye Res*. 2002;21:1-14.
- Gaffney J, Solomonov I, Zehorai E, Sagi I. Multilevel regulation of matrix metalloproteinases in tissue homeostasis indicates their molecular specificity in vivo. *Matrix Biol*. 2015;44-46:191-199.
- Chou J, Chan MF, Werb Z. Metalloproteinases: a functional pathway for myeloid cells. *Microbiol Spectr*. 2016;4:MCHD-0002-2015.
- Channa R, Zafar SN, Canner JK, Haring RS, Schneider EB, Friedman DS. Epidemiology of eye-related emergency department visits. *JAMA Ophthalmol*. 2016;134:312-319.
- Hsu KM, Chang SH, Brothers W, Edelstein SL, Hsu HY, Harocopos GJ. Indications for keratoplasty at 3 academic centers from 2002 to 2012. *Eye Contact Lens*. 2016;42:374-379.
- Luengo-Gimeno F, Tan DT, Mehta JS. Evolution of deep anterior lamellar keratoplasty (DALK). *Ocul Surf*. 2011;9:98-110.
- Shimazaki J, Ishii N, Shinzawa M, Yamaguchi T, Shimazaki-Den S, Satake Y. How much progress has been made in corneal transplantation? *Cornea*. 2015;34:S105-S111.
- Craig VJ, Zhang L, Hagoood JS, Owen CA. Matrix metalloproteinases as therapeutic targets for idiopathic pulmonary fibrosis. *Am J Respir Cell Mol Biol*. 2015;53:585-600.
- Rempe RG, Hartz AM, Bauer B. Matrix metalloproteinases in the brain and blood-brain barrier: versatile breakers and makers. *J Cereb Blood Flow Metab*. 2016;36:1481-1507.
- Rabkin SW. The role matrix metalloproteinases in the production of aortic aneurysm. *Prog Mol Biol Transl Sci*. 2017;147:239-265.
- Van Doren SR. Matrix metalloproteinase interactions with collagen and elastin. *Matrix Biol*. 2015;44-46:224-231.
- Houghton AM. Matrix metalloproteinases in destructive lung disease. *Matrix Biol*. 2015;44-46:167-174.
- Pittayapruek P, Meephanan J, Prapapan O, Komine M, Ohtsuki M. Role of matrix metalloproteinases in photoaging and photocarcinogenesis. *Int J Mol Sci*. 2016;17:868.
- Saghizadeh M, Brown DJ, Castellon R, et al. Overexpression of matrix metalloproteinase-10 and matrix metalloproteinase-3 in human diabetic corneas: a possible mechanism of basement membrane and integrin alterations. *Am J Pathol*. 2001;158:723-734.
- Chaerkady R, Shao H, Scott SG, Pandey A, Jun AS, Chakravarti S. The keratoconus corneal proteome: loss of epithelial integrity and stromal degeneration. *J Proteomics*. 2013;87:122-131.
- Galvis V, Sherwin T, Tello A, Merayo J, Barrera R, Acera A. Keratoconus: an inflammatory disorder? *Eye (Lond)*. 2015;29:843-859.
- Lema I, Duran JA, Ruiz C, Diez-Feijoo E, Acera A, Merayo J. Inflammatory response to contact lenses in patients with keratoconus compared with myopic subjects. *Cornea*. 2008;27:758-763.
- Lema I, Duran JA. Inflammatory molecules in the tears of patients with keratoconus. *Ophthalmology*. 2005;112:654-659.
- Balasubramanian SA, Mohan S, Pye DC, Willcox MD. Proteases, proteolysis and inflammatory molecules in the tears of people with keratoconus. *Acta Ophthalmol*. 2012;90:e303-e309.
- Lema I, Sobrino T, Duran JA, Brea D, Diez-Feijoo E. Subclinical keratoconus and inflammatory molecules from tears. *Br J Ophthalmol*. 2009;93:820-824.
- Pannebaker C, Chandler HL, Nichols JJ. Tear proteomics in keratoconus. *Mol Vis*. 2010;16:1949-1957.
- Seppala HP, Maatta M, Rautia M, et al. EMMPRIN and MMP-1 in keratoconus. *Cornea*. 2006;25:325-330.
- Collier SA, Madigan MC, Penfold PL. Expression of membrane-type 1 matrix metalloproteinase (MT1-MMP) and MMP-2 in normal and keratoconus corneas. *Curr Eye Res*. 2000;21:662-668.
- Collazos J, Asensi V, Martin G, Montes AH, Suarez-Zarracina T, Valle-Garay E. The effect of gender and genetic polymorphisms on matrix metalloproteinase (MMP) and tissue inhibitor (TIMP) plasma levels in different infectious and non-infectious conditions. *Clin Exp Immunol*. 2015;182:213-219.
- Otero-Estevéz O, De Chiara L, Rodríguez-Girondo M, et al. Serum matrix metalloproteinase-9 in colorectal cancer family-risk population screening. *Sci Rep*. 2015;5:13030.
- Chau KY, Sivaprasad S, Patel N, Donaldson TA, Luthert PJ, Chong NV. Plasma levels of matrix metalloproteinase-2 and -9 (MMP-2 and MMP-9) in age-related macular degeneration. *Eye (Lond)*. 2008;22:855-859.
- Barro CD, Romanet JP, Fdili A, Guillot M, Morel F. Gelatinase concentration in tears of corneal-grafted patients. *Curr Eye Res*. 1998;17:174-182.
- Chan MF, Li J, Bertrand A, et al. Protective effects of matrix metalloproteinase-12 following corneal injury. *J Cell Sci*. 2013;126:3948-3960.
- Ma DH, Chen JK, Kim WS, et al. Expression of matrix metalloproteinases 2 and 9 and tissue inhibitors of metalloproteinase 1 and 2 in inflammation-induced corneal neovascularization. *Ophthalmic Res*. 2001;33:353-362.
- Li ZR, Li YP, Lin ML, et al. Activated macrophages induce neovascularization through upregulation of MMP-9 and VEGF in rat corneas. *Cornea*. 2012;31:1028-1035.
- Ebrahim Q, Chaurasia SS, Vasanji A, et al. Cross-talk between vascular endothelial growth factor and matrix metalloproteinases in the induction of neovascularization in vivo. *Am J Pathol*. 2010;176:496-503.
- Han KY, Chang JH, Lee H, Azar DT. Proangiogenic interactions of vascular endothelial MMP14 with VEGF receptor 1 in VEGFA-mediated corneal angiogenesis. *Invest Ophthalmol Vis Sci*. 2016;57:3313-3322.
- Duarte S, Baber J, Fujii T, Coito AJ. Matrix metalloproteinases in liver injury, repair and fibrosis. *Matrix Biol*. 2015;44-46:147-156.
- Giannandrea M, Parks WC. Diverse functions of matrix metalloproteinases during fibrosis. *Dis Model Mech*. 2014;7:193-203.

41. Collier SA. Is the corneal degradation in keratoconus caused by matrix-metalloproteinases? *Clin Exp Ophthalmol*. 2001; 29:340-344.
42. Smith VA, Easty DL. Matrix metalloproteinase 2: involvement in keratoconus. *Eur J Ophthalmol*. 2000;10:215-226.
43. Lucas JL, Tacheny EA, Ferris A, et al. Development and validation of a Luminex assay for detection of a predictive biomarker for PROSTVAC-VF therapy. *PLoS One*. 2017;12: e0182739.
44. Bryant-Hudson KM, Carr DJ. CXCL1-deficient mice are highly sensitive to pseudomonas aeruginosa but not herpes simplex virus type 1 corneal infection. *Invest Ophthalmol Vis Sci*. 2012;53:6785-6792.
45. Divito SJ, Hendricks RL. Activated inflammatory infiltrate in HSV-1-infected corneas without herpes stromal keratitis. *Invest Ophthalmol Vis Sci*. 2008;49:1488-1495.
46. Maguen E, Rabinowitz YS, Regev L, Saghizadeh M, Sasaki T, Ljubimov AV. Alterations of extracellular matrix components and proteinases in human corneal buttons with INTACS for post-laser in situ keratomileusis keratectasia and keratoconus. *Cornea*. 2008;27:565-573.
47. Fournie PR, Gordon GM, Dawson DG, Edelhauser HF, Fini ME. Correlations of long-term matrix metalloproteinase localization in human corneas after successful laser-assisted in situ keratomileusis with minor complications at the flap margin. *Arch Ophthalmol*. 2008;126:162-170.
48. Wolf M, Maltseva I, Clay SM, Pan P, Gajjala A, Chan ME. Effects of MMP12 on cell motility and inflammation during corneal epithelial repair. *Exp Eye Res*. 2017;160:11-20.
49. Jobin PG, Butler GS, Overall CM. New intracellular activities of matrix metalloproteinases shine in the moonlight. *Biochim Biophys Acta*. 2017;1864:2043-2055.
50. Lopez-Otin C, Palavalli LH, Samuels Y. Protective roles of matrix metalloproteinases: from mouse models to human cancer. *Cell Cycle*. 2009;8:3657-3662.
51. Decock J, Thirkettle S, Wagstaff L, Edwards DR. Matrix metalloproteinases: protective roles in cancer. *J Cell Mol Med*. 2011;15:1254-1265.
52. Zhang H, Chang M, Hansen CN, Basso DM, Noble-Haesslein LJ. Role of matrix metalloproteinases and therapeutic benefits of their inhibition in spinal cord injury. *Neurotherapeutics*. 2011;8:206-220.
53. Trivedi A, Zhang H, Ekeledo A, et al. Deficiency in matrix metalloproteinase-2 results in long-term vascular instability and regression in the injured mouse spinal cord. *Exp Neurol*. 2016;284:50-62.
54. Amar S, Minond D, Fields GB. Clinical implications of compounds designed to inhibit ECM-modifying metalloproteinases. *Proteomics*. 2017;17:1600389.
55. Levin M, Udi Y, Solomonov I, Sagi I. Next generation matrix metalloproteinase inhibitors - novel strategies bring new prospects. *Biochim Biophys Acta*. 2017;1864:1927-1939.
56. Brejchova K, Liskova P, Hrdlickova E, Filipec M, Jirsova K. Matrix metalloproteinases in recurrent corneal melting associated with primary Sjogren's syndrome. *Mol Vis*. 2009; 15:2364-2372.
57. Predovic J, Balog T, Marotti T, et al. The expression of human corneal MMP-2, MMP-9, proMMP-13 and TIMP-1 in bullous keratopathy and keratoconus. *Coll Antropol*. 2008;32:15-19.
58. Rohini G, Murrugeswari P, Prajna NV, Lalitha P, Muthukkaruppan V. Matrix metalloproteinases (MMP-8, MMP-9) and the tissue inhibitors of metalloproteinases (TIMP-1, TIMP-2) in patients with fungal keratitis. *Cornea*. 2007;26:207-211.
59. Woessner JF Jr. Matrix metalloproteinases and their inhibitors in connective tissue remodeling. *FASEB J*. 1991;5:2145-2154.
60. Matrisian LM. Metalloproteinases and their inhibitors in matrix remodeling. *Trends Genet*. 1990;6:121-125.
61. Marchant DJ, Bellac CL, Moraes TJ, et al. A new transcriptional role for matrix metalloproteinase-12 in antiviral immunity. *Nat Med*. 2014;20:493-502.
62. Eguchi T, Kubota S, Kawata K, et al. Novel transcription-factor-like function of human matrix metalloproteinase 3 regulating the CTGF/CCN2 gene. *Mol Cell Biol*. 2008;28: 2391-2413.
63. Eguchi T, Calderwood SK, Takigawa M, Kubota S, Kozaki KI. Intracellular MMP3 promotes HSP gene expression in collaboration with chromobox proteins. *J Cell Biochem*. 2017;118:43-51.
64. Hiyama T, Ozeki N, Mogi M, et al. Matrix metalloproteinase-3 in odontoblastic cells derived from ips cells: unique proliferation response as odontoblastic cells derived from ES cells. *PLoS One*. 2013;8:e83563.
65. Shoshan E, Braeuer RR, Kamiya T, et al. NFAT1 directly regulates IL8 and MMP3 to promote melanoma tumor growth and metastasis. *Cancer Res*. 2016;76:3145-3155.
66. Kim EM, Hwang O. Role of matrix metalloproteinase-3 in neurodegeneration. *J Neurochem*. 2011;116:22-32.
67. O'Callaghan J, Crosbie DE, Cassidy PS, et al. Therapeutic potential of AAV-mediated MMP-3 secretion from corneal endothelium in treating glaucoma. *Hum Mol Genet*. 2017;26: 1230-1246.
68. Chen J, Chen P, Backman LJ, Zhou Q, Danielson P. Ciliary neurotrophic factor promotes the migration of corneal epithelial stem/progenitor cells by up-regulation of MMPs through the phosphorylation of Akt. *Sci Rep*. 2016;6:25870.
69. Gao J, Raghunathan VK, Reid B, et al. Biomimetic stochastic topography and electric fields synergistically enhance directional migration of corneal epithelial cells in a MMP-3-dependent manner. *Acta Biomater*. 2015;12:102-112.
70. Smith VA, Hoh HB, Littleton M, Easty DL. Over-expression of a gelatinase A activity in keratoconus. *Eye (Lond)*. 1995;9:429-433.
71. Mackiewicz Z, Maatta M, Stenman M, Kontinen L, Tervo T, Kontinen YT. Collagenolytic proteinases in keratoconus. *Cornea*. 2006;25:603-610.
72. Chang JH, Huang YH, Cunningham CM, et al. Matrix metalloproteinase 14 modulates signal transduction and angiogenesis in the cornea. *Surv Ophthalmol*. 2016;61:478-497.
73. Samolov B, Steen B, Seregard S, van der Ploeg I, Montan P, Kvanta A. Delayed inflammation-associated corneal neovascularization in MMP-2-deficient mice. *Exp Eye Res*. 2005;80: 159-166.
74. Han KY, Dugas-Ford J, Seiki M, Chang JH, Azar DT. Evidence for the involvement of MMP14 in MMP2 processing and recruitment in exosomes of corneal fibroblasts. *Invest Ophthalmol Vis Sci*. 2015;56:5323-5329.
75. Bian F, Wang C, Tukler-Henriksson J, et al. MMP-8 is critical for dexamethasone therapy in alkali-burned corneas under dry eye conditions. *J Cell Physiol*. 2016;231:2506-2516.
76. Mittal R, Patel AP, Debs LH, et al. Intricate functions of matrix metalloproteinases in physiological and pathological conditions. *J Cell Physiol*. 2016;231:2599-2621.
77. Gabison EE, Huet E, Baudouin C, Menashi S. Direct epithelial-stromal interaction in corneal wound healing: role of EMMPRIN/CD147 in MMPs induction and beyond. *Prog Retin Eye Res*. 2009;28:19-33.