

Paul R. Dong, MD • Leanne L. Seeger, MD • Lawrence Yao, MD • Claire B. Panosian, MD  
B. Lamar Johnson, Jr, MD • Jeffrey J. Eckardt, MD

## Uncomplicated Cat-Scratch Disease: Findings at CT, MR Imaging, and Radiography<sup>1</sup>

**PURPOSE:** To describe the epidemiologic, clinical, and imaging features of cat-scratch disease (CSD) to facilitate prompt recognition and non-invasive diagnosis of this condition.

**MATERIALS AND METHODS:** Eight otherwise healthy patients with pet cats presented with the subacute onset of epitrochlear, axillary, or groin masses. All underwent cross-sectional imaging with computed tomography (CT) ( $n = 1$ ) or magnetic resonance (MR) imaging ( $n = 7$ ). Five patients underwent radiography of the elbow.

**RESULTS:** In all patients, MR imaging and CT showed a poorly defined soft-tissue mass with extensive surrounding edema in an efferent lymphatic distribution. Radiography revealed only soft-tissue edema in two patients and an ill-defined soft-tissue mass with soft-tissue edema in three patients. Six patients underwent biopsy; the findings of all pathologic specimens supported the diagnosis of CSD. No patients underwent serologic evaluation. All patients were asymptomatic within 4 weeks of beginning antibiotic therapy.

**CONCLUSION:** CSD should be considered in all patients with upper extremity or head and neck adenopathy and a history of cat exposure. Although generally not required for diagnosis, cross-sectional imaging will reveal a mass with surrounding edema in an area of lymphatic drainage.

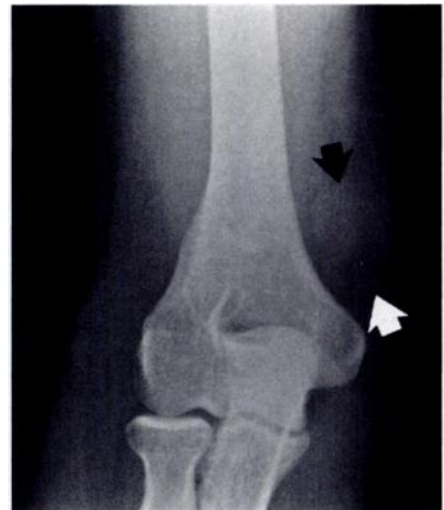**Index terms:** Cat-scratch fever, 40.209, 998.209 • Lymphatic system, infection, 998.8224, 998.209

Radiology 1995; 195:837-839

CAT-SCRATCH disease (CSD) is a benign regional lymphadenitis classically associated with cat scratches, exposure to cats, or both. Before identification of a causative agent, CSD was assumed to be an infectious process. The disease now has been linked definitively to two soil-borne proteobacteria, *Rochalimaea henselae* and *Afipia felis* (1,2). Even without antibiotic therapy, in an otherwise healthy host, the adenitis often resolves spontaneously within 3 weeks to several months. Previous reports have emphasized that CSD may be confused with breast carcinoma (3), soft-tissue sarcoma (4,5), malignant lymphoma, hematoma, and myositis ossificans (4-6). Because the lymphadenopathy associated with CSD is often mistaken for neoplasia or trauma, early consideration of this disorder will often avert an unnecessary surgical procedure. Although the diagnosis of CSD can often be rendered on clinical grounds, confirmation with use of radiologic and serologic studies may be useful if the diagnosis is in question.

### MATERIALS AND METHODS

Between 1990 and 1994, we encountered eight patients in whom CSD was eventually diagnosed and who underwent cross-sectional imaging of one or more soft-tissue masses before presentation at our institution. Of these eight patients (four male patients, four female patients; age range, 11-36 years; mean age, 21.5 years), seven patients were initially referred to our surgical oncologist with the presumed diagnosis of neoplasm. The duration of their symptoms was 3-8 weeks, with an average of 4.5 weeks. All patients had pet cats, and although none



**Figure 1.** Anteroposterior radiograph of the elbow reveals an ill-defined soft-tissue mass (arrows) with surrounding edema in the epitrochlear region.

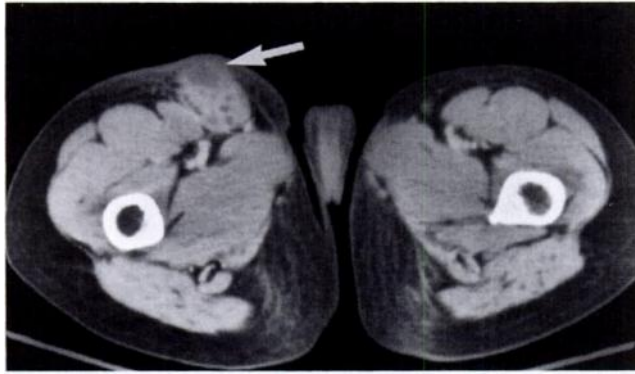
could recall a specific history of a cat scratch, one patient had multiple small scratches on his hands that were assumed to be from his cat. All patients denied fever.

The location of the dominant soft-tissue mass(es) included the medial epitrochlear region in six patients, the axilla in one patient, and the inguinal region in one patient. Six masses were tender to palpation, and two were nontender. The results of physical examination in two patients with a primary epitrochlear site of involvement revealed additional ipsilateral axillary nodes in one patient and bilateral axillary nodes in the other. The patient who presented with a dominant axillary mass also had contralateral axillary adenopathy and an epitrochlear mass.

Laboratory testing was performed in three patients, including white blood cell (WBC) count and erythrocyte sedimentation rate (ESR) in two patients, and WBC count alone in another. No serology studies or skin tests for CSD were performed.

**Abbreviations:** CSD = cat-scratch disease, ESR = erythrocyte sedimentation rate, WBC = white blood cell.

<sup>1</sup> From the Departments of Radiological Sciences (P.R.D., L.L.S., L.Y.), Medicine, Division of Infectious Diseases (C.B.P., B.L.J.), and Orthopedic Surgery (J.J.E.), University of California Los Angeles School of Medicine, 200 UCLA Medical Plaza, Suite 165-59, Los Angeles, CA 90024-6952. Received December 21, 1994; revision requested January 26, 1995; revision received February 14; accepted February 20. Address reprint requests to L.L.S.



**Figure 2.** Contrast-enhanced CT scan of the pelvis shows a poorly marginated, lobulated mass in the right groin that is surrounded by subcutaneous edema. Note rim enhancement (arrow), which is suggestive of an abscess.

Cultures for aerobic, anaerobic, fungal, and acid-fast organisms were obtained on lymph node specimens from two patients.

Imaging evaluation included radiography of the elbow in five patients, contrast material-enhanced computed tomography (CT) of the groin in one patient, and magnetic resonance (MR) imaging of the epitrochlear mass in seven patients, of whom two received intravenous contrast material. Imaging studies were performed at outside institutions; consequently, a variety of MR imaging systems and pulse sequences were employed. Spin-echo T1- and T2-weighted images were available in all cases. All MR images were interpreted at the institutions of origin as either suspicious for or most consistent with neoplasm.

Two patients underwent excisional lymph node biopsy (one epitrochlear node and one groin node), and four patients underwent fine-needle aspiration biopsy of their epitrochlear masses. These six patients then received either cephalixin or doxycycline. The two other patients were treated empirically with doxycycline for a presumptive diagnosis of CSD on the basis of their history, results of physical examination, and the characteristic appearance of their MR images. Symptoms resolved in all patients within 4 weeks of beginning antibiotic therapy.

## RESULTS

### Laboratory Evaluation

One patient had a mildly elevated WBC count ( $10.1 \times 10^9/L$ ; normal range, 4.5–10.0). WBC count and ESR were otherwise normal in the three patients tested. The two lymph node cultures failed to grow organisms.

### Imaging

In the five patients who underwent plain radiography, two studies showed only subcutaneous edema, and three revealed an ill-defined soft-tissue mass with soft-tissue edema in

the epitrochlear region (Fig 1). The one available CT scan showed an ill-defined mass with a low-attenuation center that was believed to represent necrosis (Fig 2). All seven MR images demonstrated an ill-defined mass with surrounding edema (Fig 3). The mass was an area of heterogeneous low signal intensity on T1-weighted images that was isointense to muscle. With T2 weighting, the area of the mass and surrounding edema became hyperintense. The peripheral portion of the mass enhanced in both patients who received intravenous contrast material (Fig 4).

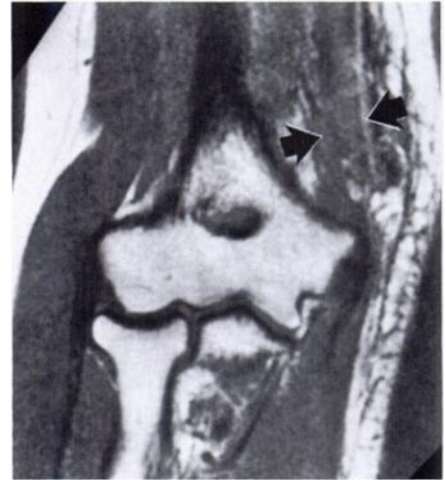### Pathologic Examination

Findings of the six pathologic specimens were consistent with CSD. At microscopic examination, the masses were composed of enlarged lymph nodes partially replaced by granulomas with central necrosis, palisading epithelioid cells, multinucleated giant cells, and lymphocytes with debris.

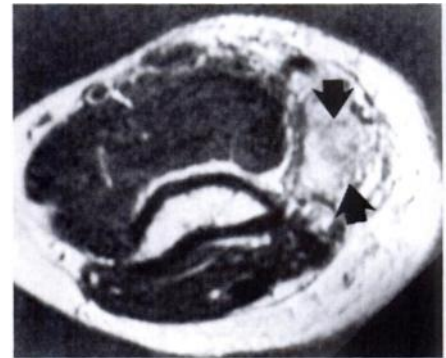
## DISCUSSION

CSD was first recognized in 1889 by Parinaud (7), and the cat was first recognized as the vector and carrier of the disease in 1931 by Debré et al (8). In 1985, Gerber and associates (9) cultivated the organism *R henselae*, a gram-negative coccobacillus currently believed to be the most common cause of the syndrome.

CSD is seen worldwide, and 60%–70% of cases affect individuals between the ages of 5 and 21 years (10). An estimated 2,000 cases occur annually in the United States (10). Although the exact mode of transmission is not known in all patients, 93% of affected patients have a history of exposure to a cat (10). Disease that

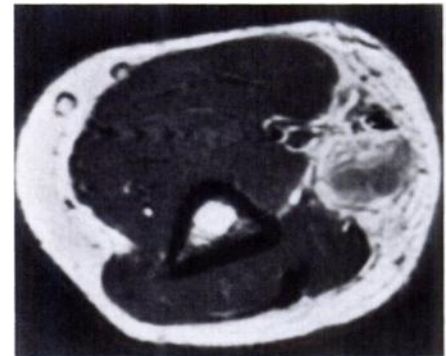


a.



b.

**Figure 3.** (a) Coronal T1-weighted (spin echo, repetition time msec/echo time msec = 600/20) and (b) axial T2-weighted (spin echo, 2,300/80) MR images. Extensive subcutaneous edema is evident on the T1-weighted image, and an ill-defined mass (arrows) is seen in the epitrochlear region on both images.



**Figure 4.** Axial T1-weighted, contrast-enhanced MR image (spin echo, 600/20). Note the mass effect due to the large necrotic node. Only the peripheral part of the mass enhances, a finding that would be expected with an abscess.

results from exposure to dogs also has been reported but is rare (11). Cats that serve as vectors for CSD are not ill and need not be destroyed (12).

Three to ten days after exposure, the inoculated area may erupt with

one or more nonpruritic papules or pustules. These lesions usually resolve in days to weeks. Three to four weeks later, most patients develop painful regional adenopathy in the draining proximal lymph nodes. Because the hands and forearms are frequent sites of inoculation, adenopathy often develops around the elbow, axilla, and head and neck. Specific areas of adenopathy include, in decreasing order of frequency, total upper extremity (axillary and epitrochlear nodes); neck and jaw (cervical and submandibular nodes); groin; and the preauricular, supraclavicular, and postauricular lymphatic chains (12). Single nodal involvement has been reported in 44%–85% of patients (13,14). Multiple nodal involvement at a single site is present in 24% of cases. The adenopathy usually resolves within 3 months but can persist for up to a year (13). Organisms are not usually cultured from tissue specimens by using routine microbiologic techniques (14); thus, histologic studies for CSD may be nonspecific. Warthin-Starry staining may reveal bacilli (14), and serologic tests for *R. henselae* are now commercially available (15).

Malaise, aches, anorexia, headache, sore throat, and nausea and vomiting are constitutional symptoms that may be seen in immunocompetent patients with CSD (16). Atypical manifestations include Parinaud oculoglandular syndrome, encephalitis, meningitis, cerebral arteritis, neuritis, granulomatous hepatitis, osteomyelitis, thrombocytopenic purpura, pneumonia, and mesenteric adenitis (16,17). In immunocompromised patients with human immunodeficiency virus infection or transplanted organs, a systemic infection due to *R. henselae* has been described that is characterized by cutaneous proliferative vascular lesions (epithelioid hemangioma or bacillary angiomatosis), subcutaneous nodules, and osteolytic lesions (18); systemic CSD also has been associated with septic shock after renal transplantation (19).

Treatment for uncomplicated CSD is controversial. Some authors believe that the disease is self-limited, and no antibiotic has been shown to alter the

course of the disease in previously healthy patients (13,14,20). Others have found that intravenous gentamicin is effective in treatment of the disease (21), as is oral trimethoprim-sulfamethoxazole (22). In immunocompromised hosts with bacillary angiomatosis, erythromycin and doxycycline have both produced excellent clinical results, although extended therapy for weeks to months may be required followed by lifelong maintenance in any patient who experiences a clinical relapse (22).

Imaging findings in classic CSD depict markedly enlarged lymph nodes with extensive surrounding edema in the distribution of lymphatic drainage proximal to the site of inoculation. In a previous report of CSD, CT of an affected epitrochlear node showed a soft-tissue mass with mixed attenuation and central low attenuation consistent with a necrotic lymph node surrounded by edema (6). Our findings on MR images were similar.

In conclusion, CSD is a benign inflammatory adenitis caused by at least two etiologic agents, *R. henselae* and *A. felis*. The domestic cat is the vector for this disease. The resultant necrotic nodes are often mistaken clinically for soft-tissue sarcomas or other neoplasms. The diagnosis of CSD should be suspected in relatively young patients with lymphadenopathy in the upper extremity or head and neck region and a history of exposure to a cat. Imaging generally does not play a role in this setting, but findings of a mass with an inflammatory appearance support the diagnosis. Serologic confirmation can be obtained, and surgical intervention most likely can be averted. Antimicrobial therapy is probably beneficial in hastening the resolution of adenitis. Patients suspected of having CSD should, however, be followed up clinically until symptoms resolve. ■

#### References

- English CK, Wear DJ, Margileth AM, Lissner CR, Walsh GP. Cat-scratch disease: isolation and culture of the bacterial agent. *JAMA* 1988; 259:1327–1352.
- Dolan MJ, Wong MT, Regnery RL, et al. Syndrome of *Rochalimaea henselae* adenitis suggesting cat scratch disease. *Ann Intern Med* 1993; 118:331–336.
- Lefkowitz M, Wear DJ. Cat-scratch disease masquerading as a solitary tumor of the breast. *Arch Pathol Lab Med* 1989; 113:473–475.

- Luddy RE, Sutherland JC, Levy BE, Schwarta AD. Cat-scratch disease simulating malignant lymphoma. *Cancer* 1982; 50:584–586.
- Nimityongskul P, Anderson LD, Sri P. Cat-scratch disease: orthopaedic presentation. *Orthop Rev* 1992; 21:55–59.
- Fox BC, Gurtler RA. Cat-scratch disease mimicking rhabdomyosarcoma. *Orthop Rev* 1993; 1148–1149.
- Parinaud H. Conjunctivite infectieuse paraissant transmise à l'homme par les animaux. *Soc Ophthalmol Paris* 1889; 2:29–31.
- Debré R, Lamy M, Jammet M, Costil L, Mozziconacci P. La maladie des griffes de chat. *Bull Mem Soc Med Hop* 1950; 66:76–79.
- Gerber MA, Sedgwick AK, MacAllister TJ, Gustafson KB, Ballow M, Tilton RC. The aetiological agent of cat scratch disease. *Lancet* 1985; 1:1236–1239.
- Margileth AM. Cat scratch disease. In: Wyngaarden JB, Smith LH, eds. *Cecil textbook of medicine*. 18th ed. Philadelphia, Pa: Saunders, 1988; 1679–1681.
- Margileth AM. Update on cat-scratch disease. *Hosp Med* 1989; 25:61–81.
- Carithers HA. Cat-scratch disease: an overview based on a study of 1,200 patients. *Am J Dis Child* 1985; 139:1124–1133.
- Margileth AM. Dermatologic manifestations and update of cat-scratch disease. *Pediatr Dermatol* 1988; 5:1–9.
- Margileth AM. Cat scratch disease: non-bacterial regional lymphadenitis; the study of 145 patients and a review of the literature. *Pediatrics* 1968; 42:803–818.
- Adal KA, Cockerell CJ, Petri WA. Cat scratch disease, bacillary angiomatosis, and other infections due to *Rochalimaea*. *N Engl J Med* 1994; 330:1509–1515.
- Roberge RJ. Cat-scratch disease. *Emerg Med Clin North Am* 1991; 9:327–333.
- Lewis DW, Tucker SH. Central nervous system involvement of cat-scratch disease. *Pediatrics* 1986; 77:714–721.
- Baron AL, Steinbach LS, LeBoit PE, Mills CM, Gee JH, Berger TG. Osteolytic lesions and bacillary angiomatosis in HIV infection: radiologic differentiation from AIDS-related Kaposi sarcoma. *Radiology* 1990; 177:77–81.
- Black JR, Herrington DA, Hadfield TL, Wear DJ, Margileth AM, Shigehawa B. Life-threatening cat-scratch disease in an immunocompromised host. *Arch Intern Med* 1986; 146:394–396.
- Carithers HA. Oculoglandular disease of Parinaud: a manifestation of cat-scratch disease. *Am J Dis Child* 1978; 132:1195–1200.
- Bogue CW, Wise JD, Gray GF, Edwards KM. Antibiotic therapy for cat-scratch disease? *JAMA* 1989; 262:813–816.
- Collipp PJ. Cat-scratch disease: therapy with trimethoprim-sulfamethoxazole. *Am J Dis Child* 1992; 146:397–399.