

UC San Diego

UC San Diego Previously Published Works

Title

A case of disseminated coccidioidomycosis and immune reconstitution inflammatory syndrome (IRIS) in a patient with HIV/AIDS.

Permalink

<https://escholarship.org/uc/item/7gv7x2vx>

Authors

Kaplan, Samantha
Rajagopal, Amutha
Cachay, Edward
et al.


Publication Date

2023

DOI

10.1016/j.idcr.2023.e01896

Peer reviewed



Case report

A case of disseminated coccidioidomycosis and immune reconstitution inflammatory syndrome (IRIS) in a patient with HIV/AIDS

Samantha R. Kaplan^{*}, Amutha Rajagopal, Edward R. Cachay, Robert Deiss

Division of Infectious Diseases and Global Public Health, University of California San Diego, San Diego, CA, USA

ARTICLE INFO

Keywords:

HIV/AIDS
coccidioidomycosis
fungal infections
immune reconstitution inflammatory syndrome
corticosteroids

ABSTRACT

Coccidioidomycosis is a fungal infection endemic to the southwestern United States and Central/South America, and its range is expanding with the warming climate. People with HIV/AIDS are at increased risk of developing disseminated infection, and furthermore are at risk for developing immune reconstitution inflammatory syndrome (IRIS) if they are initiating or re-initiating anti-retroviral therapy (ART). There have been few cases of coccidioidomycosis-related IRIS reported in the literature, and there is no clear guidance on treatment. We present a case of paradoxical IRIS in a patient with AIDS who clinically improved after initiating corticosteroids.

Introduction

Coccidioidomycosis is caused by either *Coccidioides immitis* or *Coccidioides posadasii*, which are endemic fungal species in the southwestern United States and parts of Central and South America. People with suppressed cellular immunity including Acquired Immunodeficiency Syndrome (AIDS) have an increased risk of developing disseminated coccidioidomycosis as an opportunistic infection [1]. Moreover, following initiation of antiretroviral therapy (ART), this group is at-risk for development of Immune Reconstitution Inflammatory Syndrome (IRIS). IRIS is generally classified into two categories: “paradoxical” and “unmasking.” In paradoxical IRIS, there is worsening of a known, diagnosed opportunistic infection after ART initiation. In unmasking IRIS, ART initiation typically “unmasks” a new opportunistic infection, often with marked clinical inflammation [2,3].

Due to the limited geographic spread of coccidioidomycosis, only a few cases of coccidioidomycosis-related IRIS have been published, and guidance regarding the timing of ART initiation is lacking [3–8]. We present a case of disseminated coccidioidomycosis in a patient with AIDS who developed severe paradoxical IRIS following ART initiation and was successfully treated with corticosteroids.

Case presentation

A 50-year-old male with AIDS (CD4 12 cells/ μ L [4%]; HIV RNA 99,300 copies/mL), who had recently moved from Indiana to southern California, having been off ART for four years, presented to our

emergency room with dyspnea, palpitations, and chest tightness. His past medical history was notable for polysubstance use disorder (methamphetamines, fentanyl injection drug use, tobacco), bipolar disorder, prior endocarditis, and homelessness.

His presentation was notable for supraventricular tachycardia with heart rates in the 250s requiring emergent cardioversion. After cardioversion, he was febrile (39.2C), slightly hypertensive (143/88 mmHg), tachycardic (heart rate 118), and tachypneic (respiratory rate 22), with normal oxygen saturation 99% on ambient air. Physical exam revealed oropharyngeal thrush, bilateral axillary and inguinal lymphadenopathy, and a non-focal neurological exam. Abnormal laboratory studies were notable for hemoglobin 8.6 gm/dL (13.7 – 17.5), sodium 125 mmol/L (136–145), bicarbonate 18 mmol/L (22–29), blood urea nitrogen 28 mg/dL (6–20), aspartate transferase 79 U/L (0–40), albumin 2.7 g/dL (3.5–5.2). A rapid COVID-19 / influenza nasopharyngeal PCR test was negative. Serum cryptococcal antigen was negative.

Chest x-ray showed extensive opacity of the right lung. He was started on broad-spectrum antimicrobials (vancomycin and piperacillin-tazobactam) in addition to fluconazole 200 mg daily for oral candidiasis. A computed tomography (CT) scan of the chest, abdomen, and pelvis two days later revealed miliary disease in the lungs (Fig. 1), a right upper lobe cavitory lesion, as well as multiple hypoattenuating lesions in the spleen. Blood cultures grew *Streptococcus perioris* and 1,3-beta-D-glucan was positive at > 500 pg/mL (normal <60). The fluconazole dose was increased to 400 mg daily given the imaging findings were likely indicative of disseminated fungal disease, and antimicrobials were narrowed to ceftriaxone 2g daily. He defervesced within four days of

^{*} Corresponding author at: 9500 Gilman Drive, Mail Code 0507, La Jolla, CA 92093-0507, USA.

E-mail address: Samantha.r.kaplan@gmail.com (S.R. Kaplan).

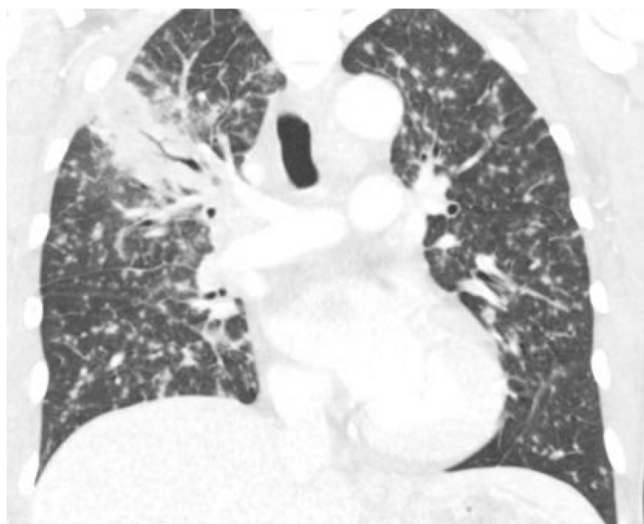


Fig. 1. Admission CT scan of the chest, coronal view.

admission. Serial AFB sputum cultures and MTB PCRs were negative for *M. tuberculosis*. Eight days into admission, the sputum cultures grew *Coccidioides immitis*, and the patient was started on liposomal amphotericin B 5 mg/kg for disseminated coccidioidomycosis, in addition to ART with bictegravir / emtricitabine / tenofovir alafenamide plus dolutegravir. *Coccidioides* serology testing (IgM and IgG) was negative at this time, which was thought to be consistent with early infection.

On hospital day 13, the patient began having high-grade fevers and altered mental status, prompting further investigational studies to rule out nosocomial complications, persistent or worsening infection (including repeat blood and fungal blood cultures), additional opportunistic infections, as well as consideration of paradoxical IRIS related to his currently treated disseminated coccidioidomycosis. CSF analysis and MRI brain and spine were normal. Serum CMV PCR was 64 copies/mL with no evidence of CMV retinitis on the ophthalmologic exam. Serum HHV8 PCR was elevated at 23,400 copies/mL. Repeat serum cryptococcal antigen was negative. Admission blood cultures eventually grew *Coccidioides immitis* 17 days into admission, consistent with a high burden of disease and prompting further consideration of a diagnosis of paradoxical IRIS. We initiated dual antifungal therapy with the addition of fluconazole 800 mg daily. However, he continued to have fevers for an additional ten days, prompting initiation of methylprednisolone 30 mg/day for presumed paradoxical IRIS, which was further supported by a rise in CD4 to 46 cells/ μ L (13%) and decline in HIV VL to 316 copies/mL two weeks after ART initiation.

Following the initiation of corticosteroids, the patient remained afebrile for six days, with one additional fever prompting a modification of the steroid taper (Fig. 2). His mental status improved ten days after starting steroids, and he was continued on a steroid taper for a total of 28 days. The patient was successfully discharged on hospital day 38, afebrile, with normal mentation. He was continued on fluconazole 800 mg daily for the remainder of his prednisone taper, in addition to

ART and atovaquone for *Pneumocystis jiroveci* prophylaxis. We decreased the fluconazole dose to 400 mg PO daily after the patient completed his steroid taper (45 days after initiation of antifungal therapy) and plan to continue it indefinitely pending his clinical course. Of note, *Coccidioides* IgM was positive four weeks after diagnosis at hospital discharge, but IgG and complement fixation (CF) titer were negative. IgG and CF titer remained negative three months after diagnosis. The CF titer was 1:32 eight months after diagnosis.

The patient has been intermittently followed at our HIV primary care clinic for 1.5 years since hospital discharge and has been mostly adherent to ART and fluconazole. His most recent CD4 was 232 (13%) cells/ μ L and HIV VL 158 copies/mL.

Discussion

We present a case of disseminated coccidioidomycosis in a patient with AIDS, who exhibited signs of paradoxical IRIS (fevers, delirium) despite proper antifungal therapy six days after ART re-initiation. The diagnosis of paradoxical IRIS was supported by a rise in CD4 from 12 (4%) to 46 (13%) and a decline in HIV viral load from 99,300 to 316 after ART initiation, with a negative workup for alternative clinical explanations. The most compelling argument for paradoxical IRIS relies on two important clinical facts. First, we knew his diagnosis: disseminated coccidioidomycosis. Second, the patient had been on proper antifungal therapy for over a week and had initially improved before his fever recurred. This coincided with over ten days of antiretroviral treatment, which signaled that the amplification of antigenic response throughout his immune system was restored despite proper antifungal therapy. This immune response is the reason that the immunomodulatory effect of corticosteroids helps to resolve the clinical manifestations of this syndrome; indeed, the patient improved after starting corticosteroids.

Our literature review revealed nine additional cases of coccidioidomycosis-related IRIS among patients initiating ART, five of whom died due to complications from severe coccidioidomycosis (Table 1) [3–8]. Three of these cases had a similar presentation and timeline to our case, in that paradoxical IRIS occurred less than two weeks after ART initiation [3,5]. However, all of these three cases had a longer duration of antifungal therapy prior to ART initiation, and two of them died. The third case was successfully treated with a prolonged corticosteroid taper and was the only other patient besides ours to be treated with steroids; this patient was newly diagnosed with HIV (CD4 166 cells/ μ L, HIV RNA 3.97 million copies/mL), had disseminated disease to the lungs and inguinal lymph nodes, and was initiated on ART and fluconazole. Subsequently the patient developed fevers and hypoxic respiratory failure consistent with paradoxical IRIS, which improved with steroid initiation [5].

In one other case of unmasking IRIS with cutaneous manifestations, steroids may have played a role in IRIS management as they were initiated for a number of days, but not for a prolonged taper [8]. In another case of disseminated disease including to the adrenal glands, steroids were used to treat adrenal insufficiency and so may have masked the severity of the paradoxical IRIS presentation [4].

Current professional guidelines do not comment on corticosteroid

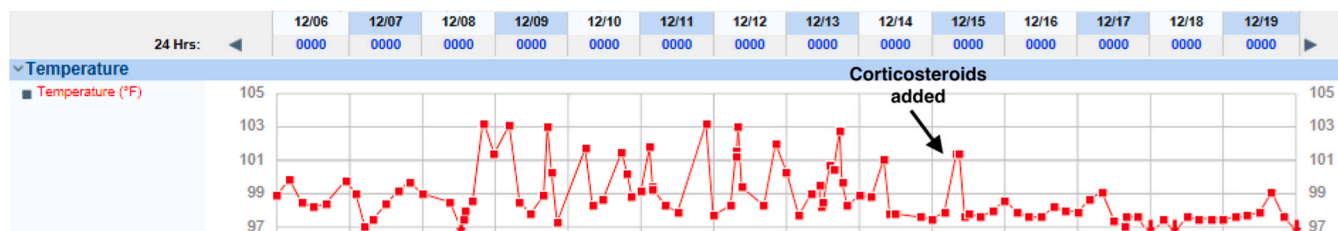


Fig. 2. Fever curve: corticosteroid taper was initiated on 12/15, resulting in defervescence.

Table 1
Summary of reported coccidiomycosis-associated IRIS cases from the literature.

	At time of coccidiomycosis diagnosis					At time of IRIS diagnosis			Anti-fungal therapy	Days of anti-fungal therapy prior to ART	Time to IRIS after ART	Type of IRIS	IRIS management			Outcome
	Age	Sex	Signs/symptoms	CD4 count*	HIV VL**	Signs/symptoms	CD4 count*	HIV VL**					Treatment	When initiated	Duration	
This case	50	M	Pulmonary, miliary / disseminated	12	99,300	Fevers, delirium	46	316	LAmB, fluconazole	7	6d	Paradoxical	Steroids, continue ART	10d into IRIS	28d	Resolved
Yaqoob et al. [2]	31	M	Pulmonary, adrenal, disseminated	120	5.29 million	Pulmonary	364	370	Fluconazole	0	NR (likely days)	Paradoxical	ART hold (5 weeks)	N/A	N/A	Resolved
Lin et al. [3]	27	M	Pulmonary, lymphadenopathy	166	3.97 million	Fevers, pulmonary	387	193	fluconazole	28	14d	Paradoxical	steroids +posaconazole	NR	36d	Resolved
Mortimer et al. [5]	39	M	pulmonary	30	NR	Pulmonary, SVC syndrome	154	<50	fluconazole	41	27 m	Paradoxical	Surgery, 1 g AmB, continue ART	N/A	N/A	Resolved
D'Avino et al. [7]	48	M	disseminated	20	212,240	Rash, arthralgias, lymphadenopathy	148	<50	fluconazole	0	11 m	Unmasking	Steroids x several days, increase fluconazole	NR	Days (unspecified)	Resolved
Trible et al. [6]	59	M	CNS, disseminated	45	420,720	CNS, disseminated	163	790	voriconazole	0	2 m	Unmasking	Continue ART	N/A	N/A	Died 2 m after ART
Mu et al. [4] Case 1	37	F	pulmonary, CNS, disseminated	44	170,077	Fever, rash, cough	225	NR	fluconazole	60	21d	Paradoxical	Stop ART	N/A	N/A	Died 2 m after ART
Mu et al. [4] Case 2	41	M	CNS, pulmonary, skin	<20	23,489	CNS, pulmonary, cutaneous	NR	NR	LAmB	21	8d	Paradoxical	Continue ART	N/A	N/A	Died 2w after ART
Mu et al. [4] Case 3	27	M	Pulmonary, miliary / disseminated	149	126,028	Pulmonary, disseminated	255	<20	LAmB	21	30d	Paradoxical	Continue ART	N/A	N/A	Died 1 m after ART
Mu et al. [4] Case 4	43	M	Pulmonary, disseminated	21	239,624	Fevers, pulmonary	22	74	LAmB	28	10d	Paradoxical	Continue ART	N/A	N/A	Died 22d after ART

ART: antiretroviral therapy; CNS: central nervous system; d: days; F: female; IRIS: immune reconstitution inflammatory syndrome; LAmB: liposomal amphotericin B; m: months;

M: male; NR: not reported; VL = viral load; w- weeks

*cells/mL; **copies/mL.

use for coccidioidomycosis-related IRIS [2], owing to a lack of evidence and concerns that corticosteroids can worsen invasive fungal infections [9], as described in HIV-associated cryptococcal meningitis [10,11]. Lin et al.'s case [5] and this case suggest otherwise.

This case also highlights some challenges in the diagnosis of coccidioidomycosis in the immunocompromised host. The patient's *Coccidioides* serology by enzyme immunoassay (IgM and IgG) was negative at the time of diagnosis despite cultures growing the organism in both sputum and blood. This was presumably due to early infection as it may take several weeks for antibodies to develop [1]. At the end of the patient's hospitalization four weeks later, the IgM was positive but the complement fixation remained negative. The complement fixation remained negative two months later while it converted to positive (titer 1:32) eight months after initial testing. We presume that this delayed positive serological positivity could have been related to the patient's immunosuppression as his CD4 count had only increased to 46 at the time of discharge; other studies have shown similar phenomena [12,13]. Other possible explanations include 1) a false negative reaction or prozone effect due to the excess of antigens in extensive dissemination of disease, 2) the use of different reference laboratories for initial and repeat testing, since IgG results may vary between laboratories [12], or 3) the presence of antibody levels below the sensitivity of testing method.

This case suggests that coccidioidomycosis-related IRIS can be successfully treated with corticosteroids while continuing concurrent antifungal and ART therapies. We suspect that issues in treating coccidioidomycosis, both in immunocompromised and immunocompetent patients, will become more pressing with climate change as the geographical range and number of patients infected with coccidioidomycosis expands beyond the southwestern United States [14]. Future studies may guide us regarding the optimal timing of ART initiation in patients with AIDS and disseminated coccidioidomycosis; current guidelines do not recommend delaying ART therapy in this context [1, 2]. In summary, systemic corticosteroid therapy in a patient with coccidioidomycosis-related IRIS was safe and effective in managing IRIS while continuing proper antifungal and ART therapies.

Funding

This research did not receive any specific grant from funding agencies in the public, commercial, or not-for-profit sectors.

Conflict of interest statement

The authors have no conflicts of interest.

Acknowledgements

The authors would like to acknowledge the patient and the multi-disciplinary care team that has contributed to his care.

References

- [1] Galgiani JN, Ampel NM, Blair JE, Catanzaro A, Geertsma F, Hoover SE, Johnson RH, Kusne S, Lisse J, MacDonald JD, Meyerson SL, Raksin PB, Siever J, Stevens DA, Sunenshine R, Theodore N. 2016 Infectious Diseases Society of America (IDSA) clinical practice guideline for the treatment of coccidioidomycosis. *Clin Infect Dis* 2016;63:e112–46.
- [2] Guidelines for the Prevention and Treatment of Opportunistic Infections in Adults and Adolescents with HIV. 2023. (Accessed 16 June 2023, at (<https://clinicalinfo.hiv.gov/en/guidelines/adult-and-adolescent-opportunistic-infection>)).
- [3] Mu A, Shein TT, Jayachandran P, Paul S. Immune reconstitution inflammatory syndrome in patients with AIDS and disseminated coccidioidomycosis: a case series and review of the literature. *J Int Assoc Provid AIDS Care* 2017;16:540–5.
- [4] Yaqoob H, Munawar MM, Salih O, Deonarine A. Disseminated coccidioidomycosis in a patient who is immunocompromised in the setting of immune reconstitution inflammatory syndrome. *BMJ Case Rep* 2021;14.
- [5] Lin AY, Chun V, Dhamija A, Bordin-Wosk T, Kadakia A. Immune reconstitution inflammatory syndrome in an HIV-infected patient with disseminated coccidioidomycosis. *Int J STD AIDS* 2019;30:923–6.
- [6] Mortimer RB, Libke R, Eghbalieh B, Bilello JF. Immune reconstitution inflammatory syndrome presenting as superior vena cava syndrome secondary to coccidioides lymphadenopathy in an HIV-infected patient. *J Int Assoc Physicians AIDS Care (Chic)* 2008;7:283–5.
- [7] Tribble R, Edgerton N, Hayek S, Winkel D, Anderson AM. Antiretroviral therapy-associated coccidioid meningitis. *Emerg Infect Dis* 2013;19:163–5.
- [8] D'Avino A, Di Giambenedetto S, Fabbiani M, Farina S. Coccidioidomycosis of cervical lymph nodes in an HIV-infected patient with immunologic reconstitution on potent HAART: a rare observation in a nonendemic area. *Diagn Microbiol Infect Dis* 2012;72:185–7.
- [9] Lionakis MS, Kontoyiannis DP. Glucocorticoids and invasive fungal infections. *Lancet* 2003;362:1828–38.
- [10] Li Z, Denning DW. The impact of corticosteroids on the outcome of fungal disease: a systematic review and meta-analysis. *Curr Fungal Infect Rep* 2023;17:54–70.
- [11] Beardsley J, Wolbers M, Kibengo FM, Ggayi A-BM, Kamali A, Cuc NTK, Binh TQ, Chau NVV, Farrar J, Merson L, Phuong L, Thwaites G, Van Kinh N, Thuy PT, Chierakul W, Siriboon S, Thiansukhon E, Onsanit S, Supphamongkholchaikul W, Chan AK, Heyderman R, Mwinjiwa E, van Oosterhout JJ, Imran D, Basri H, Mayxay M, Dance D, Phimmasone P, Rattanavong S, Laloo DG, Day JN. Adjunctive dexamethasone in HIV-associated cryptococcal meningitis. *N Engl J Med* 2016; 374:542–54.
- [12] Blair JE, Coakley B, Santelli AC, Hentz JG, Wengenack NL. Serologic testing for symptomatic coccidioidomycosis in immunocompetent and immunosuppressed hosts. *Mycopathologia* 2006;162:317–24.
- [13] Fish DG, Ampel NM, Galgiani JN, Dols CL, Kelly PC, Johnson CH, Pappagianis D, Edwards JE, Wasserman RB, Clark RJ, et al. Coccidioidomycosis during human immunodeficiency virus infection. a review of 77 patients. *Med (Baltim)* 1990;69: 384–91.
- [14] Gorris ME, Treseder KK, Zender CS, Randerson JT. Expansion of coccidioidomycosis endemic regions in the United States in response to climate change. *GeoHealth* 2019;3:308–27.