

# UC Davis

## Dermatology Online Journal

### Title

Recognizing localized perioral solar elastosis: a common finding often overlooked

### Permalink

<https://escholarship.org/uc/item/7mc5q99v>

### Journal

Dermatology Online Journal, 30(6)

### Authors

Keatts, Sydney A

Shin, Riley

Black, T Austin

et al.

### Publication Date

2024

### DOI

10.5070/D330664705

### Copyright Information

Copyright 2024 by the author(s). This work is made available under the terms of a Creative Commons Attribution-NonCommercial-NoDerivatives License, available at

<https://creativecommons.org/licenses/by-nc-nd/4.0/>

Peer reviewed

# Recognizing localized perioral solar elastosis: a common finding often overlooked

Sydney A Keatts<sup>1</sup> BS, Riley Shin<sup>2</sup> BSA, T Austin Black<sup>1</sup> BS, Rashid M Rashid<sup>3</sup> MD PhD

Affiliations: <sup>1</sup>John P and Katherine G McGovern Medical School at University of Texas Health Houston, Houston, Texas, USA, <sup>2</sup>Texas Tech University Health Sciences Center School of Medicine, Lubbock, Texas, USA, <sup>3</sup>Mosaic Dermatology, Houston, Texas, USA

Corresponding Author: RM Rashid MD PhD, Mosaic Dermatology, 2211 Norfolk Street, Suite 405, Houston, TX 77098, Tel: 281-941-5556, Email: [rashidmdphd@gmail.com](mailto:rashidmdphd@gmail.com)

## Abstract

Solar elastosis is a form of photoaging theorized to result from long-term exposure to ultraviolet radiation. Clinically, solar elastosis manifests as yellow, atrophic, rhytid skin with a leathery appearance, most commonly affecting sun-exposed areas such as the face, neck, chest, or arms. Owing to its well-documented association with an elevated risk of skin cancer, recognizing the presence of solar elastosis is essential for clinicians. In this case, we evaluate a presentation of solar elastosis confined strictly to the perioral region, sparing the remainder of sun-exposed facial areas.

*Keywords: elastosis, perioral, photoaging, solar, ultraviolet*

## Introduction

Solar elastosis, also known as actinic elastosis, is a type of photoaging theorized to result from long-term and repeated exposure to ultraviolet (UV) radiation. Clinically, solar elastosis manifests as yellow, atrophic, rhytid skin with a leathery appearance, most commonly affecting the face, neck, chest, or arms. The exact mechanism of solar elastosis pathogenesis is unknown but is believed to result from chronic inflammation and the overproduction of elastic tissue synthesized from abnormal fibroblasts related to UV damage [1]. Although solar elastosis is not an unusual finding, it is often overlooked unless patients present with specific complaints. We report a case of a 79-year-old woman with solar elastosis localized to the perioral

region, sparing the cheek, nose, and remainder of the face. This case highlights the importance of recognizing that solar elastosis can vary in presentation, both in location and appearance.

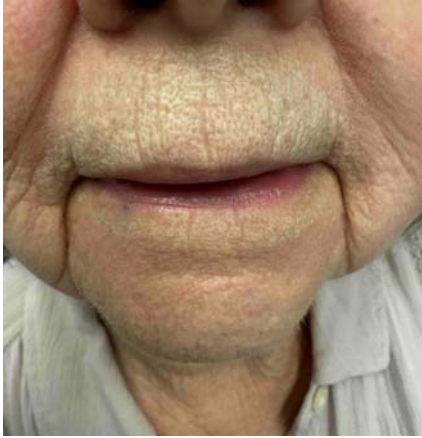## Case Synopsis

A 79-year-old light-skinned woman presented to the dermatology clinic with a five-year history of a non-pruritic rash localized to the perioral region. Although asymptomatic, the region's stark color change and cosmetic appearance prompted the patient to seek medical attention. Her past medical history was positive for hypertension, type II diabetes mellitus, and chronic kidney disease. Current medications include dapagliflozin, glimepiride, irbesartan, and metformin.

Physical examination showed thickened and coalescing yellow papules confined strictly to the perioral region (**Figure 1**). Notably, the remainder of the sun-exposed face was spared. The patient denied any prior history of treatments to the area, such as hair bleaching or waxing. A shave biopsy showed histologic findings consistent with solar elastosis (**Figure 2**). Treatment options, including laser resurfacing, peels, and tacrolimus, were discussed with the patient, who ultimately declined once a non-cancerous diagnosis was given.

## Case Discussion

Although the exact pathogenesis remains unknown, it is suspected that solar elastosis is a direct result of

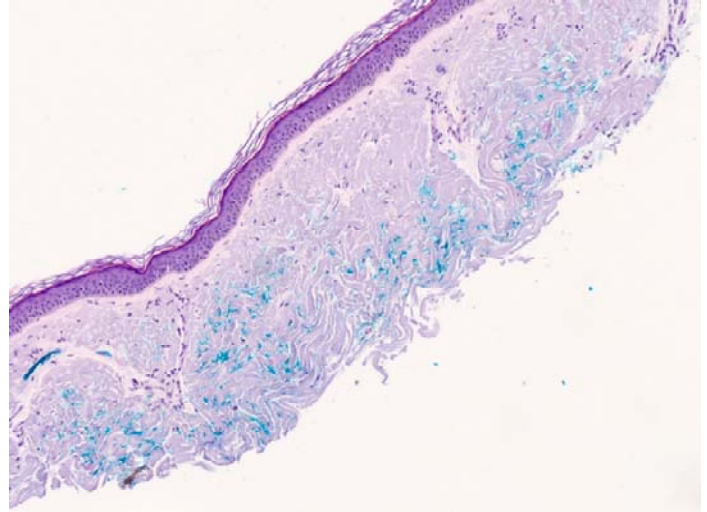


**Figure 1.** Clinical photograph showing solar elastosis isolated to the perioral region.

long-term sun damage, with the degree of elastosis correlating with the cumulative amount of UV radiation [2]. Heat and chemical-based treatments are also hypothesized to contribute to the development of solar elastosis [3]. Histologically, solar elastosis is characterized by elastic fiber hyperplasia, disorganization, and aggregation in the dermis, increasing the ratio of elastic tissue to collagen and proportionally reflecting the severity of the damage. In the affected dermis, elastotic fibers stain basophilic with hematoxylin and eosin stain, contrasting normal elastotic fibers that stain eosinophilic [1].

Several different variants of solar elastosis have been described throughout the literature. The various clinical presentations are believed to be attributed to a combination of long-term sun damage, intrinsic host genetic factors, and extrinsic factors such as mechanical stress or site-specific weakening of stromal support. Despite the unique clinical features of each variant, the histopathology remains consistent across all solar elastosis variants. Notable regions for these variants include the forearms, hands, nose, periorbital/malar region, neck, and chest [2]. One study reports a unilateral facial plaque with post-palpitory erythema [4]. Although our report of solar elastosis confined to the perioral region is not representative of a new variant, it highlights a common presentation that can be easily overlooked owing to its asymptomatic nature.

Individuals with solar elastosis, especially those with more severe cases, have a higher incidence of



**Figure 2.** H&E histologic preparation obtained via shave biopsy displaying an abundance of elastotic fiber in the superficial dermis, 10x.

melanoma, basal cell carcinoma, and squamous cell carcinoma. Thus, solar elastosis could serve as a marker for long-term UV damage and a predictor for the potential development of skin cancers [5]. This can be especially important in our elderly populations who have a significant history of lifetime sun exposure. Although treatment options are available, such as topical exfoliants, vitamins, chemical peels, dermabrasion, and lasers, the abnormal aggregation of elastotic fibers cannot be reversed [1]. Therefore, it is crucial that solar elastosis be identified and patients maintain regular dermatology visits as a preventative measure.

## Conclusion

Solar elastosis is a physical manifestation of long-term sun damage, characterized histologically by elastic fiber hyperplasia, disorganization, and aggregation in the dermis. We present a patient with solar elastosis localized to the perioral region. This manifestation of solar elastosis warrants awareness, helping to ensure proper identification and treatment of this condition.

## Potential conflicts of interest

The authors declare no conflicts of interest.

## References

1. Lewis KG, Bercovitch L, Dill SW, Robinson-Bostom L. Acquired disorders of elastic tissue: part I. Increased elastic tissue and solar elastotic syndromes. *J Am Acad Dermatol.* 2004;51:1-21. [PMID: 15243519].
2. Calderone DC, Fenske NA. The clinical spectrum of actinic elastosis. *J Am Acad Dermatol.* 1995;32:1016-24. [PMID: 7751446].
3. Stanford DG, Georgouras KE, Killingsworth M. Raimer's bands: case report with a review of solar elastosis. *Acta Derm Venereol.* 1995;75:372-4. [PMID: 8615055].
4. Wittal RA, Georgouras KE, Baird PJ, Cleary EG, Henderson M. Unilateral facial actinic elastotic plaque--a new clinical variant of actinic elastosis. *Australas J Dermatol.* 1989;30:15-22. [PMID: 2486047].
5. Carey FA, Hogan JM. The relationship of sun exposure and solar elastosis to skin cancer in a high risk population. *Ir J Med Sci.* 1990;159:44-7. [PMID: 2347678].