UC Davis
UC Davis Previously Published Works

Title

Clinical and magnetic resonance imaging (MRI) findings in 26 dogs with canine osseous-associated cervical spondylomyelopathy.

Permalink

https://escholarship.org/uc/item/7pw3h9rg

Journal

Canadian Veterinary Journal, 55(2)

ISSN

0008-5286

Authors

Murthy, Vishal D
Gaitero, Luis
Monteith, Gabrielle

Publication Date

2014-02-01

Copyright Information

This work is made available under the terms of a Creative Commons Attribution-NonCommercial-NoDerivatives License, available at https://creativecommons.org/licenses/by-nc-nd/4.0/

Peer reviewed

eScholarship.org Powered by the California Digital Library
University of California

Article

Clinical and magnetic resonance imaging (MRI) findings in 26 dogs with canine osseous-associated cervical spondylomyelopathy

Vishal D. Murthy, Luis Gaitero, Gabrielle Monteith

Abstract — The potential link between degenerative changes seen on magnetic resonance imaging (MRI) in osseous-associated cervical spondylomyelopathy (OA-CSM) and clinical signs has not been explored. Our goal was to retrospectively evaluate MRI findings, while investigating potential correlations between these changes, signalment, and clinical signs. Twenty-six dogs diagnosed with OA-CSM were included in the study. Clinical signs were converted into a Modified Frankel Score (MFS) and MRI findings were assessed and graded. Giant breeds had multiple compressed sites and presented at a younger age than large breeds, suggesting a different underlying pathophysiology. Spinal cord compression, most commonly bilateral, was present in 36.8% of intervertebral spaces. Synovial fluid loss and articular process sclerosis were the most common degenerative changes. Most dogs showed identical MFS scores, and no significant correlations were found between MFS and MRI changes. More detailed functional scales should be used to investigate this in the future.

Résumé — Constatations cliniques et résultats de l'imagerie par résonance magnétique (IRM) chez 26 chiens atteints de spondylomyélopathie cervicale osseuse canine. Le lien potentiel entre les changements dégénératifs observés sur l'imagerie par résonance magnétique (IRM) dans la spondylomyélopathie cervicale osseuse (SMC-O) et les signes cliniques n'a pas été exploré. Notre but consistait à évaluer rétrospectivement les résultats de l'IRM, tout en faisant enquête sur les corrélations potentielles entre ces changements, le signalement et les signes cliniques. Vingt-six chiens diagnostiqués avec la SMC-O ont été inclus dans l'étude. Les signes cliniques ont été convertis en une cote Frankel modifiée (CFM) et les résultats de l'IRM ont été évalués et cotés. Les races géantes présentaient des sites de compression multiples et étaient atteintes à un plus jeune âge que les grandes races, ce qui suggère une pathophysiologie sous-jacente différente. La compression de la moelle épinière, le plus souvent bilatérale, était présente dans 36,8 % des espaces intervertébraux. La perte de liquide synovial et la sclérose du processus articulaire constituaient les changements dégénératifs les plus fréquents. Des cotes de CFM identiques ont été signalées chez la plupart des chiens et aucune corrélation significative n'a été constatée entre les changements de la CFM et de l'IRM. Des échelles fonctionnelles plus détaillées devraient être utilisées pour enquêter ces cas dans l'avenir.

(Traduit par Isabelle Vallières)

Can Vet J 2014;55:169–174

Introduction

Cervical spondylomyelopathy (CSM), also known as Wobbler's syndrome, cervical vertebral instability, or cervical vertebral malformation-malarticulation, is commonly seen in large and giant breed dogs, in which chronic spinal cord compression leads to a range of clinical neurological signs from neck pain to tetraparesis (1–3). The pathophysiology of CSM is still not well understood, although it is widely accepted as being complex and multifactorial (1). Two main forms of this condition have been described in the veterinary literature. One form is disc-associated cervical spondylomyelopathy (DA-CSM), whose pathophysiology includes intervertebral disc protrusion as the main finding (1,3). This form is typically seen in middle-aged large breed dogs such as the Doberman pinscher (1,3). The other form is osseous-associated cervical spondylomyelopathy (OA-CSM), which occurs secondary to proliferation of the bony structures (primarily the articular processes) surrounding the spinal cord and is typically seen in young giant breed dogs like the Great Dane and Bernese mountain dog (1,3,4).

Magnetic resonance imaging (MRI) is the gold standard imaging modality for the diagnosis of cervical spondylomyelopathy, as it is safe, non-invasive, and provides high-resolution

Department of Clinical Studies, Ontario Veterinary College, University of Guelph, Guelph, Ontario N1G 2W1.

Address all correspondence to Dr. Luis Gaitero; e-mail: lgaitero@uoguelph.ca

This project was partially funded by the University of Guelph Undergraduate Research Assistantship (URA) program.

Use of this article is limited to a single copy for personal study. Anyone interested in obtaining reprints should contact the CVMA office (hbroughton@cvma-acmv.org) for additional copies or permission to use this material elsewhere.

Table 1. Modified Frankel Scale for OA-CSM

Modified Frankel Scale for OA-CSM	Clinical neurological signs
0 (most severely affected)	Tetraplegia with no deep nociception
1	Tetraplegia with nociception
2	Nonambulatory tetraparesis
3a	Ambulatory tetraparesis and ataxia
3b	Ambulatory paraparesis and pelvic limb ataxia with normal/mildly affected thoracic limbs
4	Spinal hyperaesthesia only
5 (least severely affected)	Complete lack of neurological signs

digital images in multiple planes (5,6). It also provides good visualization of the spinal cord parenchyma, articular joint processes, synovial fluid, cysts, nerve roots, and intervertebral discs (1,3,5,6).

While there are several studies in the veterinary literature investigating the pathophysiology of CSM, information on the potential links between OA-CSM and the clinical signs at presentation is limited (1–4). The clinical signs might correlate with the severity or type of degenerative and compressive changes seen. This information could be helpful in determining prognosis, improving understanding of this complex disease, and may assist in decision-making regarding treatment recommendations.

Our objectives were to describe, grade, and determine the frequency and type of pathological changes seen on MRI of dogs diagnosed with OA-CSM, and to investigate potential correlations between signalment, clinical signs, and MRI findings.

Materials and methods

A retrospective search of medical records at the Ontario Veterinary College Health Sciences Centre was conducted, involving all dogs diagnosed with OA-CSM based on MRI of the cervical spine and clinical presentation between January 2005 and May 2012. Cases without complete MRI study available for analysis and/or detailed medical records were excluded from the study, resulting in 26 dogs being identified.

The medical records of each dog were reviewed to collect information on the signalment and duration of clinical signs at the time of MRI. Details of the clinical neurological signs were also recorded and used to generate a score based on a Modified Frankel Scale (MFS) adapted for the specific purposes of the study (Table 1) (4,7–10).

Available MRI studies of the cervical spine for each dog were reviewed. All MRI images had been acquired under general anesthesia with the dogs positioned in dorsal recumbency using the same 1.5 Tesla unit (Signa 1.5 Tesla Excite II, General Electric Medical Systems, USA, Software v11.1). A slice thickness of 3 mm was used in all cases and TR and TE were optimized for each scan. Transverse slices were taken perpendicular to the spinal canal and there were 1 to 3 sections through each disc. Field of view ranged from 32 cm × 32 cm to 48 cm × 48 cm for sagittal and dorsal images, and from 14 cm × 14 cm to 18 cm × 18 cm for transverse images. Digital MRI images from C1 to T2, in the transverse and sagittal planes, were reviewed by 2 observers (VM, LG), using GE Advantage Workstation, Software v4.2 (General Electric Medical Systems), and measurements taken using the FuncTool Performance package (General Electric Medical Systems). Observers included a board-certified neurologist and a veterinary medical student trained for the purposes of the study by the neurologist. Results were recorded based on a consensus opinion between the 2 observers.

All three T2-weighted image (T2WI) planes were assessed at each intervertebral space from C2 to T2 for the presence and type of spinal cord compression (dorsal midline, left lateral, left dorsolateral, right lateral, right dorsolateral, bilateral, bidorsolateral, ventral or bilateral with a ventral component). Spinal cord compression was also quantitatively assessed using transverse T2WI images. Cross-sectional area (CSA) of spinal cord at the point of maximum compression was measured by manually tracing the outline of the spinal cord within the epidural fat and cerebrospinal fluid (CSF) (Figure 1). Similarly, measurements of CSA were taken from uncompressed regions immediately cranial and caudal to the compressed region. These normal measurements were used to calculate an average normal CSA for comparison. In 7 intervertebral spaces where compression was found, there was no image of a normal spinal cord available just caudally to the compressed slice; in these cases, only the cranial normal CSA was used for calculations instead of an average normal CSA. Percentage of compression was calculated as a percentage of average CSA of normal spinal cord, using the formula (5):

$$\text{Degree of Compression (\% Compression)} = \frac{\text{Average Normal CSA} - \text{Compressed CSA}}{\text{Average Normal CSA}}$$

On transverse T2WI taken at each intervertebral space articular process, joints were assessed for the presence of synovial fluid (0 = present, 1 = reduced, 2 = absent), articular surface quality (0 = smooth/normal, 1 = mildly sclerotic, 2 = irregular, severely sclerotic), and presence of dorsal and lateral hypertrophy (0 = normal, 1 = mild, 2 = severe) (3). Lateral hypertrophy was defined as outward lateral growth of bone, unlike Gutierrez-Quintana and Penderis (3), from whom the scales were adapted. Foraminal stenosis was also assessed in the same transverse T2WI based on a 0–3 scale (0 = no stenosis), where mild stenosis (grade 1) was judged to involve minor attenuation of the nerve, moderate stenosis (grade 2) involved a narrowing of about half the diameter, and severe stenosis (grade 3) was judged to involve loss of signal of the nerve, epidural fat, and cerebrospinal fluid signals. An example of the grading used is shown in Figure 2.

Inter-vertebral disc degeneration and herniation were evaluated using sagittal and transverse T2WI. Intervertebral disc degeneration was graded from 0 to 2 (0 = normal disc, 1 = partially degenerated, 2 = absent). Disc degeneration was defined as absent if the disc had a uniform ellipsoid high signal intensity, partially degenerated if part of the disc was hypointense, and completely degenerated when the entire disc was hypointense. Disc herniations were graded from 0 to 3: 0 = no herniation, a mild score (grade 1) was assigned when $< 25\%$ of the vertebral canal was occupied by extruded disc material, moderate (grade 2) was judged when $> 25\%$, but $< 50\%$ of the canal was filled, and severe (grade 3) was judged when 50% or more of the canal was filled with herniated disc material.

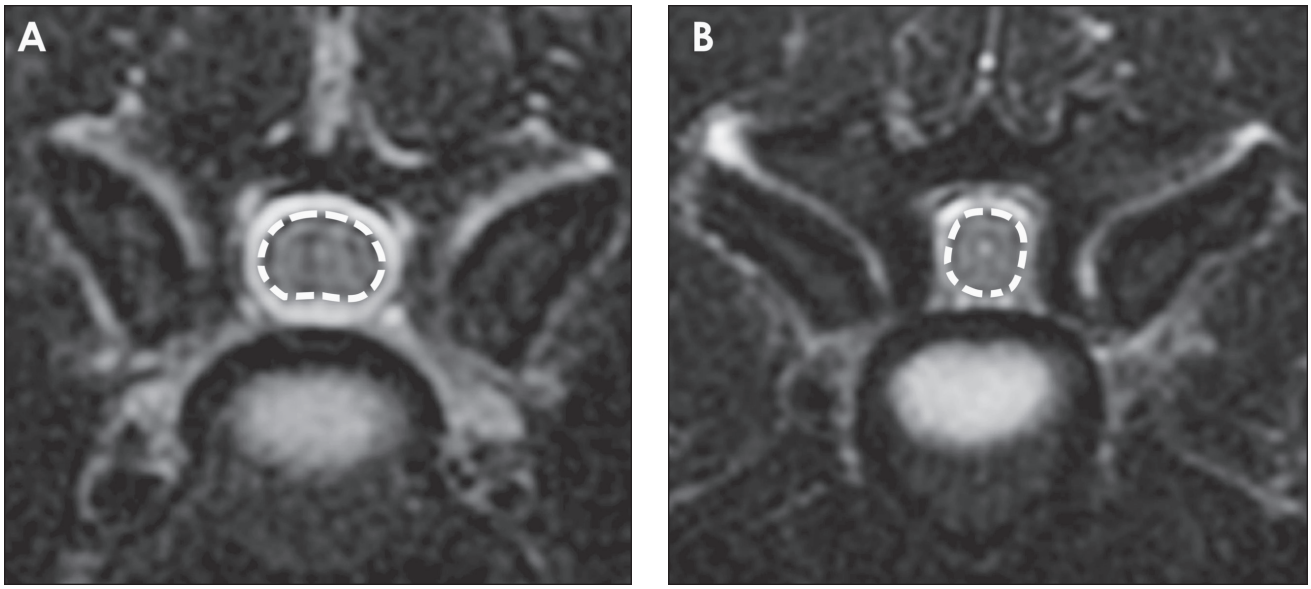

Figure 1. Comparison of normal (A) and compressed (B) spinal cords from the same dog, with outlines showing measured cross-sectional area. A – an image of C6-C7; B – an image of C5-C6.

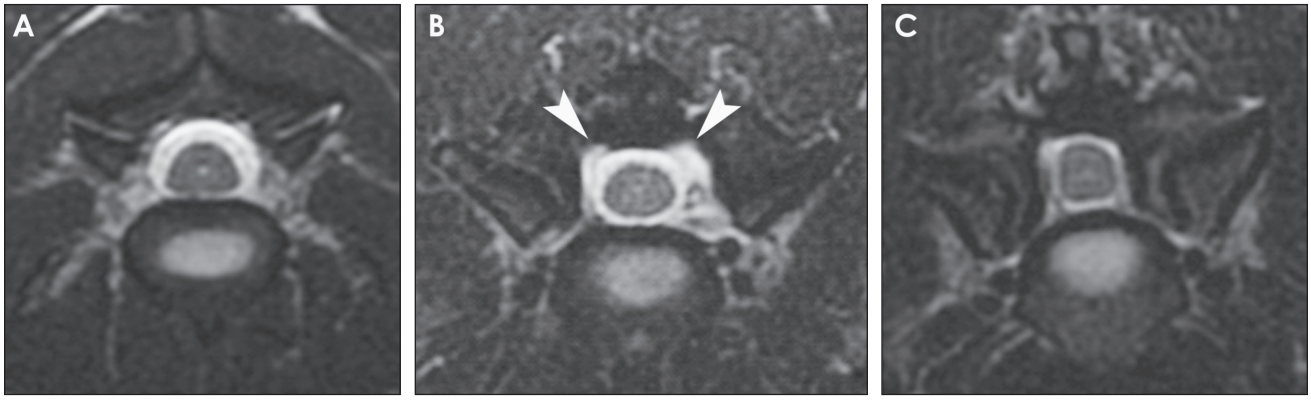

Figure 2. Comparison of severity of degenerative changes. A – Normal intervertebral space at C2-C3. B – Reduced synovial fluid (grade = 1), mild articular sclerosis (grade = 1), mild foraminal stenosis (grade = 1), and synovial cysts (arrowheads) at C4-C5. C – Reduced synovial fluid (grade = 1), severe articular sclerosis (grade = 2), and severe foraminal stenosis (grade = 3) at C5-C6. Mild disc bulging and bilateral compression are also evident.

The entire cervical spinal cord was evaluated on T2WI for the presence of intramedullary signal changes, synovial cysts, and attenuation of the epidural fat and cerebrospinal fluid.

Statistical analysis

All statistical analyses were performed on SAS 9.2 software (SAS OnlineDoc 9.2; SAS Institute, Cary, North Carolina, USA), where significance was defined as $P < 0.05$.

All parameters were assessed for normal distribution, to determine if transforms were required and to apply appropriate tests. A 2-tailed pooled *t*-test was used to determine if there was a significant difference in age and total number of compressions between breeds (giant breed dogs *versus* large breed dogs). A Kruskal-Wallis analysis of variance (ANOVA) with a post hoc Tukey (adjusted pairwise comparisons) was used to determine if there was a significant difference between intervertebral (IV) spaces for mean grades of the various degenerative changes. The type of compression was compared to different types of degenerative changes via Kruskal-Wallis ANOVAs. For some parameters (synovial cysts within the IV space, intramedullary changes, disc herniation, disc degeneration, lateral hypertrophy, attenuation of epidural fat and synovial cysts outside the IV space), score data were best treated as binary outcomes either due to the scale used, or poor distribution of scores. For these parameters, an exact logistic regression was done, and exact odds ratios were calculated. Logistic regression was also used to determine if modified Frankel score predicted degenerative changes at any IV space.

Spearman correlation was used to determine if there was an association between degenerative changes. This was also done to look for correlations between Frankel score and scored parameters of degenerative changes by IV space, as well as between Frankel score and percent compression by space. Spearman correlation tests were also conducted to look for correlations between the Frankel score and age at MRI, duration of signs, number of compressions, and total sum of compressions (i.e., sum of degree of compression in each IV space for each dog).

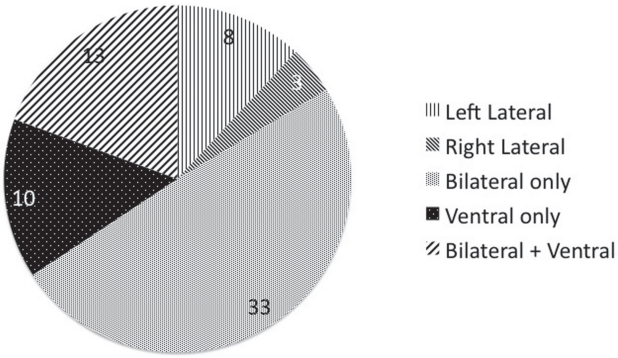

Figure 3. Distribution of compression types amongst the 67 compressed sites identified in 26 dogs.

Due to small numbers, midline compressions and bidorsolateral compressions were grouped with bilateral compressions. Similarly, unilateral dorsolateral compressions were grouped with their respective lateral compression type. For similar reasons, disc degeneration and disc herniation were treated as binary parameters for the statistical analysis.

Results

Twenty-six dogs, 20 giant and 6 large breeds, were included in the study. Giant breed dogs included 7 Bernese mountain dogs, 3 Rottweilers, 9 Great Danes, and 1 mastiff. Large breed dogs included 5 German shepherds and 1 mixed-breed dog.

Mean age at the time of MRI was 53.77 ± 29.18 mo standard deviation (SD) (range: 14 to 120 mo). Mean age at the time of MRI for giant breed dogs was 47 ± 24.31 mo (range: 14 to 96 mo), and was significantly different from that of large breed dogs, which was 76.33 ± 34.88 mo (range: 20 to 120 mo) (P = 0.0276). Duration of clinical neurological signs varied greatly, with a mean of 13.09 ± 23.82 mo (range: 3 d to 8 y).

The most commonly seen Modified Frankel Score was 3a (ambulatory tetraparesis and ataxia) in 13 dogs followed by 3b (ambulatory paraparesis with pelvic limb ataxia) in 7 dogs. Four dogs were classified as grade 4 (spinal hyperesthesia only) and 2 dogs as grade 2 (nonambulatory tetraparesis).

A total of 182 IV spaces were assessed. Spinal cord compression was identified in 67 of them (36.81%) and all 26 dogs had at least 1 compressed C2-T2 space. There were 3 compressed sites in each of 13 of the 26 dogs. Eight dogs had 2 compressed sites each while 3 had only 1 compressed site each. One dog had 4 compressed sites while another had 5. Of the 67 compressed spaces, 54 were from giant breed dogs and 13 from large breed dogs. The median numbers of compressed sites in these groups were 3 and 2.5, respectively. The highest frequency of compression was associated with C6-C7 (22 of 67 compressions), followed closely by C5-C6 (20 compressions). Of the 182 IV spaces analyzed, only T1-T2 showed no compression in all dogs.

The most common type of compression in both giant and large breed groups was bilateral (including lateral, dorsolateral, and midline dorsal compression types), occurring in 33 of the 67 compressed IV spaces (49.25%) (Figure 3). Eleven sites (16.42%) showed unilateral compression (8 left, 3 right) and were all seen in giant breed dogs, while 10 sites (14.93%) showed only ventral compression (9 in giant breeds and 1 in a large breed dog) and 13 sites (19.40%) showed concurrent bilateral and ventral compression, 10 of which were in giant breeds and 3 in large breed dogs (Figure 3). Lateral and dorsolateral compressions were related to proliferation of articular processes in most cases, although they were associated with synovial cysts in 5 spaces in 4 dogs. Dorsal midline compression was only seen in 2 sites, in 2 dogs, where it was suspected to be secondary to hypertrophy of the interarcuate ligament. Ventral compression was associated with intervertebral disc herniation (17 sites in 11 dogs), synovial cysts (2 sites in 2 dogs), suspected hypertrophy of the dorsal longitudinal ligament (3 sites in 3 dogs), or dorsomedial hypertrophy of the ventral aspect of the articular facets (1 site in 1 dog).

Degree of compression ranged from 2.70% to 43.90% with a mean of 17.31 ± 11.29%. No significant difference was found between compression types. The mean % compressions at C5-C6 and C6-C7 were not statistically different from one another (P = 0.99) but the mean % compressions at these locations were significantly higher than at all other sites ($P < 0.05$), except C4-C5 (P = 0.27; P = 0.12, respectively) (Table 2).

All dogs had degenerative changes at the articular processes and/or the IV discs in at least 6 of the 7 IV spaces analyzed, with only 4 normal sites seen, of the 182 analyzed. Synovial fluid signal loss and articular process surface sclerosis were seen in all dogs and were the 2 most commonly seen degenerative changes, occurring in 91.76% of IV spaces (167/182) and 91.2% of IV spaces (166/182), respectively. Synovial fluid was graded 1 (reduced) in 79.6% of IV spaces (133/167) while articular surface was graded 2 (irregular sclerosis) in 62.05% (103/166). Differences in scores of articular surface quality were not significant between sites; however, synovial fluid scores at T1-T2 showed more statistically significant losses of synovial fluid than at C2-C3 (P = 0.009). Varying degrees of dorsal hypertrophy (in 26 dogs) were seen in 43.96% (80/182) of articular processes joints while lateral hypertrophy (in 14 dogs) was seen in only 9.34% (17/182). C6-C7 and C7-T1 were noted to have significantly lower levels of dorsal hypertrophy than C2-C3 (P = 0.039; P = 0.018 respectively) and C4-C5 (P = 0.007; P = 0.003, respectively).

Foraminal stenosis occurred in 22 IV spaces (12 dogs) as a result of synovial cysts as well as medial and ventral proliferation of the articular facets. Of these, 45.45% (10/22) had grade 1 (mild) stenosis, 36.36% (8/22) had grade 3 (severe) stenosis, and the remaining 4 sites showed grade 2 (moderate) stenosis.

Intramedullary changes were seen in 11 IV spaces (7 dogs), while synovial cysts were present at 7 IV spaces (6 dogs). Synovial cysts were also seen at 7 locations between IV disc spaces (5 dogs). However, only 2 of these were extensions of a synovial cyst seen within the intervertebral joint space. Attenuation of the CSF and epidural fat signals was noted in 32.42% (59/182) of IV spaces.

Intervertebral disc degeneration occurred in 37 spaces (19 dogs); 89.9% (33/37) of degenerated discs were partially degenerated (grade 1) and only 4 discs were completely absent (grade 2). Disc herniations were identified at 26 of the 182 sites (15 dogs).

Table 2. Means (± standard deviation) for degree of compression per intervertebral space

	C2-C3	C3-C4	C4-C5	C5-C6	C6-C7	C7-T1	T1-T2
% Compression	3.09 (7.92)	3.42 (8.59)	7.91 (9.93)	14.19 (12.02)	15.73 (14.29)	0.25 (0.88)	0.00 (0.00)

Dogs with herniated discs had a mean age of 56.73 ± 29.97 mo (range: 20 to 120 mo) while dogs with no herniated discs had a mean age of 49.72 ± 28.98 mo (range: 14 to 96 mo). Most herniations were mild (grade 1), 2 were moderate, and none severe. C6-C7 had significantly more disc herniation than all sites ($P < 0.05$) except C5-6, which was similar ($P = 0.370$). C6-C7 also had significantly more disc degeneration than C2-3 ($P = 0.025$), C3-4 ($P = 0.020$), and C4-5 ($P = 0.008$).

There were no significant differences in scores of other degenerative changes (at articular processes or IV discs) between IV levels, and no significant correlations between degenerative changes.

Interestingly, bilateral compression placed IV spaces at a 17.54 times significantly higher risk ($P = 0.0002$) of developing intramedullary changes than did other compression types. Bilateral compression with a ventral component put IV spaces at a significantly high risk for developing synovial cysts (40 times greater than no compression; $P = 0.0017$).

No statistically significant correlations were found between MFS and age, duration of clinical signs, total number of compressions, total sum of compressions, synovial fluid signal, articular surface quality, foraminal stenosis compression or degree of compression, with the exception of C4-C5, where the MFS was negatively correlated with type of compression ($r^2 = 0.17$; $P = 0.0361$) and degree of compression ($r^2 = 0.18$; $P = 0.0319$).

Discussion

In the veterinary literature, osseous and disc-associated forms of CSM have often been discussed and studied together, thus failing to make a clear distinction between data obtained from both forms (1). However, pathophysiology, treatment, and prognosis vary between the 2 forms. Our study shows differences in patient age at the time of imaging, higher in large breeds (76.33 ± 34.48 mo) compared with giant breeds (47 ± 24.31 mo). This is consistent with data previously published for giant dogs (3,4,11). This age difference between breeds of dogs could be the result of different underlying causes for the same OA-CSM condition. The earlier onset shown by giant dogs could result from underlying congenital or developmental abnormalities associated with breed size, while age-related factors, as degenerative joint disease, are more relevant in developing OA-CSM later in life in large breed dogs. Duration of clinical signs showed too much variation for conclusions to be drawn. It was considered unreliable as owners' sense of urgency in presenting their pet, or their ability to arrange a visit to the teaching hospital was highly variable.

The highest frequency of compression was seen at C6-C7 and C5-C6, and these sites also were noted to have the worst compressions, similar to prior findings (2,11). T1-T2 consistently showed no compression in all 26 dogs studied, in contrast to a previous study in which 15% of giant breed dogs had compressions in T1-T2 (11). T1-T2 also showed more statistically significant loss of synovial fluid than did C2-3. This could be due to the smaller size of the T1-T2 facets, which make it difficult to identify synovial fluid on MRI.

As in other studies, giant breeds tended to have multiple compressions more often than large breed dogs, mainly bilateral in nature (2,3,11). The degree of compression did not vary significantly between compression types, meaning that the type of compression should not have an impact on the clinical signs directly related to the spinal cord compression. However, bilateral compression on its own was found to place that cervical site at a higher risk of presenting intramedullary signal changes. Spinal cord parenchyma hyperintensities in T2WI have been shown to help localize the most severely affected sites and seem to be associated with severity of clinical signs in Doberman pinscher dogs with CSM (12,13). Hyperintense T2WI lesions in humans with CSM are associated with edema, gliosis, demyelination, and Wallerian degeneration, even myelomalacia and spongiform changes when coupled with a T1WI hypointense signal and are associated with a poor prognosis (14,15).

Distribution of degenerative changes mostly matched those described previously (3,11). Loss of synovial fluid and articular surface sclerosis were the 2 most common degenerative changes seen on MRI, and synovial cysts were seen both within and outside the IV space, as seen in previous studies (2,3,11,16–18). On the other hand, compared to published data, we found a lower incidence of dorsal and lateral hypertrophy, foraminal stenosis, and intramedullary changes (2,3,11). This is likely due to differences in breeds assessed by the different studies, as some included a wider variety of large breed dogs than this study, while others focused on a single giant breed (2,3,11). Further, minor differences in the definition of dorsal and lateral hypertrophy and how they were assessed also contribute to this difference (3).

Disc degeneration was seen in fewer IV spaces (20.33%) compared with other studies. However, it was spread amongst 73.08% of the dogs studied here, but amongst only 28.57% of the dogs in 2 other studies (2,3). This might be due to the varieties of breeds included, as Great Danes were overrepresented in those studies (2,3). Disc herniations were seen in a relatively high number of dogs, and these dogs tended to be older. Disc herniations are typically associated with DA-CSM, and this overlap between OA-CSM and DA-CSM has been noted previously (11).

While correlations between lateral compression and foraminal stenosis with synovial fluid and articular surface quality have been reported, that was not the case in our study (3). However, sites with bilateral and ventral compressions were more likely to present disc degeneration and herniation, even more than

sites with ventral compression alone, indicating a potential correlation between intervertebral disc and osteoarthritic changes in dogs suffering OA-CSM. This could suggest a different pathophysiology for disc herniation between OA-CSM and DA-CSM. Bilateral compression with a ventral component was also associated with the presence of synovial cysts since those tended to cause further ventrolateral compression.

A spinal functional score system based on the Frankel scale was specifically adapted for the purpose of the study to discriminate dogs with CSM showing severe pelvic limb deficits with almost normal thoracic limbs despite presenting a cervical lesion. There were no significant associations between MRI findings and clinical signs, probably since half of the dogs had identical scores (3a; ambulatory tetraparesis and ataxia), representing an important limitation of the study. The Frankel score and its several modified versions are the most popular functional scales used in veterinary medicine (4,8,19). Despite this and the modification intended for CSM, the scale was still of limited value and was not a good predictor of severity of the imaging changes. Other functional score systems, like the Texas Spinal Cord Injury Score, should be used or adapted to further discriminate dogs with different degrees of ambulatory tetraparesis before concluding that there is no link between the severity of MRI findings and clinical signs (10).

We identified 26 dogs in this study; however, only 6 were large breed dogs, reflecting the higher OA-CSM incidence in giant dogs. This small sample size limited our ability to compare MRI findings between groups. A larger study is needed to further characterize this disease. Further studies focusing on associations between clinical signs, MRI findings, and histopathology findings may advance our understanding of pathophysiology and prognostic factors.

To summarize, most of our findings on OA-CSM corroborated results of previous studies and interesting associations were noted between certain compression types and degenerative changes. Our findings also emphasize the difference in age of onset of OA-CSM between giant and large breed dogs, suggesting that we consider a potential different underlying pathophysiology in those breeds.

Acknowledgments

This project was partially supported by the University of Guelph Undergraduate Research Assistantship program. The authors thank Alice Daw for her assistance with this project, and Dr. Stephanie Nykamp for her help with the preparation of the MRI images. CVJ

References

1. da Costa RC. Cervical spondylomyelopathy (wobbler syndrome) in dogs. Vet Clin North Am Small Anim Pract 2010;40:881–913.
2. Lipsitz D, Levitski R, Chauvet AE, Berry WL. Magnetic resonance imaging features of cervical stenotic myelopathy in 21 dogs. Vet Radiol Ultrasound 2001;42:20–27.
3. Gutierrez-Quintana R, Penderis J. MRI features of cervical articular process degenerative joint disease in Great Dane dogs with cervical spondylomyelopathy. Vet Radiol Ultrasound 2012;53:304–311.
4. Eagleson JS, Diaz J, Platt SR, et al. Cervical vertebral malformation-malarticulation syndrome in the Bernese Mountain dog: Clinical and magnetic resonance imaging features. J Small Anim Pract 2009;50:186–193.
5. Ryan T, Platt S, Llabres-Diaz F, McConnell J, Adams V. Detection of spinal cord compression in dogs with cervical intervertebral disc disease by magnetic resonance imaging. Vet Rec 2008;163:11–15.
6. da Costa RC, Samii VF. Advanced imaging of the spine in small animals. Vet Clin North Am Small Anim Pract 2010;40:765–790.
7. Frankel H, Hancock D, Hyslop G, et al. The value of postural reduction in the initial management of closed injuries of the spine with paraplegia and tetraplegia. Paraplegia 1969;7:179–192.
8. Budke C, Levine J, Kerwin S, Levine G, Hettlich B, Slater M. Evaluation of a questionnaire for obtaining owner-perceived, weighted quality-of-life assessments for dogs with spinal cord injuries. J Am Vet Med Assoc 2008;233:925–930.
9. Park EH, White GA, Tieber LM. Mechanisms of injury and emergency care of acute spinal cord injury in dogs and cats. J Vet Emerg Crit Care 2012;22:160–178.
10. Levine GJ, Levine JM, Budke CM, et al. Description and repeatability of a newly developed spinal cord injury scale for dogs. Prev Vet Med 2009;89:121–127.
11. da Costa RC, Echandi RL, Beauchamp D. Computed tomography myelographic findings in dogs with cervical spondylomyelopathy. Vet Radiol Ultrasound 2012;53:64–70.
12. da Costa RC, Parent JM. Magnetic resonance imaging findings in 60 dogs with cervical spondylomyelopathy. Abstract #185. ACVIM Forum, Montreal, Quebec, June 3–6, 2009. J Vet Intern Med 2009;23:740.
13. da Costa RC, Parent J, Dobson H, Holmberg D, Partlow G. Comparison of magnetic resonance imaging and myelography in 18 Doberman Pinscher dogs with cervical spondylomyelopathy. Vet Radiol Ultrasound 2006;47:523–531.
14. Ohshio I, Hatayama A, Kaneda K, Takahara M, Nagashima K. Correlation between histopathologic features and magnetic resonace images of spinal cord lesions. Spine 1993;18:1140–1149.
15. Yagi M, Ninomiya K, Kihara M, Horiuchi Y. Long-term surgical outcome and risk factors in patients with cervical myelopathy and a change in signal intensity of intramedullary spinal cord on magnetic resonance imaging. J Neurosurg Spine 2010;12:59–65.
16. Trotter EJ, deLahunta A, Geary JC, Brasmer TH. Caudal cervical vertebral malformation-malarticulation in Great Danes and Doberman Pinschers. J Am Vet Med Assoc 1976;168:917–930.
17. Wright F, Rest JR, Palmer AC. Ataxia of the Great Dane caused by stenosis of the cervical vertebral canal: Comparison with similar conditions in the Basset Hound, Doberman Pinscher, Ridgeback and the Thoroughbred horse. Vet Rec 1973;1:1–6.
18. Levitski RE, Chauvet AE, Lipsitz D. Cervical myelopathy associated with extradural synovial cysts in 4 dogs. J Vet Intern Med 1999;13:181–186.
19. De Decker S, Gielen IM, Duchateau L, et al. Evolution of clinical signs and predictors of outcome after conservative medical treatment for disk-associated cervical spondylomyelopathy in dogs. J Am Vet Med Assoc 2012;240:848–857.