

UCSF

UC San Francisco Previously Published Works

Title

Correction: Osimertinib-induced biventricular cardiomyopathy with abnormal cardiac MRI findings: a case report

Permalink

<https://escholarship.org/uc/item/7qv0n9v3>

Journal

Cardio-Oncology, 9(1)

ISSN

2057-3804

Authors

Patel, Karishma

Hsu, Kristie Y

Lou, Kevin

et al.

Publication Date

2023

DOI

10.1186/s40959-023-00195-w

Peer reviewed

CORRECTION

Open Access



Correction: Osimertinib-induced biventricular cardiomyopathy with abnormal cardiac MRI findings: a case report

Karishma Patel¹, Kristie Y. Hsu¹, Kevin Lou¹, Krishan Soni^{1,3}, Yoo Jin Lee², Claire K. Mulvey^{1,4} and Alan H. Baik^{1,3,5*}

Correction: *Cardio-Oncol* 9, 38 (2023)

<https://doi.org/10.1186/s40959-023-00190-1>

Following publication of the original article [1], the authors identified an error in Fig. 1, in which Fig. 1A and B were reversed. The correct figure is given below.

The original article [1] has been updated.

Published online: 29 November 2023

Reference

1. Patel K, Hsu KY, Lou K, et al. Osimertinib-induced biventricular cardiomyopathy with abnormal cardiac MRI findings: a case report. *Cardio-Oncology*. 2023;9:38. <https://doi.org/10.1186/s40959-023-00190-1>.

The original article can be found online at <https://doi.org/10.1186/s40959-023-00190-1>.

*Correspondence:

Alan H. Baik

alan.baik@ucsf.edu

¹ Department of Medicine, University of California, San Francisco, CA, USA

² Department of Radiology, University of California, San Francisco, CA, USA

³ Division of Cardiology, University of California, San Francisco, CA, USA

⁴ Division of Oncology, University of California, San Francisco, CA, USA

⁵ Department of Medicine, Division of Cardiology, Section of Cardio-Oncology and Immunology, University of California, San Francisco, CA, USA



© The Author(s) 2023. **Open Access** This article is licensed under a Creative Commons Attribution 4.0 International License, which permits use, sharing, adaptation, distribution and reproduction in any medium or format, as long as you give appropriate credit to the original author(s) and the source, provide a link to the Creative Commons licence, and indicate if changes were made. The images or other third party material in this article are included in the article's Creative Commons licence, unless indicated otherwise in a credit line to the material. If material is not included in the article's Creative Commons licence and your intended use is not permitted by statutory regulation or exceeds the permitted use, you will need to obtain permission directly from the copyright holder. To view a copy of this licence, visit <http://creativecommons.org/licenses/by/4.0/>. The Creative Commons Public Domain Dedication waiver (<http://creativecommons.org/publicdomain/zero/1.0/>) applies to the data made available in this article, unless otherwise stated in a credit line to the data.

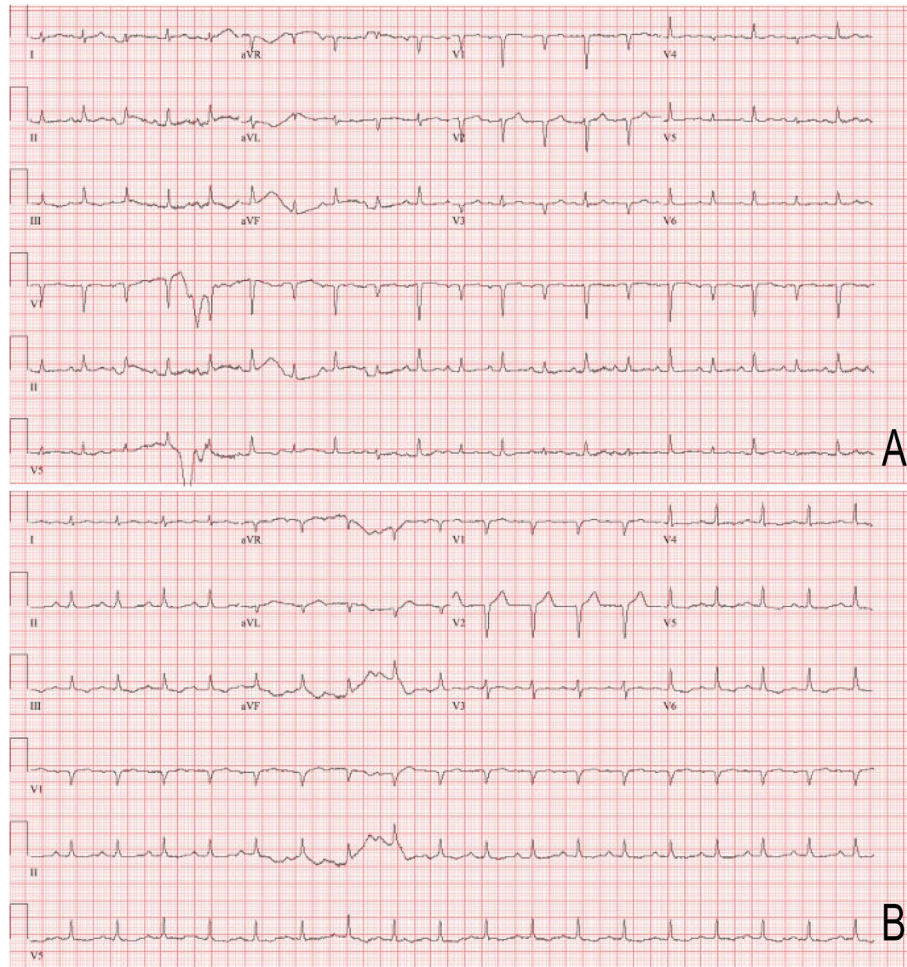


Fig. 1 Electrocardiogram (ECG) prior to **(A)** and after **(B)** pericardiocentesis. **(A)** Initial presenting ECG with electrical alternans, in which the direction of electrical activity flips beat-to-beat in lead V3. **(B)** ECG after pericardiocentesis with resolution of electrical alternans