

# UCLA

## UCLA Previously Published Works

### Title

Left Ventricular Reconstruction for Postinfarction Left Ventricular Aneurysm: Review of Surgical Techniques

### Permalink

<https://escholarship.org/uc/item/7s12j8jg>

### Journal

Texas Heart Institute Journal, 44(5)

### ISSN

0730-2347

### Authors

Ruzza, Andrea  
Czer, Lawrence SC  
Arabia, Francisco  
et al.

### Publication Date

2017-10-01

### DOI

10.14503/thij-16-6068

Peer reviewed

# Left Ventricular Reconstruction for Postinfarction Left Ventricular Aneurysm:

## Review of Surgical Techniques

**Andrea Ruzza, MD, PhD**  
**Lawrence S.C. Czer, MD**  
**Francisco Arabia, MD**  
**Roberta Vespignani, MD**  
**Fardad Esmailian, MD**  
**Wen Cheng, MD**  
**Michele A. De Robertis, RN**  
**Alfredo Trento, MD**

*Different surgical techniques, each with its own advantages and disadvantages, have been used to reverse adverse left ventricular remodeling due to postinfarction left ventricular aneurysm. The most appropriate surgical technique depends on the location and size of the aneurysm and the scarred tissue, the patient's preoperative characteristics, and surgeon preference. This review covers the reconstructive surgical techniques for postinfarction left ventricular aneurysm. (Tex Heart Inst J 2017;44(5):326-35)*

**Key words:** Cardiac surgical procedures/methods; heart aneurysm/diagnosis/etiology/pathology/surgery; heart ventricles/pathology/surgery; myocardial infarction/complications/physiopathology; risk factors; suture techniques; ventricular dysfunction, left/etiology; ventricular function, left/drug effects/physiology

**From:** Divisions of Cardiothoracic Surgery (Drs. Arabia, Cheng, Esmailian, Ruzza, Trento, and Vespignani, and Mr. De Robertis) and Cardiology (Dr. Czer), Cedars-Sinai Medical Center, Los Angeles, California 90048

**Address for reprints:** Lawrence S.C. Czer, MD, Heart Transplant Program, Cedars-Sinai Heart Institute, 127 S. San Vicente Blvd., Ste. A3100, Los Angeles, CA 90048

**E-mail:** lawrence.czer@cshs.org

© 2017 by the Texas Heart<sup>®</sup> Institute, Houston

**H**eat failure secondary to ischemic heart disease with left ventricular aneurysm (LVA) can be treated surgically. However, these operative procedures have generally been considered high risk, and they have been associated with high perioperative morbidity and mortality rates. More recently, experience has shown that surgical reversal of adverse ventricular remodeling resulting from LVA can improve cardiac function, thus improving symptoms and life expectancy.<sup>1-10</sup> The purpose of this article is to review the surgical techniques for reversal of adverse left ventricular (LV) remodeling from LVA after myocardial infarction (MI).

### Literature Search

We searched the PubMed database to identify all studies reporting surgical techniques for LV remodeling for postinfarction LVA. Search terms entered were surgical ventricular reconstruction; partial left ventriculectomy; endoventricular circular patch plasty; left ventricle surgery; left ventricle aneurysm; left ventricle aneurysm surgery; left ventricle aneurysm resection; left ventricle remodeling post-myocardial infarction; and left ventricle surgery post-myocardial infarction.

An LVA or “true” aneurysm is most simply defined as an area of distinct akinesia or dyskinesia of the LV wall that is associated with a reduced LV ejection fraction.<sup>2</sup> Favoloro and colleagues<sup>3</sup> described LVA as “a full-thickness scar-tissue replacement of the left ventricular wall, usually containing thrombus and attached to the pericardial sac by adhesions.” Functionally, an LVA is a distinct area of abnormal diastolic relaxation with paradoxical systolic dyskinesis.<sup>4</sup>

### Clinical Aspects

**Causes.** Left ventricular aneurysm has been recognized to be a consequence of coronary heart disease since 1881, and this finding has also been confirmed in autopsy series.<sup>5</sup> More than 95% of LVAs reported in the literature resulted from MI secondary to coronary artery disease; an LVA occurs in 10% to 35% of patients with MI and is more frequently found in those with acute anterior transmural MI.<sup>6</sup> Left ventricular aneurysms can also develop consequent to trauma,<sup>7</sup> Chagas disease,<sup>8</sup> and sarcoidosis,<sup>9</sup> or they can be secondary to a congenital abnormality.<sup>10</sup>

**Etiology.** Left ventricular aneurysms are classified as either true or false. A true LVA involves the entire LV wall thickness and protrudes. A false LVA follows rupture of the ventricular wall, is contained by the surrounding pericardium, and often occurs 5 to 10 days after left circumflex coronary artery occlusion. More specifically, a false LVA can result from rupture of the ventricular wall after mitral valve replacement with resection of the mitral valve apparatus, occlusion of the left circumflex coronary artery, or both.

*Pathophysiology.* The diameter of an LVA is typically from 1 to 8 cm. In 90% of cases, the LVA is located at the apex of the heart or in the anterior wall, and in 10%, it is in the posterior-inferior wall.<sup>11</sup> The pericardium generally adheres to the wall of the aneurysm.

In experimental studies of dogs with transmural MI but without collateral circulation,<sup>12</sup> the interruption of blood flow caused almost immediate cessation of contractile activity. Myocyte death started within 20 minutes. Within a few days, the endocardial surface of the developing LVA became smooth and thin, with fibrin deposition, thrombus formation, and loss of trabeculae in at least 50% of dogs. Inflammatory cells migrated into the infarct zone 2 to 3 days later and contributed to lysis of the necrotic myocytes approximately 5 to 10 days after the MI, at which point rupture of the myocardial wall occurred in some dogs. Left ventricular rupture was relatively uncommon after the aneurysmal ventricular wall was replaced with fibrous tissue.

Clinically, the effect of increased tension in the involved myocardial wall leads to the wall's progressive thinning and protrusion.<sup>13</sup> This phenomenon is explained by Laplace's law ( $\sigma = Pr / 2h$ ), which states that, at a constant ventricular pressure ( $P$ ), an increased radius ( $r$ ) of curvature and a decreased wall thickness ( $h$ ) of the affected portion of the heart contribute to increasing tension ( $\sigma$ ) of the myocardial muscle fibers and promote the deformation and expansion of the ischemic ventricular wall. Functionally, such alteration involves loss of the ventricle's original shape, causing volume overload in end-diastole.<sup>14</sup> Volume overload leads to compensatory hypertrophy in the adjacent viable myocardium, thus increasing oxygen consumption. Approximately 2 to 4 weeks after MI, vascularized granulation tissue appears, which is then replaced 6 to 8 weeks later by fibrous tissue, resulting in the formation of a chronic aneurysm.

Transmural necrosis, which leads to the formation of an LVA, involves 2 main phases: early expansion and subsequent remodeling. The early expansion occurs in the area of the MI, whereas the remodeling phase affects the muscle fiber cells, leading to fibrosis and changes in the geometry of the ventricular cavity.<sup>15</sup> These changes result in progressive ventricular dilation, increased wall tension, and altered systolic function, leading to irreversible contractile dysfunction.

*Role of Collateral Flow.* Left ventricular aneurysms occur after MI when the left anterior descending coronary artery (LAD) becomes completely occluded, and collateral circulation within the ischemic myocardium is poor. Collateral vessels, thin-walled structures with a diameter of 20 to 200  $\mu$ ,<sup>16</sup> are usually closed and non-functional in nonischemic myocardium because of a low or absent pressure gradient. After coronary occlusion, however, the distal pressure drops suddenly, the pressure gradient increases, and the collateral vessels

open, resulting in increased blood flow. Rarely, LVAs occur in the presence of multivessel disease and extensive collateral circulation.<sup>17</sup>

*Natural History.* Grondin and colleagues<sup>18</sup> studied the natural history of LVA in 40 cases of postinfarction LVA not treated surgically. These patients were divided into 2 groups according to the presence or absence of significant symptoms. In asymptomatic patients, the survival rate at 10 years was 90%, but it was only 46.3% in those who were symptomatic at the time of initial diagnosis. Deaths were due to arrhythmias or congestive heart failure. Nonfatal sequelae included arrhythmias in 34% of patients, thromboembolic events in 29%, heart failure in 29%, and recurrent MI in 22.5%.

*Clinical Presentation.* Angina, the most prevalent symptom of LVA, has been attributed to volume overload in the LV and a resultant increase in oxygen consumption.<sup>19</sup> Any functional mitral regurgitation can exacerbate ventricular overload, progressively leading to the onset of heart failure. Dyspnea, the second most frequent symptom, occurs because of a combination of systolic and diastolic dysfunction. In more than one third of patients, atrial or ventricular arrhythmias cause palpitations, syncope, or sudden death, or they exacerbate angina and dyspnea.<sup>19</sup>

*Diagnosis.* During the acute phase of MI, electrocardiograms frequently show Q waves and persistent ST-segment elevation in the anterior leads; these might persist for days or weeks. Subsequent chest radiographs may show ventricular enlargement, a characteristic bulge of the LV, and cardiomegaly.

In a patient with LVA, the left ventriculogram reveals a large and distinct area of dyskinesia, generally in the anterior, apical, and septal walls.<sup>6</sup> Two-dimensional echocardiography, which is sensitive and specific in the diagnosis of LVA, can also reveal the presence of mural thrombi and mitral valve regurgitation. Computed tomography and magnetic resonance imaging can also be used to identify aneurysms.<sup>20</sup>

*Surgical Indications.* The presence of LVA alone is not a surgical indication. Surgery is indicated when concomitant, persistent angina, refractory heart failure, thromboembolism, or life-threatening tachyarrhythmias occur.<sup>18</sup> Myocardial revascularization is typically performed at the time of aneurysmectomy. The in-hospital mortality rates for patients undergoing these procedures range from 2% to 19%, with a mean of approximately 10%.<sup>21</sup> Risk factors for early death include severe LV failure, MI, and intractable arrhythmias. Risk factors for late death include incomplete revascularization and reduced systolic function of the basal segments of the LV and the interventricular septum. After 5 years, the survival rate is approximately 69% for patients undergoing aneurysmectomy and either revascularization or mitral valve replacement, compared with 57% for those undergoing aneurysmectomy alone.<sup>21</sup>

## Surgical Techniques

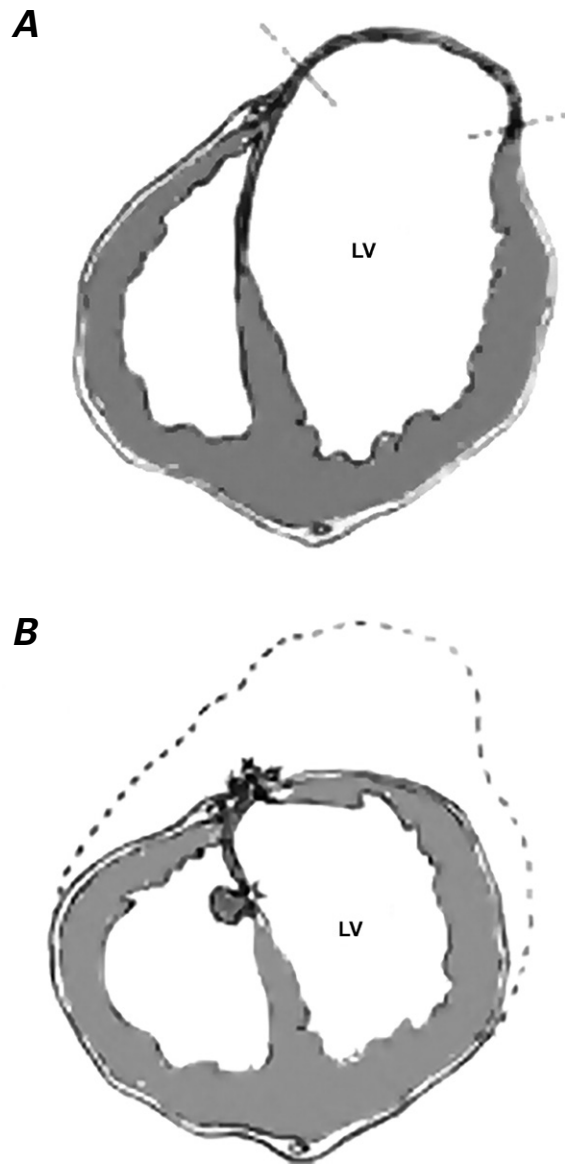
The first successful surgical treatment of an LVA, by Wieting in 1912, involved the ligation of a congenital form of LVA.<sup>22</sup> In 1944, Beck described using the fascia lata to reinforce the LVA.<sup>23</sup> The first angiographic description of LVA was published in 1951.<sup>24</sup> In 1955, Likoff and Bailey<sup>25</sup> successfully resected an LVA via thoracotomy, using a tangential clamp without cardiopulmonary bypass (CPB).

**Plication.** External plication without opening the LVA is a relatively simple technique that is currently reserved primarily for patients who have aneurysms of smaller dimensions that do not contain thrombi and for those who do not have severe LV dysfunction or high end-diastolic pressure. The repair involves a double-layered suture from one side of the aneurysm to the other; a strip of Teflon is used on both sides and is oriented to reconstruct a normal ventricular shape. Usually, the area of repair does not include the entirety of the aneurysmal tissue.<sup>26</sup>

**Cooley Technique.** Contemporary treatment of LVA began in 1958, when Cooley and associates<sup>27</sup> performed a “linear” or “sandwich” repair of a larger LVA during CPB. For the next 30 years, the technique changed very little from the one Cooley described. Specifically, after longitudinal incision of the LVA and removal of any thrombi, the wall of the aneurysm was resected (usually parallel to the LAD or posterior descending artery, depending on aneurysm location).<sup>27</sup> A border area <2 cm from the scar tissue was left to enable the reconstruction of normal LV geometry. Particular attention was paid not to resect too much of the aneurysmal wall, to avoid excessively reducing the size of the ventricular cavity. The resected area was closed vertically on either side, between 2 external strips of Teflon or pericardium: first, with a 2-layer horizontal mattress suture, and then with a 2-layer vertical running suture. A disadvantage of linear repair was that the lateral and medial (septal) LV walls were sutured together, eliminating the natural separation of a few centimeters and leaving an area of akinetic myocardium that contributed to continued LV dysfunction. The technique also failed to exclude an area of the involved septum (Fig. 1).<sup>26</sup>

Subsequently, Stoney (1973),<sup>28</sup> Daggett (1977),<sup>29</sup> Jatene (1985),<sup>30</sup> Dor (1989),<sup>31</sup> and Cooley (1989)<sup>32</sup> and their associates published papers describing techniques for reconstructing the geometry of the LV. These techniques demonstrated that restoring a more normal geometry led to improved function. In particular, the surgeons recognized that incorporating the interventricular septum into the repair led to a better geometric result with a more physiologic orientation.

**Stoney Technique.** Stoney and colleagues<sup>28</sup> showed that patients whose aneurysms were resected with the Cooley technique had incomplete reduction of the aneurysm, leaving an area of akinetic myocardium at the



**Fig. 1** Diagrams show the Cooley technique (“linear” or “sandwich” repair). **A**) The left ventricular (LV) cavity is reduced in size. **B**) The lateral and medial (septal) walls are sutured together at a point where they normally would be separated by several centimeters, resulting in nonanatomic geometry.

Reprinted with permission from Mukaddirov M, Demaria RG, Perrault LP, Frapier JM, Albat B. Reconstructive surgery of postinfarction left ventricular aneurysms: techniques and unsolved problems. *Eur J Cardiothorac Surg* 2008;34(2):256-61.<sup>26</sup>

level of the interventricular septum, resulting in functional and volumetric impairment of the LV. Therefore, Stoney introduced a new correction technique that involved the advancement and connection of the lateral myocardial wall with the border area between the viable tissue and the necrotic scar of the interventricular septum, but it omitted the revascularization of the affected area (Fig. 2).<sup>28</sup> This technique also excluded the possi-

bility of LAD revascularization because of its inclusion in the repair.

In 1980, Hutchins and Brawley<sup>33</sup> stressed that Stoney's method made it possible to increase the curvature of the free ventricular wall, reconstitute the original geometry, and improve cardiac function (Fig. 3).

In the mid to late 1980s, Jatene<sup>30</sup> and Dor<sup>31,34</sup> developed the concept of endocircular ventricular plasty, introducing, with slight variations, reconstruction of the ventricle with intracavitary exclusion of the ischemic area, as described below.

**Dor Technique.** After opening the aneurysm, the surgeon determines the extent of the endocardial scar and identifies the junction between the scar and the viable myocardium around the entire circumference of the aneurysm. The Dor technique—endoventricular circular

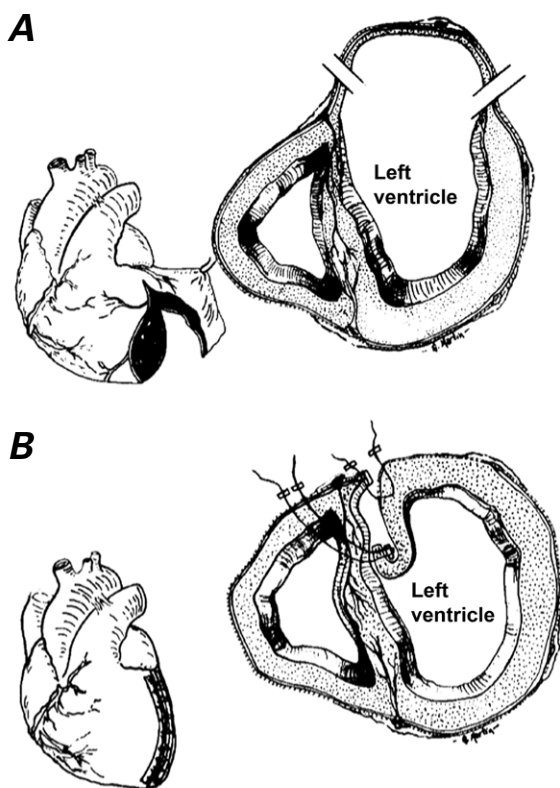
patch plasty—involves placing a continuous 2-0 suture at this junction, deeply enough in the endocardium to prevent tears when the suture is tightened. The degree of suture tension determines the extent of the remaining opening in the ventricle and the size of the endocardial patch to be used. The patch is generally 2 to 3 cm in diameter and can be made of Dacron or pericardium. After the patch has been sutured inside the LV cavity to close the endocardial opening, surgical adhesive glue is applied to reinforce the suture line.

The Dor technique has 4 advantages. First, it enables the akinetic segment of the interventricular septum to be excluded. Second, it produces a more physiologic geometric cavity. Third, it preserves the LAD for possible grafting. Fourth, it eliminates the need for external prosthetic materials, which can cause persistent pericardial adhesions (Fig. 4).<sup>34</sup> The exclusion of the ischemic interventricular septum and the reduction of ventricular volume enable a realignment of the myofiber cells of the remaining adjacent and viable remote myocardium.<sup>35</sup>

Initially, surgeons using the Dor technique did not consider it necessary to revascularize the ischemic area, but continued experience has shown that revascularizing the affected coronary artery may promote functional recovery of the spared septum and ventricular wall. In one study,<sup>6</sup> a disadvantage of the Dor technique, when buttressed with felt, was the late postoperative development of paradoxical movement.

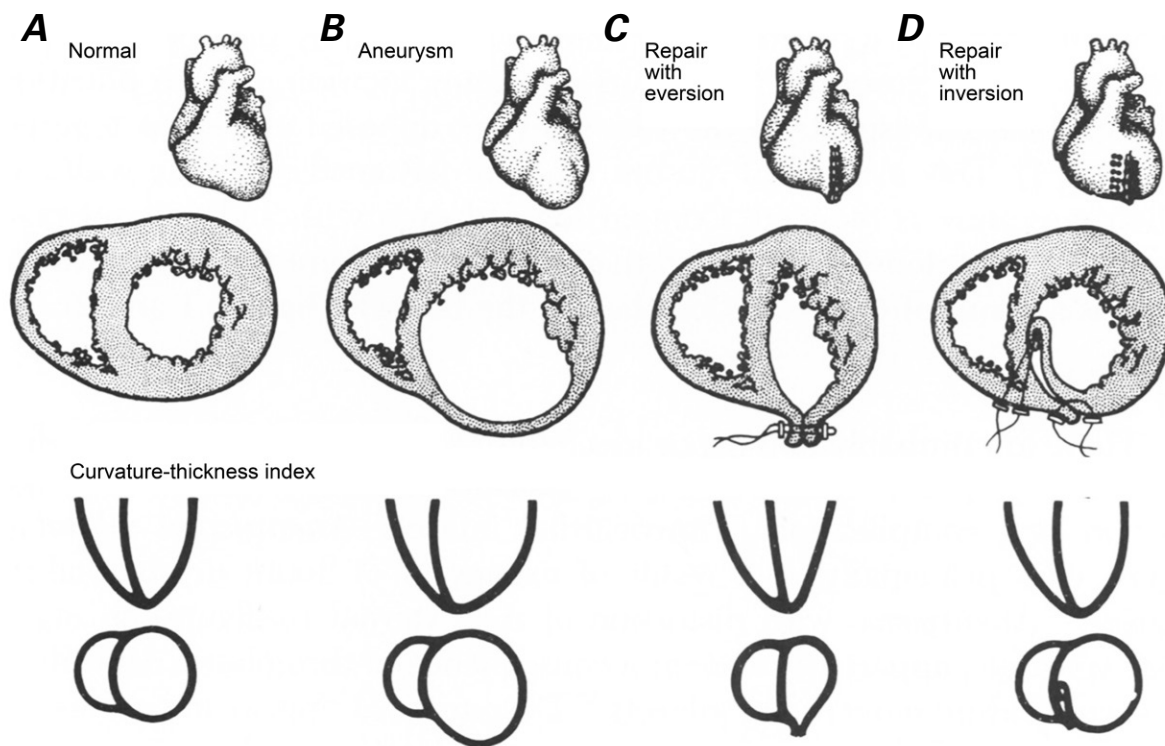
**Jatene Technique.** The Jatene technique involves opening the aneurysm, inspecting the internal cavity, and placing one or two purse-string sutures, mounted on pledgets, around the proximal portion of the aneurysm's ventricular septal aspect so that the size of the orifice can be reduced to that of the closure area. Septal plication is also performed to avoid septal dysfunction, and a ventricular Dacron patch is then stitched in the ventriculotomy orifice to stabilize the septum and restore the normal conical shape of the septum where it joins the ventricular wall. In this manner, the septum remains part of the LV wall.

The Dor technique differs from the Jatene technique in that the aneurysmal portion of the distal septum is excluded by placing an endocardial patch at the junction of the septal endocardial scar tissue and the normal septal endocardium.<sup>36</sup> The two techniques also differ in the positioning of the purse-string sutures relative to the septum. In the Jatene technique, the purse-string sutures are placed more proximally on the free wall of the LV and the septum, whereas in the Dor technique, they are placed a little more distally over the ventricular free wall and on the septum. Both use patches during final closure. Thus, the Jatene technique leaves the apical position of the ventricular cavity unchanged when compared to the septal position, whereas the Dor technique moves the apex of the ventricular cavity to a more lateral position in relation to the septum.<sup>36</sup>



**Fig. 2** Diagrams show the Stoney technique, an early attempt to increase the curvature of the left ventricle in an aneurysmal area. **A)** The lateral wall of the myocardium is brought toward the ventricular septum at the junction between viable muscle tissue and scar. The lateral edge of the myocardium is sutured to the interventricular septum, in a continuous fashion, in the border zone between the viable and scarred tissue. Then, polytetrafluoroethylene strips are used to reinforce the left ventricular margin, and stitches are brought outside through the septum to the anterior wall. **B)** The repair is completed by overlapping the lateral healthy myocardial wall of the left ventricle with the scar tissue.

Reprinted with permission from Stoney WS, Alford WC Jr, Burrus GR, Thomas CS Jr. Repair of anteroseptal ventricular aneurysm. *Ann Thorac Surg* 1973;15(4):394-404.<sup>28</sup>



**Fig. 3** Diagrams show a transverse section of the left ventricle and the curvature of the ventricular wall in **A)** a normal heart, **B)** an ischemic heart with an aneurysm, **C)** a heart with an aneurysm repaired by eversion, and **D)** a heart with an aneurysm repaired by inversion of a ventriculotomy. Whereas the eversion technique reduces the curvature of the wall, the inversion technique increases the curvature, thus promoting increased cardiac function.

Reprinted from Hutchins GM, Brawley RK. The influence of cardiac geometry on the results of ventricular aneurysm repair. *Am J Pathol* 1980;99(1):221-30,<sup>33</sup> with permission from Elsevier.

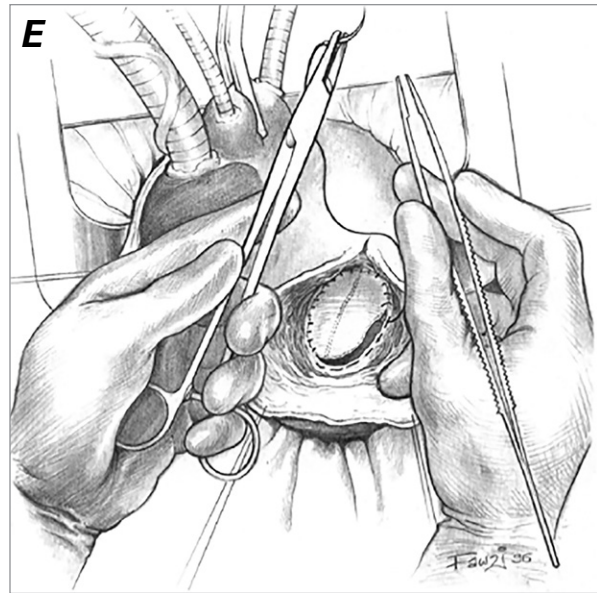
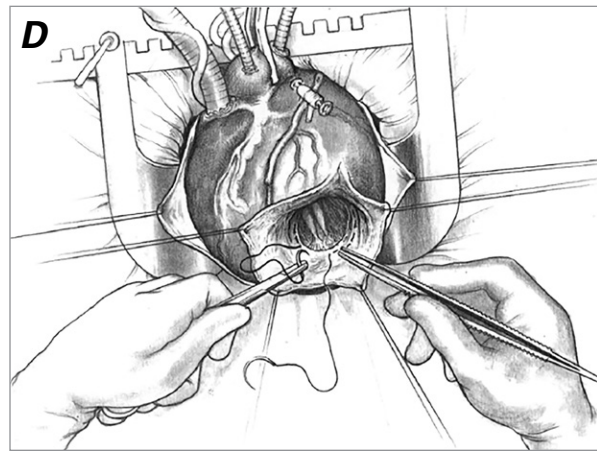
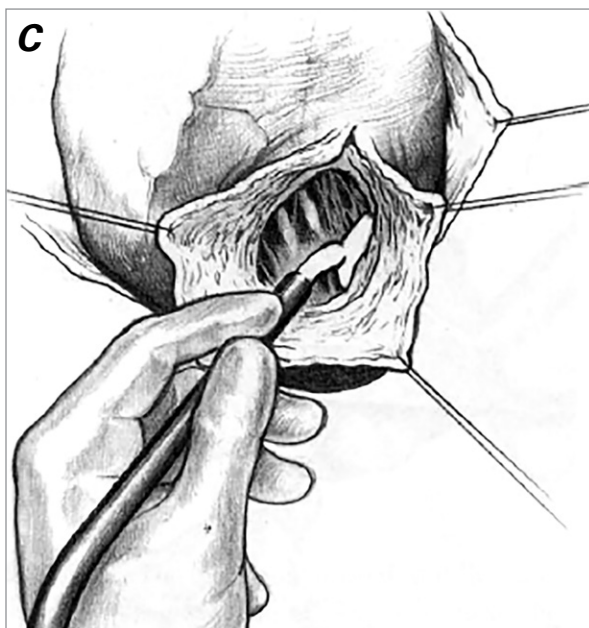
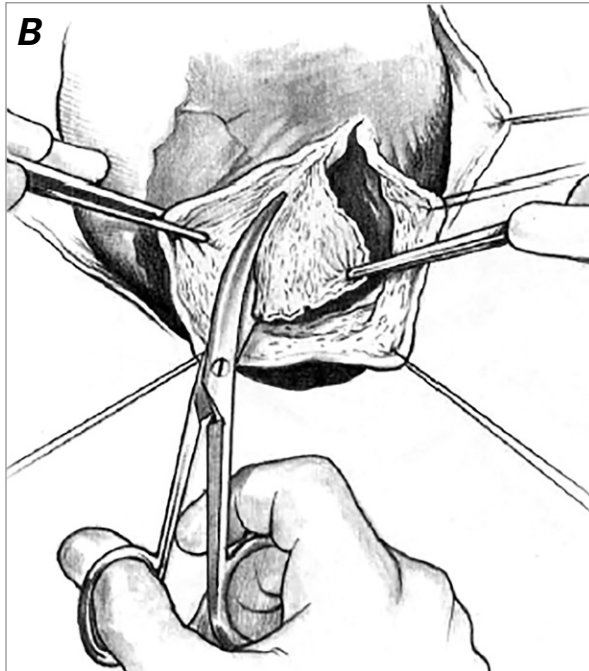
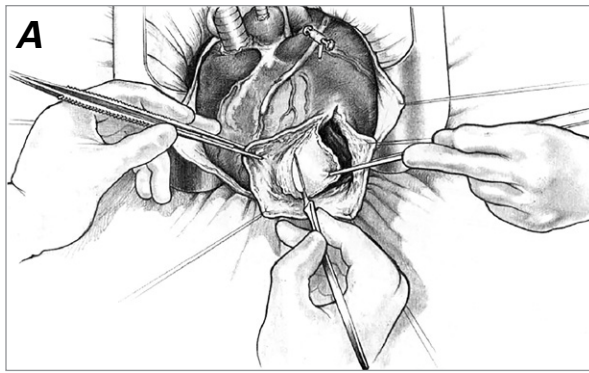
**McCarthy Technique.** In 1997, McCarthy and colleagues<sup>37,38</sup> described an endoventricular circular plasty technique that eliminated the patch. The McCarthy technique involves opening the LV apex at least 1.5 to 2 cm from the LAD. Visual inspection and palpation then enable identification of the border between the scar tissue and the contractile myocardium. This border is most easily recognized when the inspection is performed on a beating heart. If the surgeon determines that endoventricular circular plasty can be done without aortic clamping, myocardial ischemia can be avoided.

A 2-0 polypropylene, purse-string suture is first placed around the entire base of the aneurysm, deep into the scarred tissue, in order to apply considerable tension to the scar area. The suture is then tied from the inside on a Teflon pledget in an attempt to restore the geometry of the ventricular cavity. The degree of tension with which the suture is tightened determines the size of the remaining opening of the ventricle. If the opening is wider than 3 cm, a second purse-string suture is placed 4 mm distal to (above) the first one. When the ventricular opening remains greater than 3 cm, a patch is required, and closure is achieved with

the Dor technique. Otherwise, the ventricular free wall is successively approximated, and 2 strips of Teflon are secured on either side of the opening with interrupted mattress sutures. Finally, the closure is reinforced with 3-0 polypropylene continuous suture (Fig. 5).<sup>37,38</sup> This procedure completely excludes the ischemic area and surrounds the LV chamber with viable LV muscle, except for a rim of scar at the repair site. Potential improvements to the technique include a less invasive LV remodeling technique that does not necessitate opening the LV or using CPB. In the future, a thoracoscopic approach might be adopted.

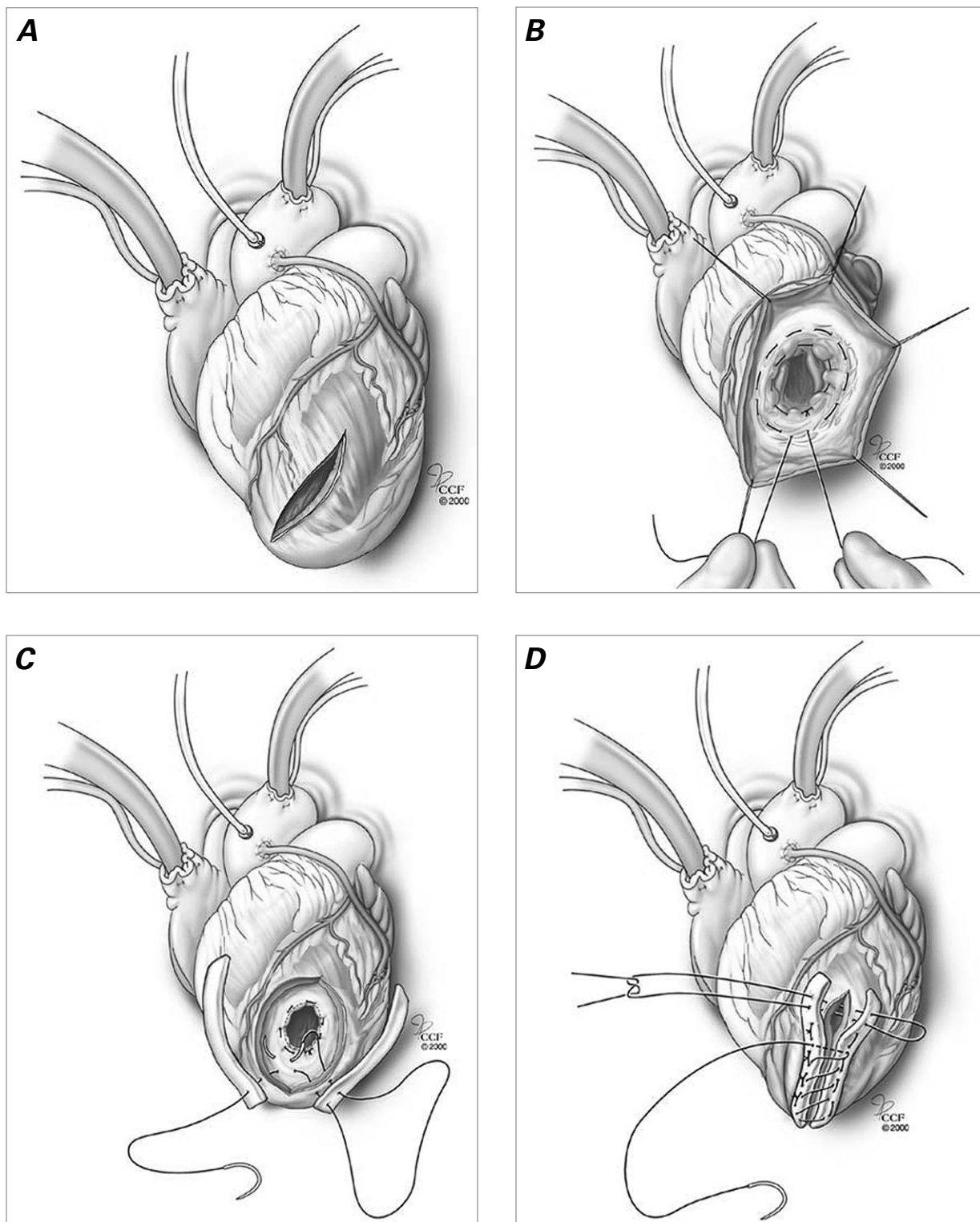
## Discussion

In patients with LVA, the primary cause of heart failure is ischemic heart disease, because it results in progressive ventricular dilation and irreversible myocardial dysfunction. In addition, mitral insufficiency can occur because of expansion of the LV or ischemia. Although it has been shown that mitral valve surgery and myocardial revascularization can lead to improvement of symptoms in patients with LVA, ventricular dilation



**Fig. 4** Diagrams show the Dor technique. **A)** After the aneurysm is opened, the endocardial scar tissue at the level of the interventricular septum is undermined and then **B)** resected. **C)** The junction between scar tissue and normal myocardium is cryoablated to prevent ventricular tachycardia. **D)** A purse-string suture is placed at the base of the aneurysm, at the junction between the endocardial scar and the normal myocardium. The suture, when tied with the proper tension, restores the normal orientation of the muscle fibers. **E)** An endocardial patch is anchored at the level of the circumferential suture to complete the closure of the ventricle.

Reprinted from Dor V. Surgical management of left ventricular aneurysms by the endoventricular circular patch plasty technique. *Oper Techn Cardiac Thorac Surg* 1997;2(2):139-50,<sup>34</sup> with permission from Elsevier.



**Fig. 5** Diagrams show the McCarthy technique. **A)** The aneurysm is opened 2 cm lateral to the left anterior descending coronary artery. **B)** A purse-string suture is placed into the scarred tissue, around the base of the aneurysm, then tied off. To ensure the resulting opening is <3 cm wide, a second purse-string suture is placed 4 mm above the first. **C)** The second purse-string suture has been tied and closure begun. **D)** To complete closure, interrupted mattress sutures are passed through Teflon felt strips on either side of the opening at the level of the purse-string suture, and the opening is reinforced with a continuous 3-0 polypropylene suture.

Reprinted with permission, Cleveland Clinic Center for Medical Art & Photography ©2000–2017. All rights reserved. Figures 6B and 6C, specifically, reprinted from Caldeira C, McCarthy PM. A simple method of left ventricular reconstruction without patch for ischemic cardiomyopathy. *Ann Thorac Surg* 2001;72(6):2148-9.<sup>38</sup>

and subsequent contractile dysfunction might be so advanced that surgical intervention to reconstruct the ventricular geometry is required.<sup>38-41</sup>

The concept of reducing the volume of the LV to improve global contractile function is certainly not new. As early as 1968, Favaloro and associates<sup>3</sup> had reported an improvement in contractile function after ventricular aneurysmectomy. However, for a time, intervention was considered possible only for patients with true aneurysms, in whom the linear resection technique described by Cooley and co-authors<sup>27</sup> was performed. Only in the 1980s was the concept of geometric reconstruction introduced through the work of Hutchins and Brawley<sup>33</sup> and the techniques developed by Daggett,<sup>29</sup> Dor,<sup>31</sup> and Jatene.<sup>30</sup> Currently, the remodeling of the aneurysmal LV is performed mostly with the surgical techniques developed by Dor and Jatene.

There are 4 key points regarding the current surgical techniques for correcting adverse remodeling of LVA after MI. First, classic ventricular aneurysms are much less prevalent now than in the past, probably as a result of the aggressive postischemic treatments, including percutaneous coronary interventions, as well as thrombolytic therapy, angiotensin-converting enzyme inhibitors,<sup>42-45</sup> and other medical therapies for advanced heart failure. Second, ventricular surgical reconstruction techniques have evolved from linear repair of the LV free wall to more complete exclusion of the ischemic area, including repair of the interventricular septum.<sup>6,36,46</sup> Third, surgical reconstruction of the dyskinetic aneurysmal area has been extended to include the akinetic, nonaneurysmal area surrounding the LV.<sup>47-49</sup> Fourth, avoiding use of an endocardial patch made with heterologous material is advisable because it may be counterproductive to reconstruct the LV by excluding an akinetic area and replacing it with an akinetic patch.

As noted above, Laplace's law explains the mechanism by which patients with an aneurysmal LV benefit from ventricular reconstruction. Reducing the radius of the LV cavity decreases stress on the LV wall, which benefits the patient in 3 ways<sup>15,50,51</sup>: it reduces the consumption of oxygen at the cardiac level; it increases myocardial efficiency, enabling the heart to do the same amount of work but with a lower expenditure of energy; and it improves myocyte orientation and, thus, contractile efficiency.

The benefits of these effects are evident not in scarred muscle tissue, but in the areas of the ventricle remote from the area of injury due to increased wall stress. This has been documented by Di Donato and co-authors,<sup>35</sup> who showed improved cardiac performance in areas distant from a reconstructed aneurysm. This is the fundamental reason why the reconstruction of a dilated ventricle can improve the function of the entire heart. Although a remodeling of the LV occurs after MI and often alters the geometry of the ventricle, reconstructive

surgery causes a beneficial LV "reshaping" that results in reverse remodeling of the entire LV—including the remote, nonischemic areas of the anterior wall—and re-creates the LV's conical shape.

Although the type of LV restoration used in a patient with LVA depends upon the surgeon's preferences, the patient's preoperative characteristics, and the surgical findings regarding the extent of the aneurysm and scarred area, the endoventricular circular plasty technique is generally the treatment of choice. The improvement in LV geometry and the decrease in the tension of the muscle fibers that this technique provides result in a decrease of oxygen consumption and an improvement in cardiac performance as indicated by increased LV ejection fraction, reduced LV end-diastolic pressure, and decreased LV volume. The technique also provides clinical improvements, as evidenced by improved postoperative New York Heart Association functional class status.

These surgical techniques enable mitral valve repair or replacement, thus contributing to the regression of hypertrophy and ventricular dilation. Finally, revascularization, especially combined with endoventricular circular plasty with or without mitral valve repair or replacement, can further improve cardiac function by increasing blood flow and oxygen supply to the ischemic areas of the myocardium.

In patients with a large LVA, the Cooley technique may be preferable to the endoventricular circular plasty technique, although the latter can be considered in patients with extensive involvement of the septum and mitral valve apparatus.<sup>52</sup> Vural and colleagues<sup>53</sup> concluded that the Cooley technique or linear closure may also be preferable in patients whose aneurysms lack a well-defined border, whereas the circular plasty technique is a better choice for patients with extensive and defined fibrotic aneurysmal sacs.

Outcomes of the surgical techniques have been reported in the literature; however, they are difficult to interpret because of variations in the patient populations undergoing the procedures and the evolution of surgical techniques. Many of the existing studies are single-center, retrospective, or nonrandomized, and many are either uncontrolled or use historical controls. Only a few randomized, controlled studies have been performed, and some of these have had enrollment problems or issues with inclusion criteria. Well-conducted multicenter, randomized, controlled studies are needed so that valid comparisons among the different surgical techniques can be made.

## Acknowledgment

We thank Sonya E. Fogg, MLS (Manager, Library and Learning Resource Center, Texas Heart Institute), for researching and verifying our historical reference.<sup>22</sup>

## References

1. Cooley DA, Henly WS, Amad KH, Chapman DW. Ventricular aneurysm following myocardial infarction: results of surgical treatment. *Ann Surg* 1959;150:595-612.
2. Rutherford JD, Braunwald E, Cohn PE. Chronic ischemic heart disease. In: Braunwald E, editor. *Heart disease: a textbook of cardiovascular medicine*. Philadelphia: Saunders; 1988. p. 1364.
3. Favalaro RG, Effler DB, Groves LK, Westcott RN, Suarez E, Lozada J. Ventricular aneurysm--clinical experience. *Ann Thorac Surg* 1968;6(3):227-45.
4. Schoen FJ. Ischemic heart disease. In: *Interventional and surgical cardiovascular pathology: clinical correlations and basic principles*. Philadelphia: Saunders; 1989. p. 58.
5. Schuster EH, Bulkley BH. Expansion of transmural myocardial infarction: a pathophysiologic factor in cardiac rupture. *Circulation* 1979;60(7):1532-8.
6. Mills NL, Everson CT, Hockmuth DR. Technical advances in the treatment of left ventricular aneurysm. *Ann Thorac Surg* 1993;55(3):792-800.
7. Grieco JG, Montoya A, Sullivan HJ, Bakhos M, Foy BK, Blakeman B, Pifarre R. Ventricular aneurysm due to blunt chest injury. *Ann Thorac Surg* 1989;47(2):322-9.
8. Anselmi A, Moleiro F, Suarez R, Suarez JA, Ruesta V. Ventricular aneurysms in acute experimental Chagas' myocardiodopathy. *Chest* 1971;59(6):654-8.
9. Silverman KJ, Hutchins GM, Bulkley BH. Cardiac sarcoid: a clinicopathologic study of 84 unselected patients with systemic sarcoidosis. *Circulation* 1978;58(6):1204-11.
10. Davila JC, Enriquez F, Bergoglio S, Voci G, Wells CR. Congenital aneurysm of the left ventricle. *Ann Thorac Surg* 1965;1(6):697-710.
11. Abrams DL, Edelist A, Luria MH, Miller AJ. Ventricular aneurysm. A reappraisal based on a study of sixty-five consecutive autopsied cases. *Circulation* 1963;27:164-9.
12. Glower DD, Schaper J, Kabas JS, Hoffmeister HM, Schaper W, Spratt JA, et al. Relation between reversal of diastolic creep and recovery of systolic function after ischemic myocardial injury in conscious dogs. *Circ Res* 1987;60(6):850-60.
13. Eaton LW, Weiss JL, Bulkley BH, Garrison JB, Weisfeldt ML. Regional cardiac dilatation after acute myocardial infarction: recognition by two-dimensional echocardiography. *N Engl J Med* 1979;300(2):57-62.
14. Hutchins GM, Bulkley BH, Moore GW, Piasio MA, Lohr FT. Shape of the human cardiac ventricles. *Am J Cardiol* 1978;41(4):646-54.
15. Gerdes AM, Capasso JM. Structural remodeling and mechanical dysfunction of cardiac myocytes in heart failure. *J Mol Cell Cardiol* 1995;27(3):849-56.
16. Kanazawa T. Coronary collateral circulation--its development and function. *Jpn Circ J* 1994;58(3):151-65.
17. Meizlish JL, Berger HJ, Plankey M, Errico D, Levy W, Zaret BL. Functional left ventricular aneurysm formation after acute anterior transmural myocardial infarction. Incidence, natural history, and prognostic implications. *N Engl J Med* 1984;311(16):1001-6.
18. Grondin P, Kretz JG, Bical O, Donzeau-Gouge P, Petitclerc R, Campeau L. Natural history of saccular aneurysms of the left ventricle. *J Thorac Cardiovasc Surg* 1979;77(1):57-64.
19. Swan HJ. Left ventricular systolic and diastolic dysfunction in the acute phases of myocardial ischemia and infarction, and in the later phases of recovery. Function follows morphology. *Eur Heart J* 1993;14 Suppl A:48-56.
20. Marcus ML, Stanford W, Hajduczuk ZD, Weiss RM. Ultrafast computed tomography in the diagnosis of cardiac disease. *Am J Cardiol* 1989;64(9):54E-59E.
21. Cosgrove DM, Lytle BW, Taylor PC, Stewart RW, Golding LA, Mahfood S, et al. Ventricular aneurysm resection. Trends in surgical risk. *Circulation* 1989;79(6 Pt 2):I97-101.
22. Wieting. Eine operative behandelte Herzmißbildung. *Deutsche Zeitschrift für Chirurgie* 1912;114(1-3):293-5. Available from: <https://babel.hathitrust.org/cgi/pt?id=uva.3470075173;view=lup;seq=311> [cited 2017 Jun 16].
23. Beck CS. Operation for aneurysm of the heart. *Ann Surg* 1944;120(1):34-40.
24. Dolly CH, Dotter CT, Steinberg H. Ventricular aneurysm in a 29-year-old man studied angiocardiographically. *Am Heart J* 1951;42(6):894-9.
25. Likoff W, Bailey CP. Ventriculoplasty: excision of myocardial aneurysm; report of a successful case. *J Am Med Assoc* 1955;158(11):915-20.
26. Mukaddirov M, Demaria RG, Perrault LP, Frapier JM, Albat B. Reconstructive surgery of postinfarction left ventricular aneurysms: techniques and unsolved problems. *Eur J Cardiothorac Surg* 2008;34(2):256-61.
27. Cooley DA, Collins HA, Morris GC Jr, Chapman DW. Ventricular aneurysm after myocardial infarction; surgical excision with use of temporary cardiopulmonary bypass. *J Am Med Assoc* 1958;167(5):557-60.
28. Stoney WS, Alford WC Jr, Burrus GR, Thomas CS Jr. Repair of antero-septal ventricular aneurysm. *Ann Thorac Surg* 1973;15(4):394-404.
29. Daggett WM, Guyton RA, Mundth ED, Buckley MJ, McEnany MT, Gold HK, et al. Surgery for post-myocardial infarct ventricular septal defect. *Ann Surg* 1977;186(3):260-71.
30. Jatene AD. Left ventricular aneurysmectomy. Resection or reconstruction. *J Thorac Cardiovasc Surg* 1985;89(3):321-31.
31. Dor V, Saab M, Coste P, Kornaszewska M, Montiglio F. Left ventricular aneurysm: a new surgical approach. *Thorac Cardiovasc Surg* 1989;37(1):11-9.
32. Cooley DA. Ventricular endoaneurysmorrhaphy: a simplified repair for extensive postinfarction aneurysm. *J Card Surg* 1989;4(3):200-5.
33. Hutchins GM, Brawley RK. The influence of cardiac geometry on the results of ventricular aneurysm repair. *Am J Pathol* 1980;99(1):221-30.
34. Dor V. Surgical management of left ventricular aneurysms by the endoventricular circular patch plasty technique. *Oper Techn Cardiovasc Surg* 1997;2(2):139-50.
35. Di Donato M, Sabatier M, Toso A, Barletta G, Baroni M, Dor V, Fantini F. Regional myocardial performance of non-ischaemic zones remote from anterior wall left ventricular aneurysm. Effects of aneurysmectomy. *Eur Heart J* 1995;16(9):1285-92.
36. Cox JL. Surgical management of left ventricular aneurysms: a clarification of the similarities and differences between the Jatene and Dor techniques. *Semin Thorac Cardiovasc Surg* 1997;9(2):131-8.
37. McCarthy PM, Starling RC, Wong J, Scalia GM, Buda T, Vargo RL, et al. Early results with partial left ventriculectomy. *J Thorac Cardiovasc Surg* 1997;114(5):755-65.
38. Caldeira C, McCarthy PM. A simple method of left ventricular reconstruction without patch for ischemic cardiomyopathy. *Ann Thorac Surg* 2001;72(6):2148-9.
39. Alderman EL, Fisher LD, Litwin P, Kaiser GC, Myers WO, Maynard C, et al. Results of coronary artery surgery in patients with poor left ventricular function (CASS). *Circulation* 1983;68(4):785-95.
40. Milano CA, White WD, Smith LR, Jones RH, Lowe JE, Smith PK, Van Trigt P 3rd. Coronary artery bypass in patients with severely depressed ventricular function. *Ann Thorac Surg* 1993;56(3):487-93.

41. Bolling SF, Deeb GM, Brunsting LA, Bach DS. Early outcome of mitral valve reconstruction in patients with end-stage cardiomyopathy. *J Thorac Cardiovasc Surg* 1995;109(4):676-83.
42. Cohn JN. Structural basis for heart failure. Ventricular remodeling and its pharmacological inhibition. *Circulation* 1995;91(10):2504-7.
43. St John Sutton M, Pfeffer MA, Moye L, Plappert T, Rouleau JL, Lamas G, et al. Cardiovascular death and left ventricular remodeling two years after myocardial infarction: baseline predictors and impact of long-term use of captopril: information from the Survival and Ventricular Enlargement (SAVE) trial. *Circulation* 1997;96(10):3294-9.
44. Gaudron P, Eilles C, Kugler I, Ertl G. Progressive left ventricular dysfunction and remodeling after myocardial infarction. Potential mechanisms and early predictors. *Circulation* 1993;87(3):755-63.
45. Konstam MA, Rousseau MF, Kronenberg MW, Udelson JE, Melin J, Stewart D, et al. Effects of the angiotensin converting enzyme inhibitor enalapril on the long-term progression of left ventricular dysfunction in patients with heart failure. SOLVD Investigators. *Circulation* 1992;86(2):431-8.
46. Cox JL. Left ventricular aneurysms: pathophysiologic observations and standard resection. *Semin Thorac Cardiovasc Surg* 1997;9(2):113-22.
47. Dor V, Sabatier M, Di Donato M, Maioli M, Toso A, Montiglio F. Late hemodynamic results after left ventricular patch repair associated with coronary grafting in patients with postinfarction akinetic or dyskinetic aneurysm of the left ventricle. *J Thorac Cardiovasc Surg* 1995;110(5):1291-301.
48. Di Donato M, Sabatier M, Dor V, Toso A, Maioli M, Fantini F. Akinetic versus dyskinetic postinfarction scar: relation to surgical outcome in patients undergoing endoventricular circular patch plasty repair. *J Am Coll Cardiol* 1997;29(7):1569-75.
49. Dor V, Sabatier M, Di Donato M, Montiglio F, Toso A, Maioli M. Efficacy of endoventricular patch plasty in large postinfarction akinetic scar and severe left ventricular dysfunction: comparison with a series of large dyskinetic scars. *J Thorac Cardiovasc Surg* 1998;116(1):50-9.
50. Klein MD, Herman MV, Gorlin R. A hemodynamic study of left ventricular aneurysm. *Circulation* 1967;35(4):614-30.
51. Pouleur HG, Konstam MA, Udelson JE, Rousseau MF. Changes in ventricular volume, wall thickness and wall stress during progression of left ventricular dysfunction. The SOLVD Investigators. *J Am Coll Cardiol* 1993;22(4 Suppl A):43A-48A.
52. Tavakoli R, Bettex D, Weber A, Brunner H, Genoni M, Pretre R, et al. Repair of postinfarction dyskinetic LV aneurysm with either linear or patch technique. *Eur J Cardiothorac Surg* 2002;22(1):129-34.
53. Vural KM, Sener E, Ozatik MA, Tasdemir O, Bayazit K. Left ventricular aneurysm repair: an assessment of surgical treatment modalities. *Eur J Cardiothorac Surg* 1998;13(1):49-56.