

UC Davis

UC Davis Previously Published Works

Title

Acute airway obstruction by a sheared endotracheal intubation stylet sheath in a premature infant

Permalink

<https://escholarship.org/uc/item/7ts252gv>

Journal

Journal of Perinatology, 27(11)

ISSN

0743-8346

Authors

Chiou, H-L
Diaz, R
Orlino, E
et al.

Publication Date

2007-11-01

Peer reviewed

Title

Acute Airway Obstruction by a Sheared Endotracheal Intubation Stylet Sheath in a Premature Infant

Short running title

Airway obstruction by a stylet sheath

Authors

Hui-Li Chiou¹, Rodney Diaz², Elmo Orino, Jr.³, Francis Poulain¹

1. Department of Pediatrics, Division of Neonatology, University of California
Davis Medical Center
2. Department of Otolaryngology - Head and Neck Surgery, University of California
Davis Medical Center
3. Department of Anesthesiology and Pain Medicine, University of California Davis
Medical Center

Corresponding author

Francis Poulain, M.D.

Address: Department of Pediatrics, Division of Neonatology, Surge 1, Room 1121,
University of California, Davis, CA 95616. USA.

Tel: (530) 752-3441

Fax: (530) 752-6215

Email: fpoulain@ucdavis.edu

Reprint request

Francis Poulain, M.D.

Address: Department of Pediatrics, Division of Neonatology, Surge 1, Room 1121,
University of California, Davis, CA 95616. USA.

Abstract

Airway obstruction by foreign bodies is rarely encountered in the neonatal intensive care unit. The majority of those cases reported are iatrogenic. This paper reports a case of a preterm infant with an acute airway obstruction by a sheared plastic sheath of an endotracheal intubation stylet that was used during tracheal intubation. The small airway of this premature infant posed a challenge to retrieve the foreign body and to ensure adequate gas exchange at the same time. The risks and benefits of available therapeutic options for this rare, but serious complication are reviewed.

Key words

Airway obstruction, foreign body, endotracheal intubation stylet, premature infant

Introduction

Although airway obstruction by foreign bodies is a common and serious problem in young children, it is extremely rare in neonates. Literature reviews reveal that the majority of foreign bodies were derived from medical devices.^{1,2,3,4,5,6,7,8} Despite the advance in videoendoscopic technology, removing foreign bodies from the airway of small infants remains a challenge, with the potential for causing significant morbidity or mortality. This paper reports a case of acute airway obstruction in a preterm infant caused by a sheared plastic sheath of an endotracheal intubation stylet used during tracheal intubation.

Case Report

A very low birth weight male infant was born at 27 weeks of gestation by spontaneous vaginal delivery. The infant was intubated with a 2.5 mm uncuffed endotracheal tube (ETT) for respiratory failure in the delivery room without difficulty. The infant's skin color, heart rate and muscle tone improved immediately afterward. A plastic-coated stylet (Flexi-Slip™ 6 FR Stylet, REF No 502501, Rusch Teleflex Medical, Bannockburn, IL, USA) was used during the intubation. Proper ETT placement was confirmed by carbon dioxide detection and auscultation. The infant's skin color, heart rate and muscle tone improved immediately afterward. Exogenous surfactant (Infasurf™), 3.4 mL in two aliquots, was administered via ETT within the first hour for persistently poor respiratory effort and presumed respiratory distress syndrome. The infant maintained good oxygenation with mechanical ventilation and a 50% fraction of inspired oxygen. Chest radiography showed ground-glass appearance of lung fields. The infant's first blood gas

from the umbilical artery at one hour of life showed severe respiratory acidosis (pH 7.00, PCO₂ 114, PO₂ 86, HCO₃ 28, BE -6). A more critical review of the chest radiograph revealed the presence of a foreign body spanning the trachea and extending into the right mainstem bronchus (Figure 1). Inspection of the stylet used during tracheal intubation revealed that the distal portion of the plastic sheath was missing (Figure 2). Otolaryngology service was emergently consulted and the infant was taken to the operating room. The ETT was slowly removed while the infant was under general anesthesia, but this failed to bring forth the foreign body. Therefore, an optical forceps was inserted and gently advanced under telescopic vision into the trachea. It revealed the proximal end of the sheared stylet sheath that obstructed approximately three-quarters of the tracheal lumen. The proximal end of the sheared fragment was securely grasped and removed via the optical forceps without inducing trauma (recovered fragment shown in Figure 2). The infant tolerated the procedure well and maintained good oxygenation. Following reintubation with a 2.5 mm ETT, the infant's respiratory acidosis rapidly resolved.

Discussion

Airway obstruction by foreign bodies is extremely rare in neonates. Fragments of pacifiers,^{10,11} syringe caps,¹² small food items,¹³ and broken glass¹⁴ have all been reported as the cause of foreign body aspiration in small infants. However, the obstruction usually involves medical devices in hospitalized infants.^{1,2,3,4,5,6,7,8} The majority of cases result in severe respiratory complications.

Endotracheal intubation stylets are commonly used to assist tracheal intubation in neonates, especially in those with major upper airway anomalies. Stylets are covered with a plastic sheath to reduce the risk of trauma to the airway and to facilitate the stylet withdrawal from the ETT. However, as examined in this case, the plastic sheath can break off and retain in the airway. Literature reviews found five case-reports of acute airway obstruction by a sheared stylet sheath, four in premature infants and one in a one-month-old term infant.^{1,2,3,4,5} Recognizing this potential hazard, one manufacturer issued a recall.⁹

It is unclear how the plastic sheath sheared off during the tracheal intubation procedure. The sheath is not bonded to the stylet's metal core. It is stretchable. Its distal portion can be separated from the metal core during withdrawal of the stylet. Previous authors have suggested that the points of maximal stress and shearing on the plastic sheath are at the ETT connector, or where the ETT is shaped or grasped during the withdrawal of the stylet.^{1,2} The timing and means of retrieval of a sheared stylet sheath have been the subjects of controversy in the literature. Although immediate withdrawal of the ETT may lead to simultaneous removal of the sheared fragment, as shown in two previous reports,^{2,4} there is no a priori guarantee that this will be the case. A sheared stylet sheath left in situ will increase the difficulty and risks of reintubation. The sheared fragment may be pushed in further during reintubation, potentially causing pulmonary parenchymal injury or migrating to a location too far to be retrieved with endoscopic instrumentation. In either scenario, an emergency thoracotomy would be required. In our case, the infant maintained oxygenation, which allowed us time to choose a more

controlled situation to retrieve the sheared stylet sheath. Because the sheared fragment had migrated distally and could not be withdrawn along with the ETT, an optical forceps was used for its removal. In 1999, Boyd et al. reported a similar case in which the sheared stylet sheath was removed via a fluoroscopy-guided gooseneck snare.³ Based on these two cases, we warn against rushing to withdraw the ETT when faced with a similar situation, especially when the sheared fragment appears to have migrated deep into the bronchus. In institutions where access to specialists experienced in pediatric airway management is available, the practitioner should seek their assistance immediately. If the infant's condition is severely compromised, any delay in removing the foreign body may further jeopardize the infant's well-being.

Tracheal intubation is one of the most common invasive procedures performed in the neonatal intensive care unit. Of all the possible complications from tracheal intubation, endotracheal retention of a sheared stylet sheath is a rare, but serious one. Therefore, careful inspection of the integrity of the intubation stylet after its removal is highly recommended. When endotracheal retention of a sheared stylet sheath is recognized, practitioners need to weigh the risks and benefits of immediate ETT withdrawal versus retrieval in a controlled situation by a specialist. When the infant's condition is stable, consulting a specialist experienced in pediatric airway management will help provide the optimal way to manage this serious complication.

References

1. Cook WP, Schultetus RR. Obstruction of an endotracheal tube by the plastic coating sheared from a stylet. *Anesthesiology* 1985; 62:803-4.
2. Bhargava M, Pothula SN, Joshi S. The obstruction of an endotracheal tube by the plastic coating sheared from a stylet: a revisit. *Anesthesiology* 1998; 88:548-9.
3. Boyd RL, Bradfield HA, Burton EM, Carter BS. Fluoroscopy-guided retrieval of a sheared endotracheal stylet sheath from the tracheobronchial tree in a premature infant. *Pediatr Radiol* 1999; 29:575-7.
4. Rabb MF, Larson SM, Greger JR. An unusual cause of partial ETT obstruction. *Anesthesiology* 1998; 88:548.
5. Zmyslowski WP, Kam D, Simpson GT. An unusual cause of endotracheal tube obstruction. *Anesthesiology* 1989; 70:883.
6. Shapiro NL, Kaselonis GL. Tracheobronchial foreign body management in an acutely ill neonate. *Int J Pediatr Otorhinolaryngol* 2000; 52:75-7.
7. Garcia-Aparicio L, Castanon M, Tarrado X, Rodriguez L, Iriundo M, Morales L. Bronchial complication of a closed-tube endotracheal suction catheter. *J Pediatr Surg* 2002; 37:1483-4.
8. Nurkin S, Waisman D, Davkin O, Kessel I, Vinograd I, Rotschild A. A rare complication of the closed tracheal suction system. *J Pediatr* 2004; 145:858.
9. Recalls and Field Corrections: Devices – Class II: Product: Mallinckrodt Satin-Slip Intubation Stylet, 6 Fr., single use, Model number 85863, Recall # Z-1431-06. on U.S. Food and Drug Administration Enforcement Report (Aug. 30, 2006).
10. Scherz RG. Premie nipples: a potential aspiration hazard. *Pediatrics* 1980; 65:163-4.

- 11.** Millunchick EW, McArtor RD. Fatal aspiration of a makeshift pacifier. *Pediatrics* 1986; 77:369-70.
- 12.** Little JP, Tunkel DE, Marsh BR. Foreign body aspiration: an unusual complication of antibiotic therapy. *Arch Pediatr Adolesc Med* 2000; 154:313-4.
- 13.** Aslan AT, Yalcin E, Ozcelik U, Ciftci AO, Kiper N. Foreign-body aspiration mimicking congenital lobar emphysema in a forty-eight-day-old girl. *Pediatr Pulmonol* 2005; 39:189-91.
- 14.** Pavan Sardana ASB, V. P. Singh, Meeta Arora. Unusual foreign bodies of the aerodigestive tract. *Indian Journal of Otolaryngology and Head and Neck Surgery* 2002; 54:123-26.

Figure legends

Figure 1. Anteroposterior chest radiograph showing the sheared stylet sheath in the trachea extending into the right main bronchus. Arrow points to the sheared stylet sheath.

Figure 2. Photograph of the broken Flexi-Slip™ 6 FR Stylet and the sheared stylet sheath.

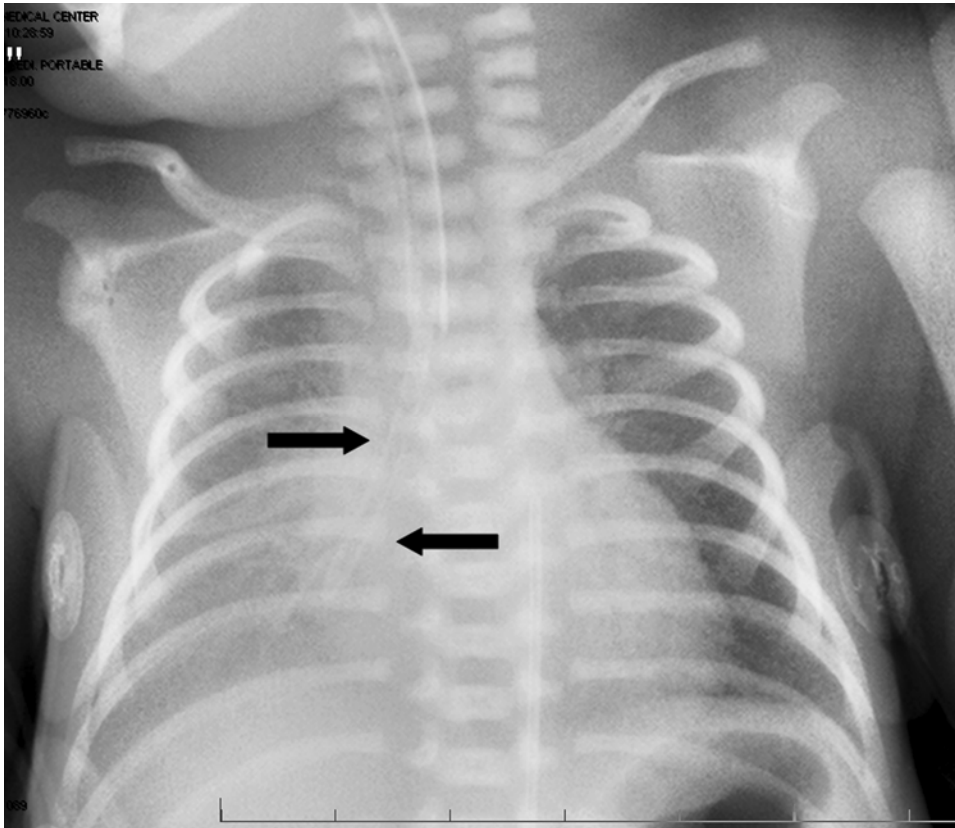


Figure 1: Anteroposterior chest radiograph shows the sheared stylet sheath in the trachea extending into the right main bronchus. Arrows point to the sheared stylet sheath

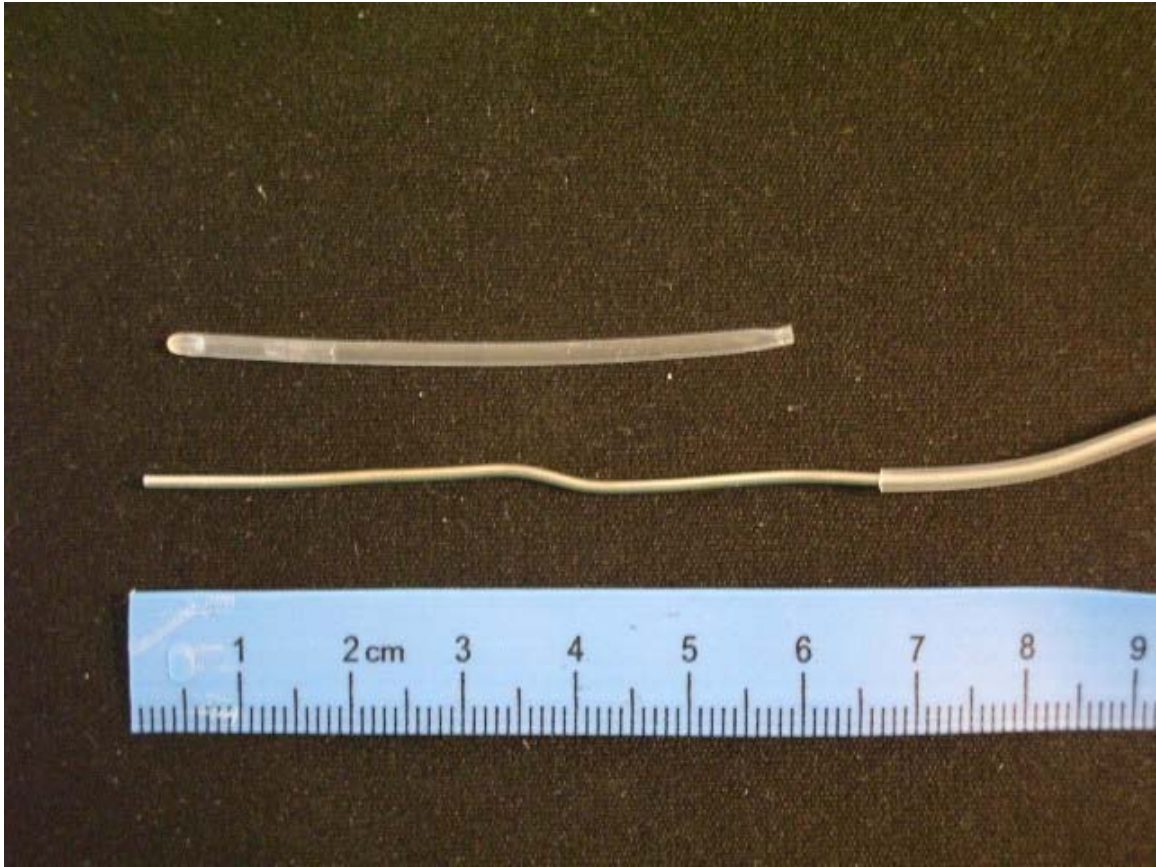


Figure 2: Photograph of the broken Flexi-Slip 6 Fr stylet and the sheared stylet sheath.