

UC Irvine

Journal of Education and Teaching in Emergency Medicine

Title

Cholelithiasis: WES Sign

Permalink

<https://escholarship.org/uc/item/81x2b170>

Journal

Journal of Education and Teaching in Emergency Medicine, 2(1)

Authors

Ehsani-Nia, Hamid
Toohey, Shannon

Publication Date

2017

DOI

10.5070/M521033785

Copyright Information

Copyright 2017 by the author(s). This work is made available under the terms of a Creative Commons Attribution License, available at <https://creativecommons.org/licenses/by/4.0/>

Peer reviewed

Cholelithiasis: WES Sign

Hamid Ehsani-Nia, MS* and Shannon Toohey, MD, MAEd[^]

*Rowan University School of Osteopathic Medicine, Stratford, NJ

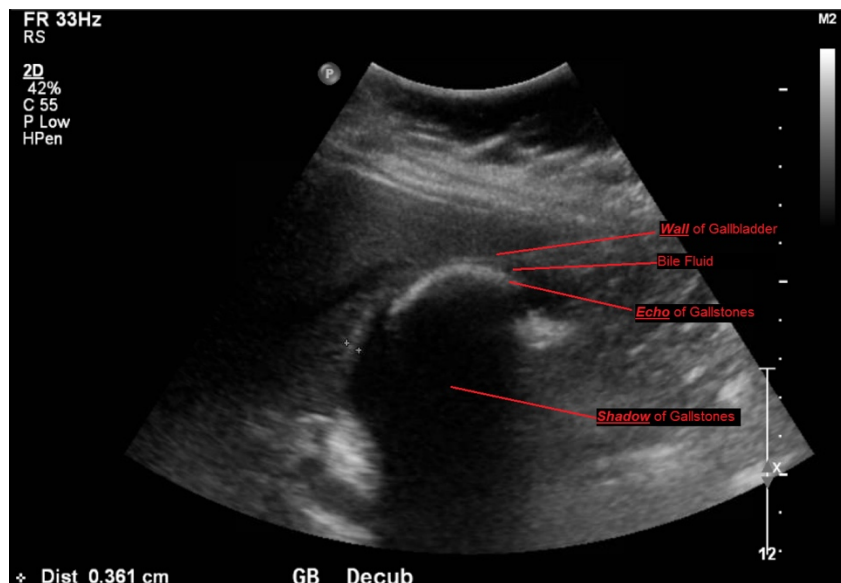
[^]University of California, Irvine, Department of Emergency Medicine, Orange, CA

Correspondence should be addressed Hamid Ehsani-Nai at hamid.ehsaninia@rutgers.edu

Submitted: November 27, 2016; Accepted: December 3, 2016; Electronically Published: January 28, 2017; <https://doi.org/10.21980/J8X300>

Copyright: © 2017 Ehsani-Nia, et al. This is an open access article distributed in accordance with the terms of the Creative Commons Attribution (CC BY 4.0) License.

See: <http://creativecommons.org/licenses/by/4.0/>



History of present illness: A 33-year-old female with multiple previous episodes of biliary colic presented to the emergency department with severe right upper quadrant pain that started 30 minutes prior to arrival. She characterized her pain as sharp and pulling and radiating to the back. Upon physical examination, patient was in acute distress with severe tenderness to right upper quadrant palpation. Her abdomen was soft, with no guarding or rebound tenderness.

Significant findings: Abdominal ultrasound showed the classic presentation of the Wall-Echo-Shadow (WES) sign. The superficial aspect of the gallbladder *wall* is represented by a hyperechogenic curve. Below this, bile fluid is represented by hypoechoogenicity. Underneath the bile fluid is the *echo* of the dense border created by the collection of gallstones, represented by a hyperechogenic curve. Due to the high density of the gallstones, nothing deeper can be visualized (including other gallstones or the far end of the gallbladder); this is the *shadow*.

Discussion: The WES sign, first described in the early 1980s, is a clear way of identifying cholelithiasis when the condition has progressed to fill the entire lumen of the gallbladder.¹ In this case, the lumen of the

gallbladder looks hypoechogenic relative to the surrounding tissue, much like an empty gallbladder. This is due to the border of the dense stones opposing the near wall of the gallbladder casting a shadow over everything distal to the stones. These key visualization techniques decrease non-visualization of chronic cholelithiasis.^{2,3,4} In most cases, WES sign is sufficient to diagnose cholelithiasis. Of note, “porcelain gallbladder” or collapsed duodenum can have the potential produce similar ultrasonographic findings.^{4,5}

Topics: Ultrasound, gallbladder, WES, wall echo shadow, cholelithiasis, gallstones, abdominal pain.

References:

1. Macdonald FR, Cooperberg PL, Cohen MM. The WES triad - a specific sonographic sign of gallstones in the contracted gallbladder. *Gastrointest Radiol.* 1981;6(1):39-41. doi: 10.1007/BF01890219
2. George N, Dawkins A, Disantis D. The wall-echo-shadow (WES) sign. *Abdom Imaging.* 2015;40(7):2903. doi: 10.1007/s00261-015-0401-4
3. Raptopoulos V, D'orsi C, Smith E, Reuter K, Moss L, Kleinman P. Dynamic cholecystosonography of the contracted gallbladder: the double-arc-shadow sign. *AJR Am J Roentgenol.* 1982;138(2):275-278. doi: 10.2214/ajr.138.2.275
4. Rybicki FJ. The WES sign. *Radiology.* 2000;214(3):881-882. doi: 10.1148/radiology.214.3.r00mr38881
5. Solomon DM, Paippattuthara J, Zoberman H, Hahn B. Images in emergency medicine: wall-echo-shadow (WES) complex. *J Emerg Med.* 2012;43(3):e203-204. doi: 10.1016/j.jemermed.2011.01.001