

# UC Irvine

## UC Irvine Previously Published Works

### Title

A DISORDER OF RAPID EYE MOVEMENTS IN HUNTINGTON'S CHOREA

### Permalink

<https://escholarship.org/uc/item/824080nj>

### Journal

Brain, 90(3)

### ISSN

0006-8950

### Author

STARR, ARNOLD

### Publication Date

1967

### DOI

10.1093/brain/90.3.545

### Copyright Information

This work is made available under the terms of a Creative Commons Attribution License, available at

<https://creativecommons.org/licenses/by/4.0/>

Peer reviewed

## A DISORDER OF RAPID EYE MOVEMENTS IN HUNTINGTON'S CHOREA

BY

ARNOLD STARR

*Division of Neurology, Stanford University School of Medicine and  
Neurology Service, Veterans Administration Hospital, Palo Alto, California*

### INTRODUCTION

NEUROLOGISTS have traditionally analysed extraocular motility in terms of deficiencies of directional gaze or of disordered ocular reflexes. It should be apparent that an analysis of the movements themselves might also be of value in understanding the mechanisms regulating extraocular behaviour. In 1903, Dodge defined the two basic ways in which the eyes move. The first is by discrete and rapid jumps (up to  $600^\circ/\text{sec.}$ ) called saccades or version movements; the second is by a slower but continuous progression (up to  $45^\circ/\text{sec.}$ ) called following or tracking movements. The two types of eye movements are employed for different purposes. Saccades serve to bring the fovea promptly on to an eccentric point in the visual field, whereas smooth movements enable the fovea to be maintained on a continuously moving object. Thus, saccades can be considered as a response to position, and following movements as a response to velocity (Westheimer, 1954; Rashbass, 1961). Evidence from a wide variety of studies in normal individuals indicates that there may be a distinct neural mechanism regulating each of these eye movements and that normal ocular motility depends upon the integration of the two systems (Dodge, Travis and Fox, 1930; Rashbass, 1961; Young and Stark, 1963; Robinson, 1965).

The purpose of this report is to provide an example of the dissociation of function of the two ocular control systems by a disease of the central nervous system, Huntington's chorea. Three patients with this illness were unable to move their eyes in a rapid saccade while preserving smooth following movements. One of the patients was studied in detail to define

the nature of the defective oculomotor performance and to relate this defect to other motor manifestations of Huntington's chorea.

#### CASE DESCRIPTIONS

*Case 1* (D.J., V.A. Hospital No. 011268), is a 25-year-old right-handed man with Huntington's chorea. The initial signs of his illness consisted of (1) an awkwardness of gait, (2) slowness of speech, and (3) changes in thinking, noted when he was 19. The movement disorder earned him the nickname of "Shaky Jake" and led to a medical discharge from the Marine Corps. The diagnosis of Huntington's chorea was made when the incidence of this illness in his family became known (fig. 1). A

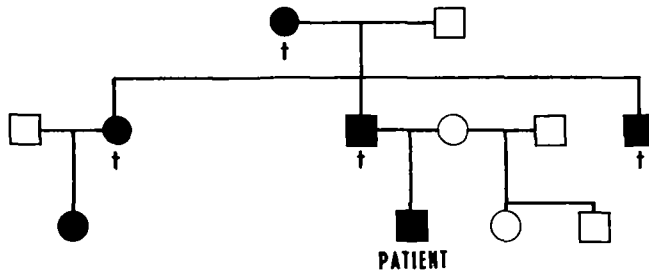


FIG. 1.—To show the incidence of Huntington's chorea in the family of D.J.

neurological examination one year later in 1962 detailed: (1) a gait disturbance characterized by sudden lurches, particularly on turning; (2) facial grimaces; (3) an inability of the eyes "to follow . . . in any direction." He voluntarily requested sterilization before his marriage in 1963. On my examination in 1964, approximately four years after the onset of his illness, the patient was alert, orientated, and without memory defects. Right-left orientation was intact. His speech was slow but otherwise intact. There were frequent facial grimaces and only an occasional choreic movement of the extremities. The gait was stiff and its rhythm was disrupted by sudden truncal lurches. Strength was preserved and the deep tendon reflexes were normal. The plantar responses were flexor and the sensation normal.

Oculomotor performance was disturbed in a remarkable manner. The patient could move his eyes to all positions in order to track a slowly moving object but was unable to look voluntarily to the side or upwards. Downward voluntary gaze, convergence, and pupillary responses were normal. The patient was not aware of his impaired oculomotor activities and had compensated for the deficits by head and neck movements. Re-examination one year later was unchanged except for the development of memory deficits and depression.

The results of pertinent laboratory tests were (1) a full-scale WAIS score of 82, with a 94 on the verbal portion and 69 on the performance portion; (2) cerebrospinal fluid protein on two occasions was 40 mg. per cent and the colloidal gold curve was 1111100000; (3) the EEG contained predominantly low voltage beta activity without focal changes; (4) skull X-rays were normal; (5) a pneumoencephalogram demonstrated an enlargement of the second portion of the lateral ventricles attributable to bilateral atrophy of the head of the caudate nucleus without any cortical atrophy.

In summary, an abnormality of rapid eye movements was an early finding in this patient with Huntington's chorea.

*Case 2* (L.A., V.A. Hospital No. 04937), is a 50-year-old right-handed man whose father, grandfather, brother and sister had Huntington's chorea. The patient's symptoms began at age 30 with abnormal truncal movements. He worked as a truck driver for a further four years until the motor disorder, coupled with suicide attempts, led to his committal to a State Hospital. In 1950 he was described as being disoriented for time, depressed, with "athetosis of the upper extremities, spasticity, hyperactive deep tendon reflexes, and extensor plantar responses bilaterally." There was no mention of extraocular movements. On my examination in 1964, the patient was confined to bed, with flexion contractures of both lower extremities; the left upper extremity was in flexion at the elbow and wrist and the right upper extremity was flexed at the wrist. Both thumbs were flexed on to the palm with the fingers covering the thumb. There was also a marked retraction of the lower jaw: The patient made only a moaning sound and it was not possible to communicate with him. There were frequent eye blinks but no spontaneous saccadic movements. The eyes tended to be in the mid-line. Slow following movements were elicited on two occasions, one of which was recorded by photography. Optokinetic nystagmus was absent. Cold caloric stimulation of the labyrinths did not evoke any nystagmus. The pupils were equal and reacted to light. Visual field testing was not feasible. In spite of severe flexion contractures, there were continuous small choreiform movements of the toes and fingers. The deep tendon reflexes were not possible to evaluate because of the contractures. The plantar responses were both extensor. Any touch around the face caused a marked withdrawal. Sensory examination showed that the limbs were withdrawn from painful stimulation.

In summary, this patient with advanced Huntington's chorea manifested by rigidity and dystonia presents a disorder of rapid extraocular movements similar to that of Case 1.

*Note.*—Dr. Lysia Forno has examined the central nervous system of Case 2, who expired early in 1967. There was severe degeneration of the putamen and caudate with a diffuse atrophy of moderate degree in cerebral cortex. The III nerve nuclei showed some cell loss, gliosis and neurofibrillary tangles, findings that may be pertinent for the clinical disorder of extraocular motility.

*Case 3* (W.B., V.A. Hospital No. A-914), was a 42-year-old male whose father and brother died in their thirties with an illness characterized by abnormal movements. The patient's inco-ordination of the limbs began at age 30. The motor disability increased over the next few years forcing him to retire in 1957. In 1958 he developed seizures and was admitted to hospital because he could not care for himself. The seizures, which persisted until his death in 1966, were of two types. The first were lapses of posture lasting 15 seconds in which he would suddenly slump forward, if sitting, and experience nausea but not lose consciousness. The second consisted of generalized tonic, clonic movements of the extremities with tongue biting and incontinence. Both were reduced in frequency by phenytoin and phenobarbital. He was described in 1958 as an alert man with abnormal grimacing movements of the face, writhing movements of his trunk and extremities, no motor weakness, flexor responses to plantar stimulation, and normal extraocular movements. The motor disability progressed so that he was unable to feed or care for himself, yet his mental status remained remarkably clear; a score of 101 was attained on the verbal portion of the Wechsler-Bellvue test in 1961. A pneumoencephalogram in the same year detailed diffuse ventricular enlargement and cortical atrophy.

Two right chemopallidectomies were done in 1961; the first was unaccompanied by any change in the patient's movements, the second resulted in a left hemiplegia.

I examined the patient in October, 1964. He was alert and accurately carried out my commands. His speech was too dysarthric for any systematic examination of verbal intelligence. There were continual writhing movements of the right limbs involving proximal more than distal muscles. The left side was hemiparetic and had decreased spontaneous movements. The plantar response was extensor on the left.

Extraocular movements were remarkable in that no saccades were noted, but slow following movements were preserved. There was no nystagmus in response to optokinetic stimulation. Cold caloric activation of the labyrinth resulted in a tonic deviation of the eyes to the stimulated side without any rapid compensatory nystagmus.

The patient became gradually less responsive, lapsed into coma, and died in March, 1966.

Examination of the nervous system showed (1) bilateral atrophy of the caudate and putamen, (2) an oligodendroglioma involving the ventricular system and infiltrating the basal ganglia, the hypothalamus, the mid-brain, and even the leptomeninges of the spinal cord.

In summary, Case 3 had a movement disorder characterized by chorea of twelve years' duration. The family history of a similar movement disorder justifies the diagnosis of Huntington's chorea. The finding of an extensive oligodendroglioma at post mortem involving some of the same structures as those affected by Huntington's chorea complicates the analysis of the patient's signs and symptoms. In particular, the disorder of oculomotor function could be assigned to the effects of the oligodendroglioma's infiltration of the mid-brain oculomotor centres, as well as to the Huntington's chorea. In any case, the clinical disorder of rapid eye movements manifested by this patient was essentially the same as in the two other patients with Huntington's chorea.

Six other patients with Huntington's chorea, ranging in age from 28 to 40, were examined for disorders of extraocular movements. Rapid eye movements were present in all of these patients, both on voluntary gaze and in response to optokinetic stimuli.

#### EXPERIMENTAL METHODS

The experiments presented in this report were undertaken to quantify the oculomotor performance of the patient reported as Case 1. The impaired mental status of the other two patients made any systematic study, other than the cinematographic registration of eye movements, difficult to perform. Eye movements were examined by electro-oculography (EOG), by direct electromyography of the extraocular muscles (EMG), and by cinematography. The electro-oculogram, which utilizes changes in the corneal-retinal potential as an index of eye position, was recorded for vertical movements from a pair of electrodes immediately above and below the eye, and for horizontal movements from a pair of electrodes just lateral and medial to the eye. The electrodes were either chlorided silver discs, 5 mm. in diameter, affixed to the skin by collodion and tape, or Beckman DC electrodes. The latter were used exclusively

on the patient's return visit in 1966. The DC potential between the electrodes of each pair was amplified and recorded either on an Offner dynograph or photographed on an oscilloscope. At each recording session the DC potential associated with calibrated movements of 10°, 20° and 30° was defined enabling the determination of eye movements during subsequent testing. Electromyography of the extraocular muscles was performed by Dr. Arthur Jampolsky.<sup>1</sup> The eye was anaesthetized with topical anaesthesia and 30 gauge coaxial needles inserted in the lateral and medial rectus muscles. The potentials were amplified and recorded on tape, along with a commentary of the eyes' position and movements. Cinematographic examination of eye movements was made by standard techniques.

Oculomotor functions were examined with the head in a fixed position during (1) attempted voluntary saccades, (2) visual tracking, (3) fixation on a slowly revolving optokinetic drum, (4) cold caloric stimulation of the labyrinth, (5) intravenous administration of sodium amytal, and (6) sleep. For voluntary saccades the patient was requested to look in a particular direction or to look at an object situated at a defined point in the visual field. For visual tracking the patient was seated in front of an oscilloscope, the eye without electrodes covered by a patch, and instructed to look at the oscilloscope beam during its deflections by sinusoidal, sawtooth, or square wave signals. These voltages were monitored along with the EOG so that the relative positions of the beam and the eye were known at all times. During twelve nights of sleep, eye movements were monitored by the EOG along with EEG and mentalis motor activity. The patient was awakened several times during each recording session and questioned about dreams.

Visual functions were assessed by standard techniques of perimetry and tangent screen determination of visual fields, by having the patient read, copy drawings, and duplicate block designs (Kohs blocks), and by having him examine visual illusions such as a Necker cube.

Finally we examined the correspondence between oculomotor and limb activities during the tracking of a moving light source, using an apparatus designed by Eppler (1966) in a study of normal tracking. The patient was seated 18 inches in front of a strip of paper on which a light source moved horizontally in discrete steps; the direction, amplitude, and frequency of movement were random. The patient's task was to maintain a movable lever, suspended from the ceiling directly in front of the paper, at the light's position. The positions of the light, the lever, the eyes, and the lever's velocity were recorded simultaneously.

## RESULTS

*I. Saccadic eye movements.*—During a normal horizontal saccade, the eyes move from the primary position with rapid velocity (up to 600°/sec.) to reach targets 10 to 30 degrees distant within 40 to 100 m.sec., (Robinson, 1964). In contrast, in our patient, more than ten times this interval was required to travel the same distances (fig. 2): from 400 to 3,000 m.sec., for 10 degrees of travel to more than 10 sec. for 30 degrees of travel. The maximum angular velocity achieved during these moves was only 30°/sec. Often the velocity was so slow that the eyes did not appear to be moving at all (fig. 3A) even though it was obvious from the widening

<sup>1</sup>Institute of Visual Sciences, Presbyterian Medical Center, San Francisco, California.

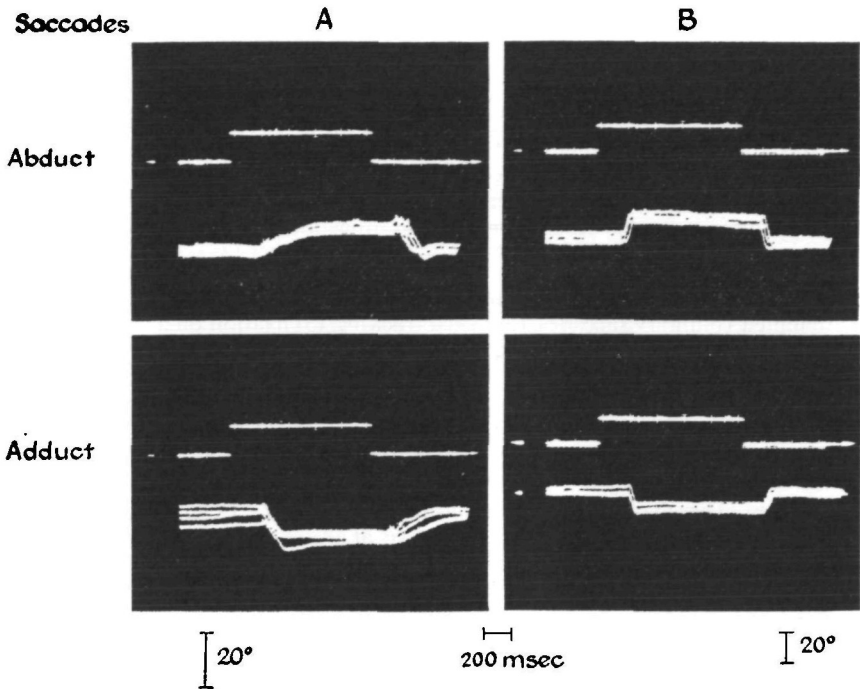


FIG. 2.—To show the EOG of eye movements in the horizontal plane of the patient D.J. (A), and of a normal control (B), during saccadic tracking. The voltage used to displace the oscilloscope beam  $10^\circ$  in the horizontal direction is depicted in the upper trace of each photograph and the corresponding EOG below. Four trials were superimposed on each photograph. The calibration of  $20^\circ$  applies only to the EOG.

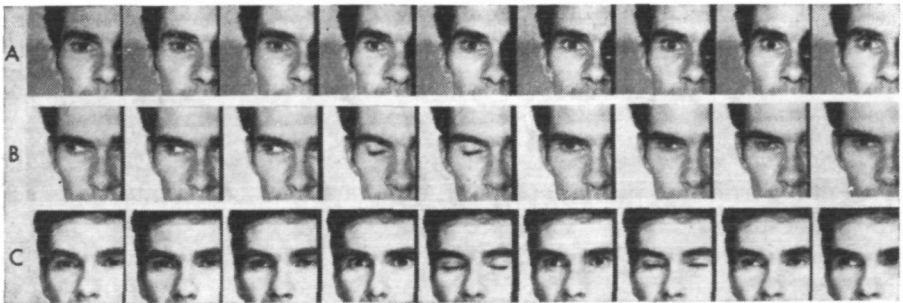


FIG. 3.—35 mm. photographs taken at six frames/sec. to show horizontal eye movements during (A) an attempted saccade in the temporal direction, (B) an attempted saccade from an abducted position back to the primary position, and (C) an attempted saccade as in (A) but with accompanying eye blinks. The frames in which the eyelid is closed represent a blink.

## SACCADES

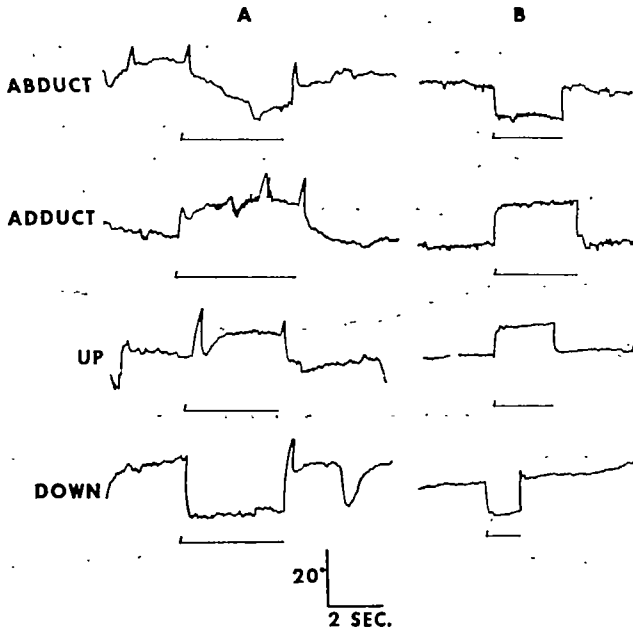


FIG. 4.—To show the EOG of eye movements in different planes of the patient D.J. (A), and of a normal control (B), in response to a command to look at a target situated in an appropriate portion of the visual field. The command for movement is represented by the thin line beneath each of the EOGs. The large upward deflections in the patient's EOG represent artifacts associated with blinking.

of the palpebral fissures that the patient was making an intense effort. In contrast to the slowed eye movements, the patient's reaction time from a signal indicating that the move should begin to the first change of eye position was comparable to that of the normal subjects (150–300 m.sec.). All saccades were not affected uniformly. Thus whereas both horizontal and upward gaze were impaired, downward movements were executed normally (fig. 4). Furthermore, horizontal gaze in the temporal direction was more impaired than in the nasal direction and both of these movements were performed less rapidly than a saccade returning the eye from the periphery back to the primary position. A consistent difference between horizontal saccades away from the primary position compared with those on return gaze was the occurrence of eye blinks during the latter movements (fig. 3B). When the patient was instructed to blink as well during gaze away from the primary position, his oculomotor performance improved (figs. 2C; 5): the eyes accelerated more rapidly and achieved distant targets not possible without blinking. The improvement associated with blinking did not seem to depend on a disruption of visual fixation



since attempted saccades with the eyes closed or in total darkness were no better than with the eyes open.

Rapid eye movements were also absent during automatic and reflexively elicited eye movements.

(a) No rapid eye movements were elicited during fixation of a rotating optokinetic drum; the patient's eyes deviated tonically in the direction of spin without compensatory return movements (optokinetic nystagmus).

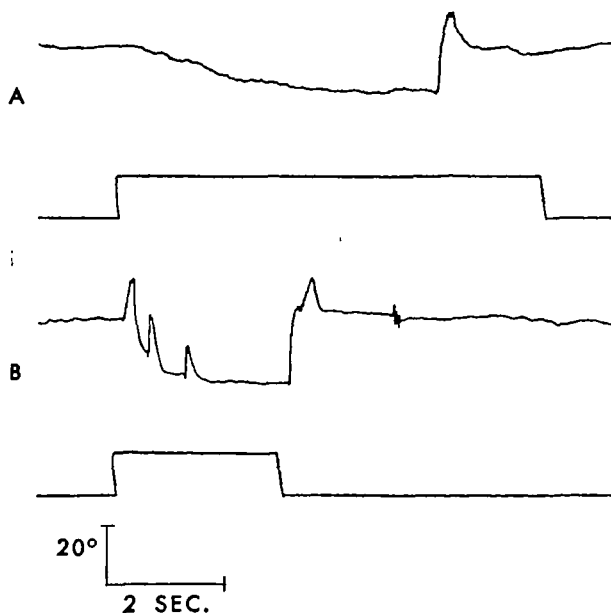


FIG. 5.—To show the improvement of a horizontal saccade with eye blinks. The upper trace of A and B is the EOG; the lower trace is the event marker indicating a tone whose onset is the signal to look rapidly at a point  $20^\circ$  from the primary position and whose termination signals the return of gaze back to the primary position. In A, the patient carried out the command in his usual fashion, and in B he was instructed to blink. The occurrence of each blink is indicated by the upward deflections of the EOG.

(b) No rapid eye movements were elicited by cold caloric stimulation of the labyrinth; the patient's eyes deviated tonically towards the stimulated ear and did not develop any rapid return movements (vestibular nystagmus). The deviation was so intense that the patient was unable to move his eyes back to mid-position either by voluntary effort or by attempts at tracking a moving object.

(c) No rapid eye movements accompanied the administration of sodium amytal. The drug was administered intravenously while the patient was

tracking a moving oscilloscope beam (fig. 6). The amplitude of tracking gradually lessened but remained smooth in shape until finally the eyes ceased moving and remained stationary at the primary position. In contrast, the administration of barbiturates to normal individuals transforms smooth tracking into a series of saccades (Rashbass, 1961) and any attempt at fixation brings forth a rapid nystagmus (Bergman, Nathanson and Bender, 1952).

(d) No rapid eye movements were detected during the paradoxical or REM stage of sleep (Dement, 1964), even though other aspects of paradoxical sleep, i.e. the low voltage fast EEG and the decrease of somatic muscle activity were evident. The patient was awakened during 25 such episodes and a report of dreaming was obtained only once.

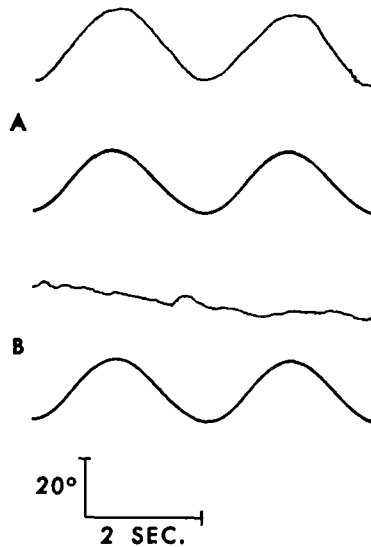


FIG. 6.—To show the effect of intravenous sodium amytal on horizontal eye movements during slow tracking. The upper trace of A and B are the EOG and the lower trace is the voltage applied to the oscilloscope beam. A was recorded prior to the administration of sodium amytal; B was recorded one minute after the injection of 150 mg. of sodium amytal. Note the disappearance of tracking in B and the absence of nystagmus. The downward slope of the EOG in B does not represent an eye movement but is an artifact due to a DC drift of the electrodes. The 20° calibration refers only to the EOG.

(e) No saccades occurred during reading. With his head fixed, the patient's eyes drifted slowly across the lines instead of proceeding in rapid jumps characteristic of normal individuals (fig. 7). To compensate for this deficit, the patient read by turning his head in jerks with an accompanying blink of the eyes.

Thus, the patient's inability to make rapid eye movements characterized all of his oculomotor activities ranging from voluntary to reflexively elicited movements.

The muscular events underlying the patient's altered eye movements were examined by electromyography of the lateral and medial rectus muscles. During an attempted horizontal saccade in the temporal direction (fig. 8B, first arrow) there was a gradual recruitment of motor units in the prime mover (lateral rectus) with a concomitant gradual decline of motor unit activity in the antagonist muscle (medial rectus). In contrast, during a normal saccade there is a short duration (30 to 150 m.sec.) burst of large

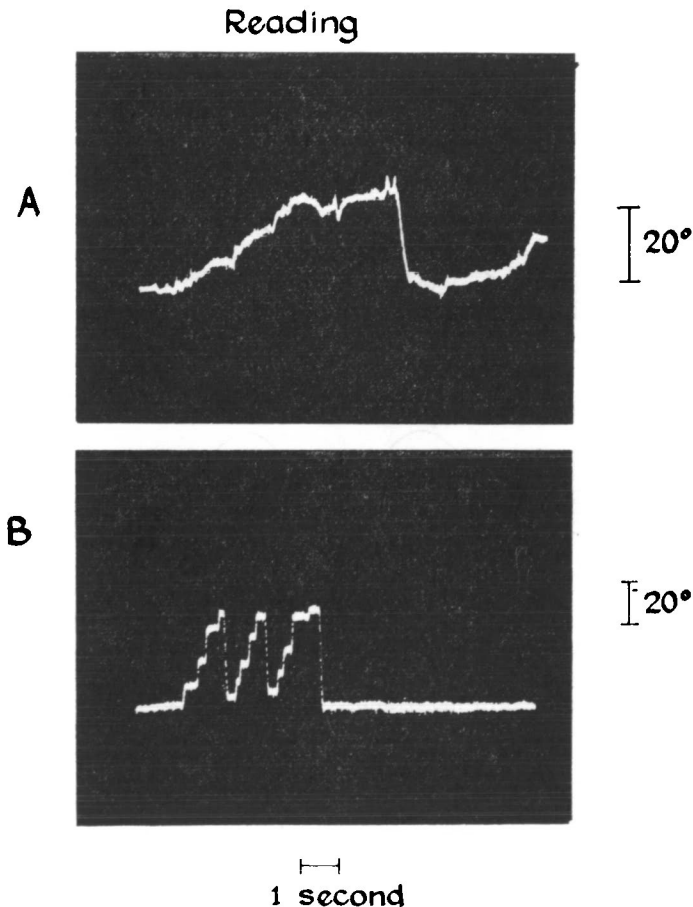


FIG. 7.—To show the absence of saccades in patient, D.J., during reading. The recordings represent the EOG of horizontal eye movements during an attempt to read three lines. A is from the patient D.J., who was able to complete only  $1\frac{1}{2}$  lines, and B is from a normal control.

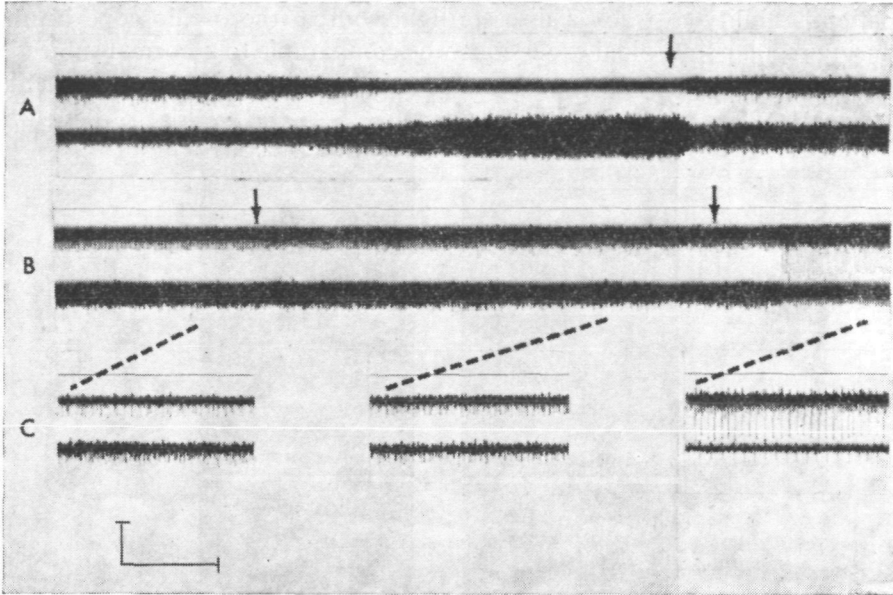


FIG. 8.—To show the EMG of the lateral rectus (upper trace of each photograph) and the medial rectus (lower trace of each photograph) during (A) slow tracking, and (B) and (C), an attempted saccade. In A, the EMG of the two muscles demonstrates a normal reciprocal relationship during slow tracking. When the eye was fully adducted (at the arrow), the patient was instructed to look back rapidly to the primary position. Note the gradual but reciprocal change of muscle activity over a 150 m.sec. period. In B, the patient was instructed to look rapidly away from the primary position. Corresponding samples of the EMG in B, but recorded at ten times faster speed, are shown in C. Following the first command (the initial arrow), the eye did not appear to move, and the EMG correspondingly shows only a slight but reciprocal change in the level of activity. At the second arrow, the patient was instructed to blink as well, and the EMG shifted with an accompanying movement of the eye. The time scale represents 1 sec. for A and B, and 100 m.sec. for C. Amplitude calibration is 100  $\mu$ V. The large single unit recorded from the lateral rectus in B and C has been retouched for clarity.

amplitude in the prime mover with complete inhibition of activity in the antagonist (Miller, 1958; Tamler, Marg, Jampolsky and Nawratzki, 1959). Even during a blink that facilitated saccades (fig. 8B, second arrow), or during a saccade returning the eye to the primary position (fig. 8A, arrow), the levels of muscle activity changed much more slowly than in normals. Thus, the slowed velocity of eye movements in our patient can be attributed to a defect in the initiation of rapid phasic changes in the extraocular muscles in the presence of a preserved pattern of reciprocal innervation.

*II. Tracking eye movements.*—Oculomotor tracking was most thoroughly examined for objects having either a sinusoidal or a uniform velocity. The

patient's ability to track a discrete light source (the oscilloscope beam) during regular sinusoidal excursions was comparable to a normal subject's tracking through  $\cdot 5$  c/s (fig. 9). At 1 c/s, the patient's eye movements

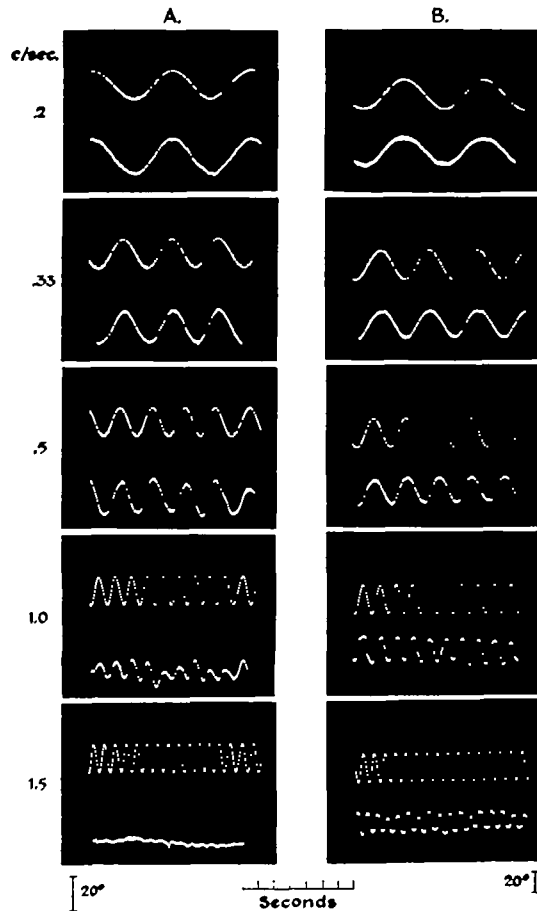


FIG. 9.—To show the EOG (lower trace of each photograph) of the patient D.J. (A) and a normal control (B) during slow tracking of a moving oscilloscope beam. The voltage displacing the oscilloscope beam is recorded in the upper trace of each photograph, and the rate of displacement is calculated in the left-hand column. Note the correspondence between the patient and the control subject during sinusoidal tracking through  $0\cdot 5$  c/s. At faster rates, saccades replace smooth movement in the control subject, whereas the patient's eye movements gradually diminished in amplitude, till they were virtually absent at  $1\cdot 5$  c/s. The calibration of  $20^\circ$  refers only to the EOG.

became irregular in amplitude and at still faster frequencies ( $1\cdot 5$  c/s), tracking ceased entirely. Normal subjects, in contrast, could continue to follow the oscilloscope beam up to about  $2\cdot 5$  c/s by changing from smooth

tracking movements to saccadic tracking. Stark, Vossius and Young (1962) have shown that the accuracy of smooth tracking for sinusoidal motions can occur up to about 1.2 c/s, but that at higher frequencies, saccades must be introduced to compensate for phase lags in smooth tracking. As our patient was unable to make saccades, his tracking depended solely on the maximum angular velocity of his smooth following movements, which was about  $35^\circ/\text{sec}$ .

A comparable figure of  $40.5^\circ/\text{sec}$ . was achieved by the patient on tracking the oscilloscope beam when it was deflected by sawtooth voltages of different slopes. Though the patient was able to achieve angular velocities of approximately  $40^\circ/\text{sec}$ . for intervals up to 400 m.sec., his tracking was accurate over longer periods only if velocities less than  $25^\circ/\text{sec}$ . were required.

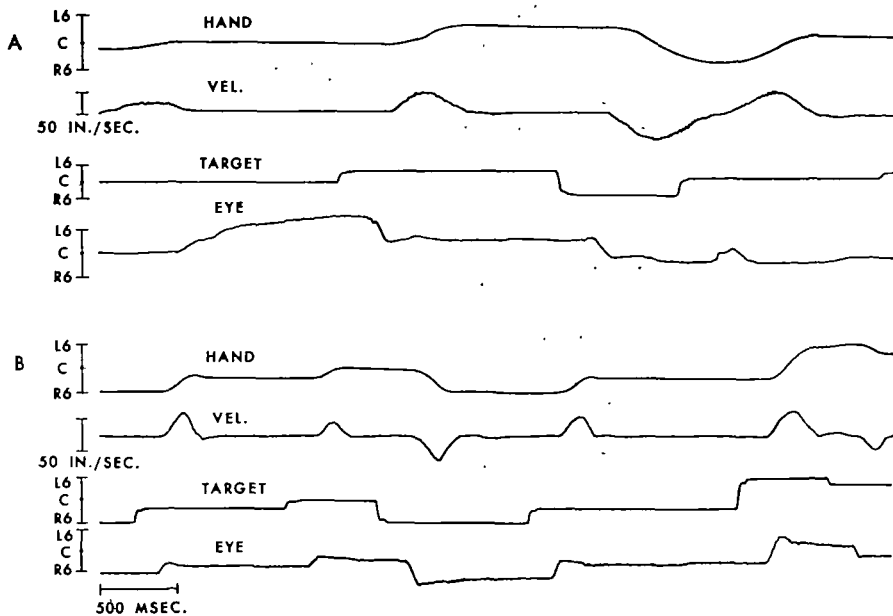


FIG. 10.—To show limb movements in a patient D.J. with Huntington's chorea (A), and in a normal control (B), during tracking of a moving light. Hand position (Hand), hand velocity (Vel.), target position (Target), and the EOG of eye position (Eye) were recorded simultaneously. The calibration C refers to a position directly in front of the subjects and L6 and R6 refer to positions six inches to the left and to the right of this centre position. Note that a longer time is required by the patient than by the control subject to achieve a maximum limb velocity.

*III. Oculomotor and limb performance.*—The patient was unable to accelerate his limb as rapidly as normal individuals. Figure 10 shows the record of limb position, limb velocity, target position, and eye position in

the patient (A), and in a normal control (B), during a portion of a tracking task in which the intent was to maintain a lever in front of a moving light. Note that while the maximum velocity of the limb was the same in this patient as in the control subject, the time required to achieve this velocity, and hence the acceleration, differed. In three normal subjects, limb acceleration for a move of six inches ranged from 420 to 650 in./sec.<sup>2</sup> (Eppler, 1966), whereas in our patient the acceleration for the corresponding move was only about half as fast, averaging 237 in./sec.<sup>2</sup> for nine individual moves. It is pertinent that the patient's reaction time from the displacement of the light to the onset of limb movement averaged 215 m.sec., a figure corresponding to the normal subjects' latencies of 200 to 220 m.sec. We may conclude that even though the patient could initiate limb muscle contractions at a short latency, he was unable to produce the requisite amount of force over a short period of time for normal acceleration. A similar conclusion is applicable to oculomotor performance on attempted saccades since the eyes could not be accelerated rapidly even though their reaction times were normal (fig. 2). Thus the disorder of rapid eye movements in this patient with Huntington's chorea is accompanied by a corresponding disorder of rapid movements in skeletal muscles.

#### DISCUSSION

The present study establishes that rapid and slow eye movements can be selectively affected in individuals with Huntington's chorea. Three patients with this illness were unable to move their eyes rapidly in a saccade but had normal slow following movements during visual pursuit. Rapid eye movements were affected over a wide range of oculomotor activities including (1) voluntary gaze, (2) responses to caloric stimulation of the labyrinth, (3) optokinetic reflexes, (4) visual fixation following parenteral barbiturates, and (5) during the paradoxical or rapid eye movement (REM) stage of sleep. During all of these activities, slow continuous eye movements were normal. The physiological mechanisms accounting for such a dissociated loss of saccadic eye movements have been clarified by the findings that saccadic and smooth following eye movements behave as if they were regulated by separate neural systems (Westheimer, 1954*b*; Rashbass, 1961; Robinson, 1964, 1965). We propose that the particular neural system subserving saccades has been selectively affected in these three patients with Huntington's chorea.

The evidence distinguishing the two neural systems for eye movements is listed in Table I in terms of the afferent, efferent, and central characteristics of each of the oculomotor activities. On the afferent side, the adequate stimulus for the two movements is different. Saccades occur (1) in response to the peripheral position of an object in the visual field, (2) during orienting responses towards the source of unexpected sounds, and (3) in

TABLE I.—DISTINGUISHING CHARACTERISTICS OF THE TWO OCULOMOTOR ACTIVITIES

	<i>Saccade</i>	<i>Continuous</i>
1. Afferent (Adequate Stimulus)	position	velocity
2. Efferent		
A. Latency	> 200 m.sec.	< 125 m.sec.
B. Velocity of move	up to 600°/sec.	not > 45°/sec.
3. Central		
A. Control system	sampled	continuous
B. presence at birth	yes	no
C. Barbiturates	no effects	abolish

response to spatial commands such as "look to the right." The adequate stimulus in these three instances is the requirement that the fovea be moved to a previously eccentric position (Rashbass, 1961; Robinson, 1964). Rashbass (1961) determined that this point need only be  $25\text{--}50^\circ$  from fixation to elicit a saccade. Smooth following movements, in contrast, occur in response to the steady motion of an object across the visual field and, by matching the object's velocity, enable the fovea to be continuously maintained on target (Rashbass, 1961). If the object's velocity exceeds  $45^\circ/\text{sec.}$ , smooth movements are not adequate for accurate pursuit and saccades must be introduced to compensate for the tracking error (Westheimer, 1954*b*).

In terms of their efferent behaviour, the two types of eye movements differ in three ways. First, their velocities are vastly disparate; during a saccade, the eye moves with a velocity of up to  $600^\circ/\text{sec.}$  (Westheimer, 1954*a*; Robinson, 1964), whereas the maximum velocity of a smooth movement is only  $45^\circ/\text{sec.}$  (Dodge, Travis and Fox, 1930). In our patient who could not make saccades, the maximum velocity of eye movements was  $40^\circ/\text{sec.}$ , corresponding to the slower continuous mode of function. Second, the latency from the adequate stimulus to the onset of eye movement is faster in continuous ocular activity than in saccades (Rashbass, 1961). Rashbass (1961) noted the two reaction times to fluctuate independently of one another during repetitive eye movements and proposed the existence of two separate neural systems to account for this phenomenon. The third distinguishing efferent characteristic of the two eye movements is their ability to move the eyes in opposite directions during complex situations (Rashbass, 1961; Robinson, 1965). Thus, a spot of light moved rapidly to the left, and then given an immediate slow velocity to the right, results in an initial slow continuous movement to the right, interrupted 100 m.sec. later by a saccade directing the eye back to the left. The eyes' behaviour in this situation is analogous to that of a vehicle controlled by



two separate drivers, each responding to different aspects of the situation.

The central mechanisms regulating saccadic and slow continuous eye movements can also be distinguished in several ways. First, the occurrence of saccades during tracking resembles the output of a model system sampling visual data at a maximum rate of 5/sec. (Young and Stark, 1963), whereas slow following ocular activity behaves as if it were controlled by a model system sampling data almost continuously (Robinson, 1965). Second, the two control systems mature differently; the infant is capable of making saccades from birth, but continuous movements only appear after three months of age (Dayton and Jones, 1964). Finally, the two neural systems can be selectively affected by pharmacological agents such as barbiturates (Rashbass, 1961), or by a variety of diseases of the central nervous system (Gassel and Williams, 1963; Noorden, Thompson and Van Allen, 1964; Rodin, 1964). In these instances, continuous eye movements are lost while saccades remain unaffected.

The structures subserving these two oculomotor systems are not known but may be related to the two types of muscle fibres found in mammalian extraocular muscle (Hess and Pilar, 1963; Dietert, 1965; Bach-y-Rita and Ito, 1966). The first has a single motor end plate with an extremely rapid time course of depolarization and the ability to respond up to 450/sec.—characteristics well suited for the development of maximal force over a short time, as is needed in saccades. The other type of muscle fibre has multiple end plates along its length, similar to the “slow” muscle fibres of insects, and possesses a long time course of depolarization with the ability to discharge repetitively only to 15–20/sec. This longer time course of depolarization might be better suited for the grading of tension, as would be needed to make slow eye movements continuous. The motor nerves to these two types of muscle fibres can be distinguished from one another by their diameter (Pilar and Hess, 1966), as well as by their physiological properties (Bach-y-Rita and Ito, 1966), but the central nervous system structures controlling these two neuromuscular systems are not known. The loss of saccades in the patients with Huntington’s chorea presented in this study and previous description of impaired or slowed conjugate gaze in this same illness (Bender, 1960; Bittenbender and Quadfasel, 1962) raises the possibility that the caudate nucleus which is predominantly affected in Huntington’s chorea may be intimately related to the neural system regulating rapid eye movements. This interpretation receives indirect support from animal experiments in which “wide and vacuous eyes” with a “paucity of eye movements” were the consequence of bilateral caudate lesions (Mettler, 1964), while stimulation of the head of the caudate evoked orienting eye movements to the opposite side (Laursen, 1963). These results can only be considered suggestive since the animals’ eye movements were not described specifically in terms of rapid or slow activities.

The loss of saccadic eye movements in only three of the nine patients with Huntington's chorea examined in this report requires an explanation. The difference between the six patients with normal eye movements and the three patients with an absence of saccades might be due to biotypes among individuals with Huntington's chorea, based on genetically determined variations in the central nervous system lesions. Such a concept has been proposed as the basis for the rigid and hypotonic forms of Huntington's chorea (Bittenbender and Quadfasel, 1962). Alternatively, since the motor manifestations of Huntington's chorea change during the course of the illness (Denny-Brown, 1962), the disorder of rapid eye movements may not yet have become manifest in these six patients and should become evident on subsequent examinations.

*Relation to ocular motor apraxia.*—The disorder of eye movement seen in these patients was initially thought to be typical of an oculomotor apraxia. Such a diagnosis requires that a movement that cannot be made on a voluntary basis occurs either spontaneously or reflexively. Thus our patients could not voluntarily look to the side, but could do so while tracking a moving object. Waltz (1961) has indicated that the mechanisms of oculomotor apraxia are varied. A failure of voluntary gaze in the presence of preserved reflex eye movements may be associated with a deficit of (1) visual perception, as in Balint's syndrome (Hécaen and Ajuriaguerra, 1954), (2) motor organization, as in lesions of the frontal lobes (Smith and Holmes, 1916), or (3) a result of heightened reflex, such as the fixation reflex (Holmes, 1938). The present instances of impaired eye movements in Huntington's chorea cannot be considered as an apraxia of gaze because the primary deficit, that of an inability to make rapid eye movements, could not be corrected either voluntarily or reflexively. An exaggerated fixation reflex was not responsible for the loss of rapid eye movements since ocular motility was not improved in the dark or with the eyes closed.

The recognition of the functional distinction between saccadic and slow continuous eye movements suggests alternatives in investigating clinical disorders of ocular motility. For instance, children with congenital oculomotor apraxia have a deficit of voluntary eye movements that has been attributed to a heightened fixation reflex (Altrocchi and Menkes, 1960). They are unable to move their eyes to an object located in the periphery but have no difficulty in tracking. A significant associated disorder is the absence of rapid eye movements in response to optokinetic or caloric stimulation. Since these children have no other evidence of apraxia, it may be that their primary disorder is not apractic but rather a developmental deficit of a portion of the neural system regulating rapid eye movements.

*Rapid eye movements and the motor deficit of Huntington's chorea.*— We propose that a disturbance of rapid movements is a general feature of Huntington's chorea and not merely a peculiarity of the extraocular muscles. One of the patients in this study, as well as two other individuals with Huntington's chorea examined by Dr. Anthony Iannone (1966), were able to accelerate their limbs only one-half as fast as control subjects in the presence of normal strength and reaction times. Such a disability of rapid movements in Huntington's chorea might be an early manifestation of mechanisms leading to akinesia. Whether this deficit also plays a role in the progressive nature of the motor manifestations of Huntington's chorea beginning with chorea and terminating in rigidity and dystonia (Denny-Brown, 1963) is not clear.

#### SUMMARY

(1) Three patients with Huntington's chorea were unable to move their eyes in a rapid saccade while preserving slow following ocular movements. Ocular motility of one of these patients was studied in detail by electro-oculography (EOG), electromyography (EMG), and cinematography.

(2) Rapid eye movements could not be detected during (a) voluntary gaze, (b) optokinetic stimuli, (c) vestibular reflexes, (d) visual fixation following parenteral barbiturates, (e) reading, and (f) paradoxical or rapid eye movement sleep. During all of these activities, slow following movements were normal. The velocity of the fastest eye movement was only  $40.5^\circ/\text{sec}$ .

(3) Electromyography of the extraocular muscles showed the defect of rapid eye movements to be associated with a slowness of recruitment of motor units in the prime mover and a concomitant decrease in the rate of inhibition of the antagonist.

(4) A corresponding decrease in limb acceleration was found in one of the patients with Huntington's chorea. The slowed acceleration was not accompanied by any alteration in strength or reaction time.

(5) The disorder of rapid eye movements is discussed in relation to oculomotor mechanisms regulating rapid and slow eye movements.

#### ACKNOWLEDGMENTS

This study was made possible by the thoughtful contributions of the following individuals: Dr. William Dement, whom I assisted on several nights of sleep studies; Dr. Walter Eppler, who studied the characteristics of limb movements in our patient; Dr. Arthur Jampolsky, who performed the electromyography of the extraocular muscles; Mr. Will Renner, whose photography of the many patients helped define the problem; and Dr. Leon Festinger, who brought my attention to the theoretical problems of oculomotor controls.

## REFERENCES

- ALTROCCHI, P. H., and MENKES, J. H. (1960) *Brain*, **83**, 579.
- BACH-Y-RITA, P., and ITO, F. (1966) *J. gen. Physiol.*, **49**, 1177.
- BENDER, M. B. (1960) *J. nerv. ment. Dis.*, **130**, 456.
- BERGMAN, P. S., NATHANSON, M., and BENDER, M. B. (1952) *Arch. Neurol. Psychiat., Chicago*, **67**, 357.
- BITTENBENDER, J. B., and QUADFASEL, F. A. (1962) *Arch. Neurol., Chicago*, **7**, 275.
- DAYTON, G. O., Jr., and JONES, M. H. (1964) *Neurology, Minneap.*, **14**, 1152.
- DEMENT, W. C. (1964) In: "The Oculomotor System," edited by M. B. Bender. New York. p. 366.
- DENNY-BROWN, D. (1962) "The Basal Ganglia," London.
- DIETERT, S. E. (1965) *Invest. Ophthalm.*, **4**, 51.
- DODGE, R. (1903) *Amer. J. Physiol.*, **8**, 307.
- , TRAVIS, R. C., and FOX, J. C., Jr. (1930) *Arch. Neurol. Psychiat., Chicago*, **24**, 21.
- EPPLER, W. (1966) "Analytical Design of Manned Control Systems," Ph.D Thesis, Stanford University.
- GASSEL, M. M., and WILLIAMS, D. (1963) *Brain*, **86**, 1.
- HÉCAEN, H., and AJURIAGUERRA, J. DE. (1954) *Brain*, **77**, 373.
- HESS, A., and PILAR, G. (1963) *J. Physiol.*, **169**, 780.
- HOLMES, G. (1938) *Brit. med. J.*, **2**, 107.
- IANNONE, A. (1966) Personal communication.
- LAURSEN, A. M. (1963) *Acta physiol. scand.*, Suppl. 211.
- METTLER, F. A. (1964) In: "The Oculomotor System," edited by M. B. Bender, New York. p. 1.
- MILLER, J. E. (1958) *Amer. J. Ophthalm.*, **46**, (November, Pt. II) p. 183.
- NOORDEN, G. K. VON, THOMPSON, H. S., and VAN ALLEN, M. W. (1964) *Invest. Ophthalm.*, **3**, 314.
- PILAR, G., and HESS, A. (1966) *Anat. Rec.*, **154**, 243.
- RASHBASS, C. (1961) *J. Physiol.*, **159**, 326.
- ROBINSON, D. A. (1964) *J. Physiol.*, **174**, 245.
- (1965) *J. Physiol.*, **180**, 569.
- RODIN, E. A. (1964) *Arch. Neurol., Chicago*, **10**, 327.
- SMITH, S., and HOLMES, G. (1916) *Brit. med. J.*, **1**, 437.

- STARK, L., VOSSIUS, G., and YOUNG, L. R. (1962) *IRE Trans. on Human Factors in Electronics*, HFE-3, 52.
- TAMLER, E., MARG, E., JAMPOLSKY, A., and NAWRATZKI, I. (1959) *Arch. Ophthal., N.Y.*, **62**, 657.
- WALTZ, A. G. (1961) *Arch. Neurol., Chicago*, **5**, 638.
- WESTHEIMER, G. (1954a) *Arch. Ophthal., N.Y.*, **52**, 710.
- (1954b) *Arch. Ophthal., N.Y.*, **52**, 932.
- YOUNG, L. R., and STARK, L. (1963) *IEEE Trans. Human Factors in Electronics*, HFE-4, 38.