

# UC Irvine

## UC Irvine Previously Published Works

### Title

Utility of adding electrodes in patients undergoing invasive seizure localization: A case series.

### Permalink

<https://escholarship.org/uc/item/84c315jt>

### Authors

Chan, Alvin Y  
Lien, Brian V  
Brown, Nolan J  
[et al.](#)


### Publication Date

2022-08-01

### DOI

10.1016/j.amsu.2022.104139

Peer reviewed



## Case Series

## Utility of adding electrodes in patients undergoing invasive seizure localization: A case series

Alvin Y. Chan<sup>a,\*</sup>, Brian V. Lien<sup>a</sup>, Nolan J. Brown<sup>a</sup>, Julian Gendreau<sup>b</sup>, Ryan S. Beyer<sup>a</sup>,  
Chen Yi Yang<sup>a</sup>, Elliot H. Choi<sup>a</sup>, Frank P.K. Hsu<sup>a</sup>, Sumeet Vadera<sup>a</sup>

<sup>a</sup> Department of Neurological Surgery, University of California, 200 South Manchester Avenue, Suite 201, Orange, CA, 92868, United States

<sup>b</sup> Johns Hopkins Whiting School of Engineering, 3400 North Charles Street, Baltimore, MD, 21218, United States

## ARTICLE INFO

## Keywords:

Electrode  
Epilepsy  
SEEG  
Seizure  
Stereoelectroencephalography  
Subdural grid

## ABSTRACT

**Introduction:** Surgery can be an effective treatment for epilepsy if the seizure onset is adequately localized. Invasive monitoring is used if noninvasive methods are inconclusive. Initial invasive monitoring may fail if the pre-surgical hypothesis regarding location of epileptic foci is wrong. At this point, a decision must be made whether to remove all electrodes without a clearly defined location of onset or to implant additional electrodes with the aim of achieving localization by expanding coverage.

**Methods:** Electrodes were placed according to a hypothesis derived from noninvasive monitoring techniques in adult patients with long term epilepsy. Seizure onset was not clearly localized at the end of the invasive monitoring period in ten patients, and additional electrodes were placed based on a new hypothesis that incorporated data from the invasive monitoring period.

**Results:** Successful localization was achieved in nine patients. There were no complications with adding additional electrodes. At final follow up, four patients were seizure free while four others had at least a 50% reduction in seizures after undergoing surgical intervention.

**Conclusion:** Seizure foci were localized safely in 90% of adult patients with long term epilepsy after implanting additional electrodes and expanding coverage. Patients undergoing invasive monitoring without clear localization should have additional electrodes placed to expand monitoring coverage as it is safe and effective.

### 1. Introduction

Epilepsy is a debilitating disease that requires high expertise to treat effectively. The majority of patients have adequate seizure control with an anti-epileptic drug (AED) regimen, but many patients have disease refractory to these medications. These patients are often candidates for surgical intervention (e.g., resection, neurostimulation). The caveat is that effective surgical treatment depends on accurate seizure focus localization, which can be performed via noninvasive or invasive monitoring. Noninvasive monitoring may involve admission to an epilepsy monitoring unit (EMU) for several days while the patient is monitored with video electroencephalography (vEEG). Invasive monitoring can be used to localize seizure foci if noninvasive monitoring is inconclusive [1]. A presurgical hypothesis of seizure origin dictates where invasive intracranial electrodes are placed. Subdural grids (SDG) and stereoelectroencephalography (SEEG) are the most common forms

of invasive monitoring. The exact indications for SDG or SEEG are unclear. However, SEEG has become the more frequent choice due to its advantages, which include intracranial electrode placement without craniotomy [2]. The literature does suggest that the indications are likely nuanced, as one modality may help localize foci when the other fails [3,4].

There are no standardized guidelines for implanting intracranial electrodes for seizure localization, which can be problematic in cases where the pre-surgical hypotheses are incorrect, and the ictal onset location cannot be accurately localized. In these cases, the epilepsy team must consider whether to remove the electrodes and treat utilizing incomplete data, or the team may opt to add more electrodes with the prospect of successfully localizing the seizure onset. These choices are often unclear, as each route has its own potential complications.

Thus, in this case series, the authors reviewed adult patients at our institution who underwent additional SDG or SEEG placement for unclear localization after initial invasive monitoring for the treatment of

\* Corresponding author. Department of Neurological Surgery, University of California, Irvine 200 S. Manchester Avenue, Suite 201, Orange, CA, 92868, United States.

E-mail address: [alvinyc1@hs.uci.edu](mailto:alvinyc1@hs.uci.edu) (A.Y. Chan).

<https://doi.org/10.1016/j.amsu.2022.104139>

Received 30 May 2022; Received in revised form 4 July 2022; Accepted 6 July 2022

Available online 9 July 2022

2049-0801/© 2022 The Author(s). Published by Elsevier Ltd on behalf of IJS Publishing Group Ltd. This is an open access article under the CC BY-NC-ND license (<http://creativecommons.org/licenses/by-nc-nd/4.0/>).

### Abbreviations

AED	Anti-epileptic drug
EMU	Epilepsy monitoring unit
IRB	Institutional review board
MRI	Magnetic resonance imaging
RNS	Responsive neurostimulation placed
SDG	Subdural grids
SEEG	Stereoelectroencephalography
vEEG	Video electroencephalography

long term epilepsy. The primary outcome of this study was to assess whether this additional placement resulted in localization of the seizure focus and whether this resulted in the improvement of symptoms. Secondary objectives were to categorize any complications occurring with additional electrode placement.

## 2. Methodology

### 2.1. Study design, data collection & statistical analysis

The work was performed in accordance with PROCESS criteria with additional registration of this study online with the unique identifier: researchregistry7878 [5,6]. Institutional Review Board (IRB) approval was obtained for this study. This study was exempt from ethical board approval as this study used no identifying patient information. All patients were treated at the University of California, Irvine Medical Center

after the year 2014 and were retrospectively reviewed.

### 2.2. Pre-surgical work up

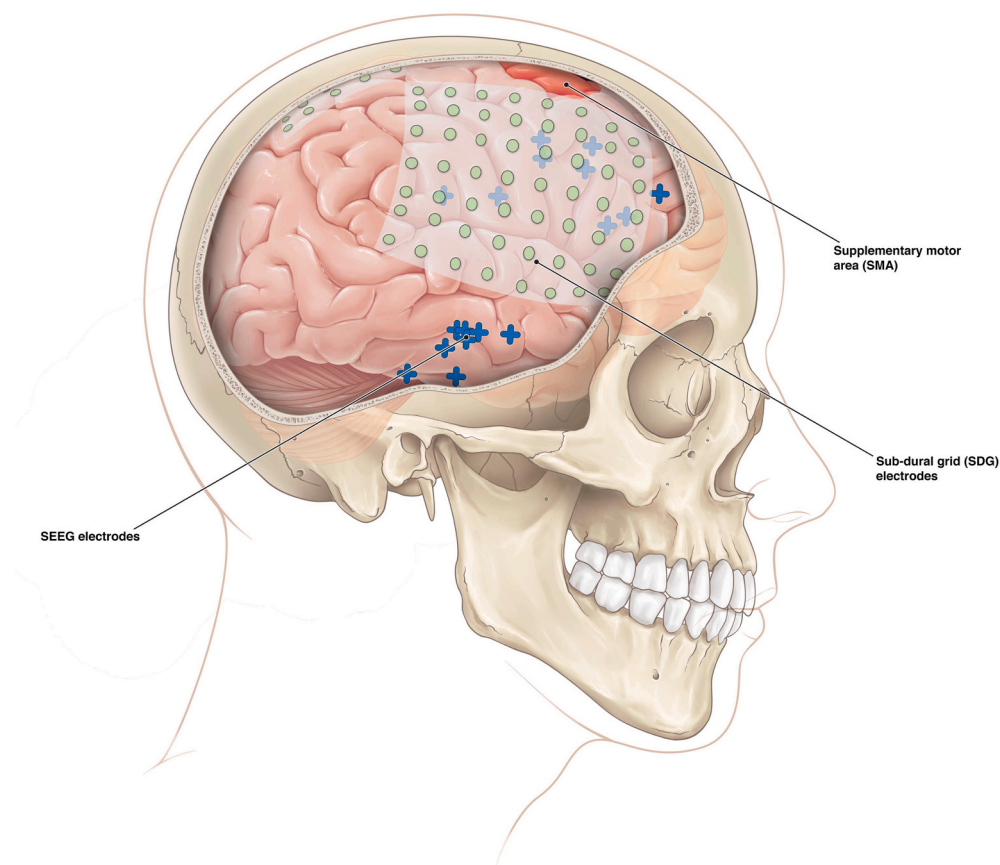
All pre-surgical data [e.g., disease burden, neuropsychological testing, magnetic resonance imaging (MRI) results, seizure semiology, vEEG] were taken into consideration. If there was a consensus that the patient should undergo invasive monitoring with SDG or SEEG placement, the decision was presented to the patient. The risks and benefits were discussed in detail. All patients consented to undergo invasive monitoring.

### 2.3. Surgical intervention

All surgical procedures were performed by S.V. to ensure standardization among procedures. The surgeon is a fellowship trained functional neurosurgeon with over 7 years of experience in epilepsy procedures. Patients were placed supine under general anesthesia, with their head secured on a stereotaxic frame. MRI and CT scans of the patient were input into the ROSA (Zimmer Biomet, Warsaw, Indiana, USA) computer program. The target trajectory was set to the patient specific cannula length and the electrode trajectory was identified. Guided electrode placement was used, where a small hole was drilled into the skull and small electrode wires were accurately inserted using ROSA. In patients with SDG placement, the SDGs were placed without robotic assistance via open craniotomy (Fig. 1).

## 3. Results

Ten adult patients met inclusion criteria for this study as they were



**Fig. 1.** Graphical depiction of both SDGs and SEEGs. SDGs are placed and offer widespread measurement across the superficial aspect of the cerebrum. However, SDGs are often unable to detect epileptiform foci at deeper tissues. SEEG is often placed at a greater depth inside the brain parenchyma enabling the device to detect epileptiform foci deeper in the brain. However, SEEG has less of a wide catch area when compared to SDG.

unable to achieve seizure foci localization using an initial attempt at invasive neuromonitoring (Table 1). No patients had any other significant medical comorbidities. The average age was  $34.6 \pm 7.7$  years. The average follow up was  $1.6 \pm 1.0$  years. The average duration of disease was  $22.5 \pm 13.9$  years. All patients had complex partial seizures. There were eight patients who had bilateral monitoring devices placed initially while the other two had unilaterally placed monitoring devices. Nine of the ten patients had only unilateral monitoring devices added while the last one had bilateral monitoring devices added at the second surgery.

Seizure foci were successfully localized after adding additional electrodes in nine of ten patients. Of the nine patients who had localization after adding electrodes, four underwent temporal resection, four underwent frontal lobe resection, and one had placement of a responsive neurostimulation device. Four of these patients were seizure free at last follow up while four others had at least a 50% reduction in seizures. The last patient did not experience any seizure reduction. There were no patients lost to follow-up and there were no observed complications.

#### 4. Discussion

An invasive neuromonitoring strategy is considered for patients with intractable focal epilepsy when noninvasive monitoring strategies fail to identify the seizure focus. In cases where the initial invasive monitoring procedure provides insufficient information to guide an adequate resection, an additional invasive monitoring procedure can be performed [4,7,8]. Localization of seizure origin is crucial to ensure complete resection, which is a predictor of seizure freedom and improved patient quality of life [8,9]. Here we describe our institution's experience with adding additional invasive neuromonitoring to localize seizure origin after an initial SDG or SEEG implantation in adult patients with long term symptoms, which resulted in 90% of patients achieving successful localization.

In these patients that achieved seizure localization with a second invasive neuromonitoring procedure, either focal resections or placement of a responsive neurostimulation device was performed. In eight of the nine patients, symptoms improved, with half of these patients achieving seizure freedom. These results are promising, especially when considering the median duration of epilepsy in these patients was over two decades. Longer durations of epilepsy have previously correlated with poorer seizure outcome after resection [4,10]. Overall, these results

suggest that a second invasive neuromonitoring intervention is a viable option for adult patients with long term epilepsy if the first invasive monitoring procedure provided unclear results.

This is important, as epilepsy surgeons often face a dilemma on future treatment options once the first attempt at invasive neuromonitoring has failed. If elected to undergoing a second invasive surgery, the implantation of additional electrodes or SDG requires the patient to undergo another invasive monitoring surgery, thereby increasing the potential for surgical complications to occur. These include risks of infection, intracranial hematoma, intraparenchymal hemorrhage, permanent neurologic deficit, or death [7,8]. If a second SDG implant is performed, there is an increased risk of scar formation due to the larger craniotomy site, although this may be addressed by performing the less invasive SEEG implant [4]. A meta-analysis of 30 studies revealed that SEEG complications occurred with a prevalence of approximately 1.3% which is lower than SDG [11]. Main complications of these devices were hemorrhage and infection. In a prospective trial directly comparing depth electrodes to SDGs, the later were found to have the highest rate of complications (7.4%) [12]. The most common complication reported was hemorrhage. SEEG procedures have increased over the past decade overall when compared to SDG, potentially due to the minimally invasive nature of the procedure and its association with less complications [13].

When considering which device to use as a second invasive neuromonitoring technique, it should be determined on a case-by-case basis. One consideration for using an SDG implant after already performing an initial SDG, is that the grids may be unable to sample or measure the electrical activity of the deep cortex such as in the insula [14,15]. Therefore, adding an additional SDG may not have much added value as a second surgery. One way to achieve measurements at deeper brain structures is to consider using SEEG as a second surgery. If planting bilateral coverage of invasive neuromonitoring in a patient, SEEGs are also preferred [16].

Despite not being able to detect deeper brain structures and having slightly higher rates of hemorrhage, SDGs do carry advantages when compared to SEEG. They can sample large and diffuse anatomical areas of cortical activity on a continuous basis, allowing the epilepsy treatment team to detect epileptic spread across the cortex. Additionally, SDGs are advantageous when the foci are suspected to be in close proximity to eloquent brain cortex, as they offer better measurement of spatial anatomy to differentiate it from eloquent area [16].

Other issues to consider are that additional invasive monitoring surgeries do not guarantee that the seizure focus will be successfully localized. Rates of achieving seizure freedom in initial invasive monitoring while also undergoing subsequent resection range between 81% and 71% for SEEG and SDG respectively [17], and these rates of accuracy may be even lower for patients undergoing a second attempt at invasive localization. Patients may be hesitant to undergo an additional neurosurgical procedure and extend their length of stay in the hospital. With respect to this, SEEG is found to have shorter hospital length of stays when compared to SDG [18,19], and SEEG has lower rates of analgesic use [19]. Overall, SEEG was found to have similar costs to SDG [18].

Finally, it is worth noting that clinical data suggests that surgical treatment of intractable epilepsy is often delayed and underutilized [1,10], as several studies have shown that patients tend to overestimate the risks of epilepsy surgery [10]. In a study of repeat surgery for incomplete resection of epileptic foci, the authors found that repeat resection was effective in achieving seizure freedom, likely due to complete removal of the epileptic focus in the second surgery [20,21]. In contrast, a repeat surgery in the form of a second invasive monitoring implant has a much lower risk of complication compared to a second resection.

**Table 1**  
Patient Demographic and Clinical Characteristics

Patient	Age	1st	2nd	Localization	Surgery	Seizure Reduction
1	32	SEEG	SEEG	Right Amygdala	Temporal Lobectomy	>50%
2	40	SEEG	SEEG	None	None	N/A
3	31	SEEG	SEEG	Right Frontal Lobe	Frontal Lobectomy & RNS	100%
4	31	SEEG	SDG	Left Temporal Lobe	Temporal Lobectomy	>75%
5	28	SDG	SEEG	Left Temporal Lobe	Temporal Lobectomy	100%
6	38	SDG	SDG	Left Frontal Lobe	Frontal Resection	100%
7	27	SEEG	SDG	Left Posterior Temporal Lobe	Temporal Resection & RNS	>75%
8	40	SEEG	SEEG	Right Frontal SMA	Frontal Resection	0%
9	50	SEEG	SDG	Bilateral Temporal Lobes	Bilateral RNS	>50%
10	25	SEEG	SDG	Right Frontal SMA	Frontal Resection	100%

RNS – Responsive neurostimulation; SDG - Subdural grids; SEEG – Stereo-electroencephalography; SMA – Supplementary motor area.

#### 4.1. Limitations

We acknowledge that retrospective studies have inherent limitations, and that the small sample size in this study lowers external validity. Therefore, these results should be interpreted with reasonable caution. Future studies that are prospective and inclusive of a larger sample size could provide greater insight into the utility of an additional SEEG or SDG implantation for more complicated patients where seizure foci cannot be clearly identified after the initial invasive monitoring.

Additionally, due to institutional database limitations, the exact number of implanted electrodes per patient and SDG sizes were unable to be retrieved. This limitation of data makes it difficult to discern the true rate of successful localization of seizures, as many patients likely had more electrodes placed than others, which would theoretically lead to more successful localization. Future studies should measure both the number and locations of electrodes in addition to the size and location SDGs, and attempt to discover associations with successful localization.

#### 5. Conclusion

In conclusion, the results of our retrospective case series suggest that a second invasive neuromonitoring procedure can be safely performed to localize seizure foci in adult patients with long term epilepsy. Additionally, the potential benefits of a second invasive monitoring surgery to localize the epileptic foci outweigh the potential risks.

#### Ethical approval

This study was exempt from ethical board approval as this study used no identifying patient information.

#### Sources of funding

This research did not receive any specific grant from funding agencies in the public, commercial, or not-for-profit sectors.

#### Author contributions

Alvin Chan: study concept, data collection, writing the paper, Brian Lien, Nolan Brown: writing the paper. Julian Gendreau, Ryan Beyer, Chen Yang, Elliot Choi: editing the paper. Frank Hsu, Sumeet Vadera: supervision, editing the paper.

#### Registration of research studies

1. Name of the registry: Research Registry (<http://www.researchregistry.com>).
2. Unique Identifying number or registration ID: researchregistry7878.
3. Hyperlink to your specific registration: <https://www.researchregistry.com/browse-the-registry#home/registrationdetails/627476cda7d9c7001e441dcd/>

#### Guarantor

The guarantor is the one or more people who accept full responsibility for the work and/or the conduct of the study, had access to the data, and controlled the decision to publish. **Correspondence:** Alvin Chan MD, Department of Neurological Surgery, University of California, Irvine, 200 S. Manchester Avenue, Suite 201. Orange, CA 92868, Email: [alviny1@hs.uci.edu](mailto:alviny1@hs.uci.edu).

#### Consent

Informed verbal consent from all the patients was taken during their

admission and management at the health care center.

#### Provenance and peer review

Not commissioned, externally peer-reviewed.

#### Declaration of competing interest

There are no financial or personal relationships to disclose with any author.

#### Appendix A. Supplementary data

Supplementary data to this article can be found online at <https://doi.org/10.1016/j.amsu.2022.104139>.

#### References

- [1] D.J. Englot, A modern epilepsy surgery treatment algorithm: incorporating traditional and emerging technologies, *Epilepsy Behav.* 80 (2018) 68–74.
- [2] S. Kovac, V.N. Vakharia, C. Scott, et al., Invasive epilepsy surgery evaluation, *Seizure* 44 (2017) 125–136.
- [3] J.P. Mullin, D. Sexton, S. Al-Omar, et al., Outcomes of subdural grid electrode monitoring in the stereoelectroencephalography era, *World Neurosurg.* 89 (2016) 255–258.
- [4] S. Vadera, J. Mullin, J. Bulacio J, et al., Stereoelectroencephalography following subdural grid placement for difficult to localize epilepsy, *Neurosurgery* 72 (2013) 723–729.
- [5] R.A. Agha, C. Sohrabi, G. Mathew, et al., The PROCESS 2020 guideline: updating consensus preferred reporting of CasE series in surgery (PROCESS) guidelines, *Int. J. Surg.* 84 (2020) 231–235.
- [6] J. Gendreau, researchregistry7878. Research Registry, 2022. Accessible at: <https://www.researchregistry.com/browse-the-registry#home/registrationdetails/627476cda7d9c7001e441dcd/>.
- [7] H.E. Goldstein, B.E. Youngerman, B. Shao, et al., Safety and efficacy of stereoelectroencephalography in pediatric focal epilepsy: a single-center experience, *J. Neurosurg. Pediatr.* 22 (2018) 444–452.
- [8] J. Gonzalez-Martinez, J. Bulacio, A. Alexopoulos, et al., Stereoelectroencephalography in the “difficult to localize” refractory focal epilepsy: early experience from a North American epilepsy center, *Epilepsia* 54 (2013) 323–330.
- [9] E.F. Chang, D.J. Englot, S. Vadera, Minimally invasive surgical approaches for temporal lobe epilepsy, *Epilepsy Behav.* 47 (2015) 24–33.
- [10] J. Bjellvi, I. Olsson, K. Malmgren, et al., Epilepsy duration and seizure outcome in epilepsy surgery, *Neurology* 93 (2019) 159–166.
- [11] J.P. Mullin, M. Shriver, S. Alomar, et al., Is SEEG safe? A systematic review and meta-analysis of stereo-electroencephalography-related complications, *Epilepsia* 57 (2016) 386–401.
- [12] E. Hedegard, J. Bjellvi, A. Edelvik, et al., Complications to invasive epilepsy surgery workup with subdural and depth electrodes: a prospective population-based observational study, *J. Neurol. Neurosurg. Psychiatry* 85 (2014) 716–720.
- [13] H. Abou-Al-Shaar, A.A. Brock, B. Kundu, et al., Increased nationwide use of stereoelectroencephalography for intracranial epilepsy electroencephalography recordings, *J. Clin. Neurosci.* 53 (2018) 132–134.
- [14] S. Alomar, J.P. Mullin, S. Smithson, et al., Indications, technique, and safety profile of insular stereoelectroencephalography electrode implantation in medically intractable epilepsy, *J. Neurosurg.* 128 (2018) 1147–1157.
- [15] A.G. Weil, N.M. Le, P. Jayakar, et al., Medically resistant pediatric insular-opercular/perisylvian epilepsy. Part 2: outcomes following resective surgery, *J. Neurosurg. Pediatr.* 18 (2016) 523–535.
- [16] S. Kovac, V.N. Vakharia, C. Scott, et al., Invasive epilepsy surgery evaluation, *Seizure* 44 (2017) 125–136.
- [17] A. Talai, K. Eschbach, N.V. Stence, et al., Comparison of subdural grid and stereoelectroencephalography in a cohort of pediatric patients, *Epilepsy Res.* 177 (2021), 106758.
- [18] A. Salehi, P.H. Yang, M.D. Smyth, Single-center cost comparison analysis of stereoelectroencephalography with subdural grid and strip implantation, *J. Neurosurg. Pediatr.* 18 (2022) 1–7.
- [19] J.C. Hunsaker, J.P. Scoville, E. Joyce, et al., Stereotactic electroencephalography is associated with reduced opioid and nonsteroidal anti-inflammatory drug use when compared with subdural grids: a pediatric case series, *J. Clin. Neurosci.* 101 (2022) 180–185.
- [20] M. Fukuda, H. Masuda, H. Shirozu, et al., Additional resective surgery after the failure of initial surgery in patients with intractable epilepsy, *Neurol. Res.* 39 (2017) 1049–1055.
- [21] C.M. Reed, S. Dewar, I. Fried, et al., Failed epilepsy surgery deserves a second chance, *Clin. Neurol. Neurosurg.* 163 (2017) 110–115.