

UCSF

UC San Francisco Previously Published Works

Title

Neurological symptoms in individuals with fibrodysplasia ossificans progressiva.

Permalink

<https://escholarship.org/uc/item/85z1j3qt>

Journal

Journal of neurology, 259(12)

ISSN

0340-5354

Authors

Kitterman, Joseph A
Strober, Jonathan B
Kan, Lixin
[et al.](#)

Publication Date

2012-12-01

DOI

10.1007/s00415-012-6562-y

Peer reviewed



Published in final edited form as:

J Neurol. 2012 December ; 259(12): 2636–2643. doi:10.1007/s00415-012-6562-y.

Neurological symptoms in individuals with fibrodysplasia ossificans progressiva

Joseph A. Kitterman,

Department of Pediatrics, University of California San Francisco, Box 0734, San Francisco, CA 94143, USA

Cardiovascular Research Institute, University of California San Francisco, Box 0734, San Francisco, CA 94143, USA

Jonathan B. Strober,

Department of Pediatrics, University of California San Francisco, Box 0734, San Francisco, CA 94143, USA

Department of Neurology, University of California San Francisco, San Francisco, CA 94143, USA

Lixin Kan,

Department of Neurology, Northwestern University Feinberg School of Medicine, Chicago, IL, USA

David M. Rocke,

Division of Biostatistics, Department of Public Health Sciences, School of Medicine, University of California Davis, Davis, CA, USA

Department of Biostatistics, University of California Davis, Davis, CA, USA

Amanda Cali,

International Fibrodysplasia Ossificans Progressiva Association, Winter Springs, FL, USA

Jeannie Peeper,

International Fibrodysplasia Ossificans Progressiva Association, Winter Springs, FL, USA

Jennifer Snow,

International Fibrodysplasia Ossificans Progressiva Association, Winter Springs, FL, USA

Patricia L. R. Delai,

Orthopaedic Department of Santa Casa de Misericórdia de São Paulo School of Medicine, São Paulo, Brazil

Rolf Morhart,

Department of Pediatrics, Klinikum Garmisch-Partenkirchen GmbH, Garmisch-Partenkirchen, Germany

Robert J. Pignolo,

Department of Orthopaedic Surgery, Perelman School of Medicine, Center for Research in FOP and Related Disorders, University of Pennsylvania, Philadelphia, PA, USA

© Springer-Verlag 2012

Correspondence to: Joseph A. Kitterman, j-k-kitterman@att.net.

Co-submitted manuscript: CNS Demyelination in Fibrodysplasia Ossificans Progressiva by Kan L, et al.

Electronic supplementary material The online version of this article (doi:10.1007/s00415-012-6562-y) contains supplementary material, which is available to authorized users.

Conflicts of interest None.

Eileen M. Shore, and

Department of Orthopaedic Surgery, Perelman School of Medicine, Center for Research in FOP and Related Disorders, University of Pennsylvania, Philadelphia, PA, USA

Frederick S. Kaplan

Department of Orthopaedic Surgery, Perelman School of Medicine, Center for Research in FOP and Related Disorders, University of Pennsylvania, Philadelphia, PA, USA

Joseph A. Kitterman: j-k-kitterman@att.net

Abstract

Fibrodysplasia ossificans progressiva (FOP), a rare, disabling condition caused by gain-of-function mutations of a bone morphogenetic protein (BMP) type I receptor, leads to episodes of heterotopic ossification and resultant immobility. Neurological problems have not been associated with FOP, but neurological symptoms are commonly reported by FOP patients. To determine the prevalence of neurological symptoms and their characteristics in individuals with FOP, we conducted a survey of the 470 patient members of the International FOP Association (IFOPA) using a questionnaire about neurological symptoms. There were 168 responses (105 females, 63 males; age 1.5–68 years) from 30 countries representing 36 % of IFOPA members. Chronic neurological symptoms were reported by 86 (51 %). Prevalence of neuropathic pain (NP) was significantly increased ($P < 0.001$) compared to the general population, and tenfold more common in females (15 %) than males (1.6 %). Of those with NP, 94 % reported other sensory abnormalities. Prevalence of recurrent severe headaches (HA) (26 %) was similar to that in the general population, but prevalence in females with FOP (36 %) was almost fourfold greater than in males. Prevalence of NP, HA, and other sensory abnormalities was substantially higher in post-pubertal females; 33 % reported symptoms worsened during menstrual periods. Worsening of neurological symptoms during FOP flare-ups was reported by 23 %. Three patients with FOP (1.8 %) reported myoclonus, a prevalence much greater than reported in the general population ($P < 0.001$). Our worldwide survey indicates that neurological symptoms are common in FOP. We speculate that these symptoms are related to effects of dysregulated BMP signaling on the central and/or peripheral nervous systems.

Keywords

ACVR1; Bone morphogenetic protein 4; Substance P

Introduction

Fibrodysplasia ossificans progressiva (FOP) is an exceedingly rare disease with autosomal dominant inheritance and a worldwide point prevalence of ~1 case per 2 million population [1]. FOP is characterized by congenital malformations of the great toes (Fig. 1) and progressive heterotopic endochondral ossification with permanent loss of mobility [2]. The heterotopic ossification occurs episodically and begins as painful swellings (flare-ups) that progress to heterotopic bone formation (Fig. 2a, b). More than 700 cases have been identified worldwide. FOP is caused by gain-of-function mutations in a bone morphogenetic protein (BMP) type I receptor, ACVR1 (ALK2) [3], leading to dysregulated BMP signaling. At this time, there is no effective treatment [1].

In recent years, we have become aware of numerous individuals with FOP who have a wide array of neurological symptoms including recurrent severe headaches, sensory abnormalities, and movement disorders (e.g., seizures and myoclonus). However, there is little information in the literature about neurological problems in individuals with FOP. In 1982, Connor and Evans reported that of 34 cases of FOP, 1 had seizures, 1 had an

extradural hemorrhage, and 8 were deaf [4]. However, hearing loss in FOP is predominantly due to conductive, not neural, hearing loss [5]. In 2009, Kaplan and associates [6] reported patients with classic and atypical forms of FOP; one patient with classic FOP had a craniopharyngioma, and several patients with FOP variants had mild cognitive impairment. In 2010, Kumar and associates [7] described a case of FOP in a 3-year old boy who had an abnormal MRI of the brain with hyperintensity of the dentate nucleus of the cerebellum on T2-weighted images and suggested that FOP may be a multisystem disease with CNS involvement.

The paucity of information in the literature regarding involvement of the nervous system in FOP was inconsistent with our clinical experience with FOP patients. Therefore, we designed a survey to investigate the prevalence of neurological symptoms among individuals with FOP worldwide. The results of that survey form the basis for this article.

Methods

Questionnaire

We prepared a questionnaire to probe each individual's experience with neurological symptoms. The questionnaire requested detailed information about the neurological symptoms as well as demographic, diagnostic, and treatment information about each individual with FOP. The questionnaire was translated from English into French, German, Italian, Portuguese, and Spanish. The study was approved by the Committee on Human Research (CHR) of the University of California San Francisco. The CHR agreed that patient consent had been obtained when an individual had completed and returned the questionnaire.

Patient recruitment

The International FOP Association (IFOPA) is an association of 470 FOP patient members from 57 countries worldwide (185 patient members from the US and 285 from other countries). Together, these patients represent >90 % of the known cases of FOP worldwide. FOP was verified for all patients through previous physical examination by at least one of the authors (JAK, PLRD, RJP, or FSK), by another physician knowledgeable about FOP, or through review of their history, photographs, and radiographs. The questionnaire was posted on the IFOPA website and circulated to all patient members of the IFOPA (by email, or by postal mail for those without access to email). The questionnaire is attached as an ESM Appendix.

Data analysis

Completed questionnaires were returned to the IFOPA. All non-English questionnaires were translated into English before evaluation. We examined the data for the presence of any of the neurological symptoms included in the questionnaire. Headaches were included if they were recurrent and graded as >4 out of 10 in severity. We asked about specific diagnoses for the headaches (i.e., tension, migraine, or cluster headaches) that were given to the individual by a physician. Neuropathic pain was included only if the diagnosis was made by a physician. We included seizures only if they were recurrent. Movement disorders included tremors, myoclonus, athetosis, and cerebral palsy. We asked for a description and the location of sensory abnormalities. Injuries to brain and spinal cord included traumatic, infectious, hemorrhagic, or other.

Results were analyzed for the group as a whole, for females and males separately, and according to ages of the individuals. We calculated the prevalence of each individual symptom and compared these to data from the literature when such data were available. We

calculated gender differences for each of the neurological symptoms. Data were analyzed using the chi-square test and regression analysis as appropriate. Statistical significance was assumed for $P < 0.05$.

Results

Completed questionnaires were received from 168 individuals with FOP from 30 countries. The respondents represent 36 % of all patient members of the IFOPA; response rates from the USA (38 %) and from other countries (34 %) were similar. Respondents included 105 females (mean age 25 years, range 2–68 years) and 63 males (mean age 23 years, range 1.5–60 years).

The presence of at least one chronic neurological symptom was reported by 86 of the 168 respondents (51 %). Twenty of the 86 symptomatic individuals (23 %) reported that their symptoms worsened during flare-ups of FOP. The prevalence of neurological symptoms differed by gender, with 60 % of females and 41 % of males reporting at least one symptom ($P < 0.025$). A marked gender difference in symptoms was also noted when expressed by age. In females, the presence of neurological symptoms increased significantly with each decade of advancing age ($r = 0.802$, $P < 0.02$). In contrast, the percent of males with neurological symptoms decreased significantly with advancing age ($r = -0.875$, $P < 0.01$). To examine the possible role of puberty as a cause of the changes with age, we compared the presence of neurological symptoms for those age 0–12 years with those older than 12 years. Again, there was a marked gender difference. In females, the percent of those older than 12 years with neurological symptoms (64 %) was significantly greater than for those aged 0–12 years (22 %, $P < 0.005$). In males there was little difference between the age groups with symptoms present in 47 % of those age 0–12 years and 39 % of those older than age 12 ($P > 0.5$). Of 49 females aged 13–59 years who were not amenorrheic and who reported the presence of at least one neurological symptom, 16 (33 %) said that their symptoms worsened at the time of their menstrual periods.

Recurrent severe headaches

The prevalence of recurrent severe headaches in FOP was similar to that for the general population [8]; however, the percent of females with these headaches was almost four times more than for males (Table 1). The characteristics of the headaches were similar in females and males; median values were age of onset 15 years, severity 7.5/10, frequency 3/month, and duration 24 h. Among the 44 individuals with recurrent severe headaches, associated symptoms were common and included nausea, vomiting, and/or dizziness in 21 individuals. Precipitating factors were listed by 22 and included stress, loud noises, and light. An association with FOP flare-ups was reported by 9; an association of the headaches with their menstrual cycles was reported by 10 of the 36 females more than 12 years of age. Twenty-one individuals had consulted doctors about their headaches, but only 15 were given a specific diagnosis including migraines ($n = 10$), cluster headaches ($n = 1$), tension-type headaches ($n = 1$), and other ($n = 3$). Only eight had further evaluation including EEG ($n = 3$), CT scan ($n = 6$), and MRI ($n = 5$). For treatment of their headaches, 28 (64 %) used non-steroidal anti-inflammatory drugs (NSAIDs), only 4 used narcotics, and 3 of the 10 diagnosed with migraines used anti-migraine medications.

Neuropathic pain

In FOP, the prevalence of neuropathic pain diagnosed by a physician was markedly greater than that reported for the general population [9], and in this study of those with FOP, this symptom was reported almost exclusively by females (Table 1). Most individuals who had been diagnosed with neuropathic pain described several types of pain; most commonly the

pains were in the legs and feet (Table 2). Among medications, NSAIDs were the most effective pain relievers in 53 %. Narcotics were effective in only one individual and were ineffective in relieving neuropathic pain in three individuals (18 %). Four (24 %) found gabapentin and/or pregabalin to be ineffective, whereas only one found them effective. Of 17 individuals with FOP who reported neuropathic pain, 94 % reported the presence of other sensory abnormalities.

Other sensory abnormalities

Other sensory abnormalities were reported by 45 % of females and 22 % of males (Table 1). Both genders gave similar descriptions of the abnormal sensations. The most common were numbness, tingling, hypersensitivity to touch (allodynia), and abnormal sensations of heat or cold. The most common locations were the legs and feet, and the arms and hands (Table 2). We could find no reports in the literature for the prevalence of other sensory abnormalities in the general population.

Other neurological symptoms

The presence of recurrent seizures, movement disorders, and injuries to the brain or spinal cord were similar among females and males (Table 1). The percent of those with FOP reporting seizures was similar to that for the general population [10]. Injuries to the brain or spinal cord occurred in 13 individuals (7.7 %), a percentage similar to that reported previously for FOP patients who had suffered severe head injuries from falls [11] (Table 1). Movement disorders were reported by 12 individuals (Table 1). A variety of movement disorders was described; however, the only types that were reported by more than one individual were tremors (in two individuals) and myoclonus (in three individuals). This represents a prevalence of myoclonus of 1.8 % in FOP, much greater than the reported prevalence of myoclonus in the general population (8.6 per 100,000; $P < 0.001$) [12]. Interestingly, two of the three individuals with myoclonus in this study have been diagnosed by neurologists with propriospinal myoclonus, an unusual type of myoclonus [13]; both individuals are young women in their early 20s. In one, the myoclonus was due to spinal cord injury resulting from marked kyphosis in the lower cervical spine; the cause of myoclonus in the other young woman is unknown. We could find no reports in the literature of the overall prevalence of movement disorders in the general population.

Discussion

Although FOP is characterized as a rare and disabling genetic disorder of progressive heterotopic ossification, our study indicates that chronic neurological symptoms are exceedingly prevalent in this patient population. The current study was undertaken because neurological symptoms were reported to us by numerous FOP patients. The 168 completed questionnaires from FOP patients represent 36 % of the IFOPA membership, 38 % of the US membership, and 34 % of the membership from 29 other countries. Ages of the respondents ranged from 1.5 to 68 years. Thus, there is broad geographical and age distribution, which provides a representative picture of those with FOP.

Results regarding the different neurological symptoms merit comment. The percent of FOP patients with recurrent severe headaches is similar to that reported for the general population (Table 1) [8]. However, significantly more females than males reported headaches, a finding similar to that for the general population [8]. Therefore, FOP does not seem to increase the prevalence of severe headaches. In contrast, the prevalence of neuropathic pain in FOP was 20 times greater than that reported for the general population [9], and in FOP patients this symptom occurred almost exclusively in females (Table 1). Similarly, other sensory abnormalities were significantly more common in females. In contrast, there were no gender

differences for seizures, movement disorders, or injuries to the brain or spinal cord (Table 1). Therefore, the increased prevalence in females was seen only in neurological symptoms that were sensory in nature. These gender differences could be explained by the lower threshold for pain in females [14]. Published reports have suggested various reasons for this gender difference in pain sensation including hormonal, socio-cultural, psychological, experiential, and genetic factors [15, 16]. In the current study, involvement of hormonal factors is strongly suggested by several factors, including the significant increase in neurological symptoms with advancing age in females, the significantly higher percentage of symptomatic females over the age of 12 years compared to younger females, and the finding that 33 % of symptomatic females aged 13–59 noted worsening of their symptoms at the time of their menstrual periods. The association of the menstrual cycle with worsening symptoms has previously been noted for headaches [17] and seizures [18]. These findings strongly suggest that hormonal factors may influence the metabolism of BMP4 or the activity of the mutated ACVR1, the genetic cause of FOP [3].

Most individuals with FOP who have recurrent severe headaches and/or neuropathic pain reported that they take medications to relieve their symptoms. The most commonly used medications are NSAIDs. Very few use narcotics. Gabapentin and pregabalin are widely prescribed for neuropathic pain. It is noteworthy that in the current study four individuals with neuropathic pain reported that these agents are ineffective, and only one has found them to be effective. The common use of NSAIDs for neurological complaints, especially selective COX-2 inhibitors, can be anecdotally attributed to their effectiveness in relieving symptoms. Their efficacy may be related to the inhibition of inflammatory prostaglandins, inhibition of heterotopic ossification [19], or anti-angiogenic effects [20]. It is interesting that inflammatory prostaglandin levels are dramatically elevated in the plasma of patients who have FOP [21]. Therefore, some of the relief gained by NSAID use may be ascribed to reduction in inflammatory responses that irritate or injure nervous tissue.

Among those who were diagnosed with neuropathic pain, 94 % reported other sensory abnormalities including numbness, tingling, allodynia, and abnormal sensations of heat and/or cold. These findings in FOP patients are remarkably similar to those of Maier and associates [22] who studied 1,236 individuals with neuropathic pain and reported that 92 % had sensory abnormalities. In our study, the most common locations for both neuropathic pain and the other sensory abnormalities were the legs and feet (Table 2), similar to the locations reported by Dieleman and associates [9] in a study of neuropathic pain in the general population. One factor that has been suggested as the cause of neuropathic pain and the associated other abnormal sensations in FOP is nerve irritation or entrapment by heterotopic bone. However, in individuals with FOP, the location of neuropathic pain, the percent of those with neuropathic pain who have other sensory abnormalities, and the types of these sensory abnormalities are very similar to results reported previously for individuals who do not have FOP [9, 22]. Therefore, it seems unlikely that these symptoms in FOP are due to nerve involvement by heterotopic bone, but rather they are probably due to effects of FOP on the nervous system. However, because we do not have information regarding the extent of heterotopic ossification in the individuals who returned completed questionnaires, we cannot rule out an effect of heterotopic bone on peripheral nerves as a cause of at least some of the cases of neuropathic pain.

The prevalence of movement disorders was low, with no gender difference. However, three individuals reported myoclonus, including two young women diagnosed with propriospinal myoclonus. This unusual form of myoclonus most commonly results from spinal injury [13], which was the cause in one of the two FOP patients; the cause in the other patient is unknown. The co-existence of two very rare conditions, FOP and propriospinal myoclonus, in these two patients suggests that the two diseases may be related.

We do not know the reasons for the increased prevalence in FOP of neuropathic pain and other sensory abnormalities, the pronounced female-to-male ratio of these conditions and of recurrent severe headaches, or the occurrence of an unusual form of myoclonus. Studies published over the past few years provide possible clues.

The genetic cause of FOP is an activating mutation in the BMP type 1 receptor, ACVR1/ALK2 [3], leading to dysregulated BMP signaling [23]. Levels of BMP4 and its mRNA are elevated in cultured lymphocytes from FOP patients [24]. Osteogenic progenitor cells from individuals with FOP show ligand-independent BMP signaling and ligand-dependent hyperresponsiveness to BMP stimulation [25]. BMPs inhibit differentiation of oligodendrocyte precursor cells (OPCs) into mature oligodendrocytes in vitro, and this effect can be reversed by the BMP receptor antagonist, Noggin [26]. Similar effects are seen in cells from brains of transgenic mice (NSE-BMP4) that overexpress BMP4 [27]. In the brains of mice with cuprizone-induced demyelination, BMP4 increases the proliferation of OPCs, but not mature oligodendrocytes; infusion of Noggin increases the density of mature oligodendrocytes and produces an increase in remyelinated axons [28]. Transgenic NSE-BMP4 mice develop heterotopic ossification similar to human FOP [29]. Their brains show increased density of astrocytes and decreased density of oligodendrocytes, but no changes in the developmental pattern of myelination [27]. In a companion study to this report, Kan and associates report that the NSE-BMP4 transgenic mice and knock-in mice with the identical mutation (ACVR1/ALK2 c.617G>A; R206H) that occurs in classic FOP patients have acquired demyelinating lesions in the central nervous system that, on MRI, appear similar to lesions seen in the brain and spinal cord of some individuals with FOP.¹ These studies show that BMP4 has significant effects on the developing brain and may interfere with remyelination following neural injury, and these effects may contribute to the neurological symptoms in FOP.

Recently, Kan and associates [30] reported that the proinflammatory neuropeptide, Substance P, is present in tissue from early stage lesions in individuals with FOP or with acquired heterotopic ossification. Using three different transgenic mouse models, they demonstrated that Substance P initiates a neuro-inflammatory cascade that leads to heterotopic ossification. Substance P is involved in nociception and is released at sensory nerve endings. Therefore, it is noteworthy that the most prominent neurological symptoms in those with FOP are sensory and mostly involve pain. Twenty-three percent of FOP patients reported that their neurological symptoms worsened during flare-ups of their FOP, a time when both BMP4 and Substance P have been shown to be elevated [24, 30]. Therefore, it seems likely that dysregulated BMP signaling and possibly Substance P participate not only in the heterotopic ossification seen in FOP, but also in causing the neurological symptoms through their effects on the central and peripheral nervous systems.

The major limitation to the current study is that the data have been obtained by questionnaire. Therefore, the validity of the results depends upon the accuracy of each patient's memory, their understanding of their medical condition, and that those responding are a representative sample of the entire FOP population. We cannot rule out bias in the responses and that those with neurological symptoms were more likely to respond than those who were symptom free. There are indications in the results that ascertainment bias is not a major problem. The prevalence of recurrent severe headaches and that of seizures in FOP are similar to those reported for the general population [8, 10]. Furthermore, in FOP the percent of individuals with neuropathic pain who reported other sensory abnormalities (94 %) is almost identical to that previously reported for those with neuropathic pain who do not

¹Kan L, Kitterman JA, Procissi D, Chakkalakal S, McGuire TL, Goldsby RE, Pignolo RJ, Shore EM, Kaplan FS, Kessler, JA (2012) CNS demyelination in fibrodysplasia ossificans progressiva. Submitted to Journal of Neurology as a companion paper to this paper.

have FOP (92 %), and the types of sensory abnormalities are very similar to those reported previously [22]. Furthermore, it is unlikely that the very high prevalence of neuropathic pain, 20 times the reported prevalence in the general population [9], can be explained by ascertainment bias. Questionnaires have been used extensively to study FOP, including the natural history of heterotopic ossification [31], the pattern of joint involvement [32], the likelihood of permanent heterotopic ossification after immunization injections [33], restriction of jaw movement after injection of local anesthetic [34], the relationship of viral illnesses to FOP flare-ups [35], and the prevalence of diagnostic errors [36] among individuals with FOP.

In conclusion, individuals with FOP report a high prevalence of neurological symptoms including recurrent severe headaches, neuropathic pain, other sensory abnormalities, and myoclonus. Data from in vitro studies, in vivo studies in BMP4 transgenic and FOP knock-in mice, and in individuals with FOP indicate that the neurological symptoms in FOP may be due to effects of dysregulated BMP signaling on the central and peripheral nervous systems and may be mediated by the proinflammatory neuropeptide, Substance P. Additional research is needed to confirm this and to determine if interventions specifically aimed at abrogating BMP signaling and Substance P signaling may be effective in relieving the neurological symptoms in FOP as well as preventing the heterotopic ossification of FOP.

Supplementary Material

Refer to Web version on PubMed Central for supplementary material.

Acknowledgments

The authors thank the FOP patients and their families who participated in this study, and the staff members of the IFOPA who provided assistance with the study. This study was supported in part by the International Fibrodysplasia Ossificans Progressiva Association, the Center for Research in FOP and Related Disorders, the Ian Cali Endowment for FOP Research, the Whitney Weldon Endowment for FOP Research, the Isaac and Rose Nassau Professorship of Orthopaedic Molecular Medicine (to FSK), the Penn Center for Musculoskeletal Disorders, and the National Institutes of Health (NIH R01-AR41916).

References

1. Kaplan FS, Le Merrer M, Glaser DL, Pignolo RJ, Goldsby R, Kitterman JA, Groppe J, Shore EM. Fibrodysplasia ossificans progressiva. *Best Pract Res Clin Rheumatol*. 2008; 22:191–205. [PubMed: 18328989]
2. Kaplan FS, Glaser DL, Shore EM, Deirmengian GK, Gupta R, Delai P, Morhart R, Smith R, Le Merrer M, Rogers JG, Connor JM, Kitterman JA. The phenotype of fibrodysplasia ossificans progressiva. *Clin Rev Bone Miner Metab*. 2005; 3–4:183–188.
3. Shore EM, Xu M, Feldman GJ, Fenstermacher DA, Cho TJ, Choi IH, Connor JM, Delai P, Glaser DL, Le Merrer M, Morhart R, Rogers JG, Smith R, Triffitt JT, Urtizberea JA, Zasloff M, Brown MA, Kaplan FS. A recurrent mutation in the BMP type I receptor ACVR1 causes inherited and sporadic fibrodysplasia ossificans progressiva. *Nat Genet*. 2006; 38:525–527. [PubMed: 16642017]
4. Connor JM, Evans DAP. Fibrodysplasia ossificans progressiva. The clinical features and natural history of 34 patients. *J Bone Jt Surg Br*. 1982; 64:76–83.
5. Levy C, Lash AT, Janoff HN, Kaplan FS. Conductive hearing loss in individuals with fibrodysplasia ossificans progressiva. *Am J Audiol*. 1999; 8:29–33. [PubMed: 10499116]
6. Kaplan FS, Xu M, Seemann P, Connor JM, Glaser DL, Carroll L, Delai P, Fastnacht-Urban E, Forman SJ, Gillissen-Kaesbach G, Hoover-Fong J, Köster B, Pauli RM, Reardon W, Zaidi S, Zasloff M, Morhart R, Mundlos S, Groppe J, Shore EM. Classic and atypical fibrodysplasia ossificans progressiva phenotypes are caused by mutations in the bone morphogenetic protein type 1 receptor ACVR1. *Hum Mutat*. 2009; 30:379–390. [PubMed: 19085907]

7. Kumar S, Keerthiraj B, Kesavadas C. Teaching Neuro-Images: MRI in fibrodysplasia ossificans progressiva. *Neurology*. 2010; 74:e20. [PubMed: 20142609]
8. Rasmussen BK, Jensen R, Schroll M, Olesen J. Epidemiology of headache in a general population—A prevalence study. *J Clin Epidemiol*. 1991; 44:1147–1157. [PubMed: 1941010]
9. Dieleman JP, Kerklaan J, Huygen FJ, Bouma PA, Sturkenboom MC. Incidence rates and treatment of neuropathic pain conditions in the general population. *Pain*. 2008; 137:681–688. [PubMed: 18439759]
10. Mohammadi MR, Ghanizadeh A, Davidian H, Mohammadi M, Norouzi M. Prevalence of epilepsy and comorbidity of psychiatric disorders in Iran. *Seizure*. 2006; 15:476–482. [PubMed: 16931061]
11. Glaser DL, Rocke DM, Kaplan FS. Catastrophic falls in patients who have fibrodysplasia ossificans progressiva. *Clin Orthop Relat Res*. 1998; 346:110–116. [PubMed: 9577417]
12. Caviness JN, Alving LI, Maraganore DM, Black RA, McDonnell SK, Rocca WA. The incidence and prevalence of myoclonus in Olmsted County, Minnesota. *Mayo Clin Proc*. 1999; 74:565–569. [PubMed: 10377930]
13. Brown P, Rothwell JC, Thompson PD, Marsden CD. Propriospinal myoclonus: evidence for spinal “pattern” generators in humans. *Mov Disord*. 1994; 9:571–576. [PubMed: 7990853]
14. Walker JS, Carmody JJ. Experimental pain in healthy human subjects: gender differences in nociception and in response to ibuprofen. *Anesth Analg*. 1998; 86:1257–1262. [PubMed: 9620515]
15. Mogil JS, Bailey AL. Sex and gender differences in pain and analgesia. *Prog Brain Res*. 2010; 186:141–157. [PubMed: 21094890]
16. Jazin E, Cahill L. Sex differences in molecular neuroscience: from fruit flies to humans. *Nat Rev Neurosci*. 2010; 11:9–17. [PubMed: 20019686]
17. Silberstein SD, Merriam GR. Sex hormones and headache. *J Pain Symptom Manage*. 1993; 8:98–114. [PubMed: 8492007]
18. Foldvary-Schaeffer N, Harden C, Herzog A, Falcone T. Hormones and seizures. *Cleve Clin J Med*. 2004; 71(suppl 2):S11–S18. [PubMed: 15379295]
19. DiCesare PE, Nimni ME, Peng L, Yazdi M, Cheung DT. Effects of indomethacin on demineralized bone-induced heterotopic ossification in the rat. *J Orthop Res*. 1991; 9:855–861. [PubMed: 1919848]
20. Iñiguez MA, Rodriguez A, Volpert OV, Fresno M, Redondo JM. Cyclooxygenase-2: a therapeutic target in angiogenesis. *Trends Mol Med*. 2003; 9:73–78. [PubMed: 12615041]
21. Levitz CL, Cohen RB, Zasloff MA, Kaplan FS. The role of prostaglandins in the pathogenesis of fibrodysplasia ossificans progressiva. *Calcif Tissue Int*. 1992; 50:387. (Abstract).
22. Maier C, Baron R, Tölle TR, Binder A, Birbaumer N, Birklein F, Gierthmühlen J, Flor H, Geber C, Hüge V, Krumova EK, Landwehrmeyer GB, Magerl W, Maihöfner C, Richter H, Rolke R, Scherens A, Schwarz A, Sommer C, Tronnier V, Üçeyler N, Valet M, Wasner G, Treede R-D. Quantitative sensory testing in the German research network on neuropathic pain: somatosensory abnormalities in 1236 patients with different neuropathic pain syndromes. *Pain*. 2010; 150:439–450. [PubMed: 20627413]
23. Shen Q, Little SC, Xu M, Haupt J, Ast C, Katagiri T, Mundlos S, Seemann P, Kaplan FS, Mullins MC, Shore EM. The fibrodysplasia ossificans progressiva R206H ACVR1 mutation activates BMP-independent chondrogenesis and zebrafish embryo ventralization. *J Clin Invest*. 2009; 119:3462–3472. [PubMed: 19855136]
24. Shafritz AB, Shore EM, Gannon FH, Zasloff MA, Taub R, Muenke M, Kaplan FS. Overexpression of an osteogenic morphogen in fibrodysplasia ossificans progressiva. *New Engl J Med*. 1996; 335:555–561. [PubMed: 8678932]
25. Billings PC, Fiori JL, Brentwood JL, O’Connell MP, Jiao X, Nussbaum B, Caron RJ, Shore EM, Kaplan FS. Dysregulated BMP signaling and enhanced osteogenic differentiation of connective tissue progenitor cells from patients with fibrodysplasia ossificans progressiva. *J Bone Miner Res*. 2008; 23:305–313. [PubMed: 17967130]
26. Wang Y, Cheng X, He Q, Zheng Y, Kim DH, Whittemore SR, Cao QL. Astrocytes from contused spinal cord inhibit oligodendrocyte differentiation of adult oligodendrocyte precursor cells by

- increasing the expression of bone morphogenetic proteins. *J Neurosci.* 2011; 31:6053–6058. [PubMed: 21508230]
27. Gomes WA, Mehler MF, Kessler JA. Transgenic overexpression of BMP4 increases astroglial and decreases oligodendroglial lineage commitment. *Dev Biol.* 2003; 255:164–177. [PubMed: 12618141]
 28. Sabo JK, Aumann TD, Merlo D, Kilpatrick TJ, Cate HS. Remyelination is altered by bone morphogenetic protein signaling in demyelinated lesions. *J Neurosci.* 2011; 31:4504–4510. [PubMed: 21430151]
 29. Kan L, Hu M, Gomes WA, Kessler JA. Transgenic mice overexpressing BMP4 develop a fibrodysplasia ossificans progressiva (FOP)-like phenotype. *Am J Pathol.* 2004; 165:1107–1115. [PubMed: 15466378]
 30. Kan L, Lounev VY, Pignolo RJ, Duan L, Liu Y, Stock SR, McGuire TL, Lu B, Gerard NP, Shore EM, Kaplan FS, Kessler JA. Substance P signaling mediates BMP-dependent heterotopic ossification. *J Cell Biochem.* 2011; 112:2759–2772. [PubMed: 21748788]
 31. Cohen RB, Hahn GV, Tabas JA, Peeper J, Levitz CL, Sando A, Sando N, Zasloff MA, Kaplan FS. The natural history of heterotopic ossification in patients who have fibrodysplasia ossificans progressiva. *J Bone Jt Surg Am.* 1993; 75:215–219.
 32. Rocke DM, Zasloff M, Peeper J, Cohen RB, Kaplan FS. Age- and joint-specific risk of initial heterotopic ossification in patients with fibrodysplasia ossificans progressiva. *Clin Orthop Relat Res.* 1994; 301:243–248. [PubMed: 8156682]
 33. Lanchoney TF, Cohen RB, Rocke DM, Zasloff MA, Kaplan FS. Permanent heterotopic ossification at the injection site after diphtheria-tetanus-pertussis immunizations in children who have fibrodysplasia ossificans progressiva. *J Pediatr.* 1995; 126:762–764. [PubMed: 7752003]
 34. Luchetti W, Cohen RB, Hahn GV, Rocke DM, Helpin M, Zasloff M, Kaplan FS. Severe restriction in jaw movement after routine injection of local anesthetic in patients who have fibrodysplasia ossificans progressiva. *Oral Surg Oral Med Oral Pathol Oral Radiol Endod.* 1996; 81:21–25. [PubMed: 8850477]
 35. Scarlett RF, Rocke DM, Kantanie S, Patel JB, Shore EM, Kaplan FS. Influenza-like viral illnesses and flare-ups of fibrodysplasia ossificans progressiva. *Clin Orthop Relat Res.* 2004; 423:275–279. [PubMed: 15232462]
 36. Kitterman JA, Kantanie S, Rocke DM, Kaplan FS. Iatrogenic harm caused by diagnostic errors in fibrodysplasia ossificans progressiva. *Pediatrics.* 2005; 116:e654–e661. [PubMed: 16230464]

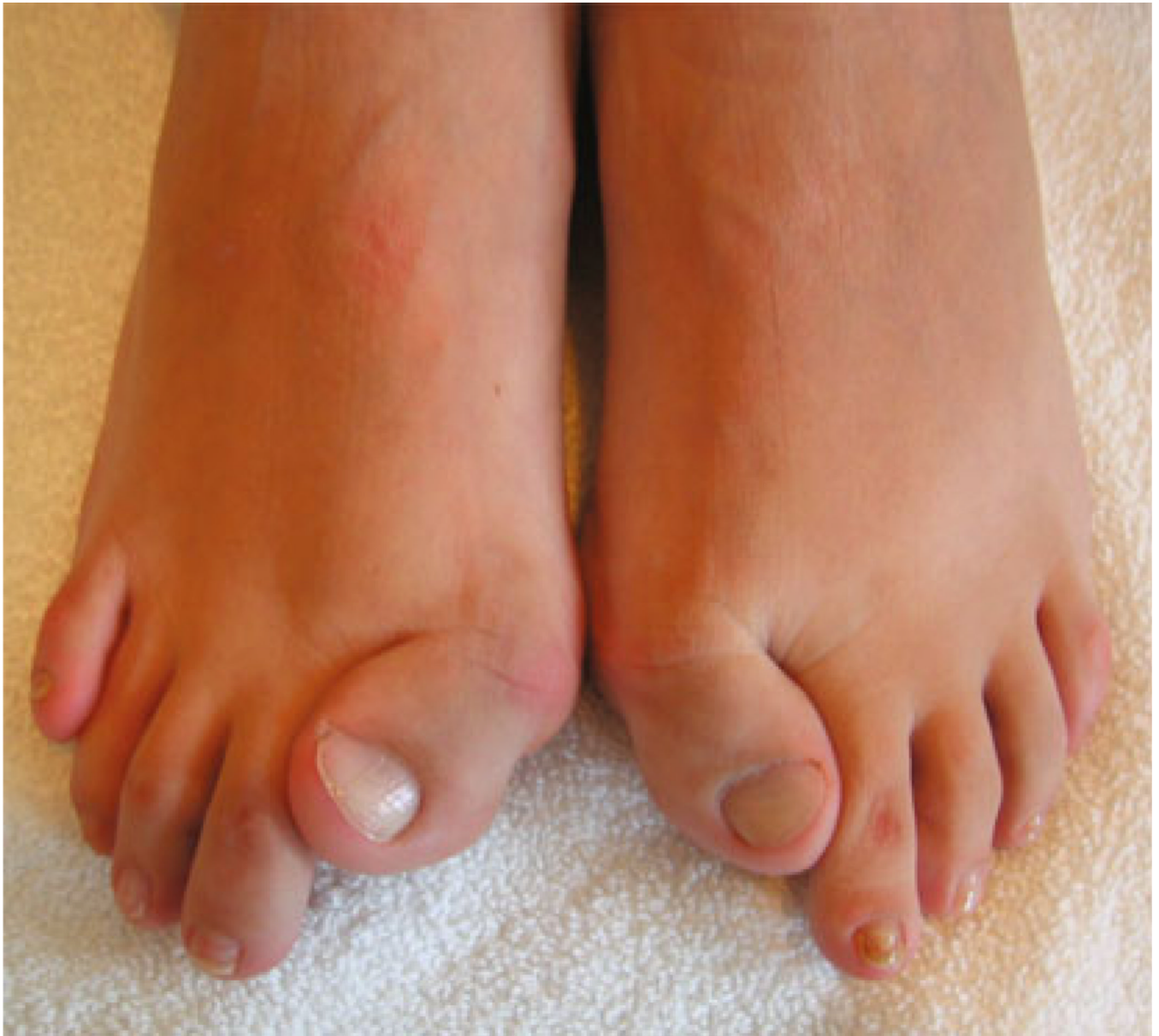

Fig. 1. Malformation of the great toes in an individual with fibrodysplasia ossificans progressiva (FOP). The great toes are short with hallux valgus

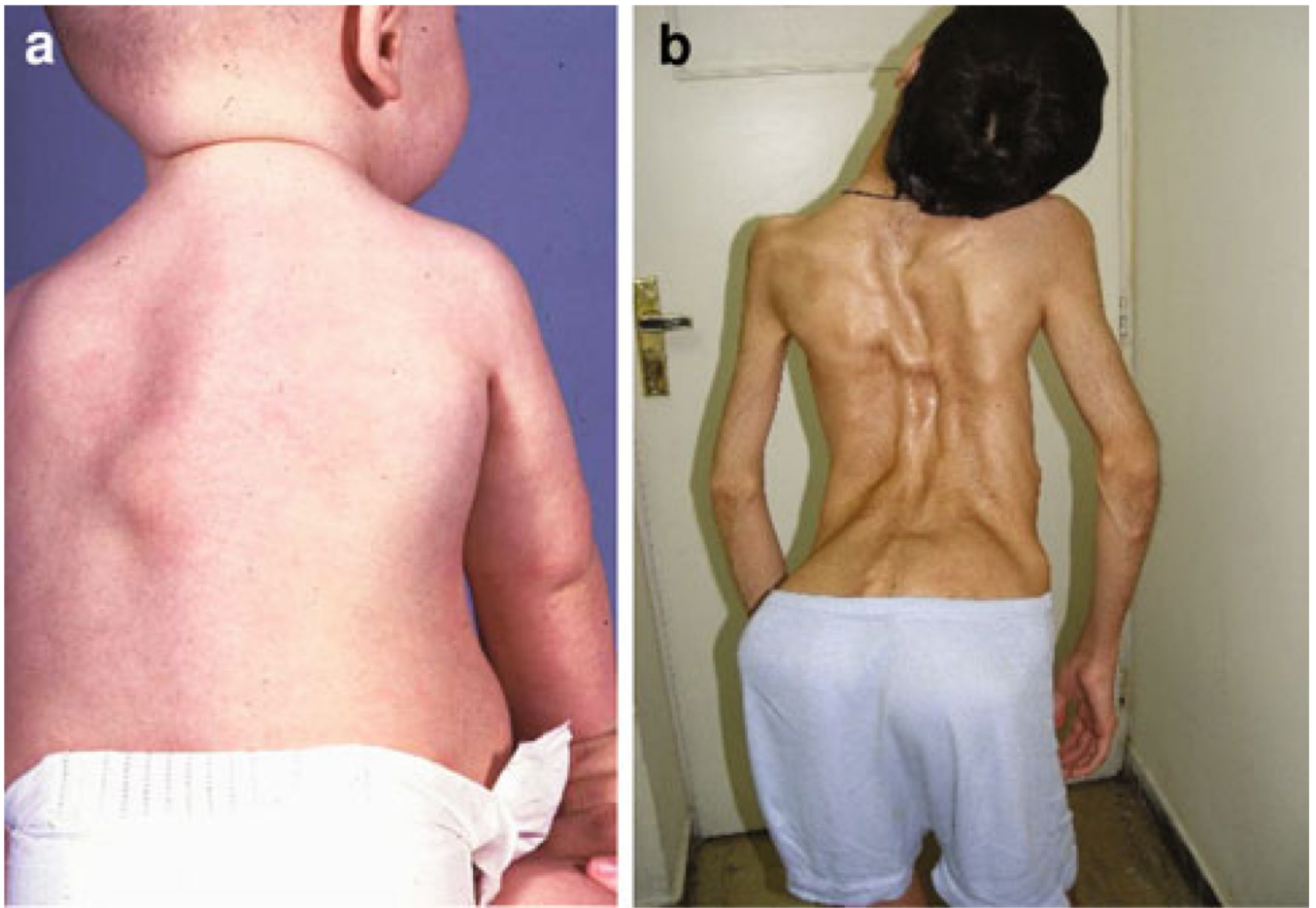


Fig. 2. Heterotopic Ossification in FOP. **a** Early FOP lesion (flare-up) in the middle of an infant's back. **b** Ribbons of heterotopic bone in the back of a young man with FOP. Multiple flare-ups have led to extensive heterotopic bone leading to lordosis, scoliosis, and immobilization of the back

Table 1
Prevalence of individual neurological symptoms among 105 females and 63 males with fibrodysplasia ossificans progressiva

Symptom	Females (n = 105)	Males (n = 63)	P*	All (n = 168)	Incidence [reference]	P†
Recurrent severe headaches	38 (36.2 %)	6 (9.5 %)	<0.001	44 (26.2 %)	36.0 % [8]	<0.10, >0.05
Neuropathic pain	16 (15.2 %)	1 (1.6 %)	<0.005	17 (10.1 %)	0.8 % [9]	<0.001
Other sensory abnormalities	47 (44.8 %)	14 (22.2 %)	<0.005	61 (36.3 %)	–	–
Recurrent seizures	3 (2.8 %)	1 (1.6 %)	>0.5	4 (2.4 %)	1.8 % [10]	>0.5
Movement disorders	8 (7.6 %)	4 (6.3 %)	>0.75	12 (7.1 %)	–	–
Injuries to brain or S/C	7 (6.7 %)	6 (9.5 %)	>0.5	13 (7.7 %)	10 % [11]	>0.10

S/C spinal cord

* Comparison between females and males

† Comparison between results for all respondents and data from the literature

Table 2

Characteristics of (A) neuropathic pain and (B) sensory abnormalities in individuals with fibrodysplasia ossificans progressiva

	<i>n</i>	Frequency (%)
(A) Neuropathic pain		
Type of pain		
Sharp/stabbing	11	64.7
Shooting/radiating	10	58.8
Burning	9	52.9
Dull, aching	9	52.9
Cramping	4	23.5
Location of pain		
Legs and/or feet	13	82.4
Head, neck and/or back	8	47.1
Arms and/or hands	6	35.3
(B) Sensory abnormalities		
Type of abnormal sensation		
Numbness	37	60.6
Tingling	31	50.8
Hypersensitivity to touch (allodynia)	19	31.1
Heat and/or cold	14	23.0
Location		
Legs and/or feet	39	63.9
Arms and/or hands	26	42.6
Head, neck and/or back	12	19.7

The total numbers for types of pain and their locations are more than the number of individuals because several listed more than one type of pain and location