

# UCSF

## UC San Francisco Previously Published Works

### Title

Evaluation and Management of Anal Intraepithelial Neoplasia in HIV-Negative and HIV-Positive Men Who Have Sex with Men

### Permalink

<https://escholarship.org/uc/item/86w6m7wz>

### Journal

Current Infectious Disease Reports, 12(2)

### ISSN

1523-3847

### Authors

Park, Ina U  
Palefsky, Joel M

### Publication Date

2010-03-01

### DOI

10.1007/s11908-010-0090-7

Peer reviewed

# Evaluation and Management of Anal Intraepithelial Neoplasia in HIV-Negative and HIV-Positive Men Who Have Sex with Men

Ina U. Park · Joel M. Palefsky

Published online: 24 February 2010

© The Author(s) 2010. This article is published with open access at Springerlink.com

**Abstract** The incidence of human papillomavirus (HPV)–associated anal cancer in men who have sex with men (MSM) is striking and has not been mitigated by the use of highly active antiretroviral therapy. Detection and treatment of high-grade anal intraepithelial neoplasia (HGAIN) may reduce the incidence of anal cancer. Anal cytology is a useful tool to detect HGAIN; annual screening of HIV-positive MSM and biennial screening of HIV-negative MSM appears to be cost-effective. MSM with abnormal cytology should be referred for high-resolution anoscopy and biopsy. Individuals with HGAIN should receive treatment; treatment modalities for HGAIN demonstrate moderate efficacy and are usually well tolerated, but greater study is required to determine which treatment is optimal. Large prospective studies are needed to document the efficacy of screening and treatment of HGAIN on anal cancer incidence. The HPV vaccine holds promise for primary prevention of anal cancer in MSM, but significant implementation challenges remain.

**Keywords** Anal intraepithelial neoplasia · Anal cancer · Prevention · HIV · Human papillomavirus · Screening

## Introduction

Anal cancer occurs at alarming rates in HIV-positive and HIV-negative men who have sex with men (MSM)

I. U. Park (✉)

Department of Family and Community Medicine,  
University of California San Francisco,  
San Francisco, CA 94143, USA  
e-mail: parki@fcm.ucsf.edu

J. M. Palefsky

Department of Medicine,  
University of California San Francisco,  
San Francisco, CA 94143, USA  
e-mail: palefskyj@gcrc.ucsf.edu

compared with the general population. According to recent data from the United States and Europe, the incidence of anal cancer among HIV-positive individuals ranges from 42 to 137 cases per 100,000 person-years, a rate that is 30 to 100 times higher than that of the general population [1•, 2•, 3•, 4•, 5]. Even before the HIV epidemic, anal cancer incidence among MSM was estimated to be as high as about 35 cases per 100,000 person-years, which is comparable to the incidence of cervical cancer in the United States before the advent of routine cervical cytology screening [6]. Anal cancer pathogenesis is similar to that of cervical cancer, including a causative association with the human papillomavirus (HPV) [7•]. Persistence of oncogenic HPV infection is thought to be a necessary factor in the development of anal cancer and high-grade anal intraepithelial neoplasia (HGAIN), the putative anal cancer precursor.

Unlike cervical HPV infection, which peaks in the third decade in women, anal HPV infection is highly prevalent throughout adult life among MSM well into the sixth decade [8, 9]. Among HIV-positive MSM, the prevalence of anal HPV infection ranges between 72% and 90%, whereas among HIV-negative MSM, the prevalence ranges from 57% to 61% [10, 11•]. Consistent with the high prevalence of anal HPV infection, HGAIN is highly pervasive among HIV-positive MSM, with a prevalence of 43% to 52% and an incidence of 49% over 4 years [12, 13]. Though less widespread, HGAIN among HIV-negative MSM is still substantial, with a prevalence of 25% and incidence of 17% over 4 years [11•, 12].

If left untreated, HGAIN has demonstrated potential for malignant transformation [14, 15]. Even with surveillance and treatment of HGAIN, malignancy can develop, especially in immunosuppressed individuals with extensive disease [16]. In HIV-positive individuals, restoration of immune function such as that afforded by highly active antiretroviral therapy (HAART) has not demonstrated

substantial benefit in reducing incidence of HGAIN or regression of existing high-grade lesions [2••, 17]. Several studies have demonstrated a higher incidence of anal cancer since the introduction of HAART compared with the pre-HAART era [1••, 18]. This may be attributable to increased survival on HAART allowing HIV-positive individuals to live with oncogenic HPV infection long enough to develop HGAIN and anal cancer.

## Screening

The goal of anal cancer screening is similar to that of cervical cancer screening, namely, to identify and treat HGAIN before the development of cancer. Cytology is the primary screening tool for detection of HPV-associated disease in the anus. The cytology technique is simple and can easily be performed in the context of an office visit. Although anal cytology is typically performed by clinicians, patient self-collected anal cytology has also been evaluated. Self-collected specimens offer the advantage of convenience and privacy, are acceptable to patients, and have been used for rectal specimens to screen for other sexually transmitted diseases [19]. Though specimen adequacy rates for cytology are slightly lower for self-collected samples, sensitivity for detection of anal intraepithelial neoplasia (AIN) is comparable [11••, 20]. Samples that are inadequate because of scant cellularity may also be repeated.

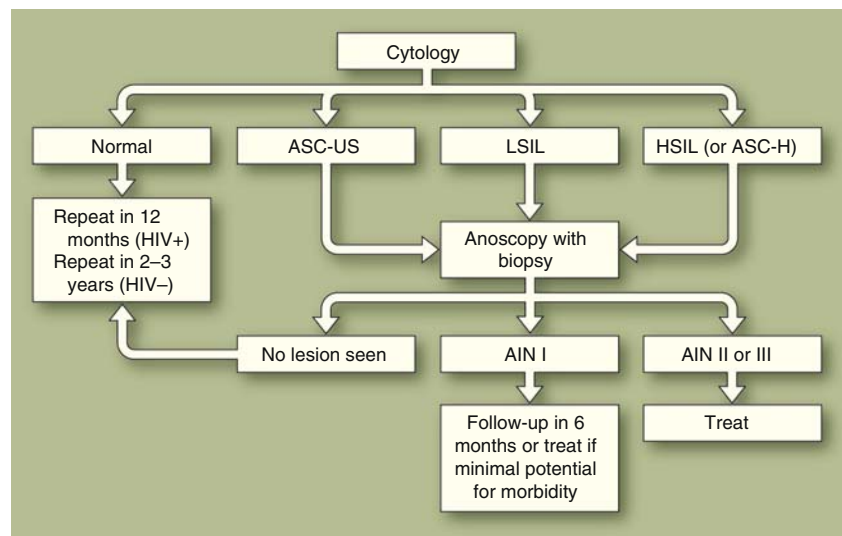
To perform cytology, a rayon or polyester swab is first moistened with tap water and then inserted blindly as far as possible, with gentle pressure and rotation until it reaches the entire rectum. Synthetic fiber swabs are preferred over cotton because cells cling to cotton, decreasing cellular

yield. The swab is then rotated 360 degrees while gentle pressure is applied to the walls of the anal canal as the swab is gradually withdrawn. The swab can then be placed in liquid cytology media or smeared on a glass slide (conventional cytology). Both liquid-based and conventional cytology are acceptable modalities with similar cellular yield and adequacy rates [21].

Anal cytology is categorized according to the Bethesda system for cervical cytology: normal, atypical squamous cells of undetermined significance—ASC-US, low-grade squamous intraepithelial lesion—LSIL, high-grade squamous intraepithelial lesion—HSIL, atypical squamous cells, cannot rule out HSIL—ASC-H [22]. Anal histology is graded according to severity; mild abnormalities are graded as AIN I, and moderate to severe abnormalities are graded as AIN II or AIN III (HGAIN). Although a cytologic diagnosis of HSIL is nearly always associated with HGAIN diagnosed on biopsy, HGAIN is also frequently associated with mildly abnormal cytologic diagnoses (ASC-US, LSIL) [23]. Therefore, we recommend that individuals with abnormal cytology findings of ASCUS or worse be referred for high-resolution anoscopy (HRA) with biopsy. Individuals with HGAIN on biopsy should subsequently be treated (Fig. 1).

If resources for HRA are limited, then cytology can be used for triage: patients with HSIL or ASC-H cytology should be prioritized for HRA, followed by patients with LSIL, and finally by those with ASC-US. Cytology can also be useful as a quality control measure for the anoscopist, because individuals with HSIL on cytology should have HGAIN on biopsy. If no AIN or only low-grade AIN is detected in an individual with HSIL cytology, we recommend repeat HRA to ensure the high-grade lesion was not missed.

**Fig. 1** Protocol for screening of anal intraepithelial neoplasia (AIN). ASC-H—atypical squamous cells, cannot rule out HSIL; ASC-US—atypical squamous cells of undetermined significance; HSIL—high-grade squamous intraepithelial lesion; LSIL—low-grade squamous intraepithelial lesion



Multiple studies have examined the operating characteristics of anal cytology. The reported sensitivity to detect AIN on HRA among different high-risk populations (including HIV-positive MSM) is between 69% and 93%, with specificity ranging from 32% to 64% [24]. Among HIV-negative MSM, cytology is generally less sensitive but more specific than in HIV-positive MSM, with sensitivity reported as about 50% to 60% and specificity of 76% to 84% [11•, 25]. The predictive value of cytology can be improved through repeated testing; in a large, prospective, cohort study by Palefsky et al. [26], the positive predictive value of cytology improved from 38% to 78% and the negative predictive value improved from 46% to 79% after consecutive testing for 2 years.

Although cervical HPV testing is regularly used as an adjunct to triage women with mildly abnormal cervical cytology test results, the role of anal HPV testing as an adjunct to anal cytology is unclear. Based on limited data, it appears that in HIV-positive MSM, using HPV testing as an adjunct to cytology for detection of HGAIN is highly sensitive but has poor specificity and poor positive predictive value [27]. HPV testing may be more useful in HIV-negative MSM, because the presence of oncogenic HPV infection, especially HPV-16, is highly specific for HGAIN on biopsy [25•]. HPV testing may also be useful among populations with a lower prevalence of anal HPV infection than HIV-positive MSM (eg, HIV-negative MSM) for its negative predictive value.

Because of the high prevalence of AIN in certain populations, some researchers have advocated foregoing cytology and using HRA as a primary screening test. This consideration is reasonable, given that a single negative cytology result has a poor negative predictive value in populations with a high prevalence of disease (eg, HIV-positive MSM). However, given the insufficient availability of HRA, we believe that use of cytology to triage individuals to HRA and biopsy is the appropriate approach to AIN or anal cancer screening in most settings.

Currently, no national consensus exists on an optimal method and frequency for anal cancer screening. Guidelines from the Centers for Disease Control and Prevention acknowledge that cytology is used by many experts to screen for AIN in HIV-positive individuals [28•]. Screening HIV-positive MSM annually and screening HIV-negative MSM every 2 years appears to be cost-effective, with a cost of about \$16,000 per quality-adjusted life year (QALY) saved; this is comparable to other commonly used preventive health measures [29, 30]. However, modeling studies conducted under different assumptions in the United Kingdom demonstrate much higher costs per QALY for MSM, thus the issue of cost efficacy must be analyzed separately in health care systems where screening may be used [31].

An important caveat regarding our recommendation for anal cytology screening is that screening should only be instituted if treatment is available for individuals with HGAIN. If expertise is not available to perform HRA and treat HGAIN, then, at a minimum, high-risk patients should receive an annual digital rectal exam (DRE) to feel for masses in the anal canal. Although no data exist on the performance of DRE in detecting anal cancer, DRE is easy to perform and offers the potential benefit of detecting anal cancers at an early and treatable stage.

## Diagnosis

HRA is typically performed in an outpatient setting using techniques similar to those of cervical colposcopy. After insertion of an anoscope and the application of 3% acetic acid with or without Lugol's iodine, the transformation zone between rectal columnar and anal squamous epithelium, up to and including the perianal epithelium, is visualized under magnification, and abnormal areas are biopsied. Local anesthesia is usually not required to perform biopsy unless the lesion is perianal or close to the anal verge.

Although HRA-guided biopsy is the gold standard for diagnosis of HGAIN, like cervical colposcopy, the performance of HRA as a diagnostic test is dependent on operator ability to visualize and properly perform biopsy of lesions. In our experience, a significant and lengthy learning curve exists for developing competence in HRA. No large studies have been conducted on the magnitude of interobserver variability associated with this technique.

Our institution is committed to addressing the current shortage of HRA providers by educating and training providers in HRA techniques. Courses in HRA are provided by clinician-investigators from our institution in collaboration with American Society of Colposcopy and Cervical Pathology. HRA can be performed by any clinician who cares for at-risk patients, including advance practice clinicians, primary care and specialist physicians (ie, dermatology, infectious disease, oncology), and surgeons. Clinicians may also receive advanced training and experience at the University of California San Francisco Anal Neoplasia Clinic.

## Current Treatment Modalities

AIN treatment can be challenging because recurrence after treatment and development of metachronous lesions (concurrent separate lesions) is common. There are no randomized controlled trials of AIN treatments to inform treatment recommendations, thus selection of treatment modality is

directed not only by the extent and location of disease but also by available expertise and resources. Treatment of AIN generally falls into three categories: local treatment with clinician or patient-applied creams and liquids, clinician-applied ablative techniques such as electrocautery, carbon dioxide (CO<sub>2</sub>) laser, infrared coagulation (IRC; Redfield Corporation, Rochelle Park, NJ), and surgery. The advantages and disadvantages of these approaches are listed in Table 1. Although complications are uncommon, patients should be counseled that ablative and surgical therapies may be associated with side effects such as painful defecation, abscess formation, anal stenosis, incontinence, and scarring/disfigurement.

We generally recommend treatment for HGAIN except in situations of extensive circumferential disease where morbidity from treatment may outweigh benefit. One treatment approach under study for diffuse disease includes use of 5-fluorouracil cream to reduce the extent of disease, which may then lend itself to focal therapy with IRC [32]. Extensive disease that includes both HGAIN and low-grade AIN (LGAIN) can be addressed by focusing treatment on areas of HGAIN. Extensive HGAIN is more common and more difficult to eradicate in HIV-positive MSM, but successful treatment is possible with use of surgery followed by IRC [33••]. Although the malignant potential of LGAIN (AIN I) is unknown, AIN I has the potential to

**Table 1** Treatments for perianal and intra-anal intraepithelial neoplasia

Treatment modality	Efficacy data	Advantages	Disadvantages
<i>Topical treatments</i>			
85% trichloroacetic acid (TCA)	X	Inexpensive Office-based pain usually shortlived and relatively mild	May lead to scarring Multiple visits may be needed More effective for limited disease
Liquid nitrogen		Inexpensive Office-based pain usually shortlived and relatively mild	May lead to scarring Multiple visits may be needed More effective for limited disease
Imiquimod	X	Patient-applied	Pain/irritation Multiple visits may be needed Patients may miss small lesions May be less efficacious in HIV-positive individuals Approved only for perianal lesions Approved only for condyloma
<i>Ablative therapies</i>			
Infrared coagulation	X	Office-based Can treat extensive disease	Pain Bleeding Infection
Electrocautery		May be office-based Inexpensive	Pain Bleeding Infection
CO <sub>2</sub> laser	X	May be office-based Can treat extensive disease	Pain Bleeding Infection Generates smoke “plume” that requires evacuation
Surgical excision		Used to treat extensive disease	Requires surgical setting Pain Bleeding Infection Relatively expensive compared with other therapies

X—Designates therapy shown to be potentially effective in retrospective studies or open-label trials.

progress to HGAIN [12]. Therefore, if treatment for HGAIN is undertaken, it is advisable to treat adjacent LGAIN as well if the lesions can be treated without excessive morbidity. In addition, it is appropriate to treat individuals with LGAIN who manifest symptoms such as pain or pruritus.

For small lesions (<1 cm<sup>2</sup>) located in the perianal or intra-anal region, there are several topical treatment options. Multiple treatment sessions are often necessary, but these therapies are generally well tolerated. Trichloroacetic acid was effective in treating intra-anal HGAIN in a small series of HIV-positive and HIV-negative MSM and appeared most effective in individuals with limited disease (fewer than two lesions) [34•]. Perianal and intra-anal disease can also be treated with liquid nitrogen. Imiquimod has also been used in small open-label studies in Europe and shows promise for treatment of intra-anal HGAIN [35]. In long-term follow-up (30 months) 14 of 19 (74%) treated patients remained clear of AIN at the originally treated site, whereas 4 of 19 developed recurrence of HGAIN at the original site and more than 50% developed HGAIN at a different site [36•]. Although encouraging, these results have not been successfully replicated by North American groups and further study is needed.

For larger lesions, ablative therapies including IRC, CO<sub>2</sub> laser, and electrocautery are usually warranted. IRC is an office-based procedure and offers an advantage over electrocautery because no smoke is created. Several retrospective studies and a phase 1 safety study indicate that IRC is well tolerated and is about 65% effective at treating an individual HGAIN lesion in HIV-positive MSM, with even better efficacy (81% for a single lesion) in HIV-negative MSM [37, 38•, 39]. One retrospective study conducted primarily in MSM used CO<sub>2</sub> laser alone or in combination with surgical excision and/or imiquimod and found that 65% of patients were completely disease free at 12 months [40]. Because of the use of multiple treatment modalities, it is difficult to infer the independent effect of CO<sub>2</sub> laser. No published studies have described the efficacy of electrocautery.

Surgical destruction is usually reserved for individuals with extensive disease who require an examination under anesthesia and multiple biopsies to rule out invasive cancer. In a large retrospective study of surgical treatment followed by repeated office-based procedures to treat recurrent disease, a high resolution rate at 36 months was achieved (86%) [33••].

### Follow-up and Surveillance after Treatment

No consensus exists about optimal frequency of follow-up and surveillance after treatment of AIN with surgical or

ablative techniques. At our institution, individuals are seen for repeat anosopic evaluation as soon as they are able to tolerate examination, typically within 2 months post-treatment. If further small pockets of disease are found, they can often be treated topically as described above. If no further evidence of disease is found, the patient can then return for HRA in 6 to 12 months.

For individuals with untreated HGAIN (eg, patients with contraindications to treatment or disease too extensive to treat), we recommend close monitoring with repeat clinical evaluation and HRA every 3 to 4 months to search for any signs of progression to cancer (eg, pain, bleeding, ulceration). Frequent evaluation is imperative so that if anal cancer occurs, it is detected at an early and highly curable stage.

### The Promise of Prevention

Given that at a large majority of anal cancers are attributable to HPV-16 (~72%), the implications are enormous for HPV vaccination as a primary prevention tool to prevent AIN and anal cancer [7•]. The quadrivalent vaccine against HPV types 6, 11, 16, and 18 was demonstrated to be safe and effective in preventing genital warts and persistent HPV infection in males as well as preventing cervical and genital cancer precursor lesions in females [41, 42]. Data regarding vaccine efficacy to prevent AIN are forthcoming. Currently, the vaccine is licensed for males between the ages of 9 and 26 years for the prevention of warts. Though the efficacy of the vaccine against persistent HPV infection implies that it would also be effective at preventing anal cancers attributable to HPV 16 and 18, the vaccine's efficacy against AIN and anal cancer will depend on the timing of vaccination and the levels of penetration achieved in the target population of MSM. If only low levels of vaccination are achieved or vaccination primarily occurs after the acquisition of anal HPV, then the vaccine may not have a great impact on anal cancer incidence in MSM.

Although the recent licensure of the quadrivalent HPV vaccine for boys heralds an era of opportunity for prevention of anal cancer in MSM, numerous challenges may prevent the vaccine from achieving high levels of penetration in the male population. First, the vaccine is costly, and cost-efficacy studies have suggested that vaccination of males to prevent cervical cancer in females would not be cost efficient if high levels of coverage were achieved in the female population [43]. As of 2008, vaccination coverage in the US female population ranging in age from 13 to 17 years (37% received ≥ one dose, 18% received all three doses) is much lower than that used in the above cost-efficacy model, so vaccination of males is likely more cost-effective than current estimates suggest [44]. Furthermore, these analyses did not take into account the

vaccine's potential impact on anal cancer among MSM, a factor that should be considered in deciding whether vaccination of males is warranted. Another issue is that the vaccine is most effective in HPV-naïve individuals, so that ideally males should be targeted for vaccination prior to sexual debut. Identifying young MSM at risk for anal cancer prior to sexual debut would be challenging, if not impossible. Therefore, if the HPV vaccine is to be effective in decreasing anal cancer in MSM, universal vaccination of preadolescent males would likely be necessary.

## Conclusions

Of foremost interest for future study is whether detection and treatment of HGAIN ultimately reduces anal cancer incidence. A randomized, controlled trial would provide definitive evidence for the efficacy of anal cancer screening. Anal HPV infection may also have public health implications beyond anal cancer because recent data have demonstrated that infection with multiple HPV types is independently associated with acquisition of HIV infection among MSM [45]. A link between sexually transmitted infections and increased susceptibility to HIV infection has been established over the past decade; however, interventions to treat or prevent sexually transmitted infections to reduce HIV acquisition have generally been disappointing [46]. The possible role that anal HPV infection might play in HIV acquisition certainly warrants further investigation, especially given the availability of a highly efficacious vaccine against HPV infection.

**Disclosure** No potential conflict of interest relevant to this article was reported.

**Open Access** This article is distributed under the terms of the Creative Commons Attribution Noncommercial License which permits any noncommercial use, distribution, and reproduction in any medium, provided the original author(s) and source are credited.

## References

Papers of particular interest, published recently, have been highlighted as:

- Of importance
- Of major importance

1. •• Piketty C, Selinger-Leneman H, Grabar S, et al.: Marked increase in the incidence of invasive anal cancer among HIV-infected patients despite treatment with combination antiretroviral therapy. *AIDS* 2008, 22:1203–1211. *The incidence of anal cancer was 75 per 100,000 person-years among HIV-positive MSM in the French Hospital Database on HIV and increased from the pre-HAART era to the post-HAART era.*

2. •• Chaturvedi AK, Madeleine MM, Biggar RJ, Engels EA: Risk of human papillomavirus-associated cancers among persons with AIDS. *J Natl Cancer Inst* 2009, 101:1120–1130. *Linking AIDS and cancer registry data from 15 US states, this study showed the incidence of anal cancer increased 104% from the pre-HAART era to the post-HAART era (20.7 cases vs 42.3 cases /100,000 person-years).*
3. •• D'Souza G, Wiley DJ, Li X, et al.: Incidence and epidemiology of anal cancer in the multicenter AIDS cohort study. *J Acquir Immune Defic Syndr* 2008, 48:491–499. *The incidence of anal cancer in the US multicenter AIDS cohort study was 137/100,000 person-years among HIV-positive MSM since 1996.*
4. •• Patel P, Hanson DL, Sullivan PS, et al.: Incidence of types of cancer among HIV-infected persons compared with the general population in the United States, 1992–2003. *Ann Intern Med* 2008, 148:728–736. *Matching data from the Adult and Adolescent Spectrum of HIV Disease Project, the HIV Outpatient Study and the Surveillance, Epidemiology, and End Results Program, this study showed that the incidence of anal cancer in HIV-positive MSM was 78 per 100,000 person-years since 2000.*
5. Joseph DA, Miller JW, Wu X, et al.: Understanding the burden of human papillomavirus-associated anal cancers in the US. *Cancer* 2008, 113(10 Suppl):2892–2900.
6. Daling JR, Weiss NS, Hislop TG, et al.: Sexual practices, sexually transmitted diseases, and the incidence of anal cancer. *N Engl J Med* 1987, 317:973–977.
7. • Hoots BE, Palefsky JM, Pimenta JM, Smith JS: Human papillomavirus type distribution in anal cancer and anal intraepithelial lesions. *Int J Cancer* 2009, 124:2375–2383. *This meta-analysis describes the prevalence and type distribution of HPV in 992 cases of invasive anal cancer—472 HSIL cases and 360 LSIL cases. HPV prevalence was 71%, 91%, and 88%, respectively. HPV 16 or HPV 18 were present in 72% of anal cancers.*
8. Schiffman M, Kjaer SK: Chapter 2: Natural history of anogenital human papillomavirus infection and neoplasia. *J Natl Cancer Inst Monogr* 2003, 31:14–19.
9. Chin-Hong PV, Vittinghoff E, Cranston RD, et al.: Age-specific prevalence of anal human papillomavirus infection in HIV-negative sexually active men who have sex with men: the EXPLORE study. *J Infect Dis* 2004, 190:2070–2076.
10. Palefsky JM, Holly EA, Ralston ML, Jay N: Prevalence and risk factors for human papillomavirus infection of the anal canal in human immunodeficiency virus (HIV)-positive and HIV-negative homosexual men. *J Infect Dis* 1998, 177:361–367.
11. •• Chin-Hong PV, Berry JM, Cheng SC, et al.: Comparison of patient- and clinician-collected anal cytology samples to screen for human papillomavirus-associated anal intraepithelial neoplasia in men who have sex with men. *Ann Intern Med* 2008, 149: 300–306. *This population-based study of HIV-positive and HIV-negative MSM in San Francisco, California demonstrated that the prevalence of HGAIN was 43% in HIV-positive and 25% in HIV-negative MSM. Self-collected anal cytology demonstrated similar sensitivity for detection of AIN compared with clinician-collected samples.*
12. Palefsky JM, Holly EA, Ralston ML, et al.: High incidence of anal high-grade squamous intra-epithelial lesions among HIV-positive and HIV-negative homosexual and bisexual men. *AIDS* 1998, 12:495–503.
13. Palefsky JM, Holly EA, Efrird JT, et al.: Anal intraepithelial neoplasia in the highly active antiretroviral therapy era among HIV-positive men who have sex with men. *AIDS* 2005, 19:1407–1414.
14. Devaraj B, Cosman BC: Expectant management of anal squamous dysplasia in patients with HIV. *Dis Colon Rectum* 2006, 49:36–40.

15. Watson AJ, Smith BB, Whitehead MR, et al.: Malignant progression of anal intra-epithelial neoplasia. *ANZ J Surg* 2006, 76:715–717.
16. Scholefield JH, Castle MT, Watson NF: Malignant transformation of high-grade anal intraepithelial neoplasia. *Br J Surg* 2005, 92:1133–1136.
17. Palefsky JM, Holly EA, Ralston ML, et al.: Effect of highly active antiretroviral therapy on the natural history of anal squamous intraepithelial lesions and anal human papillomavirus infection. *J Acquir Immune Defic Syndr* 2001, 28:422–428.
18. Engels EA, Biggar RJ, Hall HI, et al.: Cancer risk in people infected with human immunodeficiency virus in the United States. *Int J Cancer* 2008, 123:187–194.
19. van der Helm JJ, Hoebe CJ, van Rooijen MS, et al.: High performance and acceptability of self-collected rectal swabs for diagnosis of Chlamydia trachomatis and Neisseria gonorrhoeae in men who have sex with men and women. *Sex Transm Dis* 2009, 36:493–497.
20. Cranston RD, Darragh TM, Holly EA, et al.: Self-collected versus clinician-collected anal cytology specimens to diagnose anal intraepithelial neoplasia in HIV-positive men. *J Acquir Immune Defic Syndr* 2004, 36:915–920.
21. Darragh TM, Jay N, Tupkelewicz BA, et al.: Comparison of conventional cytologic smears and ThinPrep preparations from the anal canal. *Acta Cytologica* 1997, 41:1167–1170.
22. Solomon D, Davey D, Kurman R, et al.: The 2001 Bethesda System: terminology for reporting results of cervical cytology. *JAMA* 2002, 287:2114–2119.
23. Panther LA, Wagner K, Proper J, et al.: High-resolution anoscopy findings for men who have sex with men: inaccuracy of anal cytology as a predictor of histologic high-grade anal intraepithelial neoplasia and the impact of HIV serostatus. *Clin Infect Dis* 2004, 38:1490–1492.
24. Chiao EY, Giordano TP, Palefsky JM, et al.: Screening HIV-infected individuals for anal cancer precursor lesions: a systematic review. *Clin Infect Dis* 2006, 43:223–233.
25. • Berry JM, Palefsky JM, Jay N, et al.: Performance characteristics of anal cytology and human papillomavirus testing in patients with high-resolution anoscopy-guided biopsy of high-grade anal intraepithelial neoplasia. *Dis Colon Rectum* 2009, 52:239–247. *This study describes the sensitivity of abnormal anal cytology to detect HGAIN. Sensitivity was 87% in HIV-positive men and 55% in HIV-negative men.*
26. Palefsky JM, Holly EA, Hogeboom CJ, et al.: Anal cytology as a screening tool for anal squamous intraepithelial lesions. *J Acquir Immune Defic Syndr Hum Retrovirol* 1997, 14:415–422.
27. Goldstone SE, Enyinna CS, Davis TW: Detection of oncogenic human papillomavirus and other predictors of anal high-grade dysplasia in men who have sex with men with abnormal cytology. *Dis Colon Rectum* 2009, 52:31–39.
28. •• Kaplan JE, Benson C, Holmes KH, et al.: Guidelines for prevention and treatment of opportunistic infections in HIV-infected adults and adolescents: recommendations from CDC, the National Institutes of Health, and the HIV Medicine Association of the Infectious Diseases Society of America. *MMWR Recomm Rep* 2009, 58(RR-4):1–207. *This article presents the guidelines from the US Public Health Service for screening and treatment of AIN in HIV-positive individuals.*
29. Goldie SJ, Kuntz KM, Weinstein MC, et al.: The clinical effectiveness and cost-effectiveness of screening for anal squamous intraepithelial lesions in homosexual and bisexual HIV-positive men. *JAMA* 1999, 281:1822–1829.
30. Goldie SJ, Kuntz KM, Weinstein MC, et al.: Cost-effectiveness of screening for anal squamous intraepithelial lesions and anal cancer in human immunodeficiency virus-negative homosexual and bisexual men. *Am J Med* 2000, 108:634–641.
31. Karnon J, Jones R, Czoski-Murray C, Smith KJ: Cost-utility analysis of screening high-risk groups for anal cancer. *J Public Health (Oxf)* 2008, 30:293–304.
32. Jay N, Berry JM, Darragh T, Palefsky JM: Abstract P19.16: Treatment of diffuse high-grade anal intraepithelial neoplasia with 5% fluorouracil cream. Presented at the 25th International Papillomavirus Conference. Malmö, Sweden; 2009.
33. •• Pineda CE, Berry JM, Jay N, et al.: High-resolution anoscopy targeted surgical destruction of anal high-grade squamous intraepithelial lesions: a ten-year experience. *Dis Colon Rectum* 2008, 51:829–835. *This article describes a retrospective study of patients treated for HGAIN using surgery guided by HRA, followed by office-based procedures to treat recurrent disease. After 36 months of follow-up, HGAIN had a high resolution rate (86%) with a low complication rate.*
34. • Singh JC, Kuohung V, Palefsky JM: Efficacy of trichloroacetic acid in the treatment of anal intraepithelial neoplasia in HIV-positive and HIV-negative men who have sex with men. *J Acquir Immune Defic Syndr* 2009, 52:474–479. *This retrospective study of 35 HIV-positive and 19 HIV-negative MSM demonstrated efficacy of 85% trichloroacetic acid in the treatment of AIN. On a per lesion basis, 71% of HGAIN lesions cleared to either LGAIN or no lesion; in HIV-positive MSM, those with two or fewer lesions had the highest rate of clearance.*
35. Wieland U, Brockmeyer NH, Weissenborn SJ, et al.: Imiquimod treatment of anal intraepithelial neoplasia in HIV-positive men. *Arch Dermatol* 2006, 142:1438–44.
36. • Kreuter A, Potthoff A, Brockmeyer NH, et al.: Imiquimod leads to a decrease of human papillomavirus DNA and to a sustained clearance of anal intraepithelial neoplasia in HIV-infected men. *J Invest Dermatol* 2008, 128:2078–83. *This open label-study of 17 patients treated with imiquimod for AIN demonstrated a 74% clearance of the original lesion; however, more than half of patients developed new lesions during follow-up.*
37. Goldstone SE, Hundert JS, Huyett JW: Infrared coagulator ablation of high-grade anal squamous intraepithelial lesions in HIV-negative males who have sex with males. *Dis Colon Rectum* 2007, 50:565–575.
38. • Stier EA, Goldstone SE, Berry JM, et al.: Infrared coagulator treatment of high-grade anal dysplasia in HIV-infected individuals: an AIDS malignancy consortium pilot study. *J Acquir Immune Defic Syndr* 2008, 47:56–61. *This small, multicenter, phase 1 study demonstrated that infrared coagulator treatment of HGAIN in HIV-positive individuals was well tolerated, with resolution of 64% of lesions after treatment.*
39. Cranston RD, Hirschowitz SL, Cortina G, Moe AA: A retrospective clinical study of the treatment of high-grade anal dysplasia by infrared coagulation in a population of HIV-positive men who have sex with men. *Int J STD AIDS* 2008, 19:118–120.
40. Nathan M, Hickey N, Mayuranathan L, Vowler SL, Singh N: Treatment of anal human papillomavirus-associated disease: a long term outcome study. *Int J STD AIDS* 2008, 19:445–9.
41. Guiliano A, Palefsky J: Abstract O-01.07: Quadrivalent HPV Vaccine Efficacy Against Male Genital Disease And Infection. 25th International Papillomavirus Conference. Malmö, Sweden, 2009.
42. Ault KA: Effect of prophylactic human papillomavirus L1 virus-like-particle vaccine on risk of cervical intraepithelial neoplasia grade 2, grade 3, and adenocarcinoma in situ: a combined analysis of four randomised clinical trials. *Lancet* 2007, 369:1861–8.



43. Kim JJ, Goldie SJ: Cost effectiveness analysis of including boys in a human papillomavirus vaccination programme in the United States. *BMJ* 2009, 339:b3884.
44. Centers for Disease Control and Prevention: National, state, and local area vaccination coverage among adolescents aged 13–17 years—United States, 2008. *MMWR Morb Mortal Wkly Rep* 2009, 58:997–1001.
45. • Chin-Hong PV, Husnik M, Cranston RD, et al.: Anal human papillomavirus infection is associated with HIV acquisition in men who have sex with men. *AIDS* 2009, 23: 1135–42. *This prospective cohort study of HIV-negative MSM demonstrated that infection with two or more types of anal HPV was independently associated with acquisition of HIV after adjustment for demographic and other risk factors.*
46. Sexton J, Garnett G, Rottingen JA: Metaanalysis and metaregression in interpreting study variability in the impact of sexually transmitted diseases on susceptibility to HIV infection. *Sex Transm Dis* 2005, 32:351–7.