

UC Davis

Dermatology Online Journal

Title

Primary mucocutaneous histoplasmosis in an immunocompetent patient

Permalink

<https://escholarship.org/uc/item/87614080>

Journal

Dermatology Online Journal, 21(3)

Authors

Kash, Natalie
Jahan-Tigh, Richard Reza
Efron-Everett, Melissa
et al.

Publication Date

2015

Supplemental Material

<https://escholarship.org/uc/item/87614080#supplemental>

License

[CC BY-NC-ND 4.0](https://creativecommons.org/licenses/by-nc-nd/4.0/)

Peer reviewed

Case presentation

Primary mucocutaneous histoplasmosis in an immunocompetent patient

Natalie Kash BS¹, Richard Jahan-Tigh MD¹, Melissa Efron-Everett MD¹, and Nadarajah Vigneswaran DMD².

Dermatology Online Journal 21 (3): 14

¹Department of Dermatology, University of Texas Medical School at Houston and MD Anderson Cancer Center, Houston, Texas

²University of Texas at Houston School of Dentistry, Houston, Texas

Correspondence:

Richard R. Jahan-Tigh, MD
6655 Travis St, HMC 980
Houston, TX 77030
Phone: (713) 500-8329
Email: Richard.R.JahanTigh@uth.tmc.edu

Abstract

We report a case of primary mucocutaneous histoplasmosis in an immunocompetent individual. The patient, a 61-year-old woman, presented with a non-healing ulcer on the lateral border of her tongue. Excisional biopsy of the lesion was consistent with histoplasmosis and no evidence of pulmonary or disseminated infection was found. Although mucocutaneous infection has been well-described as a manifestation of disseminated disease, especially in immunocompromised individuals, oral infections in immunocompetent patients are rare.

Keywords: histoplasmosis, *Histoplasma capsulatum*, primary mucocutaneous, immunocompetent, itraconazole, cirrhosis

Abbreviation / Acronym List:

HIV: human immunodeficiency virus
GMS: Grocott-Gomori's methenamine silver
PAS: Periodic acid Schiff

Introduction

Histoplasmosis is a mycosis caused by the dimorphic fungus *Histoplasma capsulatum* [1, 2]. Although endemic to particular regions including the central United States, South America, areas of Africa, Australia, India, and Malaysia, histoplasmosis is very widely distributed and the most common endemic mycosis in North America [1, 2]. It is typically contracted through exposure to airborne spores in soil contaminated with bird and bat droppings [1, 2]. It most frequently manifests as a pulmonary infection but may disseminate to the liver, adrenal glands, meninges, skin, and mucous membranes [1, 3]. Primary mucocutaneous infection is rare, especially in immunocompetent individuals [2]. Cutaneous findings include papules, nodules, plaques, and punched out ulcers [2]. Our human immunodeficiency virus (HIV)-negative patient presented with primary mucocutaneous infection.

Case synopsis

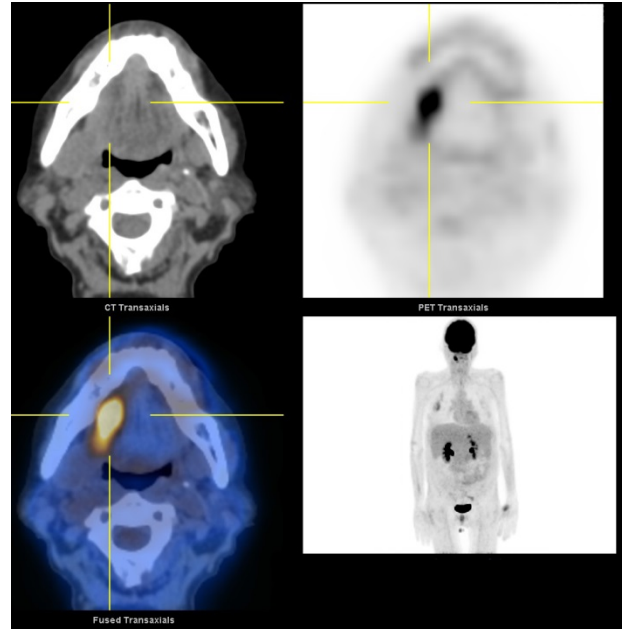
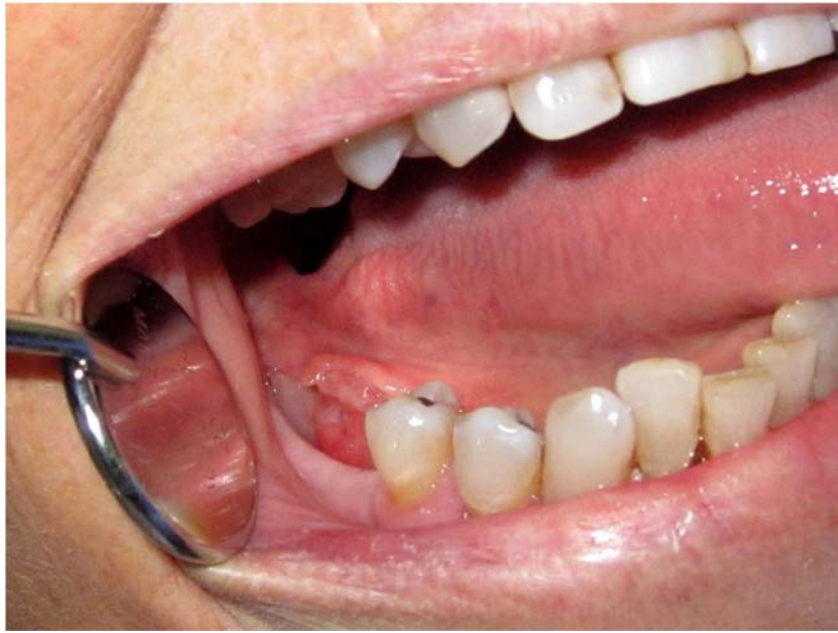
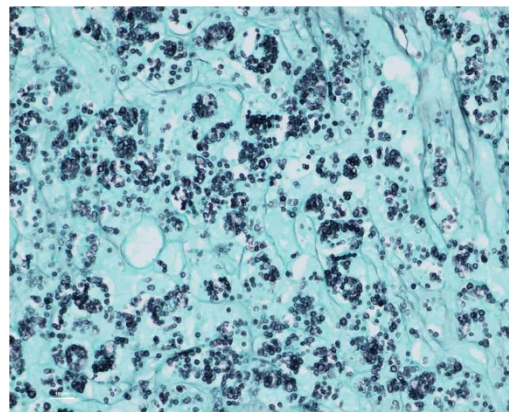
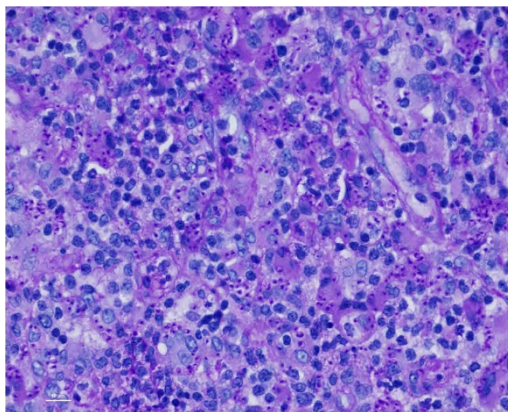
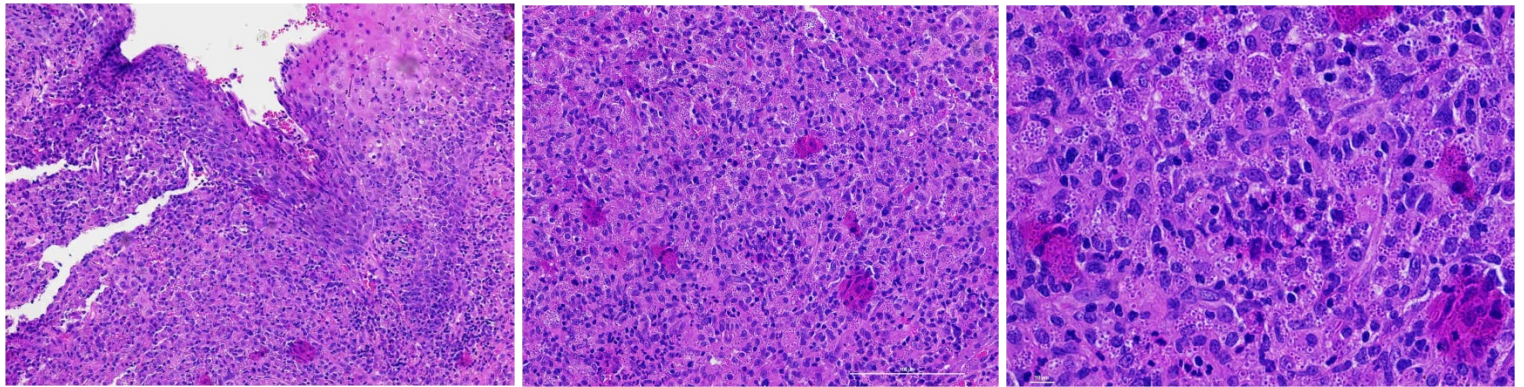


Figure A. An ulcerated, tender mass 1.3 by 1.1 cm on the right posterolateral tongue/ floor of the mouth. **Figure B.** Computed tomography scan with overlay of FDG-PET scan done as part of the patient's staging prior to lesional biopsy. A single nodule was detected at the base of the right lateral tongue.

A woman in her 60's with a past medical history of cirrhosis, hypertension, and osteoporosis presented to clinic with a one-month history of a lesion on the right lateral border of her tongue. She experienced pain in her mouth that radiated to her right ear, dysphagia, and odynophagia. Examination of the area was significant for an indurated, erythematous and ulcerated mass 1.3 cm by 1.1 cm on the right posterior tongue/floor of her mouth (Figure A). Her other mucous membranes were clear, and she had no lymphadenopathy. A PET scan was done because of concern for malignancy and a single area of FDG uptake was noted at the base of the right tongue coinciding with the location of the lesion (Figure B). No other areas of activity were found in the scan.



Excisional biopsy demonstrated granulomatous inflammation with many scattered small clear cells, both interstitially and within histiocytes (Figure C, D, E). The 2 to 4 µm organisms were highlighted with Periodic acid Schiff (PAS) and Grocott-Gomori's methenamine silver (GMS) stains (Figure F, G), which confirmed the diagnosis of histoplasmosis.

The patient, a Texas resident, denied any travel abroad or outside of the state of Texas during the previous 5 years. She specifically denied any travel to any states in the Mississippi River or Ohio River Valley. She previously worked in a school cafeteria for 20 years and retired in 2013. She denied any history of spelunking, visiting caves, or exposure to pigeons, chicken coops, or other birds.

The patient was referred to the infectious disease department for evaluation of possible disseminated disease, but no evidence of systemic infection was found. Her complete blood count, alpha-fetoprotein, albumin, prothrombin time, and comprehensive metabolic panel were within normal limits besides an elevated alkaline phosphatase of 233. A computed tomography of the chest revealed no nodules or changes consistent with pulmonary histoplasmosis. Her HIV test was negative. A 6-month course of itraconazole 200 mg BID was initiated. At one-month follow up, she reported resolution of her pain and examination demonstrated no ulceration with decreased inflammation of the affected area. She reported no side effects from the itraconazole, and it will be continued for a total of 6 months.

Discussion

Histoplasmosis is the most common endemic mycosis in North America [1, 2]. Acute pulmonary, acute disseminated, chronic disseminated, and chronic pulmonary are the four variants of clinical disease that are most classically described [1]. *Histoplasma capsulatum* is an important cause of morbidity and mortality in HIV-positive and other immunocompromised patients [4]. In these patients, disseminated disease is a potentially fatal complication for which the incidence and severity have been shown to increase with the degree of HIV progression [1, 3]. Oral ulceration is one of many well-described manifestations of disseminated disease in the immunosuppressed [1, 5].

In immunocompetent individuals, cases of histoplasmosis infection, mostly asymptomatic pulmonary infection, have been well described especially in endemic areas [1, 3]. However, primary mucocutaneous disease in this population is rare but has been reported to present as papules, nodules, plaques, or punched out ulcers of skin or oral mucosa [2, 3, 5].

Our HIV-negative patient presented with an ulceration on the lateral border of her tongue and was found to have histological findings consistent with histoplasmosis with no evidence of pulmonary or disseminated disease. Her history was negative for known histoplasmosis risk factors.

It may be that our patients' cirrhosis may have contributed to some degree of immunosuppression. Cirrhotic patients are known to be predisposed to bacterial infections, including spontaneous bacterial peritonitis, sepsis, cellulitis, tuberculosis, and to fungal infections, including candidiasis and cryptococcosis [6-10]. However, histoplasmosis is not an infection classically associated with this patient population.

Oral itraconazole and liposomal amphotericin B are well studied, have been shown to be the most effective antifungal agents against histoplasmosis, and thus are the preferred treatment modalities according to both the Infectious Disease Society of America (IDSA) and American Thoracic Society (ATS) [11-12]. Oral itraconazole is the recommended treatment for mild to moderate acute pulmonary histoplasmosis lasting at least three to four weeks, chronic pulmonary histoplasmosis, and mild to moderate disseminated histoplasmosis. A course of liposomal amphotericin B followed by itraconazole therapy is the recommended regimen for moderate to severe acute pulmonary, moderate to severe disseminated, and central nervous system histoplasmosis [11-12].

There are no guidelines or recommendations specific to the treatment of primary cutaneous histoplasmosis owing to the rarity of this condition. However, the resolution of our patient's symptoms with oral itraconazole is consistent with the previously reported cases of primary mucocutaneous histoplasmosis in immunocompetent patients responding to this therapy [1-5, 13-15]. Despite the known risk of hepatic toxicity with itraconazole and the history of liver cirrhosis in our patient, itraconazole therapy with appropriate laboratory monitoring, including itraconazole levels and liver function tests, was the most appropriate treatment regimen in our patient. Fluconazole and ketoconazole are azole alternatives that have been shown to be efficacious in the treatment of histoplasmosis. However, both the IDSA and ATS recommend their use as second-line agents because they are known to have lower rates of efficacy (fluconazole) and higher rates of adverse effects (ketoconazole) compared to itraconazole. Thus, itraconazole therapy was preferred and it was well tolerated in our patient. Amphotericin B was not an appropriate first-line choice in our patient owing to the lack of both intravenous access and a true indication; the work-up in her case demonstrated no

