UC Irvine
Clinical Practice and Cases in Emergency Medicine

Title
Case Report of Concurrent Deep Vein Thrombosis and Pulmonary Embolism in Congenital Inferior Vena Cava Absence

Permalink
https://escholarship.org/uc/item/87q8w7f4

Journal
Clinical Practice and Cases in Emergency Medicine, 0(0)

Authors
Bouchal, Elise
Drechsel, Zoe
Calder, Scott
et al.

Publication Date
2026-11-24

DOI
10.5811/cpcem.62967

Copyright Information
This work is made available under the terms of a Creative Commons Attribution License, available at https://creativecommons.org/licenses/by/4.0/

Peer reviewed

eScholarship.org Powered by the California Digital Library
University of California

Case Report of Concurrent Deep Vein Thrombosis and Pulmonary Embolism in Congenital Inferior Vena Cava Absence

Elise Bouchal, BS, BA
Zoe Drechsel, BS
Scott Calder, DO
Komal Chughtai, MD
Wayne Martini, MD

Mayo Clinic, Department of Emergency Medicine, Phoenix, Arizona

Section Editor: Joel Moll, MD
Submission history: Submitted February 17, 2026; Revision received June 27, 2026; Accepted July 1, 2026
Electronically published [date]
Full text available through open access at http://escholarship.org/uc/uciem_cpcem
DOI: 10.5811/cpcem.62967

Introduction: Congenital absence/atresia of the inferior vena cava (AIVC) is a rare venous anomaly that predisposes patients to venous thromboembolism. Diagnostic evaluation can be challenging because initial ultrasound may be negative despite evolving thrombus, and pulmonary embolism (PE) may be minimally symptomatic.

Case Report: A 41-year-old man with known AIVC with azygos continuation and a prior right-leg deep vein thrombosis (DVT) presented to the emergency department with acute left hip/groin and leg pain. He had previously been prescribed rivaroxaban but discontinued anticoagulation in 2019 after relocating and was not on anticoagulation at the time of presentation. Initial venous duplex ultrasound of the left lower extremity showed no DVT, and he was discharged with return precautions. Within 12–24 hours, he returned with rapid progression to marked swelling and severe pain with ambulation. Repeat duplex demonstrated DVT from the external iliac vein through the calf veins. Computed tomography pulmonary angiography showed bilateral lower lobe pulmonary emboli without right heart strain and confirmed AIVC interruption with azygos continuation. He was started on intravenous heparin and underwent catheter-directed thrombolysis. Transthoracic echocardiography showed normal right ventricular function, and he was discharged on indefinite rivaroxaban.

Conclusion: In patients with AIVC and high clinical suspicion for DVT, a negative initial ultrasound does not exclude evolving extensive thrombosis. Rapid symptom progression should prompt repeat and/or advanced imaging, and clinicians should consider evaluation for PE even with minimal symptoms. Early thrombus-directed therapy plus long-term anticoagulation may reduce morbidity and require strong adherence counseling. [Clin Pract Cases Emerg Med. 2026;X(X):XXX–XXX.]

Keywords: *inferior vena cava agenesis/atresia; deep vein thrombosis; pulmonary embolism; duplex ultrasound; case report.*

INTRODUCTION

Congenital absence of the inferior vena cava (AIVC) is a rare vascular anomaly associated with an increased risk of deep vein thrombosis (DVT), particularly in younger patients presenting with unprovoked lower-extremity thrombosis. Review studies estimate the incidence of AIVC to be approximately 0.2% among all patients diagnosed with DVT, increasing to between 5% and 11% in patients under 30 years of age with unprovoked DVT.[1] This condition is most often discovered incidentally during cross-sectional imaging obtained for evaluation of venous thrombosis or chronic venous insufficiency.

Patients with AIVC typically exhibit venous return through enlarged azygos, hemiazygos, and lumbar collateral

pathways. The increased risk of thrombosis in this population is thought to result from venous stasis caused by diversion of blood flow through these collateral networks. Notably, many patients with AIVC present with DVT in the absence of other identifiable risk factors, suggesting AIVC alone may be sufficient to predispose to thrombosis. Review studies have reported that 44.1% of adult patients and 33% of pediatric patients with AIVC-associated DVT present without additional thrombotic risk factors.[1,2]with 178 reports included. A total of 376 patients were analyzed. Overall, males seem to be more affected than females, with a ratio of almost 2:1 (male, 227 [64.1%]; vs female, 127 [35.8%]

While limited to a few case reports, pulmonary embolism (PE) has also been reported in patients with AIVC as potentially being caused by the absence of a continuous inferior vena cava, describing the potential for thrombus propagation through collateral venous pathways.[3–5]presenting with massive pulmonary embolism. Subsequent evaluation with abdominal CT scan revealed the congenital absence of retrohepatic IVC. The patient was successfully treated with anticoagulation. When deep venous thrombosis (DVT

We present a case of an otherwise healthy patient with known AIVC who developed extensive acute DVT with a concurrent, minimally symptomatic PE. This case highlights diagnostic challenges associated with early imaging, the importance of repeat evaluation in high-risk patients, and current considerations for acute and long-term management.

CPC-EM Capsule

What do we already know about this clinical entity?

Congenital absence/atresia of the inferior vena cava (IVC) is a rare venous anomaly that predisposes patients to venous thromboembolism.

What makes this presentation of disease reportable?

Congenital IVC absence complicated by extensive deep vein thrombosis (DVT) and minimally symptomatic bilateral pulmonary embolism (PE) within 24 hours of a negative venous ultrasound.

What is the major learning point?

A negative initial ultrasound does not exclude evolving extensive DVT in patients with congenital IVC absence; concurrent PE may be minimally symptomatic.

How might this improve emergency medicine practice?

Prompt repeat or advanced imaging for worsening symptoms despite negative ultrasound, and consider PE evaluation in patients with extensive DVT and IVC anomalies.

CASE REPORT

A 41-year-old man with a known history of AIVC with azygos continuation and a prior right lower-extremity (DVT) in 2014 treated with catheter-directed thrombolysis presented to the emergency department (ED) with acute left hip and leg pain. Following his prior thrombotic event, he had been prescribed long-term rivaroxaban but self-discontinued anticoagulation in 2019 after relocating and becoming lost to follow-up. He had no other known risk factors for venous thromboembolism and denied tobacco or illicit drug use.

His symptoms began after moving furniture, initially as left hip and groin pain, progressing over 24 hours to diffuse left leg discomfort. He presented to the ED reporting worsening pain and newly noted diffuse discoloration of the left lower extremity, without swelling, chest pain, or dyspnea. Vital signs were notable for hypertension (168/95 mm Hg) with normal heart rate and oxygen saturation. Physical examination demonstrated intact distal pulses and mild diffuse discoloration without significant edema.

A left lower-extremity venous duplex ultrasound, evaluating the common femoral, femoral, popliteal, and visualized deep calf veins, demonstrated no evidence of DVT (Image 1). Hip radiographs were without acute findings. He was discharged with a presumed musculoskeletal diagnosis and strict return precautions.

Within 12–24 hours, his symptoms progressed rapidly. He returned to the ED early the next day with marked swelling from the thigh to the shin, severe pain with ambulation, inability to dorsiflex the ankle, and grayish-purple discoloration of the limb. He described the leg as feeling “like a balloon.” On arrival, he was tachycardic (heart rate, 126 beats per minute) but normotensive (blood pressure, 131/77 mm Hg) and saturating 100% on room air. Examination revealed a markedly edematous and discolored left lower extremity with a firm calf, concerning for an evolving phlegmasia cerulea dolens-like presentation, although distal pulses remained present on Doppler.

Repeat venous duplex ultrasound demonstrated a hyperacute, extensive, mostly occlusive DVT extending from the external iliac vein through the femoral, popliteal, posterior tibial, and peroneal veins (Image 2).

Despite minimal cardiopulmonary symptoms, computed tomography (CT) pulmonary angiography revealed acute segmental and subsegmental bilateral lower lobe pulmonary emboli without evidence of right heart strain, as well as interruption of the inferior vena cava with azygos continuation. A CT angiogram of the left lower extremity demonstrated patent arterial vasculature with a markedly distended deep venous system and surrounding inflammatory fat stranding, consistent with extensive venous thrombosis.

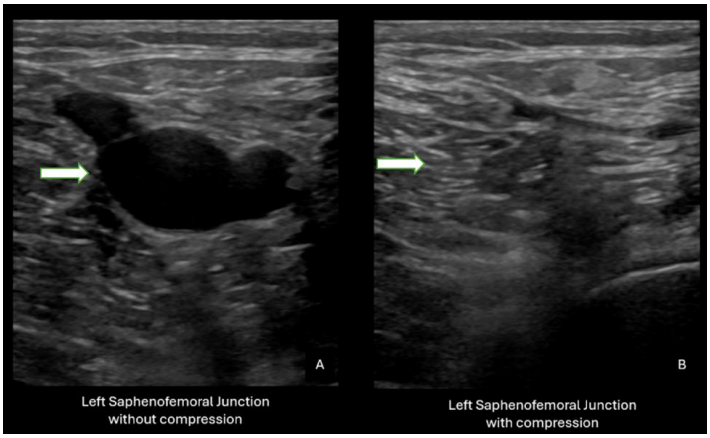

Image 1. Duplex ultrasonography of the left saphenofemoral junction in transverse view. **A,** An image obtained without probe compression demonstrates a patent, anechoic venous lumen (arrow) at the saphenofemoral junction. **B**, With graded transducer compression, complete coaptation of the venous walls is observed (arrow), confirming normal compressibility and absence of intraluminal thrombus at this level.

Laboratory studies showed mild leukocytosis and elevated C-reactive protein; cardiac biomarkers for troponin and N-terminal pro–B-type natriuretic peptide were negative.

The patient was started on therapeutic intravenous heparin and admitted. Interventional radiology performed catheter-directed thrombolysis using an EKOS catheter, with the infusion segment extending from a prominent azygos/lumbar venous collateral into the common femoral vein, reflecting venous drainage patterns associated with his congenitally absent IVC (Image 3).

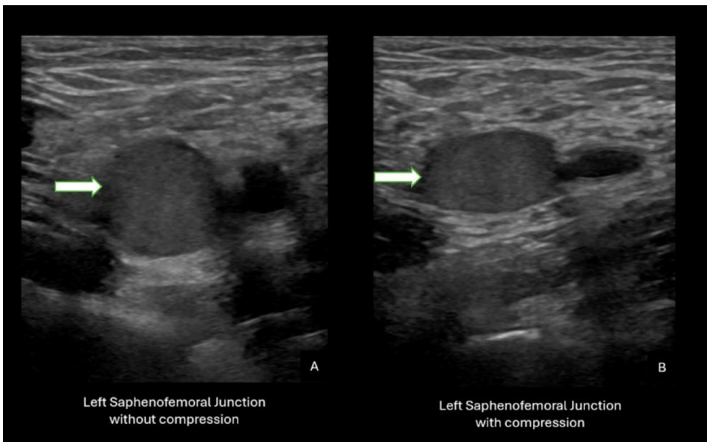

Image 2. Duplex ultrasonography of the left saphenofemoral junction in transverse view. **A**, Without probe compression, the common femoral vein demonstrates intraluminal echogenic material (arrow) and incomplete luminal filling. **B**, With graded transducer compression, there is persistent venous noncompressibility (arrow), consistent with acute thrombosis at the left saphenofemoral junction.



Image 3. Digital subtraction angiogram of the left iliofemoral venous system in an oblique projection. A contrast injection demonstrates opacification of the left common femoral and external iliac veins, with focal luminal narrowing at the level of the left common iliac vein (white arrow), consistent with iliac vein compression. Collateral venous channels are visible within the pelvis, suggesting a hemodynamically significant outflow obstruction due to congenitally absent inferior vena cava.

He was monitored in the intensive care unit for 24 hours without complication. Transthoracic echocardiography demonstrated normal right ventricular size and systolic function. Following improvement in lower-extremity edema and discoloration, he was transitioned to indefinite oral anticoagulation with rivaroxaban, counseled on medication adherence, and discharged home with vascular medicine follow-up.

DISCUSSION

This case highlights the importance of using early and repeat ultrasound imaging, or advanced imaging in high-risk

patients. Duplex ultrasound (DUS) is the most commonly used initial diagnostic modality for suspected DVT and has reported sensitivity and specificity approaching 97%.[6] When used as point-of-care ultrasound, DUS allows for rapid bedside evaluation and informs early clinical decision-making.[7] However, ultrasound is limited in its ability to visualize the full extent of pelvic, iliac, and collateral venous anatomy, particularly in patients with congenital venous anomalies.

In patients with high clinical suspicion for thrombosis—such as those with prior DVT, interruption of anticoagulation, or known AIVC—negative initial ultrasound findings should prompt consideration of repeat imaging or cross-sectional modalities. Computed tomography venography and magnetic resonance venography provide more comprehensive evaluation of venous anatomy and thrombus burden and are recommended when diagnostic uncertainty persists.[7]

In this case, the initial negative DUS was followed by rapid clinical deterioration, prompting repeat imaging that demonstrated extensive hyperacute thrombosis. Additionally, the patient's PE were minimally symptomatic, causing no cardiopulmonary symptoms (ie, shortness of breath, chest pain) aside from tachycardia. This highlights the importance of considering thoracic imaging in patients with extensive thrombosis and known venous anomalies, even in the absence of classic cardiopulmonary symptoms.

Due to the rarity of AIVC and its frequent incidental discovery, management strategies have historically relied on case reports and small case series, with treatment approaches ranging from short-term anticoagulation to lifelong therapy, with or without thrombolysis.8–11 More recent reviews suggest improved outcomes with early thrombus removal combined with long-term anticoagulation.12,13

In a systematic review of 56 cases of DVT in patients with AIVC, 42.3% of patients managed conservatively with anticoagulation alone developed chronic symptoms such as residual pain, swelling, and heaviness. In contrast, only 11.5% of patients treated with thrombolysis followed by anticoagulation developed chronic symptoms, and none developed post-thrombotic syndrome. Additionally, recurrence rates were lower in the thrombolysis group (7.7%) compared to the conservatively managed group (13%).[13]

These findings suggest that catheter-directed thrombolysis combined with long-term anticoagulation may offer superior functional outcomes in selected patients with extensive iliofemoral thrombosis and AIVC. However, recurrence risk remains present regardless of treatment strategy, underscoring the importance of patient education and strict adherence to anticoagulation therapy.

CONCLUSION

This case highlights the increased risk of recurrent DVT and concurrent, clinically silent pulmonary embolism in patients with congenital absence of the inferior vena cava. It demonstrates the importance of repeat and advanced imaging following an initially negative duplex ultrasound when clinical suspicion for thrombosis remains high. Finally, this case supports the use of catheter-directed thrombolysis combined with lifelong anticoagulation in selected patients and emphasizes the critical role of medication adherence counseling. Emergency physicians should maintain heightened awareness of atypical presentations and concurrent thromboembolic disease in patients with known or suspected AIVC, and counsel appropriately for patient return protocol in the setting of initially negative imaging.

The authors attest that their institution requires neither Institutional Review Board approval, nor patient consent for publication of this case report. Documentation on file.

Address for Correspondence: Elise Bouchal, BS, BA, Mayo Clinic, Department of Emergency Medicine, 5951 East Mayo Blvd., Phoenix, AZ 85054. Email: Bouchal.elise@mayo.edu.

Conflicts of Interest: By the *CPC-EM* article submission agreement, all authors are required to disclose all affiliations, funding sources and financial or management relationships that could be perceived as potential sources of bias. The authors disclosed none.

Copyright: © 2026 Bouchal et al. This is an open access article distributed in accordance with the terms of the Creative Commons Attribution (CC BY 4.0) License. See: http://creativecommons.org/licenses/by/4.0/

REFERENCES

1. Saab K, Brahmandam AS, Brackett AL, et al. Systematic review of inferior vena cava atresia. *J Vasc Surg Venous Lymphat Disord.* 2023;11(6):1253-1264.
2. Tarango C, Kumar R, Patel M, et al. Inferior vena cava atresia predisposing to acute lower extremity deep vein thrombosis in children: a descriptive dual-center study. *Pediatr Blood Cancer.* 2018;65(2):e26785.
3. Cho BC, Choi HJ, Kang SM, et al. Congenital absence of inferior vena cava as a rare cause of pulmonary thromboembolism. *Yonsei Med J.* 2004;45(5):947-951.
4. Plumptre H, Giannoudi M, Kurian J. An unusual case of bilateral deep venous thrombosis with associated pulmonary embolus. *Oxf Med Case Rep.* 2022;2022(11):omac115.
5. D'Aloia A, Faggiano P, Fiorina C, et al. Absence of inferior vena cava as a rare cause of deep venous thrombosis complicated by liver and lung embolism. *Int J Cardiol.* 2003;88(2):327-329.
6. Arnoldussen CWKP. Imaging of deep venous pathology. *Cardiovasc Intervent Radiol.* 2024;47(12):1580-1594.
7. Barrosse-Antle ME, Patel KH, Kramer JA, et al. Point-of-care ultrasound for bedside diagnosis of lower extremity DVT. *Chest.*

2021;160(5):1853-1863.

8. Im D, Kang A, Kim SH, et al. Congenital absence of the inferior vena cava, a rare cause of deep vein thrombosis in adolescent: case report. *Medicine (Baltimore).* 2025;104(32):e43818.
9. Algaly G, Alsuyihili A, Parveen A. Extensive deep vein thrombosis in a young girl with absent inferior vena cava and iliac veins: a case report. *Oxf Med Case Rep.* 2023;2023(2):omad008.
10. Pulliam ZR and Kloecker G. Recurrent deep vein thrombosis in a middle-aged woman due to congenital absence of the inferior vena cava: a case report. *Cureus.* 2024;17(12):e100151.
11. Khalafallah AA, Renu S, Sharp C, et al. Extensive venous thrombosis in a healthy young man with a short inferior vena cava syndrome treated successfully with rivaroxaban. *BMJ Case Rep.* 2012;2012:bcr2012007313.
12. Tarazi M, Bashir A, Khan K, et al. A literature review and case series of DVT patients with absent IVC treated with thrombolysis. *Ann Vasc Surg.* 2020;67:521-531.
13. Alexiou VG, Ntanika A, Pappas G, et al. Conservative treatment vs thrombus removal for iliofemoral vein thrombosis in patients with congenital abnormalities of the inferior vena cava: a case report and systematic review of the literature. *J Thromb Thrombolysis.* 2022;54(2):230-254.