

UCLA

UCLA Previously Published Works

Title

Neuropathologic Findings in Elderly HIV-Positive Individuals

Permalink

<https://escholarship.org/uc/item/87v377mk>

Journal

Journal of Neuropathology & Experimental Neurology, 81(7)

ISSN

0022-3069

Authors

Magaki, Shino D

Vinters, Harry V

Williams, Christopher K

et al.

Publication Date


2022-06-20

DOI

10.1093/jnen/nlac040

Peer reviewed

# Neuropathologic Findings in Elderly HIV-Positive Individuals

Shino D. Magaki , MD, PhD, Harry V. Vinters, MD, Christopher K. Williams, Sergey Mareninov, BS, Negar Khanlou, MD, Jonathan Said, MD, Natasha Nemanim, MA, Jessica Gonzalez, BS, Jose G. Morales, BS, Elyse J. Singer, MD, and William H. Yong, MD<sup>1</sup>

## Abstract

The elderly HIV-positive population is growing due to the widespread use of combination antiretroviral therapy (cART), but the effects of longstanding HIV infection on brain aging are unknown. A significant proportion of HIV-positive individuals develop HIV-associated neurocognitive disorder (HAND) even on cART, but the pathogenesis of HAND is unknown. Although neuroinflammation is postulated to play an important role in aging and neurodegenerative diseases such as Alzheimer disease (AD), it is unclear whether HIV accelerates aging or increases the risk for AD. We examined the brains of 9 elderly HIV-positive subjects on cART without co-infection by hepatitis C virus compared to 7 elderly HIV-negative subjects. Microglial and astrocyte activation and AD pathologic change in association with systemic comorbidities and neurocognitive assessment were evaluated. There was no difference in microglial or astrocyte activation between our HIV-positive and HIV-negative cohorts. One HIV-positive subject and 2 HIV-negative subjects demonstrated significant amyloid deposition, predominantly in the form of diffuse senile plaques, but these individuals were cogni-

tively normal. Neurofibrillary tangles were sparse in the HIV-positive cohort. There was a high prevalence of cardiovascular comorbidities in all subjects. These findings suggest that multiple factors likely contribute to aging and cognitive impairment in elderly HIV-positive individuals on cART.

**Key Words:** Aging, Alzheimer disease, Cognitive impairment, Human immunodeficiency virus, Neurodegeneration.

## INTRODUCTION

Life expectancy has approached population norms in individuals living with HIV due to the success of combination antiretroviral therapy (cART), or highly active antiretroviral therapy (HAART), with individuals over 55 years of age becoming the fastest-growing group in the HIV-infected adult population in the United States (1–3). However, this results in additional comorbidities associated with aging. HIV-positive individuals have an increased risk for aging-related comorbidities such as cardiovascular disease, metabolic disorders, neoplasms, and cognitive impairment (4, 5). HIV-associated neurocognitive disorders (HAND) comprise a spectrum of cognitive dysfunction associated with HIV infection, ranging from asymptomatic neurocognitive impairment and mild neurocognitive disorder to HIV-associated dementia (HAD), which affects approximately 30%–50% of treated HIV-positive individuals (1, 6). The incidence of the most severe manifestation, HAD, which had been attributed to severe HIV infection, or HIV encephalitis (HIVE), has decreased with the advent of cART (7). However, there is an increasing prevalence of the milder forms of HAND, the pathogenesis and neuropathologic substrates of which are unclear (4). Although evidence suggests that HIV-positive subjects have a premature aging phenotype in brain tissue and peripheral blood based on DNA methylation analysis (3, 8), it is unknown whether HIV infection confers an increased risk for and/or exerts synergistic effects with other neurodegenerative diseases such as Alzheimer disease (AD) (9). This population also frequently has multiple comorbidities such as co-infection with hepatitis C virus (HCV) and substance abuse that may exacerbate age-related neurodegeneration and contribute to cognitive impairment (5).

From the Section of Neuropathology, Department of Pathology and Laboratory Medicine, Ronald Reagan UCLA Medical Center and David Geffen School of Medicine, Los Angeles, CA, USA (SDM, HVV, CKW, SM, NK, WHY); Department of Pathology and Laboratory Medicine, Ronald Reagan UCLA Medical Center and David Geffen School of Medicine, Los Angeles, CA, USA (JS); Department of Neurology, Ronald Reagan UCLA Medical Center and David Geffen School of Medicine, Los Angeles, CA, USA (HVV, NN, JG, JGM, EJS); Brain Research Institute, University of California, Los Angeles, CA, USA (HVV).

Send correspondence to: Shino D. Magaki, MD, PhD, Department of Pathology and Laboratory Medicine, David Geffen School of Medicine at University of California-Los Angeles, 10833 Le Conte Ave., Los Angeles, CA 90095, USA; E-mail: smagaki@mednet.ucla.edu

Elyse J. Singer and William H. Yong contributed equally to this work.

<sup>1</sup>Present address: Department of Pathology and Laboratory Medicine, University of California-Irvine School of Medicine, Irvine, CA, USA.

This publication was made possible from NIH funding through the National Institute of Mental Health (NIMH) and National Institute of Neurological Disorders and Stroke (NINDS) Institutes by the following grants: Texas NeuroAIDS Research Center: U24MH100930, California NeuroAIDS Tissue Network: U24MH100928, National Neurological AIDS Bank: U24MH100929, Manhattan HIV Brain Bank: U24MH100931, and the Data Coordinating Center: U24MH100925. Its contents are solely the responsibility of the authors and do not necessarily represent the official view of the NNTC or NIH.

The authors have no duality or conflicts of interest to declare.

The need to characterize brain aging in individuals with HIV and differentiate HAND from other neurodegenerative diseases of aging is an emerging health problem. Even in virally suppressed patients, HIV DNA persists in microglia and macrophages in the brain and is thought to cause a chronic inflammatory state contributing to neuronal damage and dysfunction (10, 11). Neuroinflammation in the form of activated microglia and astrocytes and elevated cytokines plays a significant role in aging and AD (3). While there have been reports of elevated PET tracer retention using [18F] florbetaben and [18F] FDDNP in subjects with HIV (1, 5), 2 series from the US and Australia did not detect elevated <sup>11</sup>C-PiB levels (indicative of amyloid deposition) in HIV-positive subjects with or without cognitive impairment (12, 13). These studies did not have confirmatory autopsy follow-up, however. A few autopsy studies of subjects in both the pre- and post-cART era have suggested accelerated amyloid (14, 15), and tau deposition (16) in HIV-positive individuals. One recent study demonstrated neuropathologically confirmed AD changes in 2 individuals, one of whom was demented and the other who was cognitively intact, suggesting multiple factors likely underlying cognitive impairment in HIV-positive individuals (17).

To help shed light on brain aging in HIV infection, we characterized vascular and other comorbidities through clinical assessment and autopsy examination in elderly HIV-positive individuals on cART without HCV co-infection. We further examined astrocytic and microglial activation and AD neuropathologic change, including senile plaques and neurofibrillary tangles (NFTs), in the brains of elderly HIV-positive subjects compared to elderly HIV-negative individuals.

## MATERIALS AND METHODS

### Study Cohort Demographics and Autopsy Tissue

All autopsy brain tissue was obtained from subjects enrolled in the National NeuroAIDS Tissue Consortium (NNTC), which includes 4 clinical sites across the United States, funded by the National Institute of Mental Health (NIMH) and National Institute of Neurological Disorders and Stroke (NINDS). The centers clinically follow HIV-infected individuals to autopsy and maintain well-characterized central nervous system (CNS) and non-CNS tissue and fluid from HIV-positive and HIV-negative individuals, many of whom have undergone extensive neurocognitive and laboratory testing (18). Clinical, neuropsychiatric, laboratory, and pathologic datasets are standardized across all sites.

For our HIV-positive and HIV-negative cohorts, inclusion criteria were age 58 years or older and without hepatitis B (HBV) or HCV infection. Approximately 10%–30% of all HIV-positive patients and up to 90% of those with a history of injection drug use have co-infection with HBV or HCV (19). HCV infection itself is associated with neurocognitive impairment and may have additive effects on cognition in HIV-positive patients even with low HIV viral loads (20–22). The duration of HIV infection was obtained from the first date of HIV-seropositive diagnosis and date of death. The clinical

comorbidities assessed included: hypertension, diabetes mellitus, hyperlipidemia, viral hepatitis (all cases with viral hepatitis excluded in our study), end-stage liver disease, chronic renal disease, cardiac disease, chronic obstructive pulmonary disease (COPD), non-acquired immunodeficiency syndrome (AIDS) defining cancer, lipodystrophy, and tobacco smoking. Standardized protocols were used to evaluate for neurocognitive impairment and neuropsychiatric disease according to established criteria (18, 23, 24). Subjects underwent neurocognitive assessment performed according to the American Academy of Neurology (AAN) criteria for HIV-associated neurocognitive disorders (25, 26). Neurologic examination was performed by board-certified neurologists which included administration of the Mini-Mental Status Exam (MMSE) and HIV Dementia Scale (HDS). Neuropsychological testing was performed by a trained neuropsychometry technician under the supervision of a board-certified neuropsychologist. From each subject, blood was collected and evaluated for plasma viral load, CD4 count, and HCV and syphilis serology. In some subjects, cerebrospinal fluid (CSF) was obtained and CSF viral load measured. At autopsy, the brain and spinal cord, and (in the majority of cases), tissue from other sites including heart, lung, kidney, liver, and gastrointestinal tract, was collected and subsequently divided for freezing and formalin fixation. Microscopic examination of formalin-fixed paraffin-embedded (FFPE) tissue was performed by board-certified pathologists according to the NNTC standard protocol (18). The brain was examined macroscopically and microscopically and assessed using uniform neuropathologic datasets. This included evaluation for vascular disease such as the presence or absence of atherosclerosis (severe or not severe), arteriolosclerosis and cerebral amyloid angiopathy, hypoxic/ischemic change/lesions, hemorrhage, white matter changes, Alzheimer type 2 astrocytes, active or chronic infection and inflammation, and neoplasms. Non-CNS datasets included atherosclerosis, myocardial infarct, acute and chronic pulmonary disease, pulmonary thromboembolism, glomerulopathy, nephropathy, and liver steatosis/steatohepatitis, among other findings (18). HIV-related CNS pathology was evaluated according to criteria initially proposed by Budka et al (27). MRI data were not available for these subjects.

As we looked for subtle changes, we limited tissue to the NNTC as all sites follow a standardized protocol for clinical assessment of the subjects as well as tissue collection, processing, and evaluation. Thus, the cases are a convenience sample restricted by the availability of tissue from this well characterized cohort. Subjects with any active infectious or inflammatory process seen on routine neuropathologic evaluation were excluded to prevent confounding by HIVE and opportunistic infections. Further inclusion criteria were a post-mortem interval of less than 48 hours and, for the HIV-positive cohort, that subjects were on active cART (defined as cART therapy within approximately 12 months of death (28)), which resulted in 10 HIV-positive subjects and 8 HIV-negative subjects that met all inclusion and exclusion criteria in this study. Extensive FFPE tissue preservation artifact precluded accurate evaluation of one subject in each cohort, limiting the tissues available for assessment to 9 HIV-positive and 7 HIV-negative subjects. The investigation was conducted in

accordance with the guidelines of the institutional review board at the respective sites.

## Neuropathologic Examination and Image Analysis

FFPE tissue from the frontal and temporal cortices sectioned at 6  $\mu\text{m}$  in thickness were obtained from the following NNTC member sites: National Neurological AIDS Bank (NNAB) at University of California, Los Angeles, CA; Texas NeuroAIDS Research Center (TNRC) at University of Texas Medical Branch, Galveston, TX; and California NeuroAIDS Tissue Network (CNTN) at University of California, San Diego. Immunohistochemistry was performed with antibodies to  $\beta$ -amyloid 1–42 (1:1000, EMD Millipore [Burlington, MA], rabbit polyclonal, AB5078P) for amyloid plaques, phospho-tau (1:1000, ThermoFisher [Waltham, MA], mouse monoclonal, AT8) for NFTs and neuropil threads, glial fibrillary acid protein (GFAP) (1:100, BioCare [Pacheco, CA], rabbit polyclonal) for astrocytes, and ionized calcium-binding adaptor molecule (Iba-1) (1:100, EMD Millipore, mouse monoclonal, Clone 20A12.1) for microglia. Sections were incubated with the primary antibody followed by either horse anti-mouse or horse anti-rabbit secondary antibody conjugated to horseradish peroxidase (MP7402 and MP7401; Vector Laboratories, Burlingame, CA). Antibody reactivity was visualized with N'N diaminobenzidine as chromogen (no. SK-4100; Vector Laboratories) and counterstained with hematoxylin. Specimens from both HIV-positive and HIV-negative subjects were processed side by side under the same conditions. Slides were then scanned and digitized using the ScanScope image scanner (Aperio Technologies, Vista, CA).

Microglia and astrocytes were evaluated by both positive pixel counting and manual cell count. Iba-1 is a pan-microglial immunohistochemical marker known to label all microglia independent of activation state and is useful in the evaluation of microglial morphology into non-activated and activated subtypes (29, 30). GFAP is an intermediate filament protein that in the CNS is expressed exclusively, though not by all, astrocytes and shows higher expression in white matter compared to gray matter (31, 32). GFAP is a sensitive immunohistochemical marker for reactive astrocytes, with GFAP expression being essential for the process of reactive astrogliosis although not necessary for normal astrocyte function (33). The percentage of immunoreactivity for Iba-1 and GFAP were semi-quantitatively analyzed using the positive pixel count algorithm in the ImageScope program with the following parameters: hue value of 0.1, hue width of 0.175, and color saturation threshold of 0.19. The positivity (percentage of positive pixels) was calculated from the number of positive pixels divided by the total number of pixels (positive and negative) and multiplied by 100. Parameters were kept constant across groups for each antibody. Microglia were counted according to the method by Mao et al (34) except they were counted within an area between 0.5 and 1  $\text{mm}^2$  in 5 random areas each from the gray matter and white matter and density of microglia calculated per  $\text{mm}^2$ . Microglia were subtyped into ramified and activated, with amoeboid microglia incorporated into activated microglia as they were rare; the percentages of activated

microglia were then calculated in each area (29). GFAP-positive astrocytes were counted in a manner similar to microglia and similarly grouped into normal and abnormal based on morphologic features on GFAP staining as previously described (35, 36). Only microglia and astrocytes with nuclei in the plane of section were counted (35).

Sections were also examined for amyloid (senile) plaques and NFTs, characteristic neuropathologic features of AD. The degree of amyloid deposition as senile plaques was scored as none, sparse, moderate, and abundant. Neuritic plaques, a subset of senile plaques associated with dystrophic neurites which are more strongly associated with AD, were separately scored as none = 0, sparse = 1, moderate = 2, and frequent = 3 according to the Consortium to Establish a Registry for Alzheimer's Disease (CERAD) criteria (37) in the NIA-AA guidelines for the neuropathologic assessment of Alzheimer disease (38). NFTs were counted according to the method of Jeynes and Provias (39) in which 10 contiguous fields, encompassing the full cortical thickness, were examined to assess the density of NFTs per field, except at 200 $\times$  magnification instead of 250 $\times$ . APOE genotype was determined in all HIV-positive and HIV-negative subjects.

## Statistical Analysis

The Shapiro-Wilk test was used to assess for normality of the data. The unequal variances *t*-test was used for data with a normal distribution and nonparametric Mann-Whitney *U* test for non-normally distributed values to determine differences between groups. A *p* value <0.05 was considered statistically significant.

## RESULTS

### Study Cohort

Demographic characteristics and medically significant comorbid conditions of HIV-positive and HIV-negative subjects are shown in Table 1. There were 9 HIV-positive subjects (mean age = 63.2  $\pm$  4.5 [SD] years, range = 60–73) and 7 HIV-negative subjects (mean age = 71.3  $\pm$  7.9 years, range = 62–85). The mean age of the HIV-positive cohort was approximately 8 years younger than the HIV-negative cohort (*p* = 0.008). Although clinical comorbidity information was incomplete, 4 subjects had one or more cardio- or cerebrovascular comorbidities (including hypertension, hyperlipidemia, and stroke), one subject had chronic kidney disease, and one subject had a history of malignancy (non-Hodgkin lymphoma) in our HIV-positive cohort. Of the 2 subjects (P4 and P6) with clinical history of stroke, both of whom also had cognitive impairment, subject P4 additionally had a history of hypertension, hyperlipidemia, COPD, and tobacco smoking. Subject P6 also had a history of hypertension, hyperlipidemia, and tobacco smoking. In the HIV-negative cohort, 6 subjects had one or more cardio- or cerebrovascular comorbidities (including hypertension, hyperlipidemia, and diabetes mellitus) and 4 subjects had a history of malignancy (squamous cell carcinoma, basal cell carcinoma, and metastatic prostate carcinoma). Subject N7 with clinical history of stroke also had hypertension and hyperlipidemia.

**TABLE 1.** Subject Demographics, Clinical Diagnoses, and Non-CNS Pathologic Comorbidities

	HIV-positive (n = 9)	HIV-negative (n = 7)
Demographics		
Age at death, years (mean ± SD)	63.2 ± 4.5	71.3 ± 7.9
Male/female	9/0	5/2
Caucasian/African American	6/3	7/0
Clinical comorbidities		
Hypertension	3	3
Diabetes mellitus	0	1
Hyperlipidemia	3	2
Cardiac disease	1	3
Chronic obstructive pulmonary disease	2	1
End-stage liver disease	0	0
Chronic renal disease	1	0
Cancer*	1	4
Cerebrovascular disease	2	1
Lipodystrophy	1	Not applicable
Tobacco smoking	4	2
Non-CNS pathologic comorbidities		
Systemic atherosclerosis	6	7
Coronary artery disease	4	4
Myocardial infarct	0	2
Pneumonia	5	3
Diffuse alveolar damage	1	0
Chronic lung disease	2	2
Steatosis/steatohepatitis	3	4
Chronic renal disease	5	4
Malignancy	3	1
Non-AIDS defining for HIV-positive cohort.		

There was no significant difference in the years of education between HIV-positive (mean number of years = 14.4 ± 3.2 [SD] years, range = 9 to 18) and HIV-negative subjects (mean number of years = 17.0 ± 2.2 years, range = 13 to 20) although there was a trend toward a greater number of years of education in the HIV-negative cohort ( $p = 0.08$ ) (Table 2). In the HIV-positive cohort, 3 subjects were cognitively normal while one subject was diagnosed with neuropsychological impairment that did not meet the criteria for a syndromic disorder. Four subjects were diagnosed with neuropsychological impairment or dementia due to other causes and included one subject (P6) whose neurocognitive impairment was thought to be due to *Toxoplasma* encephalitis that was not, however, confirmed on neuropathologic examination. One subject was diagnosed with probable minor cognitive motor disorder. The majority (6 of 10 subjects) had possible to definite HIV-associated distal symmetrical polyneuropathy. In one subject the neuropathy was thought to be due to combined HIV effect and nucleoside therapy. All HIV-negative subjects were neurocognitively normal.

In the HIV-positive cohort, the mean duration of HIV infection was 11 years and ranged from 5 to 24 years (Table 2). Four subjects likely contracted HIV through male-to-male sex and 2 through an unknown route. CD4 T-cell counts obtained

approximately within 6 months of death except for subject P9, for whom the last CD4 T-cell count was obtained slightly over 3 years prior to death, were low and ranged from 61 to 497 cells/mm<sup>3</sup>. All subjects except 2 met criteria for advanced HIV infection according to the WHO definition (40) during their disease course with a single measurement or nadir CD4 T-cell count of <200 cells/mm<sup>3</sup> with 2 subjects having a nadir of <50 cells/mm<sup>3</sup>. The subject (P2) with a nadir of 30 cells/mm<sup>3</sup> concurrently had an undetectable plasma viral load but had undergone chemoradiation for diffuse large B-cell lymphoma 1–2 months prior to the measurement. The other subject (P8) had a concurrent plasma viral load of 141 433 copies/mL 9 months prior to death although the CD4 T-cell count recovered to 289 cells/mm<sup>3</sup> 4 months prior to death, at which time point viral load was undetectable. In 4 subjects, plasma viral loads were consistently below the limit of detection which differed based on when the measurement was taken due to different assays utilized at the time (<20 to 400 copies/mL). CSF viral loads were available in 5 subjects with undetectable CSF viral loads in all except subject P5, who had a CSF viral load of >14 000 copies/mL at death even though he had an undetectable plasma viral load 4 months prior.

## Pathologic Findings

Non-CNS pathologic findings included malignancies such as metastatic adenosquamous carcinoma originating from the gastroesophageal junction, lung carcinoma, and diffuse large B-cell lymphoma in 3 HIV-positive subjects (Table 1). The majority demonstrated some degree of systemic and/or coronary artery atherosclerosis, confirming clinical assessment, with 3 subjects showing severe coronary artery disease. Five subjects had pneumonia, many with severe infection, with subject P1 demonstrating infection by *Aspergillus* species with necrosis and abscess formation, subject P8 showing necrotizing and hemorrhagic bacterial infection, and subject P9 both bacterial and Cryptococcal pneumonia. Subject P9 also had end-stage renal disease on autopsy examination as well as severe coronary artery disease and biventricular cardiac hypertrophy. Among the HIV-negative cohort, 3 subjects had pneumonia, 4 subjects had coronary artery disease ranging from mild to severe, and 1 patient demonstrated prostatic adenocarcinoma metastatic to the lungs and liver and acute myeloid leukemia.

## Neuropathologic Findings

There were no significant findings on gross examination except in one subject (P9) who demonstrated arteriolosclerosis and severe atherosclerosis although there were no ischemic changes in the brain parenchyma on microscopic examination (Table 3). On the other hand, 2 subjects showed focal infarct/ischemic change but no significant arteriolosclerosis or atherosclerosis; subject P4 with clinical history of stroke demonstrated no infarcts or vascular changes. Despite the elevated CSF viral load at death, subject P5 showed no significant changes on neuropathologic examination. Subject P6, who had a clinical history of stroke and was suspected to have *Toxoplasma* encephalitis (which was not confirmed on patho-

**TABLE 2. HIV-Related Demographic and Laboratory Data and Neurologic Diagnoses in HIV-Positive Cohort**

Case	Age	Edu	AAN	HIV Infection (Years)	Risk Factors	CD4 Count (cells/ $\mu$ L)		Plasma Viral Load (Copies/mL)		CSF Viral Load (Copies/mL)	
						Last	Nadir	Last	Peak	Last	Peak
P1	68	13	Normal	6	MSM	427	251	<40	<400	<40	<50
P2	61	14	Normal	24	MSM	137	30	<400	<400	n/a	n/a
P3	60	16	Other cause	11	MSM	398	Single*	n/a	n/a	n/a	n/a
P4	60	12	Other cause	6	Unknown	497	177	<48	900	n/a	n/a
P5	64	9	Other, non-syndromic	5	Heter	61	61	<75	12563	14636	Single*
P6	60	18	Other cause	8	MSM, heter	244	169	<400	<400	<50	Single*
P7	61	12	Probable MCMD	13	Unknown	73	Single*	<20	<400	n/a	n/a
P8	62	18	Other cause	9	Heter, IVD	289	22	<75	141433	<12	<12
P9	73	18	Normal	19	MSM	191	162	<20	29512	<50	<50

Single data point.

AAN, American Academy of Neurology criteria for HIV associated neurocognitive disorder; Age, age at death; Edu, years of education; heter, heterosexual exposure; HIV infection, duration of HIV infection; IVD, intravenous drug use; MCMD, minor cognitive motor disorder; MSM, male-to-male sex; n/a, not available; other cause, neuropsychological impairment or dementia due to other cause; other, non-syndromic, neuropsychological impairment, does not meet criteria for syndromic disorder.

logic examination) showed focal superficial cortical necrosis, microhemorrhage, and white matter pallor and gliosis. As he did not show significant atherosclerosis or arteriolosclerosis, the pathologic changes may have been sequelae of prior infection. In the HIV-negative cohort, subject N4 showed arteriolosclerosis and focal old microinfarcts in the basal ganglia and cerebellum, and subject N5 showed focal laminar necrosis in the occipital cortex. Subject N6 demonstrated acute microhemorrhage and leukemic cells within the vasculature but no brain parenchymal involvement. No other neoplasms were identified in any of the subjects. The one subject with clinical history of stroke (N7) did not show infarcts on neuropathologic examination. Most of the HIV-positive and HIV-negative subjects did not show significant atherosclerosis or arteriolosclerosis, perhaps because of their relatively younger age compared to many dementia cohorts.

On immunohistochemistry, there was a spectrum of microglial morphology including ramified/resting microglia with small bodies and thin long processes (Fig. 1D), activated microglia with enlarged cell bodies and bushy processes, and rarely, amoeboid microglia with enlarged cell bodies lacking processes, consistent with what has been described previously (41). No difference in Iba-1 immunoreactivity by positive pixel analysis, density of microglia or the percentage of activated microglia was seen between HIV-positive and HIV-negative subjects in the gray and white matter of the frontal and temporal lobes (Fig. 1). No microglial nodules or multinucleated giant cells were seen. Normal appearing astrocytes demonstrate a small body and long processes (Fig. 2D) while reactive, abnormal appearing astrocytes have an enlarged cell body and shortened processes or lack processes, changes which can be seen in aging and post-stroke patients (35). Most subjects showed predominantly normal appearing astrocytes although a few subjects showed many astrocytes with enlarged soma and short thickened processes despite no other findings in the section. There was also no significant difference in GFAP immunoreactivity, astrocyte density, or percentage of activated astrocytes between the groups (Fig. 2).

Four HIV-positive subjects demonstrated amyloid plaques either in the frontal or temporal cortex or both with 3 showing only sparse diffuse plaques (Table 4). One subject (P9) demonstrated abundant senile plaques in both temporal and frontal cortices, predominantly of the diffuse type with sparse neuritic plaques only in the temporal lobe but was cognitively normal. Two subjects each in the HIV-positive and HIV-negative cohorts were APOE  $\epsilon$ 3/ $\epsilon$ 4 heterozygote, one of whom had abundant plaques and the other sparse plaques in both cohorts. The remainder of the HIV-positive subjects were homozygous for  $\epsilon$ 3, 2 of whom showed sparse plaques and the remainder an absence of plaques. One HIV-negative subject was an APOE  $\epsilon$ 2/ $\epsilon$ 4 heterozygote with no plaques. The remainder were homozygous for  $\epsilon$ 3, one of whom showed abundant plaques in the frontal cortex. HIV-positive subjects had absent to rare NFTs in the temporal lobe and no NFTs seen in the frontal cortex although the 2 subjects with the most, albeit sparse, NFTs (P8 and P9) demonstrated rare neuropil threads in the frontal cortex. Despite all HIV-negative subjects having normal cognition, 2 HIV-negative subjects had rare to scattered NFTs in the frontal cortex and abundant amyloid plaques

**TABLE 3.** Neuropathologic Findings

Case	Vascular Disease	Ischemia	Hemorrhage
HIV positive			
P1	—	—	—
P2	—	—	—
P3	—	—	—
P4	—	—	—
P5	—	—	—
P6	—	+ (superficial cortical necrosis)	+ (microhemorrhage)
P7	—	+ (focal infarct)	—
P8	—	+ (focal infarct, ischemic change)	—
P9	+ (arteriolosclerosis, severe atherosclerosis)	—	—
HIV negative			
N1	—	—	—
N2	—	—	—
N3	—	—	—
N4	+ (arteriolosclerosis)	+ (microinfarcts)	—
N5	—	+ (focal laminar necrosis)	—
N6	—	—	+ (microhemorrhage)
N7	u	—	—

+, present; —, absent; u, unknown.

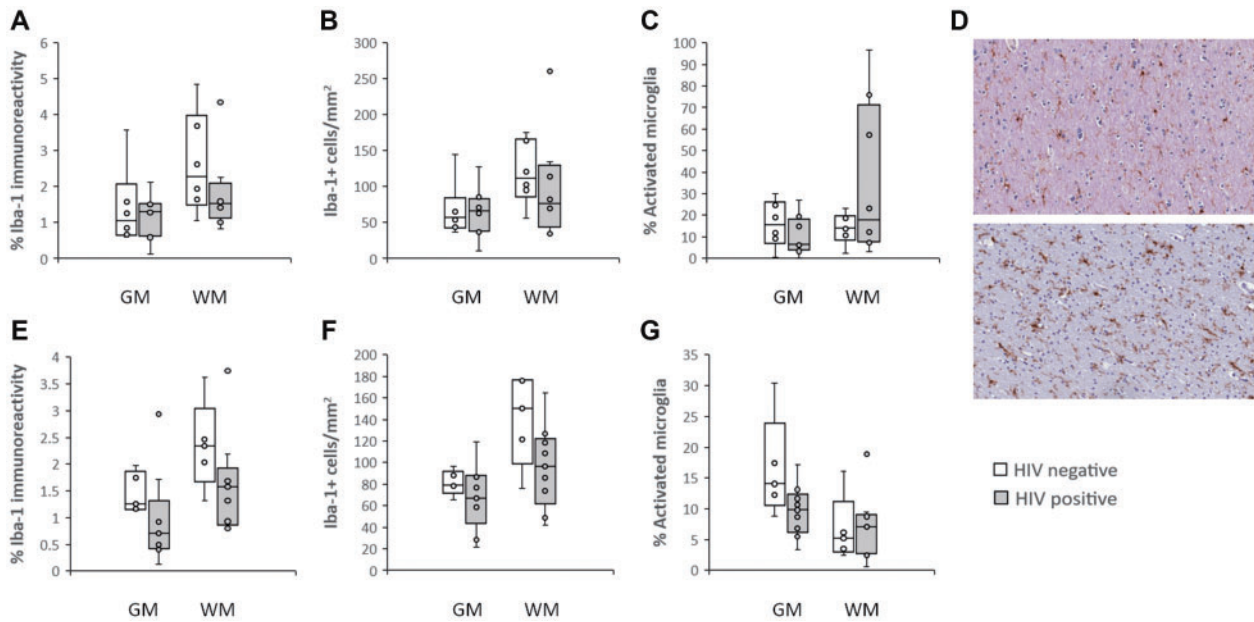
with a moderate density of neuritic plaques in the frontal cortex, exemplifying the often poor correlation between senile plaques and cognitive impairment (42). Two HIV-negative subjects (N4 and N5) demonstrated a mild to moderate density of NFTs in the hippocampus and entorhinal cortex extending to the temporal cortex but with no amyloid deposition in the frontal or temporal cortices, suggestive of primary age-related tauopathy (PART), a neuropathologic finding commonly observed in elderly individuals with varying clinical manifestations ranging from no neuropsychologic abnormalities to severe cognitive impairment (43).

## DISCUSSION

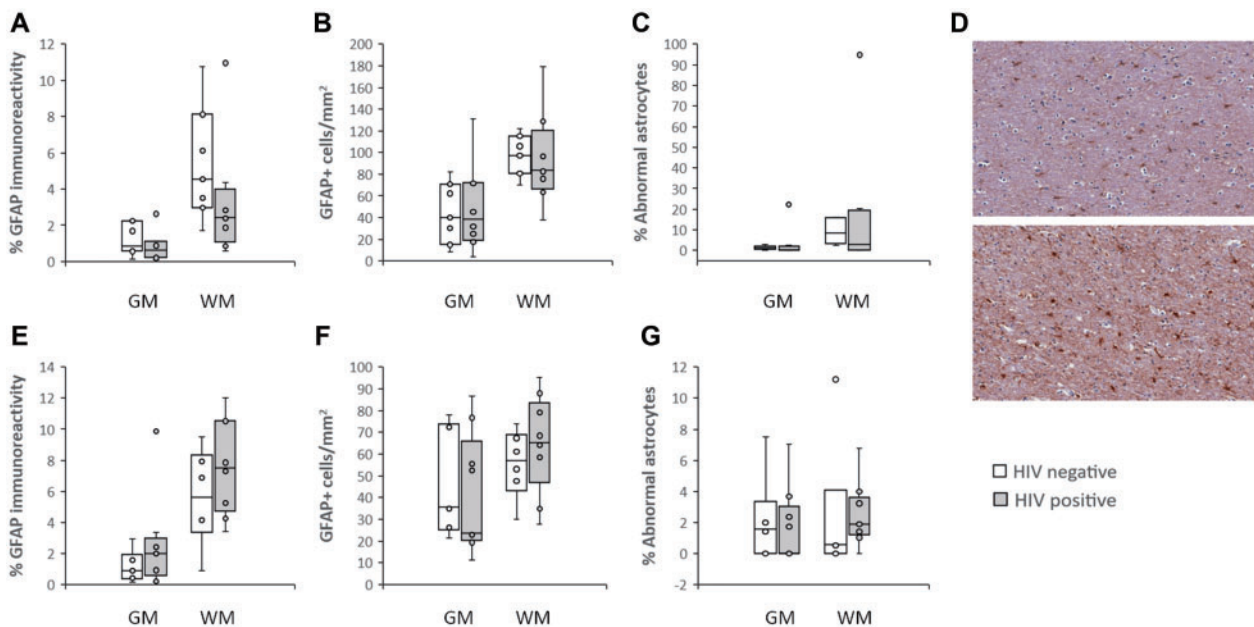
Currently half of the individuals living with HIV are over 50 years of age and there is a need to characterize aging in this cohort (3). Imaging studies have demonstrated premature brain aging in HIV-positive subjects (44, 45). Resting cerebral blood flow and functional brain demands as assessed by arterial spin labeling and functional MRI, respectively, are decreased in HIV-positive individuals compared to HIV-negative subjects (46, 47). Volume deficits have also been seen in several regions including frontal, temporal, and parietal cortices and thalamus in HIV-infection, with these changes likely conferring increased risk for cognitive impairment and dementia (45, 47). Even in the post-cART era up to half of individuals with HIV have HAND even though milder forms of the disease predominate (7). Cardiovascular disease, drug use and HCV infection, all common comorbidities in individuals with HIV, are also risk factors for cognitive impairment (44). Furthermore, certain antiretroviral drugs have been associated with neurotoxicity as well as dyslipidemia and insulin resistance (4). In this study, the majority of HIV-positive sub-

jects and all HIV-negative subjects had cardiovascular comorbidities such as coronary artery disease and arteriolosclerosis. In both the HIV-positive and HIV-negative cohort, pneumonia was common at autopsy. Despite all HIV-positive subjects being on cART, several individuals showed severe pneumonia with fungal and bacterial organisms detected on histologic examination, consistent with underlying immune dysregulation.

Before cART, the majority of HIV-positive individuals progressed to AIDS with 20%–30% at autopsy showing HIVE, which was thought to be the neuropathologic substrate of dementia in many of these patients even though neurologic symptoms were also commonly caused by opportunistic infections (5, 48). HIVE is characterized by microgliosis with microglial nodules, frequent multinucleated giant cells, astrogliosis, neuronal and myelin loss, and high viral burden (7, 48). Since the advent of cART, many patients with dementia do not demonstrate HIVE whereas decedents with HIVE are often not demented (9, 48, 49). Different pathogenic mechanisms may underlie neurocognitive impairment in the post-cART era. Indeed, more cortical involvement, rather than the subcortical involvement in the pre-cART era, is observed clinically (5, 6). Patterns of cognitive impairment in the post-cART era show more resemblance to neurodegenerative disorders common in the general population (5, 6). Possible contributing factors include effects of longstanding HIV infection, side effects of therapy, accelerated aging, and/or increased risk for neurodegenerative diseases such as AD (5, 7). Characterizing the neuropathologic findings in elderly HIV-positive individuals on cART may help elucidate the pathophysiology of cognitive impairment in these subjects (50). Recently it has been demonstrated that production of amyloid beta (A $\beta$ ), which comprises one of the pathologic hallmarks of AD, amyloid plaques, is increased in HIV infection and that



**FIGURE 1.** Box and whisker plots demonstrating immunoreactivity for Iba-1 (**A**), density of Iba-1-positive microglia (**B**), and percentage of activated Iba-1-positive microglia (**C**) in the frontal lobe (HIV-positive, n = 8; HIV-negative, n = 6) and temporal lobe (HIV-positive, n = 9; HIV-negative, n = 5) (**E-G**) of elderly HIV-positive and HIV-negative subjects. (**D**) Representative images from the frontal lobe white matter showing morphology of resting/ramified microglia in the upper panel and activated microglia with hypertrophy and decreased branching in the lower panel on Iba-1 immunohistochemistry (200×). GM, gray matter; WM, white matter.



**FIGURE 2.** Box and whisker plots demonstrating immunoreactivity for GFAP (**A**), density of GFAP-positive astrocytes (**B**), and percentage of abnormal GFAP-positive astrocytes (**C**) in the frontal lobe (HIV-positive, n = 8; HIV-negative, n = 7) and temporal lobe (HIV-positive, n = 9; HIV-negative, n = 6) (**E-G**) in elderly HIV-positive and HIV-negative subjects. (**D**) Representative images from the frontal lobe white matter showing morphology of normal appearing GFAP-positive astrocytes with elongated processes in the upper panel and abnormal astrocytes with enlarged soma and short thickened processes in the lower panel (200×). GM, gray matter; WM, white matter.



**TABLE 4.** Senile Plaques and Neurofibrillary Tangles

Case	APOE Genotype	Senile Plaques (Neuritic)		Neurofibrillary Tangles*	
		Temporal	Frontal	Temporal	Frontal
HIV positive					
P1	E3/E3	None	None	0	0
P2	E3/E3	None	Sparse (0)	0.1	0
P3	E3/E4	Sparse (0)	None	0.1	0
P4	E3/E3	None	None	0.2	0
P5	E3/E3	None	n/a	0	n/a
P6	E3/E3	None	None	0	0
P7	E3/E3	None	None	0	0
P8	E3/E3	Sparse (0)	Sparse (0)	0.2	0
P9	E3/E4	Abundant (1)	Abundant (0)	0.8	0
HIV negative					
N1	E3/E4	None	Sparse (0)	0.1	0
N2	E2/E4	None	None	0.1	0.1
N3	E3/E3	None	None	0	0
N4	E3/E3	None	None	1.6	0
N5	E3/E3	None	None	3.3	0
N6	E3/E3	n/a	Abundant (2)	n/a	0.5
N7	E3/E4	Abundant (2)	Abundant (2)	0.3	1.6

Density of neurofibrillary tangles per 200× field.  
n/a, not available.

A $\beta$  peptide has antiviral properties (51). It is unclear, however, whether HIV is a risk factor for AD or can occur synergistically with AD to cause dementia (50, 51).

HIV enters the CNS during the initial stage of systemic infection, likely through infected monocytes that migrate across the blood-brain barrier (BBB) to replenish perivascular macrophages (46, 52, 53). This causes inflammation of the leptomeninges and vasculitis, leading to disruption of the BBB as well as parenchymal inflammation and neuronal and glial dysfunction, the longstanding effects of which are unknown (46, 52, 53). Chronic inflammation is thought to play an important role in aging and neurodegenerative disease, and persistent neuroinflammation from low HIV loads may exacerbate aging changes (3). Using highly sensitive in situ hybridization techniques, Ko et al (10) demonstrated that HIV DNA can be demonstrated in the brains of all virally suppressed HIV-positive individuals in microglia/macrophages, especially perivascular macrophages. This suggests that even with cART, HIV persists in the brain in macrophages/microglia which serve as reservoirs and cause chronic inflammation and neuronal dysfunction (10, 11). In patients on cART these downstream effects rather than viral load are more strongly associated with cognitive dysfunction (6). HAND is seen even in individuals with undetectable plasma viral loads (10). Gelman et al (28) have shown that patients with both HAND and HIVE have higher HIV RNA and DNA levels than patients without HAND but patients with HAND without HIVE have no difference in brain viral load compared to patients without HAND. Radiologic studies using PET with [11C]DPA-713 to image the translocator protein, a marker of microglial activation, in HIV-positive individuals have shown that microglial

activation in the frontal, temporal, and occipital cortices as assessed by higher [11C]DPA-713 binding was inversely associated with cognitive performance (54). All of our HIV-positive subjects were on cART and for the 5 subjects in whom CSF viral loads were available, only one subject (P5) had a detectable viral load. However, many of the subjects had longstanding HIV infection, at minimum 5 years and up to 24 years, and all subjects except 2 had a CD4 T-cell count that would have met criteria for advanced HIV infection at some point during their disease course. There is increasing evidence that early viral infection with decreased CD4 counts cause residual cognitive impairment even when CD4 counts increase and viral load is subsequently suppressed (45).

Sensitive in situ studies of human postmortem brains have detected HIV-1 DNA, and in a minority of cases viral RNA, exclusively in microglia/macrophages and not astrocytes, but productive infection has also been detected in astrocytes at least in vitro (5, 10, 55). Infected microglia release viral proteins and cytokines such as tumor necrosis factor with neurotoxic effects (53). Cytokines further activate macrophages and microglia as well as astrocytes (53). Astrocytes are key regulators of brain homeostasis and crucial in the maintenance of the BBB (53). The astrogliosis characteristic of HIVE can be seen even in virally suppressed individuals (5), and Solomon et al (7) reported a trend toward a greater proportion of subjects with gliosis as assessed by GFAP in HIV-positive subjects with and without varying degrees of cognitive impairment compared to HIV-negative subjects. Reactive astrogliosis is also associated with aging and AD (53), with an increase in GFAP expression the most frequent change in astrocytes with age, especially after 65 years (56). This in-

crease is not due to a greater number of GFAP-positive astrocytes but an increase in the expression of GFAP per cell suggesting that a greater portion of astrocytes are transformed into reactive astrocytes with age, especially in the white matter (32). Although the role of astrocytes in AD is unclear, GFAP levels are increased in AD patients, especially in the temporal lobe (57), and GFAP-positive astrocytes have been seen in proximity to amyloid plaques (7, 58).

In our cohort, we did not see a difference in the density or proportion of activated microglia or GFAP-positive astrocytes demonstrating reactive change in the frontal and temporal cortices between elderly HIV-positive and HIV-negative subjects. The difference between this study and prior studies may be due to the exclusion of individuals with HIVE and HCV co-infection, as we aimed to exclude as many confounding parameters as possible and this necessitated the constraint of a small sample size. One of the difficulties in studying the HIV population is the high prevalence of multiple comorbidities (13). Moreover, examination of elderly HIV-positive individuals further limited our cohort size. Another limitation is the older age of the HIV-negative group; all cases were obtained from the same consortium to ensure consistency in tissue processing and evaluation. The previously seen microglial activation in HIV-positive subjects with severe dementia have included subjects both with and without HIVE (59). Both GFAP- and Iba-1 immunoreactivity were found to be elevated in elderly HIVE patients in comparison to young HIVE patients as well as to age-matched HIV-positive individuals without HIVE, with an increase in the number of microglia and extended microglial processes in HIVE (60). Increased immunostaining for macrophage/microglial markers has also been seen in HIV-positive subjects without encephalitis but it is unclear whether their number and/or activation is altered (61, 62). Furthermore, a significant proportion of the HIV-positive cohort has HCV co-infection (19), and several groups have demonstrated that co-infection decreases cognitive function in HIV-positive patients likely through exacerbation of glial activation and neuronal death (20–22, 63); one study failed to show that HCV was contributory in the absence of significant HCV-related liver disease (64). HCV infection has been associated with neuroinflammation and increased white matter abnormalities in the setting of HIV coinfection (22, 65). In autopsy studies, HCV has been shown to infect microglia as well as astrocytes, although to a lesser extent, with evidence of microglial activation (66, 67). Although HCV is not known to cause AD changes, neuropathologic studies of individuals with HCV are sparse. Furthermore, recent studies have raised the possibility of a role for infections, especially viral, in AD (68–70).

There are conflicting data on amyloid deposits in HIV-positive subjects. One of the earlier studies found a greater prevalence of amyloid plaques, mostly sparse and of the diffuse type, in AIDS patients, including in younger cohorts even in their 30s. Rempel et al (14, 71) demonstrated increased numbers of diffuse but not neuritic plaques in HIV-positive subjects including individuals with HAD, suggesting an acceleration and increase in amyloid pathology. However, Gelman and Schuenke (72) showed increased ubiquitin stained structures in AIDS subjects but no difference in amyloid plaque

counts compared to HIV-negative individuals. Several studies have detected intraneuronal staining with the 4G8 antibody to A $\beta$  with absent to only occasional plaques (11, 15, 16, 73). Soontornniyomkij et al (74) also found mostly diffuse plaques in HIV-positive subjects, and that among APOE  $\epsilon$ 4 carriers, amyloid plaques were associated with HAND. Studies on the association between APOE status and HAND have also demonstrated conflicting results with some showing no association with cognitive impairment or imaging abnormalities while others showing an association with both, which may partly be due to the differences in age and severity of disease of the cohorts examined (75–82). Interestingly, Green et al (83) showed increased amyloid deposition in HIV-positive subjects in the post-HAART compared to the pre-HAART era. In one study, only sparse amyloid deposits were seen in HIV-positive subjects but elevated levels of phosphorylated tau (p-tau) were observed in the hippocampus compared to HIV-negative subjects that only reached statistical significance in HIV-positive patients on antiretroviral therapy (16).

Few studies have examined tau in HIV-infected individuals. Decreased CSF A $\beta$ 42 with increased total tau and p-tau have been seen in subjects with AIDS dementia complex, with levels similar to those seen in patients with AD (84). Patrick et al (85) showed increased p-tau on immunoblotting in the frontal cortex of HIV-positive subjects with HIVE compared to HIV-positive subjects without HIVE. Both increased tau and amyloid deposition have been detected in the brains of HIV-positive injecting drug users compared to HIV-negative subjects (11). Thus, there may be complex interactions between the severity of HIV infection, cART use, and other risk factors affecting amyloid and tau pathology in these individuals.

Turner et al (1) reported the first HIV-infected patient with a positive amyloid PET scan using [18F] florbetaben, raising awareness that other neurodegenerative diseases such as AD should be a consideration in cognitively impaired patients with HIV. A few cognitively impaired HIV-positive patients have also been shown to have increased [18F] FDDNP binding on PET imaging in the cortex compared to controls, but not to the levels usually seen in AD (5). A series reporting <sup>11</sup>C-PiB PET imaging in 10 subjects with virally suppressed HAND did not detect a significant difference as a group compared to cognitively intact older subjects, but individual patients with HIV showed abnormally increased or decreased amyloid burden (13). The only autopsy study demonstrating AD neuropathologic change in 2 HIV-positive patients showed that moderate to severe AD neuropathologic changes can be seen in both cognitively intact and severely impaired individuals with HIV (17).

In our cohort, one HIV-positive subject demonstrated abundant diffuse plaques in both temporal and frontal cortices with sparse neuritic plaques only in the temporal lobe but was cognitively normal. Three HIV-positive subjects had only sparse diffuse plaques and the remainder were devoid of amyloid plaques. Two HIV-negative subjects showed both diffuse and neuritic plaques but were also cognitively normal. NFTs were sparse in HIV-positive subjects. Six of 9 HIV-positive subjects had some degree of neuropsychological impairment that was not associated with amyloid plaques or NFTs. Cognitive impairment in these elderly HIV-infected individuals may

be multifactorial in etiology. HIV-positive subjects with normal cognition and no significant neuropathologic change have downregulation of neuronal type genes involved in synaptic plasticity (9), and decreased synaptic density and dendritic complexity have been correlated with decreasing cognitive function in the frontal cortex in HIV infection (86, 87).

In summary, this study examined the neuropathology of elderly HIV-positive individuals to shed light on aging in the context of controlled but longstanding HIV infection, which is becoming increasingly common since cART. The pathophysiology of cognitive impairment in HIV-positive individuals is likely complex and distinct from that in the pre-cART era, in which HIVE was frequently observed in patients with cognitive dysfunction, such that neuropathologic manifestations may not be readily apparent using standard histochemical and immunohistochemical tools. Although beyond the scope of this study, in-depth studies at the functional level may help elucidate the pathogenesis of HAND. Brain gene expression analysis has demonstrated that there is increased expression of genes involved in the immune response and downregulation of genes involved in neuronal pathways in cognitively impaired subjects with HIVE, but upregulation of transcripts expressed by vascular cells in cognitively impaired subjects without HIVE. This suggests at least 2 different pathways to cognitive impairment in HIV-infected subjects (9). It can be hypothesized that HIV infection disrupts the BBB and causes neuroinflammation, the latter but not the former ameliorated with cART, leading to neuronal and glial dysfunction, and future studies characterizing the neurovascular unit in HIV-positive subjects may be warranted (9). Multiple insults acting synergistically with decreased cognitive reserve may result in accelerated aging and cognitive impairment in individuals living with HIV (5).

## ACKNOWLEDGMENTS

*We would like to thank all of the participants and their caregivers involved in the NNTC and Ms. Elizabeth Kulka for facilitating data selection and retrieval.*

## REFERENCES

- Turner RS, Chadwick M, Horton WA, et al. An individual with human immunodeficiency virus, dementia, and central nervous system amyloid deposition. *Alzheimers Dement (Amst)* 2016;4:1–5
- Hall HI, Song R, Rhodes P, et al.; HIV Incidence Surveillance Group. Estimation of HIV incidence in the United States. *JAMA* 2008;300:520–9
- Rubin LH, Sundermann EE, Moore DJ. The current understanding of overlap between characteristics of HIV-associated neurocognitive disorders and Alzheimer's disease. *J Neurovirol* 2019;25:661–72
- Xu J, Ikezu T. The comorbidity of HIV-associated neurocognitive disorders and Alzheimer's disease: A foreseeable medical challenge in post-HAART era. *J Neuroimmune Pharmacol* 2009;4:200–12
- Mackiewicz MM, Overk C, Achim CL, et al. Pathogenesis of age-related HIV neurodegeneration. *J Neurovirol* 2019;25:622–33
- Clifford DB, Ances BM. HIV-associated neurocognitive disorder. *Lancet Infect Dis* 2013;13:976–86
- Solomon IH, De Girolami U, Chettimada S, et al. Brain and liver pathology, amyloid deposition, and interferon responses among older HIV-positive patients in the late HAART era. *BMC Infect Dis* 2017;17:151
- Horvath S, Levine AJ. HIV-1 infection accelerates age according to the epigenetic clock. *J Infect Dis* 2015;212:1563–73
- Gelman BB, Chen T, Lisinicchia JG, et al.; National NeuroAIDS Tissue Consortium. The National NeuroAIDS Tissue Consortium brain gene array: Two types of HIV-associated neurocognitive impairment. *PLoS One* 2012;7:e46178
- Ko A, Kang G, Hattler JB, et al. Macrophages but not astrocytes harbor HIV DNA in the brains of HIV-1-infected aviremic individuals on suppressive antiretroviral therapy. *J Neuroimmune Pharmacol* 2019;14:110–9
- Smith DB, Simmonds P, Bell JE. Brain viral burden, neuroinflammation and neurodegeneration in HAART-treated HIV positive injecting drug users. *J Neurovirol* 2014;20:28–38
- Ances BM, Benzinger TL, Christensen JJ, et al. 11C-PiB imaging of human immunodeficiency virus-associated neurocognitive disorder. *Arch Neurol* 2012;69:72–7
- Howdle GC, Quidé Y, Kassem MS, et al. Brain amyloid in virally suppressed HIV-associated neurocognitive disorder. *Neurol Neuroimmunol Neuroinflamm* 2020;7:e739
- Rempel HC, Pulliam L. HIV-1 Tat inhibits neprilysin and elevates amyloid  $\beta$ . *AIDS* 2005;19:127–35
- Achim CL, Adame A, Dumaop W, et al.; Neurobehavioral Research Center. Increased accumulation of intraneuronal amyloid  $\beta$  in HIV-infected patients. *J Neuroimmune Pharmacol* 2009;4:190–9
- Anthony IC, Ramage SN, Carnie FW, et al. Accelerated Tau deposition in the brains of individuals infected with human immunodeficiency virus-1 before and after the advent of highly active anti-retroviral therapy. *Acta Neuropathol* 2006;111:529–38
- Morgello S, Jacobs M, Murray J, et al. Alzheimer's disease neuropathology may not predict functional impairment in HIV: A report of two individuals. *J Neurovirol* 2018;24:629–37
- Morgello S, Gelman BB, Kozlowski PB, et al. The National NeuroAIDS Tissue Consortium: A new paradigm in brain banking with an emphasis on infectious disease. *Neuropathol Appl Neurobiol* 2001;27:326–35
- Wyles DL, Sulkowski MS, Dieterich D. Management of hepatitis C/HIV coinfection in the era of highly effective hepatitis C virus direct-acting antiviral therapy. *Clin Infect Dis* 2016;63:S3–11
- Hinkin CH, Castellon SA, Levine AJ, et al. Neurocognition in individuals co-infected with HIV and hepatitis C. *J Addict Dis* 2008;27:11–7
- Sun B, Abadjian L, Rempel H, et al. Differential cognitive impairment in HCV coinfecting men with controlled HIV compared to HCV mono-infection. *J Acquir Immune Defic Syndr* 2013;62:190–6
- Vivithanaporn P, Nelles K, Deblock L, et al. Hepatitis C virus coinfection increases neurocognitive impairment severity and risk of death in treated HIV/AIDS. *J Neurol Sci* 2012;312:45–51
- Woods SP, Rippeth JD, Frol AB, et al. Interrater reliability of clinical ratings and neurocognitive diagnoses in HIV. *J Clin Exp Neuropsychol* 2004;26:759–78
- Morgello S, Holzer IC, Ryan E, et al. Interrater reliability of the psychiatric research interview for substance and mental disorders in an HIV-infected cohort: Experience of the National NeuroAIDS Tissue Consortium. *Int J Methods Psychiatr Res* 2006;15:131–8
- Antinori A, Arendt G, Becker JT, et al. Updated research nosology for HIV-associated neuro cognitive disorders. *Neurology* 2007;69:1789–99
- Janssen RS, Cornblath DR, Epstein LG, et al. Nomenclature and research case definitions for neurologic manifestations of human immunodeficiency virus-type 1 (HIV-1) infection. Report of a Working Group of the American Academy of Neurology AIDS Task Force. *Neurology* 1991;41:778–85
- Budka H, Wiley CA, Kleihues P, et al. HIV-associated disease of the nervous system: Review of nomenclature and proposal for neuropathology-based terminology. *Brain Pathol* 1991;1:143–52
- Gelman BB, Lisinicchia JG, Morgello S, et al. Neurovirological correlation with HIV-associated neurocognitive disorders and encephalitis in a HAART-era cohort. *J Acquir Immune Defic Syndr* 2013;62:487–95
- Paasila PJ, Davies DS, Kril JJ, et al. The relationship between the morphological subtypes of microglia and Alzheimer's disease neuropathology. *Brain Pathol* 2019;29:726–40
- Streit WJ, Braak H, Xue QS, et al. Dystrophic (senescent) rather than activated microglial cells are associated with tau pathology and likely precede neurodegeneration in Alzheimer's disease. *Acta Neuropathol* 2009;118:475–85
- Magaki SD, Williams CK, Vinters HV. Glial function (and dysfunction) in the normal & ischemic brain. *Neuropharmacology* 2018;134:218–25

32. Lundgaard I, Osório MJ, Kress BT, et al. White matter astrocytes in health and disease. *Neuroscience* 2014;276:161–73
33. Sofroniew MV, Vinters HV. Astrocytes: Biology and pathology. *Acta Neuropathol* 2010;119:7–35
34. Mao Q, Wang D, Li Y, et al. Disease and region specificity of granulin immunopositivities in Alzheimer disease and frontotemporal lobar degeneration. *J Neuropathol Exp Neurol* 2017;76:957–68
35. Chen A, Akinyemi RO, Hase Y, et al. Frontal white matter hyperintensities, clasmatodendrosis and gliovascular abnormalities in ageing and post-stroke dementia. *Brain* 2016;139:242–58
36. Hase Y, Chen A, Bates LL, et al. Severe white matter astrocytopathy in CADASIL. *Brain Pathol* 2018;28:832–43
37. Mirra SS, Heyman A, McKeel D, et al. The Consortium to Establish a Registry for Alzheimer's Disease (CERAD). Part II. Standardization of the neuropathologic assessment of Alzheimer's disease. *Neurology* 1991;41:479–86
38. Montine TJ, Phelps CH, Beach TG, et al.; Alzheimer's Association. National Institute on Aging-Alzheimer's Association guidelines for the neuropathologic assessment of Alzheimer's disease: A practical approach. *Acta Neuropathol* 2012;123:1–11
39. Jaynes B, Provias J. The possible role of capillary cerebral amyloid angiopathy in Alzheimer lesion development: A regional comparison. *Acta Neuropathol* 2006;112:417–27
40. Prabhu S, Harwell JI, Kumarasamy N. Advanced HIV: Diagnosis, treatment, and prevention. *Lancet HIV* 2019;6:e540–51–51
41. He J, Crews FT. Increased MCP-1 and microglia in various regions of the human alcoholic brain. *Exp Neurol* 2008;210:349–58
42. Nelson PT, Alafuzoff I, Bigio EH, et al. Correlation of Alzheimer disease neuropathologic changes with cognitive status: A review of the literature. *J Neuropathol Exp Neurol* 2012;71:362–81
43. Cray JF, Trojanowski JQ, Schneider JA, et al. Primary age-related tauopathy (PART): A common pathology associated with human aging. *Acta Neuropathol* 2014;128:755–66
44. Saylor D, Dickens AM, Sacktor N, et al. HIV-associated neurocognitive disorder—Pathogenesis and prospects for treatment. *Nat Rev Neurol* 2016;12:234–48
45. Pfefferbaum A, Rogosa DA, Rosenbloom MJ, et al. Accelerated aging of selective brain structures in human immunodeficiency virus infection: A controlled, longitudinal magnetic resonance imaging study. *Neurobiol Aging* 2014;35:1755–68
46. Ances BM, Sisti D, Vaida F, et al.; On behalf of the HNRC group. Resting cerebral blood flow. A potential biomarker of the effects of HIV in the brain. *Neurology* 2009;73:702–8
47. Ances BM, Vaida F, Yeh MJ, et al. HIV infection and aging independently affect brain function as measured by functional magnetic resonance imaging. *J Infect Dis* 2010;201:336–40
48. Wiley CA, Achim C. Human immunodeficiency virus encephalitis is the pathological correlate of dementia in acquired immunodeficiency syndrome. *Ann Neurol* 1994;36:673–6
49. Glass JD, Wesselingh SL, Selnes OA, et al. Clinical-neuropathologic correlation in HIV-associated dementia. *Neurology* 1993;43:2230–7
50. Milanini B, Valcour V. Differentiating HIV-associated neurocognitive disorders from Alzheimer's disease: An emerging issue in geriatric neuroHIV. *Curr HIV/AIDS Rep* 2017;14:123–32
51. Fulop T, Witkowski JM, Larbi A, et al. Does HIV infection contribute to increased beta-amyloid synthesis and plaque formation leading to neurodegeneration and Alzheimer's disease? *J Neurovirol* 2019;25:634–47
52. Gray F, Scaravilli F, Everall I, et al. Neuropathology of early HIV-1 infection. *Brain Pathol* 1996;6:1–15
53. González-Scarano F, Martín-García J. The neuropathogenesis of AIDS. *Nat Rev Immunol* 2005;5:69–81
54. Rubin LH, Sacktor N, Creighton J, et al. Microglial activation is inversely associated with cognition in individuals living with HIV on effective antiretroviral therapy. *AIDS* 2018;32:1661–7
55. Carroll-Anzinger D, Al-Harhi L. Gamma interferon primes productive human immunodeficiency virus infection in astrocytes. *J Virol* 2006;80:541–4
56. Salminen A, Ojala J, Kaamiranta K, et al. Astrocytes in the aging brain express characteristics of senescence-associated secretory phenotype. *Eur J Neurosci* 2011;34:3–11
57. Ross GW, O'Callaghan JP, Sharp DS, et al. Quantification of regional glial fibrillary acidic protein levels in Alzheimer's disease. *Acta Neurol Scand* 2003;107:318–23
58. Serrano-Pozo A, Mielke ML, Gómez-Isla T, et al. Reactive glia not only associates with plaques but also parallels tangles in Alzheimer's disease. *Am J Pathol* 2011;179:1373–84
59. Glass JD, Fedor H, Wesselingh S, et al. Immunocytochemical quantitation of human immunodeficiency virus in the brain: Correlations with dementia. *Ann Neurol* 1995;38:755–62
60. Fields J, Dumaop W, Rockenstein E, et al. Age-dependent molecular alterations in the autophagy pathway in HIVE patients and in a gp120 tg mouse model: Reversal with beclin-1 gene transfer. *J Neurovirol* 2013;19:89–101
61. Tavazzi E, Morrison D, Sullivan P, et al. Brain inflammation is a common feature of HIV-infected patients without HIV encephalitis or productive brain infection. *Curr HIV Res* 2014;12:97–110
62. Anthony IC, Ramage SN, Carnie FW, et al. Influence of HAART on HIV-related CNS disease and neuroinflammation. *J Neuropathol Exp Neurol* 2005;64:529–36
63. Ryan EL, Morgello S, Isaacs K, et al.; Manhattan HIV Brain Bank. Neuropsychiatric impact of hepatitis C on advanced HIV. *Neurology* 2004;62:957–62
64. Clifford DB, Vaida F, Kao YT, et al.; CHARTER Group. Absence of neurocognitive effect of hepatitis C infection in HIV-coinfected people. *Neurology* 2015;84:241–50
65. Vivithanaporn P, Maingot F, Lin LT, et al. Hepatitis C virus core protein induces neuroimmune activation and potentiates human immunodeficiency virus-1 neurotoxicity. *PLoS One* 2010;5:e12856
66. Wilkinson J, Radkowski M, Laskus T. Hepatitis C virus neuroinvasion: Identification of infected cells. *J Virol* 2009;83:1312–9
67. Wilkinson J, Radkowski M, Eschbacher JM, et al. Activation of brain macrophages/microglia cells in hepatitis C infection. *Gut* 2010;59:1394–1400
68. Ashraf GM, Tarasov VV, Makhmutova A, et al. The possibility of an infectious etiology of Alzheimer disease. *Mol Neurobiol* 2019;56:4479–91
69. Vinters HV. Emerging concepts in Alzheimer's disease. *Annu Rev Pathol* 2015;10:291–319
70. Ball MJ, Lukiw WJ, Kammerman EM, Hill JM. Intracerebral propagation of Alzheimer's disease: Strengthening evidence of a herpes simplex virus etiology. *Alzheimers Dement* 2013;9:169–75
71. Esiri MM, Biddolph SC, Morris CS. Prevalence of Alzheimer plaques in AIDS. *J Neurol Neurosurg Psychiatry* 1998;65:29–33
72. Gelman BB, Schuenke K. Brain aging in acquired immunodeficiency syndrome: Increased ubiquitin-protein conjugate is correlated with decreased synaptic protein but not amyloid plaque accumulation. *J Neurovirol* 2004;10:98–108
73. Khanlou N, Moore DJ, Chana G, et al.; HNRC Group. Increased frequency of alpha-synuclein in the substantia nigra in human immunodeficiency virus infection. *J Neurovirol* 2009;15:131–8
74. Soontornniyomkij V, Moore DJ, Gouaux B, et al. Cerebral  $\beta$ -amyloid deposition predicts HIV-associated neurocognitive disorders in APOE  $\epsilon$ 4 carriers. *AIDS* 2012;26:2327–35
75. Geffin R, McCarthy M. Aging and Apolipoprotein E in HIV Infection [published correction appears in *J Neurovirol*. 2018 Nov 19]. *J Neurovirol* 2018;24:529–48
76. Joska JA, Combrinck M, Valcour VG, et al. Association between apolipoprotein E4 genotype and human immunodeficiency virus-associated dementia in younger adults starting antiretroviral therapy in South Africa. *J Neurovirol* 2010;16:377–83
77. Morgan EE, Woods SP, Letendre SL, et al.; CNS HIV Antiretroviral Therapy Effects Research (CHARTER) Group. Apolipoprotein E4 genotype does not increase risk of HIV-associated neurocognitive disorders. *J Neurovirol* 2013;19:150–6
78. Becker JT, Martinson JJ, Penugonda S, et al. No association between Apo $\epsilon$ 4 alleles, HIV infection, age, neuropsychological outcome, or death. *J Neurovirol* 2015;21:24–31
79. Cooley SA, Paul RH, Fennema-Notestine C, et al.; for the CNS HIV Anti-Retroviral Therapy Effects Research (CHARTER) Group. Apolipoprotein E  $\epsilon$ 4 genotype status is not associated with neuroimaging outcomes in a large cohort of HIV+ individuals. *J Neurovirol* 2016;22:607–14

80. Brito-Marques PR, Rocha-Filho PAS, Dellalibera E, et al. Cognitive changes in patient living with HIV-AIDS and apolipoprotein-E polymorphism: Is there an association? *Mol Biol Rep* 2020;47:8757–62
81. Wendelken LA, Jahanshad N, Rosen HJ, et al. ApoE  $\epsilon$ 4 is associated with cognition, brain integrity, and atrophy in HIV over age 60. *J Acquir Immune Defic Syndr* 2016;73:426–32
82. Panos SE, Hinkin CH, Singer EJ, et al. Apolipoprotein-E genotype and human immunodeficiency virus-associated neurocognitive disorder: The modulating effects of older age and disease severity. *Neurobehav HIV Med* 2013;5:11–22
83. Green DA, Masliah E, Vinters HV, et al. Brain deposition of beta-amyloid is a common pathologic feature in HIV positive patients. *AIDS* 2005;19:407–11
84. Brew BJ, Pemberton L, Blennow K, et al. CSF amyloid beta42 and tau levels correlate with AIDS dementia complex. *Neurology* 2005;65:1490–2
85. Patrick C, Crews L, Desplats P, et al. Increased CDK5 expression in HIV encephalitis contributes to neurodegeneration via tau phosphorylation and is reversed with Roscovitine. *Am J Pathol* 2011;178:1646–61
86. Everall I, Heaton R, Marcotte T, et al. Cortical synaptic density is reduced in mild to moderate human immunodeficiency virus neurocognitive disorder. *Brain Pathol* 1999;9:209–17
87. Masliah E, Heaton RK, Marcotte TD, et al. Dendritic injury is a pathological substrate for human immunodeficiency virus-related cognitive disorders. *Ann Neurol* 1997;42:963–72