

# UCSF

## UC San Francisco Previously Published Works

### Title

Cytomegalovirus infection and antibody protection of the developing placenta.

### Permalink

<https://escholarship.org/uc/item/8846w92r>

### Journal

Clinical Infectious Diseases, 57 Suppl 4(Suppl 4)

### Authors

Petitt, Matthew

Tabata, Takako

Pereira, Lenore

### Publication Date

2013-12-01

### DOI

10.1093/cid/cit583

Peer reviewed

# Cytomegalovirus Infection and Antibody Protection of the Developing Placenta

Lenore Pereira, Matthew Pettit, and Takako Tabata

Department of Cell and Tissue Biology, School of Dentistry, University of California, San Francisco

**Human cytomegalovirus (HCMV) infection is transmitted from the infected mother to the placenta and fetus. Virus replicates in the decidua, invasive cytotrophoblasts that breach the uterine vasculature and villous cytotrophoblasts underlying syncytiotrophoblasts, then reaches blood vessels in the villus core. Virus replication, fibrosis, and edema result in a hypoxic intrauterine environment and release of cytokines that stimulates compensatory development of the placenta. We employed villous explant cultures to study viral effects on differentiation and test novel approaches to rescue the placenta from infection.**

**Keywords.** congenital infection; placenta; cytotrophoblasts; hypoxia.

Primary maternal human cytomegalovirus (HCMV) infection during gestation poses a 40%–50% risk of transplacental transmission, whereas virus transmission and disease are considerably reduced in recurrent infection [1]. Transmission occurs throughout pregnancy; however, congenital disease is more severe when infection occurs in the first trimester [2]. Intrauterine growth restriction (IUGR) can occur in the absence of transmission, suggesting that it can result from placental injury, fibrosis, and edema, which impair functions.

Studies of placentas infected in utero and primary placental cytotrophoblasts and anchoring villous explants infected in vitro revealed sites of HCMV replication and complex molecular mechanisms that impair differentiation. Examination of paired biopsy specimens from the uterine–placental interface showed that virus frequently infects maternal decidua, specifically glandular epithelium (Figure 1, zone III, site 1), vascular and lymphatic endothelial cells, and interstitial and endovascular cytotrophoblasts [3, 4]. HCMV infects villous cytotrophoblasts and blood vessels in the villous

core (Figure 1, zone 1, sites 2–4). In the immunotolerant pregnant uterus, innate immune cells, macrophages, and natural killer cells limit virus replication, and high-avidity, HCMV-specific immunoglobulin G (IgG) with neutralizing activity suppresses virus replication [4–7]. Transcytosis of IgG across syncytiotrophoblasts by the neonatal Fc receptor reduces virus spread in the placentas, but low-avidity antibodies fail to prevent transmission.

HCMV replicates in cytotrophoblasts, causing the release of factors that contribute to pathogenesis, and alters expression of key differentiation molecules required for the cells' differentiation/invasion. Infection decreases the expression of integrins  $\alpha 1\beta 1$  [3] and matrix metalloproteinase 9 (MMP-9) [8], required for cytotrophoblast invasiveness, and alters other cell–cell and cell–matrix adhesion molecules, as well. In addition, CMV interleukin 10, a viral cytokine with immunosuppressive activities, reduces MMP-9 activity and cytotrophoblast invasion [8]. Collagen deposition is increased through activation of TGF- $\beta$  by integrin in infected endothelial cells, potentially reducing blood flow in the uterine–placental vasculature [9]. This constellation of molecular changes suggests multiple mechanisms by which direct infection and paracrine factors could impair cytotrophoblast invasion, cause inflammation, and undermine placental and fetal development.

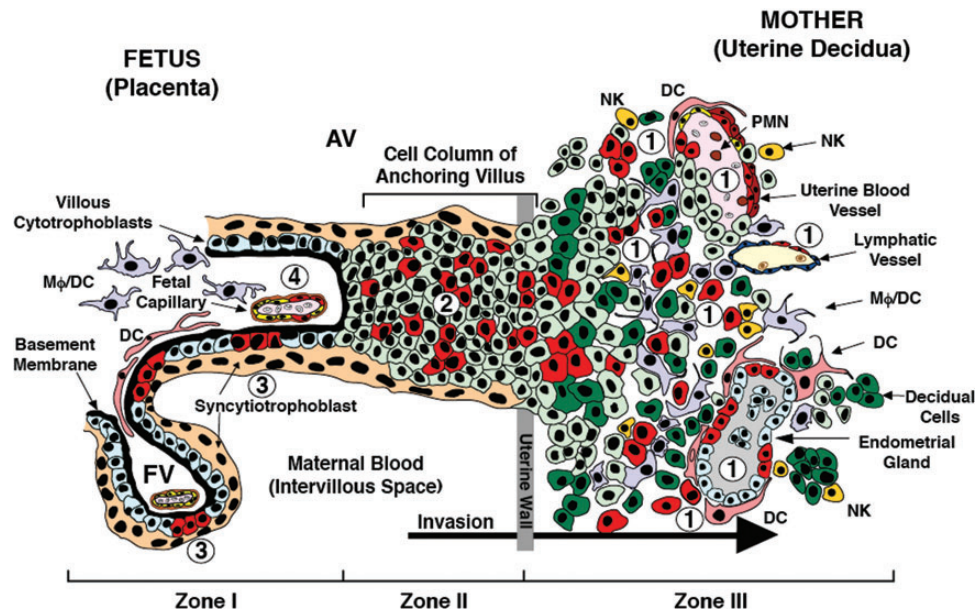
Increased levels of neutralizing antibodies that suppress HCMV replication are central to passive immunity

Correspondence: Lenore Pereira, PhD, Department of Cell and Tissue Biology, School of Dentistry, UCSF, San Francisco, CA (lenore.pereira@ucsf.edu).

**Clinical Infectious Diseases** 2013;57(S4):S174–7

© The Author 2013. Published by Oxford University Press on behalf of the Infectious Diseases Society of America. All rights reserved. For Permissions, please e-mail: journals.permissions@oup.com.

DOI: 10.1093/cid/cit583



**Figure 1.** Schematic diagram of the cellular composition of the human uterine–placental interface in early gestation. Floating chorionic villi are in direct contact with maternal blood. Anchoring villi attach the fetus to the uterus by means of cell columns. Undifferentiated villous cytotrophoblasts of floating villi (zone I); cytotrophoblasts forming the cell columns of the anchoring villi (zone II); extravillous differentiating and endovascular cytotrophoblasts, which invade the uterine stroma and remodel arterioles (zone III); and blood and lymphatic vessels and endometrial glands (zone III). Sites of human cytomegalovirus replication are indicated by numbers 1–4. Infected cells are colored red. Abbreviations: AV, anchoring villi; DC, dendritic cell; Mφ, macrophage; NK, natural killer cell; PMN, polymorphonuclear neutrophil. Adapted from Pereira et al [4].

and fetal protection [4, 6, 8]. A study of placentas from uncomplicated deliveries in HCMV-seropositive women showed that the concentration of IgG with neutralizing activity in cord blood is approximately equal to levels in maternal circulation [7]. Passive immunity escalates in the third trimester of pregnancy, mediated by neonatal Fc receptor transcytosis [10]. In a collaborative study of paired maternal and cord sera and placental biopsy specimens from cases of idiopathic IUGR, we used serology to identify maternal primary and recurrent infection as the underlying etiology (L. Pereira et al, manuscript in preparation). Recurrent infections were asymptomatic at delivery, or were associated with edema, hypoxia, and IUGR with or without evidence of virus transmission. In contrast, primary HCMV infection was found in cases of premature delivery with placental pathology, IUGR, and transmission to the fetus.

HCMV-specific hyperimmunoglobulin (HIG) treatment reduces virus transmission and placental injury [11]. Analysis of pathology in congenitally infected placentas showed considerable differences between untreated maternal infection, which correlated with hypoxia, and compensatory development with HIG, which prevented placental damage [12]. The results strongly support the possibility that infusion with HIG early after maternal seroconversion reduces HCMV replication at the uterine–placental interface.

Congenital infection and associated injury at the uterine–placental interface leads to a hypoxic environment and compensatory development. Normal placental development depends on the appropriate balance between vascular endothelial growth factor (VEGF) and placental growth factor (PlGF). VEGF-A, an angiogenic factor induced under both physiological and pathological conditions, binds receptor tyrosine kinases that regulate cell proliferation, migration, survival, and angiogenesis. The biological activity of VEGF-A is modulated by a soluble form of its receptor (sFlt1), which binds and reduces free circulating levels of VEGF and PlGF [12]. In the first trimester, physiological hypoxia favors VEGF-A expression and branching angiogenesis [13]. Under hypoxic conditions in culture, cytotrophoblasts strongly increase VEGF-A expression. In addition, VEGF-A expression is dramatically increased in placentas from women who smoke during gestation, and enormously enlarged blood vessels develop at the villous periphery to facilitate the transfer of oxygen to the fetus [14].

Congenitally infected placentas develop a hypoxia-like condition that stimulates compensatory development that increases the surface area in contact with maternal blood [12]. Upregulated VEGF-A parallels the increase in the number of blood vessels and the development of immature villi with HIG treatment. In the first trimester, villous cytotrophoblasts proliferate,

differentiate, and invade the uterine wall, regulated by oxygen tension. Prolonged hypoxia from infection, inflammation, and fibrosis at the uterine-placental interface could extend this process; that is, villous cytotrophoblasts proliferate and new villi develop. As an example, in pregnancies from high altitudes with low oxygen, the relative volume of cytotrophoblasts increases, and placentas weigh significantly more than they do at sea level, suggesting adaptation by development of a more extensive peripheral villous tree [13]. Placentas with congenital HCMV infection increase in weight and thickness, and HIG treatment leads to some reduction in size [15], suggesting that irreversible enlargement could result from a combined inflammatory response and development of chorionic villi that increases the surface area and compensates for uteroplacental hypoxia.

To further explore HCMV replication in the placenta, we studied villous explant cultures infected with the laboratory strain AD169 or the low-passage, clinical isolate VR1814 [16]. Mock-infected controls developed robust cell columns, and cytotrophoblasts in anchoring villi aggregated and attached to the extracellular matrix (Figure 1, zones I and II). AD169-infected explants also formed normal-size anchoring villi, indistinguishable from controls. In contrast, VR1814-infected explants formed spindly cell columns composed largely of individual cytotrophoblasts migrating on the surface of the substrate. Analysis of infected cytotrophoblasts within the placental villi revealed that few cells in AD169-infected explants expressed IE1&2 proteins, whereas VR1814 infected many cells. Invasive cytotrophoblasts differentiated and expressed MHC class I HLA-G, but this was downregulated in VR1814-infected cells, as previously reported [3].

Because AD169 and VR1814 exhibited markedly distinct levels of infection and gB expression in placental explants, the differences were quantified by counting the number of cytotrophoblasts expressing IE1&2 proteins in the cell columns and anchoring villi. AD169-infected explants contained a median of 2% infected cytotrophoblasts with a 5% maximum. In contrast, VR1814-infected placental villi contained a median of 26% infected cells with a 67% maximum. To quantify the effects on development of anchoring villi, the sizes of villi formed were determined by measuring the areas covered by the villous outgrowths. Control and AD169-infected explants were comparable, whereas VR1814-infected explants formed significantly smaller villi, <10% the size of those in control and AD169-infected explants. Together, the results showed that VR1814 infects cell column cytotrophoblasts of placental explants and impairs functions of the subpopulation of cells that contribute to forming anchoring villi, reducing their size.

Cell columns bridge the gap between the placenta and the uterus and are suspended in the intervillous space by homotypic interactions. Cell columns express E-cadherin, as well as L-selectin and its carbohydrate ligand, part of a specialized adhesion

system activated by shear stress that maintains column integrity during the early stages of placental development. This type of adhesion facilitates cytotrophoblast movement in and exit from cell columns, a prerequisite for uterine invasion. Virus replication could decrease the population of cytotrophoblasts that progress further down the differentiation pathway and perturb the specialized adhesive properties of cell columns, limiting the number of cytotrophoblasts that exit. Together these events would severely reduce development of anchoring villi in infected explants.

Progression of congenital HCMV infection and placental fibrosis was prevented in pregnancies with early HIG treatment [12]. This remarkable outcome suggested that human monoclonal antibodies with neutralizing activity could have comparable or improved protective qualities. Accordingly, human monoclonal antibodies to viral protein gB and UL128-131A, which have potent neutralizing activity against VR1814 infection in human umbilical cord vascular endothelial cells, primary cytotrophoblasts, and fibroblasts from the human placenta, were evaluated in intact chorionic villous explants. Neutralizing activity was compared with a commercial HIG preparation. Efficacy was measured by counting the number of infected cytotrophoblasts in cell columns. Overall, these antibodies had consistently higher neutralizing titers than did HIG products (data not shown). These important results indicate that the development of human placental villi can be rescued by neutralizing antibodies that preclude infection with a pathogenic HCMV strain and have important implications for development of novel antibody-based immunotherapies.

## Notes

**Financial support.** This work was supported by the US Public Health Service (grants AI046657, AI073753, and AI090200 to L. P. and HD061890 to T. T.).

**Supplement sponsorship.** This manuscript appears as part of the supplement "Prenatal Therapy of Congenital Cytomegalovirus Infection," sponsored by the Anticito Onlus Association.

**Potential conflicts of interest.** All authors: No reported conflicts.

All authors have submitted the ICMJE Form for Disclosure of Potential Conflicts of Interest. Conflicts that the editors consider relevant to the content of the manuscript have been disclosed.

## References

1. Fowler KB, Stagno S, Pass RF, Britt WJ, Boll TJ, Alford CA. The outcome of congenital cytomegalovirus infection in relation to maternal antibody status. *N Engl J Med* **1992**; 326:663-7.
2. Enders G, Daiminger A, Bader U, Exler S, Enders M. Intrauterine transmission and clinical outcome of 248 pregnancies with primary cytomegalovirus infection in relation to gestational age. *J Clin Virol* **2011**; 52:244-6.
3. Fisher S, Genbacev O, Maidji E, Pereira L. Human cytomegalovirus infection of placental cytotrophoblasts in vitro and in utero: implications for transmission and pathogenesis. *J Virol* **2000**; 74:6808-20.
4. Pereira L, Maidji E, McDonagh S, Genbacev O, Fisher S. Human cytomegalovirus transmission from the uterus to the placenta correlates with the presence of pathogenic bacteria and maternal immunity. *J Virol* **2003**; 77:13301-14.

5. Maidji E, McDonagh S, Genbacev O, Tabata T, Pereira L. Maternal antibodies enhance or prevent cytomegalovirus infection in the placenta by neonatal Fc receptor-mediated transcytosis. *Am J Pathol* **2006**; 168:1210–26.
6. McDonagh S, Maidji E, Chang HT, Pereira L. Patterns of human cytomegalovirus infection in term placentas: a preliminary analysis. *J Clin Virol* **2006**; 35:210–5.
7. Nozawa N, Fang-Hoover J, Tabata T, Maidji E, Pereira L. Cytomegalovirus-specific, high-avidity IgG with neutralizing activity in maternal circulation enriched in the fetal bloodstream. *J Clin Virol* **2009**; 46 (suppl 4):S58–63.
8. Yamamoto-Tabata T, McDonagh S, Chang HT, Fisher S, Pereira L. Human cytomegalovirus interleukin-10 downregulates metalloproteinase activity and impairs endothelial cell migration and placental cytotrophoblast invasiveness in vitro. *J Virol* **2004**; 78:2831–40.
9. Tabata T, Kawakatsu H, Maidji E, et al. Induction of an epithelial integrin  $\alpha$ v $\beta$ 6 in human cytomegalovirus-infected endothelial cells leads to activation of transforming growth factor- $\beta$ 1 and increased collagen production. *Am J Pathol* **2008**; 172:1127–40.
10. Simister NE, Story CM. Human placental Fc receptors and the transmission of antibodies from mother to fetus. *J Reprod Immunol* **1997**; 37:1–23.
11. Nigro G, Adler SP, La Torre R, Best AM. Passive immunization during pregnancy for congenital cytomegalovirus infection. *N Engl J Med* **2005**; 353:1350–62.
12. Maidji E, Nigro G, Tabata T, et al. Antibody treatment promotes compensation for human cytomegalovirus-induced pathogenesis and a hypoxia-like condition in placentas with congenital infection. *Am J Pathol* **2010**; 177:1298–310.
13. Benirschke K, Kaufmann P. *Pathology of the human placenta*. 4th ed. New York: Springer, **2000**.
14. Genbacev O, McMaster MT, Zdravkovic T, Fisher SJ. Disruption of oxygen-regulated responses underlies pathological changes in the placentas of women who smoke or who are passively exposed to smoke during pregnancy. *Reprod Toxicol* **2003**; 17:509–18.
15. La Torre R, Nigro G, Mazzocco M, Best AM, Adler SP. Placental enlargement in women with primary maternal cytomegalovirus infection is associated with fetal and neonatal disease. *Clin Infect Dis* **2006**; 43:994–1000.
16. Tabata T, Pettit M, Fang-Hoover J, et al. Cytomegalovirus impairs cytotrophoblast-induced lymphangiogenesis and vascular remodeling in an in vivo human placentation model. *Am J Pathol* **2012**; 181:1540–59.