

# UCSF

## UC San Francisco Previously Published Works

### Title

Unilateral Posterior Interstitial Keratitis as a Clinical Presentation of Herpes Simplex Virus Disease

### Permalink

<https://escholarship.org/uc/item/8970f2fq>

### Journal

Cornea, 37(3)

### ISSN

0277-3740

### Authors

Farooq, Asim V  
Paley, Grace L  
Lubniewski, Anthony J  
[et al.](#)

### Publication Date

2018-03-01

### DOI

10.1097/ico.0000000000001499

Peer reviewed

# Unilateral Posterior Interstitial Keratitis as a Clinical Presentation of Herpes Simplex Virus Disease

*Asim V. Farooq, MD,\* Grace L. Paley, MD, PhD,† Anthony J. Lubniewski, MD,‡  
John A. Gonzales, MD,‡ and Todd P. Margolis, MD, PhD†*

**Purpose:** To describe a case series of patients with unilateral, posterior interstitial keratitis presumed to be caused by herpes simplex virus.

**Methods:** Retrospective case series.

**Results:** Five patients were found to have unilateral, posterior interstitial keratitis. Three of the involved eyes had decreased corneal sensation, and 2 eyes had corneal stromal neovascularization. All patients were treated with topical steroids and an oral antiviral, and among those with long-term follow-up, clinical improvement required treatment over an extended duration. A review of the literature revealed 1 reported case with a similar clinical appearance, although that case was attributed to Lyme disease.

**Conclusions:** The clinical presentation of unilateral, posterior interstitial keratitis may be rare manifestation of herpes simplex virus keratitis.

**Key Words:** herpes simplex virus, stromal keratitis, interstitial keratitis, posterior stromal keratitis, neurotrophic keratitis

(*Cornea* 2017;0:1–4)

Interstitial keratitis, also known as stromal keratitis, is a clinical diagnosis. Slit-lamp examination may reveal a stromal infiltrate(s), corneal neovascularization, and thinning of the corneal stroma among other signs.<sup>1</sup> The differential diagnosis may include herpes simplex virus (HSV), herpes zoster virus (HZV), syphilis, Cogan syndrome, Hansen disease, and others. Although systemic evaluation is war-

ranted at times, the pattern of examination findings, as well as the clinical history, can point to a specific etiology. It follows that recognition of characteristic features is important in developing an appropriate differential diagnosis. Here, we report a series of patients who presented with unilateral, nearly diffuse posterior interstitial keratitis presumed to be caused by HSV.

## MATERIALS AND METHODS

A retrospective case review was performed at the Washington University in St. Louis and the Proctor Foundation at the University of California, San Francisco. This review was performed in accordance with the Institutional Review Board of each institution and the Declaration of Helsinki.

Corneal sensation testing was performed on all patients using waxed dental floss on a 0 to 4-point scale (0 = no reflex blink or verbal response, 1 = verbal response but no blink, 2 = verbal response plus delayed or sluggish blink, 3 = normal blink and response, and 4 = exaggerated blink and response).

## CASE REPORTS

### Case 1

A 59-year-old white woman presented for a second opinion. She noted that approximately 4 months prior, she began to notice blurry vision in the right eye. Best-corrected visual acuities (BCVAs) were 20/40 OD and 20/25 OS. Corneal sensation was 2 of 4 OD and 4 of 4 OS. Central corneal thickness was 528  $\mu$ m OD and 532  $\mu$ m OS. Slit-lamp examination of the right eye revealed nearly diffuse posterior corneal stromal haze without corneal neovascularization (Fig. 1). The conjunctiva of the right eye was white and quiet, and the anterior chamber was deep and quiet. Slit-lamp examination of the left eye was normal, except for a mild posterior subcapsular cataract.

A presumptive diagnosis of unilateral HSV keratitis was made. The patient was continued on difluprednate QID OD, and loteprednol etabonate ophthalmic ointment QHS was added. The patient was also administered oral valacyclovir 1 g PO TID. After several months, her BCVA improved to 20/30 OD, with a mild residual corneal scar. She remains on difluprednate once daily and oral valacyclovir 500 mg BID at her last follow-up visit at 15 months.

Received for publication August 14, 2017; revision received October 27, 2017; accepted November 7, 2017.

From the \*Department of Ophthalmology and Visual Science, University of Chicago, Chicago, IL; †Department of Ophthalmology and Visual Sciences, Washington University in St. Louis, St. Louis, MO; and ‡Francis I. Proctor Foundation, University of California San Francisco, San Francisco, CA.

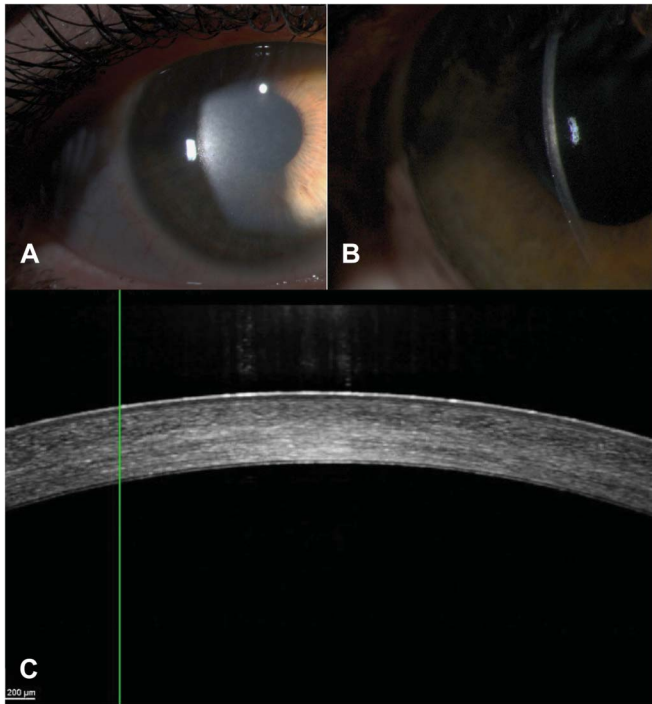
Supported in part by an unrestricted grant from Research To Prevent Blindness to the Department of Ophthalmology and Visual Sciences at Washington University. The funding organization had no role in the design or conduct of this research.

The authors have no conflicts of interest to disclose.

A. V. Farooq and G. L. Paley are co-first authors.

Reprints: Todd P. Margolis, MD, PhD, Alan A. and Edith L. Wolff Distinguished Professor and Chairman, Department of Ophthalmology and Visual Sciences, Washington University in St. Louis, 4921 Parkview Place, St. Louis, MO 63110 (e-mail: margolist@wustl.edu).

Copyright © 2017 Wolters Kluwer Health, Inc. All rights reserved.



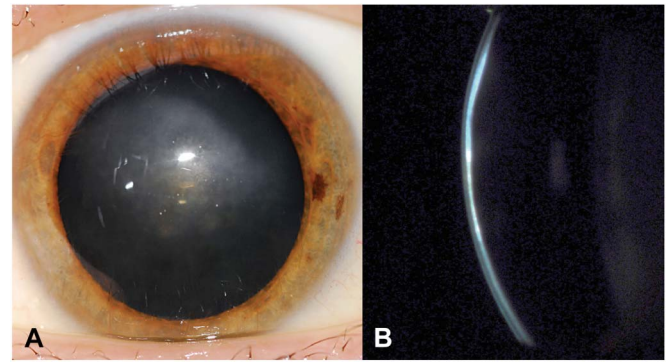
**FIGURE 1.** Case 1: (A) Full-field and (B) narrow slit-beam photographs of posterior interstitial keratitis demonstrated nearly diffuse posterior stromal haze. C, Anterior segment optical coherence tomography of the same eye showed increased reflectivity in the posterior stroma.

**Case 2**

A 27-year-old Asian American man presented with blurry vision in the left eye. He had previously been treated with subconjunctival bevacizumab for corneal neovascularization by an outside ophthalmologist. His uncorrected visual acuities were 20/20 OD and 20/100 pinholing to 20/70 OS. Central corneal thickness was greater on the left (531 μm OD vs. 591 μm OS). Corneal sensation was full OD but diminished to 0 to 1 of 4 in the left eye. Slit-lamp examination of the left eye revealed posterior corneal stromal haze and neovascularization (Fig. 2) but was otherwise normal, including white and quiet conjunctiva. Both rapid plasma reagin and fluorescent treponemal antibody absorption serologies were found to be negative. He was diagnosed with HSV keratitis and treated with topical prednisolone acetate 1% QID and oral valacyclovir 1 g TID. After 1 month of treatment, there was significant improvement in his clinical appearance, and his visual acuity with a contact lens overrefraction was 20/30 OS. He was subsequently discharged to local ophthalmic care.

**Case 3**

A 22-year-old Asian American man seen for routine eye examination was noted to have a decreased visual acuity of 20/25 OD compared with 20/20 OS. His central corneal thickness was 582 μm OD and 584 μm OS. Corneal sensation was full OU. His slit-lamp examination was remarkable for paracentral “steel wool-like” haze involving the posterior corneal stroma OD (Fig. 3). A presumed diagnosis of HSV keratitis was made based on the unilateral presentation and similar appearance to other cases. He was prescribed topical prednisolone acetate 1% QID and oral acyclovir 400 mg 5 times a day. Unfortunately, he was lost to follow-up.




**FIGURE 2.** Case 2: (A) Full-field and (B) narrow slit-beam photographs of posterior stromal keratitis demonstrated posterior stromal haze and corneal neovascularization. The slit-beam photograph also revealed an abnormal posterior curvature.

**Case 4**

A 27-year-old white woman was referred for evaluation of interstitial keratitis in the right eye. One week prior, she had been administered prednisolone acetate 1% (6 times a day for 2 days, then QID) and oral acyclovir 400 mg PO BID. This eye had a history of dendritic epithelial keratitis managed by an outside provider. A review of systems was notable for a history of recurrent herpes labialis. BCVAs were 20/25–2 OD and 20/20 OS. Corneal sensation was 3 of 4 OD and 4 of 4 OS. Slit-lamp examination of the right eye revealed diffuse posterior corneal stromal haze.

She was continued on acyclovir, and prednisolone acetate 1% was decreased to BID. Two months later, she complained of blurry vision OD. Her visual acuity had decreased to 20/40+2 OD. Slit-lamp examination was notable for deep corneal stromal vessels and trace anterior chamber cell. The prednisolone acetate was increased to QID OD. A subsequent examination 2 months later did not show active inflammation, and her steroid was decreased to BID. She was then discharged to local ophthalmic care. At the time



**FIGURE 3.** Case 3: A narrow slit-beam photograph of posterior interstitial keratitis demonstrated nearly diffuse posterior stromal “steel wool-like” haze.

of a return visit 7 years later, her BCVA was 20/100 pinholing to 20/40+2 OD. The right eye had deep central corneal stromal haze with fine “ghost” vessels, as well as a posterior subcapsular cataract. She was continued on oral acyclovir and prednisolone acetate 1% BID OD.

### Case 5

A 42-year-old white woman presented with photophobia in the left eye. BCVAs were 20/20 OD and 20/40 OS. Central corneal thickness was 517  $\mu\text{m}$  OD and 514  $\mu\text{m}$  OS, with intact corneal sensation OU. Slit-lamp examination revealed diffuse posterior stromal haze OS. A presumed diagnosis of HSV keratitis was made based on the unilateral presentation and similar appearance to other cases; in addition, rapid plasma reagin and fluorescent treponemal antibody absorption serologies were negative. After treatment with topical prednisolone acetate 1% QID and oral valacyclovir 1 g TID for 1 month, she had an improved clinical appearance, and her visual acuity improved to 20/30 OS. She was discharged to local ophthalmic care.

## DISCUSSION

We present a series of patients who developed a similar clinical appearance of unilateral posterior interstitial keratitis. Clinical features suggestive of herpetic keratitis<sup>2</sup> included a unilateral presentation in all cases, decreased corneal sensation in 3 cases,<sup>3</sup> steel wool keratopathy in 1 case,<sup>4</sup> and previous dendritic epithelial keratitis in 1 case. It is well known that HSV is a cause of interstitial keratitis and also tends to cause unilateral disease.<sup>2</sup> In all cases, a review of systems, medical history, and social history excluded *Borrelia burgdorferi* (none of the patients had been to endemic areas) and Cogan syndrome (no tinnitus or hearing loss). *Treponema pallidum* serologies were negative in cases that were tested.

Serologic testing for nonherpetic etiologies of interstitial keratitis (including *T. pallidum*) should be obtained in cases with normal corneal sensation, no steel wool keratopathy, no clear history of preceding dendritic epithelial keratitis, or if the medical, social, and/or sexual history suggest another diagnosis.<sup>5</sup> In addition, when there is an active anterior uveitis with at least 1+ anterior chamber cell that is suspected to be viral in etiology (particularly in association with stellate keratic precipitates, elevated intraocular pressure, or iris transillumination defects), anterior chamber paracentesis may be considered with directed polymerase chain reaction for HSV, varicella-zoster virus, and cytomegalovirus.<sup>6</sup> In our case with mild anterior chamber cell (less than 1+), there was complete resolution with an oral antiviral and topical steroid.

The pathogenesis of HSV interstitial keratitis is related to viral activity and the host immune response. The extended duration of this disease has not been fully explained, but some have hypothesized long-term viral antigen persistence in the corneal stroma.<sup>7,8</sup> CD4<sup>+</sup> T cells have been implicated as primary mediators of the immune response. Although HSV interstitial keratitis was at one time treated with topical antivirals, most corneal specialists now treat this disease with a combination of oral antivirals and topical corticosteroids to both resolve active corneal inflammation and reduce the risk

of disease recurrence.<sup>9</sup> It should be noted that long-term antiviral prophylaxis may potentially lead to resistance.<sup>10</sup>

HSV interstitial keratitis has several clinical presentations, including ghost dendritic keratitis, which may develop in the anterior stroma in association with a recent dendrite; unifocal or multifocal anterior stromal keratitis, with or without overlying epithelial defect(s); sectoral or diffuse corneal neovascularization; a stromal immune ring; and corneal melt. Chronic HSV interstitial keratitis may lead to the appearance of a metallic-like, polychromatic stromal opacity termed “steel wool keratopathy,” as we found in case 3.<sup>4</sup> The clinical pattern in our series was distinct in that the inflammation was localized to the posterior stroma, there were no keratic precipitates or features of endotheliitis, and there was little or no conjunctival injection. Also, patients were either asymptomatic or only had mild blurring or photophobia at presentation. Decreased corneal sensation was not universal in this case series, perhaps because of the posterior location of the corneal inflammation.

To our knowledge, there is only 1 report in the published literature of a similar presentation describing unilateral, posterior interstitial keratitis.<sup>11</sup> In that case, a 13-year-old girl presented with posterior stromal haze limited to the inferior cornea. Corneal sensation was intact. She was initially treated with topical prednisolone acetate 1% QID; as no improvement was noted, systemic workup was performed, which revealed a positive *B. burgdorferi* antibody enzyme immunoassay and Western blot. Lyme disease was suspected, and clinical improvement was observed with continuation of the topical steroid and the addition of oral doxycycline.<sup>11</sup>

In similar presentations of interstitial keratitis, we recommend careful and thorough clinical examination, including corneal sensation testing.<sup>12,13</sup> We also recommend a complete review of systems, with attention to those systems that may be associated with corneal inflammation. In the setting of posterior interstitial keratitis similar to the cases in this series, and particularly with a unilateral presentation, decreased corneal sensation, steel wool keratopathy, and/or previous dendritic epithelial keratitis, consideration should be given to HSV as a likely etiology.

## REFERENCES

- Holland EJ, Schwartz GS, Shah KJ. Herpes simplex keratitis. In: Mannis MJ, Holland EJ, eds. *Cornea: Fundamentals, Diagnosis, and Management*. 4th ed. New York, NY: Elsevier Mosby; 2017.
- Farooq AV, Shukla D. Herpes simplex epithelial and stromal keratitis: an epidemiologic update. *Surv Ophthalmol*. 2012;57:448–462.
- Bonini S, Rama P, Olzi D, et al. Neurotrophic keratitis. *Eye (Lond)*. 2003;17:989–995.
- Seitzman GD, Strauss EC, Margolis TP. “Steel wool keratopathy”: a clinical sign of chronic inflammation. *Cornea*. 2006;25:742–744.
- Rosenbaum JT, Wernick R. Selection and interpretation of laboratory tests for patients with uveitis. *Int Ophthalmol Clin*. 1990;30:238–243.
- Takase H, Kubono R, Terada Y, et al. Comparison of the ocular characteristics of anterior uveitis caused by herpes simplex virus, varicella-zoster virus, and cytomegalovirus. *Jpn J Ophthalmol*. 2014;58:473–482.
- Farooq AV, Shukla D. Corneal latency and transmission of herpes simplex virus-1. *Future Virol*. 2011;6:101–108.
- Toma HS, Murina AT, Areaux RG, Jr, et al. Ocular HSV-1 latency, reactivation and recurrent disease. *Semin Ophthalmol*. 2008;23:249–273.

9. Tsatsos M, MacGregor C, Athanasiadis I, et al. Herpes simplex virus keratitis: an update of the pathogenesis and current treatment with oral and topical antiviral agents. *Clin Exp Ophthalmol*. 2016;44:824–837.
10. van Velzen M, van de Vijver DA, van Loenen FB, et al. Acyclovir prophylaxis predisposes to antiviral-resistant recurrent herpetic keratitis. *J Infect Dis*. 2013;208:1359–1365.
11. Oldham GW, Seitzman GD. Unilateral posterior stromal keratitis possibly secondary to Lyme disease. *Cornea*. 2013;32:196–198.
12. Gallar J, Tervo TM, Neira W, et al. Selective changes in human corneal sensation associated with herpes simplex virus keratitis. *Invest Ophthalmol Vis Sci*. 2010;51:4516–4522.
13. Sacchetti M, Lambiase A. Diagnosis and management of neurotrophic keratitis. *Clin Ophthalmol*. 2014;8:571–579.