

# UC Irvine

## UC Irvine Previously Published Works

### Title

Neuronal localization of C1q in preclinical Alzheimer's disease

### Permalink

<https://escholarship.org/uc/item/8cb5149k>

### Journal

Neurobiology of Disease, 15(1)

### ISSN

0969-9961

### Authors

Fonseca, Maria I  
Kawas, Claudia H  
Troncoso, Juan C  
[et al.](#)

### Publication Date

2004-02-01

### DOI

10.1016/j.nbd.2003.09.004

### Copyright Information

This work is made available under the terms of a Creative Commons Attribution License, available at <https://creativecommons.org/licenses/by/4.0/>

Peer reviewed

## Neuronal localization of C1q in preclinical Alzheimer's disease

Maria I. Fonseca,<sup>a</sup> Claudia H. Kawas,<sup>b</sup> Juan C. Troncoso,<sup>c</sup> and Andrea J. Tenner<sup>a,\*</sup>

<sup>a</sup>Department of Molecular Biology and Biochemistry, University of California, Irvine, CA, USA

<sup>b</sup>Neurobiology and Behavior and Neurology, University of California, Irvine, CA, USA

<sup>c</sup>Departments of Pathology and Neurology, Johns Hopkins University School of Medicine, Baltimore, MD, USA

Received 14 January 2003; revised 8 September 2003; accepted 11 September 2003

**Complement has been postulated to contribute to inflammatory reactions associated with the neuropathology of Alzheimer's disease (AD). C1q, an initial component of the complement cascade, is associated with neuritic plaques and with neurons in the hippocampus of AD brain. Here, we report the presence of C1q in a cognitively intact subject, previously identified as preclinical AD. We compared in detail brain tissue of this preclinical case with a genetically related late-onset AD case. In the AD brain, C1q was typically associated with fibrillar A $\beta$  plaques in frontal cortex and with plaques and neurons in the hippocampus. In the preclinical subject, C1q was abundantly present but it was cell-associated only, being primarily colocalized with neurons in both frontal cortex and hippocampus. However, no predominant cortical neuronal C1q localization was found in other preclinical cases or in Down's cases of different ages. Thus, it is possible that this neuronal-associated C1q reflects an early, but transient, response to injury that may modulate the progression of neurological dysfunction in AD.**

© 2003 Elsevier Inc. All rights reserved.

**Keywords:** C1q; Complement; Inflammation; Alzheimer's disease; Neurons

### Introduction

Alzheimer's disease (AD) is a neurodegenerative disorder associated with the loss of cognitive function and the presence of characteristic neuropathological changes that include synaptic and neuronal loss, neurofibrillary tangles, and extracellular senile plaques composed of  $\beta$ -amyloid (A $\beta$ ) protein deposits. The association of complement proteins, as well as acute phase proteins and reactive glia, with senile plaques in AD brain, suggests that inflammatory processes may play a role in this disease (Akiyama et al., 2000; Rogers et al., 1996). Observational studies in which anti-inflammatory drug use has been associated with delay in the onset of AD are consistent with a contribution of inflammation to the neurodegeneration, although this might be in part due to the

modulation of amyloid deposition by a subset of NSAIDs (Weggen et al., 2001).

C1q, a subcomponent of C1, the first component of the classical complement pathway, is able to directly bind  $\beta$ -amyloid that is in  $\beta$ -sheet conformation and activate complement in vitro (Jiang et al., 1994; Rogers et al., 1992). The activation of complement could cause lysis of neurons or trigger an inflammatory reaction that damages or compromises neuronal integrity (reviewed in Tenner and Webster, 2001). In AD, C1q has been shown to be associated with fibrillar A $\beta$  plaques, and with tangles (PHF1 positive), but not with early tangles (AT-8 positive) (Afagh et al., 1996; Shen et al., 2001). The fibrillar A $\beta$  deposits were shown to correlate with cognitive decline (Cummings and Cotman, 1995). The C1q-positive A $\beta$  plaques are associated with reactive astrocytes and microglia, which are often related to degenerative events (Afagh et al., 1996; Dickson, 1997; Griffin et al., 1998). As a result, it has been hypothesized that C1q, via activation of complement, can play a detrimental role in the development of AD pathology, promoting an inflammatory state via the recruitment of activated glial cells.

C1q, however, is also known to enhance phagocytosis (Webster et al., 2000), bind to apoptotic cells (Korb and Ahearn, 1997), and down-regulate the induction of proinflammatory molecules (Tenner and colleagues, unpublished observations). More recently, neuronal synthesis of C1q, even in the absence of other complement proteins, has been detected in several injury models (Dietzschold et al., 1995; Goldsmith et al., 1997; Lee et al., 2000; Singhrao et al., 1999). As a result, it can be hypothesized that C1q could play a protective role in early stages of neuronal injury by promoting the rapid clearance of apoptotic cells and/or cellular debris that result from an initial injury, thereby suppressing the progression of an inflammatory state (Tenner, 2001).

In this work, we report the early presence of C1q in a previously described preclinical case of AD (Troncoso et al., 1998). Immunohistochemical analysis of this case, which had a family history of AD, had demonstrated abundant amyloid and striking endosomal–lysosomal abnormalities (enlarged endosomes and increases in cathepsin D), previously suggested to be early markers of AD (Cataldo et al., 1996). However, there was no gliosis and no neurofibrillary tangles detected. The data presented here demonstrating the near exclusive neuronal localization of C1q in this case contrasts with the lack of cortical neuronal staining and typical plaque C1q association seen in AD brain, and other preclinical and Down's syndrome cases.

\* Corresponding author. Department of Molecular Biology and Biochemistry, University of California—Irvine, 3205 McLaugh Hall, Irvine, CA 92697-3900. Fax: +1-949-824-8551.

E-mail address: atenner@uci.edu (A.J. Tenner).

Available online on ScienceDirect (www.sciencedirect.com.)

## Materials and methods

### Subjects

Brain tissue was obtained from a 74-year-old woman followed by the Johns Hopkins Alzheimer's Disease Research Center (ADRC) and from her 47-year-old daughter. The 74-year-old patient was suffering from mild dementia (Clinical Dementia Rating = 1) (Morris, 1993). She also had a family history of dementia (her mother also had an onset of dementia in her early 70s). Her ApoE genotype was 4/4. The daughter had not been formally tested, but had no cognitive complaints and was working full-time as a licensed practical nurse. Her ApoE genotype was 2/4. Tissue from the mother had pathological indicators of AD while the daughter had numerous diffuse amyloid plaques with no gliosis or neuronal loss. Tissues from additional subjects were obtained from the UC Irvine Institute of Brain Aging and Dementia and ADRC, and the Johns Hopkins (Baltimore, MD) ADRC. These additional subjects were divided as: (a) preclinical cases ( $n = 5$ ) selected because they had no obvious cognitive impairment during life, but mild–moderate AD pathology on autopsy or (b) moderate to severe AD cases ( $n = 5$ ). Controls ( $n = 6$ ) were chosen to match either age, race, or cause of death with the mother and daughter cases. In addition, Down's cases ( $n = 6$ , ages ranging from 23–59 years old) were also studied.

### Tissue

Postmortem interval for the mother/daughter subjects (homicidal strangulation cases), and the controls for the same cause of death was about 36 h (Troncoso et al., 1998). In all other cases, tissue was collected within 2–11 h of death. Tissue was fixed in 4% paraformaldehyde or 10% formalin as previously described (Afagh et al., 1996). Our studies included sections from frontal cortex and hippocampus.

### Immunohistochemistry

Rabbit anti-C1q antibody (DAKO, Carpinteria, CA) and goat anti-C1q antibody (Quidel, San Diego, CA) were used at 6  $\mu\text{g}/\text{ml}$ , and goat anti-C1q antibody affinity purified (Tenner and Volkin, 1986) at 5  $\mu\text{g}/\text{ml}$ . While all three antibodies gave the same results, the figures presented are all using the rabbit anti-C1q antibody. The specificity of this antibody was confirmed by Western blot analysis of human brain lysates from a control and an AD case. Antibody reactivity was detected in the lysate samples only in bands corresponding to the purified human C1q used as a positive control (data not shown). Rabbit polyclonal anti human A $\beta$ 1–42 antibody (#1536), a gift from Dr. Neil Cooper (The Scripps Research Institute, La Jolla, CA) purified by octanoic acid and ammonium sulfate precipitation (McKinney and Parkinson, 1987), and rabbit anti-bovine GFAP (DAKO) were used at 5  $\mu\text{g}/\text{ml}$ . Immunohistochemistry was performed as described previously (Afagh et al., 1996). Briefly, 40- $\mu\text{m}$  sections were incubated with the primary antibodies as indicated, followed by the corresponding biotinylated secondary antibody. The label was detected either by peroxidase using DAB or Substrate G (VECTOR, Burlingame, CA) as substrates or by fluorescence using CY3-conjugated Streptavidin (Jackson ImmunoResearch, West Grove, PA). Some of the fluorescently labeled sections were also stained with 1% thioflavine (Sigma, St. Louis, MO). For double labeling, A $\beta$  was first detected with DAB substrate (brown) followed by GFAP detected with

substrate G (blue-gray). IgGs of the same species of the primary antibodies were used as negative controls.

## Results

Brain tissues from a preclinical case and the genetically related (mother) late-onset AD case previously characterized (Troncoso et al., 1998) were studied to assess the association of C1q with pathological changes. Immunohistochemical staining of frontal cortex from the preclinical case showed the presence of robust C1q immunostaining mainly associated with neurons (Figs. 1A and

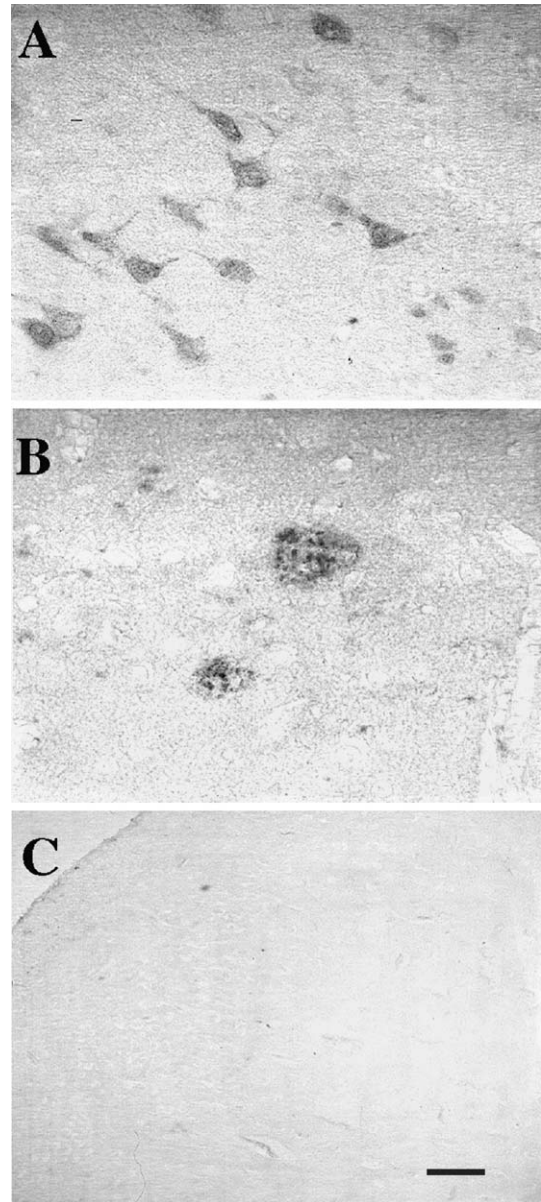


Fig. 1. Intraneuronal localization of C1q in early AD. C1q immunostaining of frontal cortex from a preclinical AD (A), a genetically related AD (B), and a strangulation control subject (C). Note that in the brain of the daughter, presumably in an early or preclinical stage of AD, C1q is present only in neurons, but not in plaques. In contrast, in the brain of the mother with established AD, C1q is associated with plaques. Scale bar: 25  $\mu\text{m}$ .



2A). This contrasted with the typical plaque localization of C1q seen in the frontal cortex of AD, as shown in Figs. 1B and 2B. No C1q was detected in control subjects matched for either the cause of death (Fig. 1C), age, or race (data not shown) with any of the three anti-C1q antibodies used. Similar to frontal cortex, the hippocampus of the preclinical case showed prominent anti-C1q immunoreactivity in neuritic processes and cell bodies of pyramidal neurons and some glia (Fig. 2C). The hippocampus of the AD case showed robust association of C1q with both plaque-like structures and neurons (Fig. 2D) as previously reported in other AD cases (Afagh et al., 1996).

Confirming previous results, A $\beta$ -positive plaques were seen in both daughter and mother (Figs. 3A,B). However, counterstaining with thioflavine demonstrated that only the AD brain had mature fibrillar plaques containing  $\beta$ -sheet peptide (Figs. 3C,D). Subsequent colocalization of A $\beta$  with GFAP showed no astrogliosis around the diffuse plaques of the daughter (Fig. 3E) while the fibrillar A $\beta$  plaques of the AD brain, as expected, had significant associated astrocytic reactivity (Fig. 3F), verifying the correlation of fibrillar plaques, C1q binding, and recruitment of glial cells (possibly by complement activation product, C5a).

We have studied the C1q distribution in additional presumed preclinical cases with mild age-associated pathology (Figs. 4A,B) as well as in Down's cases of different ages (Figs. 4C–F). In two of the preclinical cases that presented some mature A $\beta$  plaques, C1q was colocalized with the thioflavine-positive plaques and some glia in frontal cortex (Figs. 4A,B and insets). Neuronal-associated C1q was also seen in frontal cortex of one of the cases (Fig. 4B), but to a much more limited extent than in the daughter.

Two other cases that had rare diffuse plaques only were negative for C1q immunoreactivity (data not shown). Frontal cortex of several Down's syndrome cases from age 23 to 59 was also studied. Fig. 4 shows a Down's case at age 28 with abundant diffuse A $\beta$  (Fig. 4C) but no fibrillar A $\beta$  (Fig. 4E) and no C1q staining (Fig. 4G). In contrast, a 59-year-old Down's case with abundant fibrillar plaques (Figs. 4D,F) showed C1q associated only with plaques (Fig. 4H).

## Discussion

Here, we report the prominent neuronal presence of C1q in a preclinical case of AD in both frontal cortex and hippocampus. While neuronal-associated C1q is found in AD hippocampus (Afagh et al., 1996), little to no such neuronal C1q has been detected in frontal cortex in other brain areas in AD or other preclinical AD cases. C1q is associated with fibrillar plaques as shown here in the genetically related AD subject (mother) and other AD cases studied (data not shown). By contrast, C1q was not associated with plaques in the "daughter" preclinical case shown here, presumably because the plaques were of the diffuse type. Other preclinical cases that contain limited fibrillar amyloid deposits showed C1q present in the thioflavine-positive plaques, a few glia, and a very limited number of neurons in the frontal cortex. In addition, no neuronal C1q was detected in frontal cortex of Down's syndrome samples. C1q was only localized with fibrillar A $\beta$  plaques similar to previously published studies (Head et al., 2001; Stoltzner et al., 2000). Controls (tissue with no evidence of amyloid

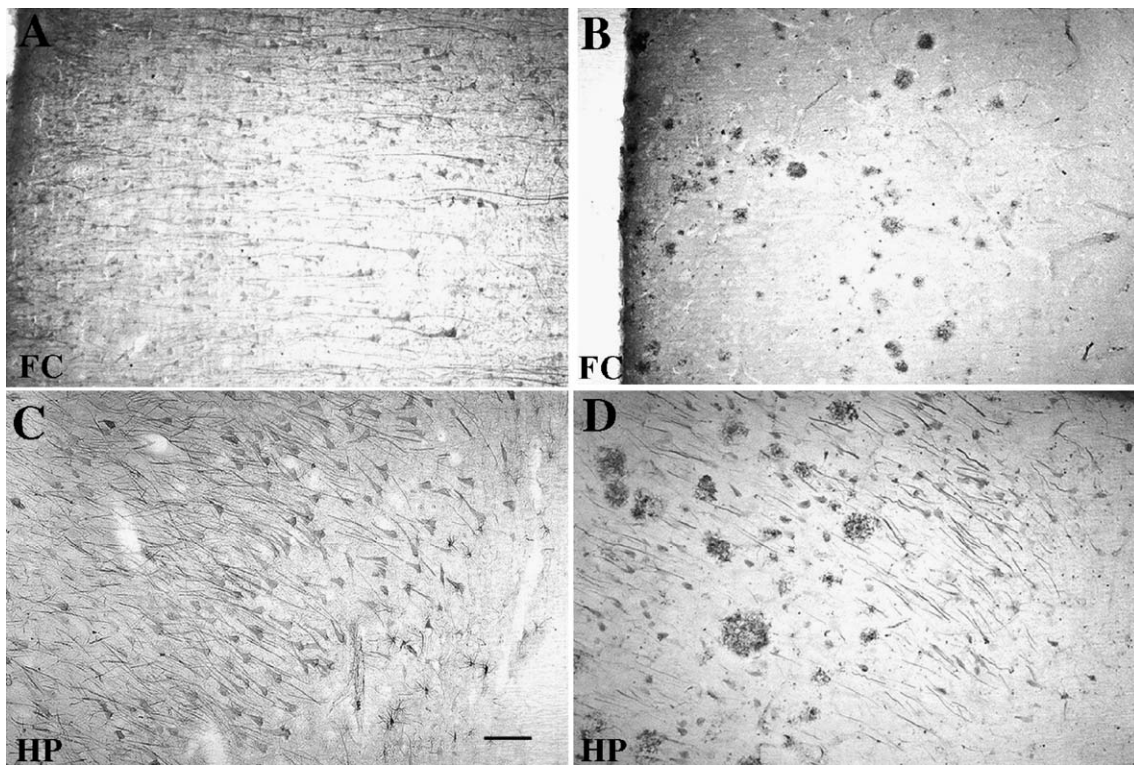


Fig. 2. Neuronal localization of C1q is observed in both frontal cortex and hippocampal regions of early AD brain, but largely only in hippocampus of AD brain. Low magnification image demonstrates C1q immunostaining of daughter (A,C) and mother (B,D) in frontal cortex (FC) (A,B) and hippocampus (HP) (C,D). Scale bar: 100  $\mu$ m.

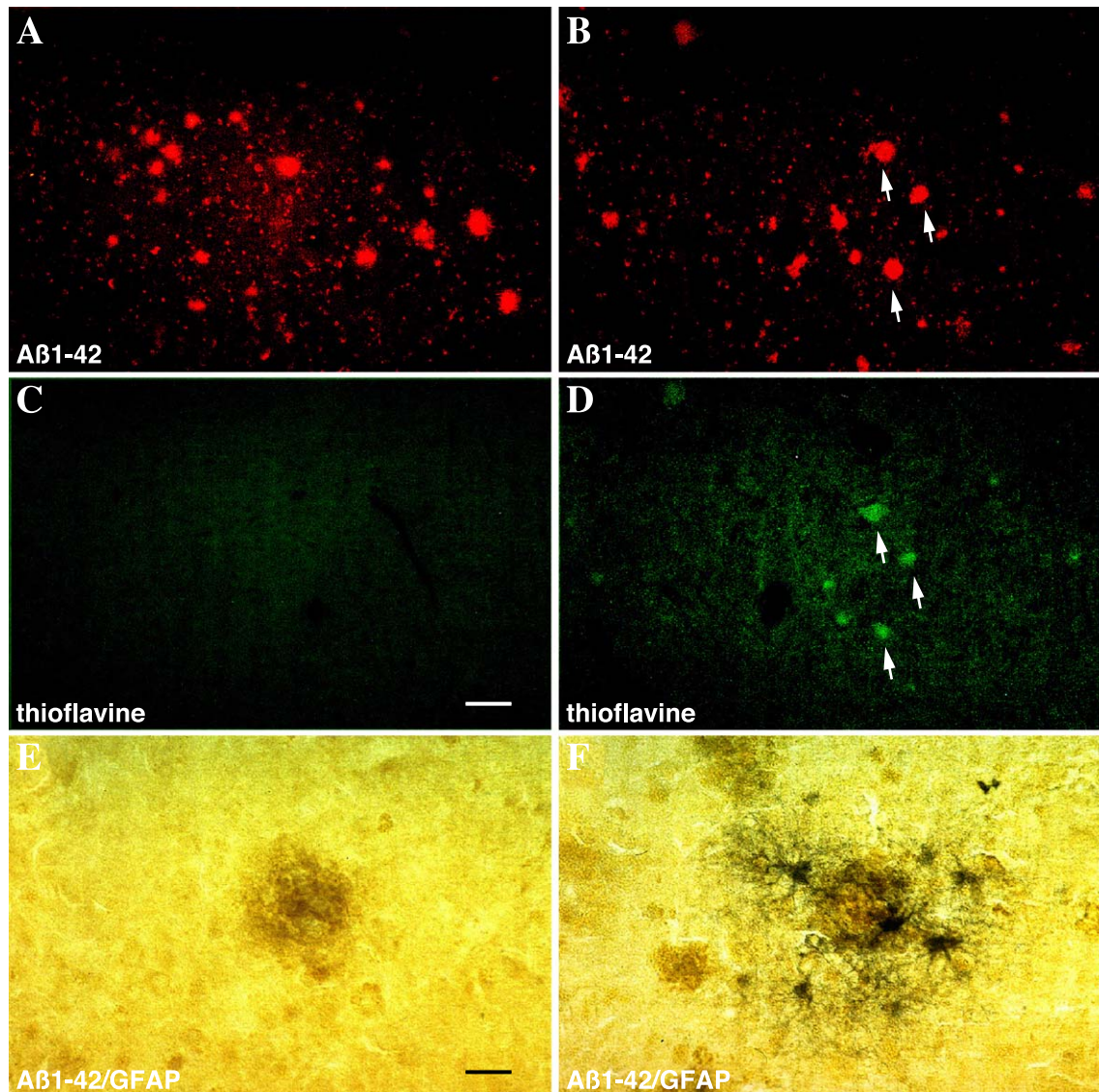


Fig. 3. A $\beta$  plaques of early AD case are diffuse and do not have associated astrocytic reactivity. Frontal cortex sections of daughter (A,C) and mother (B,D) labeled with anti-A $\beta$  antibody (red) (A,B) and thioflavine (green) (C,D). Scale bar: 100  $\mu$ m. Double immunostaining of A $\beta$  (brown) and GFAP (astrocytes, blue-grey) in frontal cortex of daughter (E) and mother (F). Scale bar: 25  $\mu$ m. Note the lack of thioflavine labeling of amyloid plaques in the early AD case (A and C) compared with the AD case (B,D, arrows), and the lack of astrocytes with the A $\beta$  plaque in the early AD (E), but present as expected in the AD case (F).

deposition) matched either for age, race, or cause of death showed no such expression of C1q. Thus, the predominant neuronal C1q localization in both frontal cortex and hippocampus makes this early preclinical AD case currently unique. This could be due to the fact that preclinical AD samples with the same characteristics of this case (very abundant and early deposition of A $\beta$ ) have not yet been found, and/or that the rate of secretion of C1q is regulated differentially in these regions and/or disease states.

Consistent with the prominent presence of C1q in neurons of the preclinical case, pyramidal neurons, as well as glial cells, have been shown to synthesize C1q (in the absence of other complement proteins), in several injury models (Dietzschold et al., 1995; Goldsmith et al., 1997; Lee et al., 2000; Liu et al., 1995; Singhrao et al., 1999) and in AD (Fischer et al., 1995; Shen et al., 1997; Terai et al., 1997). Furthermore, we have recently observed that pyramidal neurons from rat hippocampal slices in culture are able to up-

regulate C1q synthesis in response to A $\beta$  exposure (Fan and Tenner, 2003). C1q may play a role in facilitating the rapid clearance of apoptotic neurons or cellular debris while avoiding inflammation since C1q has been shown to bind to apoptotic cells (Botto et al., 1998; Korb and Ahearn, 1997) and enhance phagocytosis (Henson et al., 2001; Webster et al., 2000) without triggering proinflammatory cytokine expression in monocytes/macrophages (Tenner and colleagues, manuscript in preparation). Thus, it is possible that the synthesis of C1q by neurons may be an initial neuroprotective mechanism in response to injury.

In a previous study (Troncoso et al., 1998), this preclinical case showed only two striking neuropathological abnormalities in the brain. These were abundant diffuse amyloid and enlarged endosomal/lysosomal system of the pyramidal neurons, suggesting an important role of these neurons in the processing of APP and generation of A $\beta$  (Nixon, 2000). As fibrillar amyloid plaques



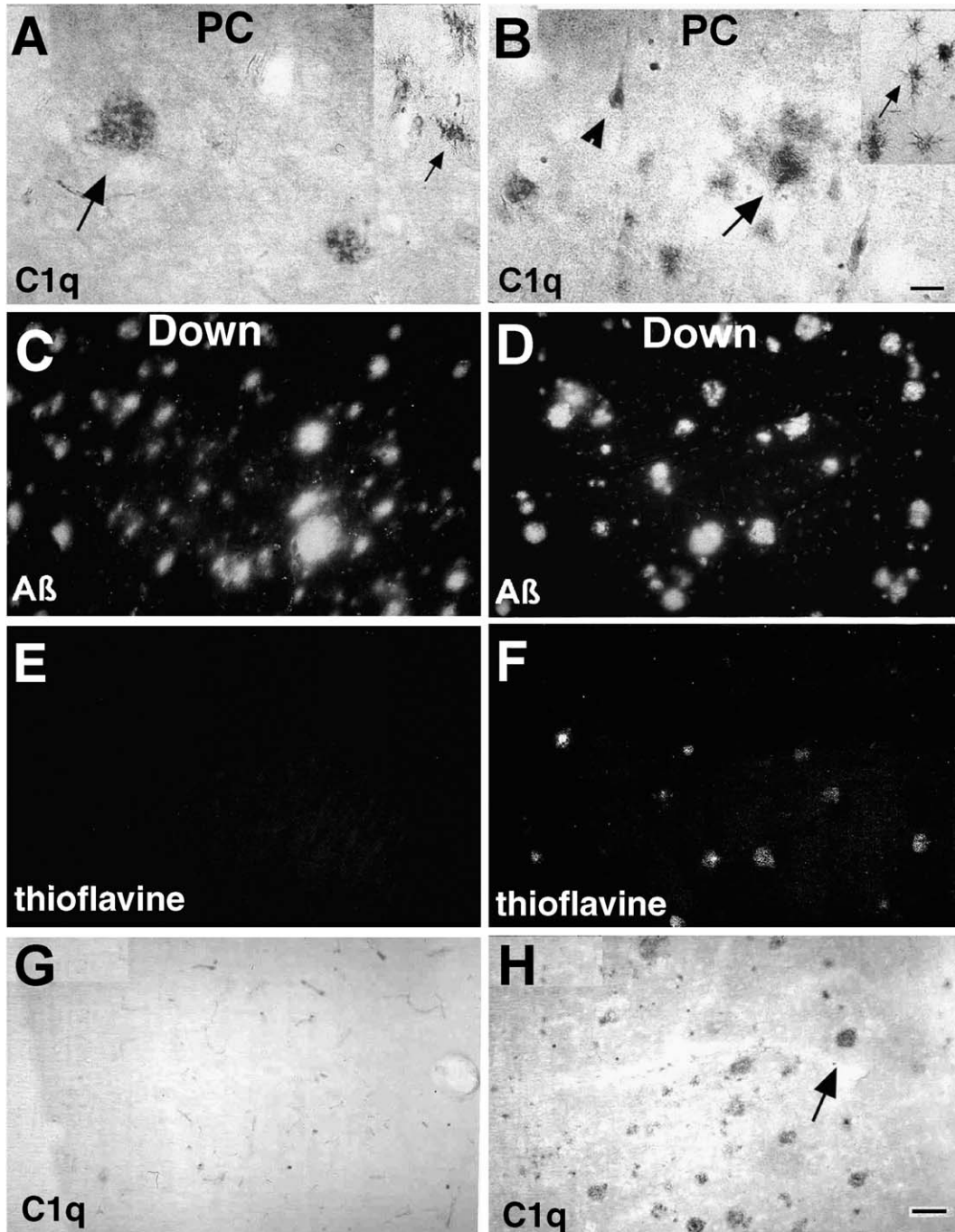


Fig. 4. C1q distribution in other preclinical AD and Down's brain. Frontal cortex of two preclinical cases (A,B) and two Down's cases (28 years old: C,E,G, and 59 years old: D,F,H) was immunostained for C1q (A, B, G, and H), A $\beta$  (C,D), or thioflavine (E,F). C1q is mainly present in plaques (big arrows), but also detected in glia (small arrows) and few neurons (arrowheads). Double labeling for A $\beta$  (C,D) and thioflavine (E,F) show fibrillar A $\beta$  in the 59-year-old Down's cases (D,F) but not in 28-year-old cases (C,E). C1q (single labeling, G,H) is only present when A $\beta$  is fibrillar (thioflavine positive). Scale bar: 25  $\mu$ m for A,B and 50  $\mu$ m for C–H.

resistant to ingestion and/or degradation accumulate and other complement pathway proteins are secreted from “activated” glial cells (Barnum, 1995; Gasque et al., 2000), C1q would then complex with C1r and C1s to form C1, the initial component of the classical complement pathway. C1 binding to fibrillar A $\beta$  could then start the proinflammatory complement cascade. The resultant recruitment of reactive glia to the plaque and production

of proinflammatory cytokines and proteases as well as toxic radicals may contribute to neuronal degeneration. C1q as well as other complement proteins may then play a dual role, as supported by studies with transgenic models of AD in which both protective and detrimental roles of complement proteins were seen (Pasinetti et al., 1996; Wyss-Coray et al., 2002). Future exploration of the dual function of C1q may lead to effective therapeutic interven-

tions to preserve the beneficial functions of this complement component while eliminating the detrimental effects of complement activation.

## Acknowledgments

The authors thank the Johns Hopkins University ADRC Brain Resource Center and Dr. Brian Cummings of the UCI ADRC Tissue Repository for help in accessing the tissue used in this study. Supported by NIA AG 00538, P50 AG16573, and AG-05146.

## References

- Afagh, A., Cummings, B.J., Cribbs, D.H., Cotman, C.W., Tenner, A.J., 1996. Localization and cell association of C1q in Alzheimer's disease brain. *Exp. Neurol.* 138, 22–32.
- Akiyama, H., Barger, S., Barnum, S., Bradt, B., Bauer, J., Cole, G.M., Cooper, N.R., Eikelenboom, P., Emmerling, M., Fiebich, B.L., Finch, C.E., Frautschy, S., Griffin, W.S., Hampel, H., Hull, M., Landreth, G., Lue, L., Mrak, R., Mackenzie, I.R., McGeer, P.L., O'Banion, M.K., Pachter, J., Pasinetti, G., Plata-Salaman, C., Rogers, J., Rydel, R., Shen, Y., Streit, W., Strohmeyer, R., Tooyama, I., Van Muiswinkel, F.L., Veerhuis, R., Walker, D., Webster, S., Wegrzyniak, B., Wenk, G., Wyss-Coray, T., 2000. Inflammation and Alzheimer's disease. *Neurobiol. Aging* 21, 383–421.
- Barnum, S.R., 1995. Complement biosynthesis in the central nervous system. *Crit. Rev. Oral Biol. Med.* 6, 132–146.
- Botto, M., Dell'agnola, C., Bygrave, A.E., Thompson, E.M., Cook, H.T., Petry, F., Loos, M., Pandolfi, P.P., Walport, M.J., 1998. Homozygous C1q deficiency causes glomerulonephritis associated with multiple apoptotic bodies. *Nat. Genet.* 19, 56–59.
- Cataldo, A.M., Hamilton, D.J., Barnett, J.L., Paskevich, P.A., Nixon, R.A., 1996. Properties of the endosomal–lysosomal system in the human central nervous system: disturbances mark most neurons in populations at risk to degenerate in Alzheimer's disease. *J. Neurosci.* 16, 186–199.
- Cummings, B.J., Cotman, C.W., 1995. Image analysis of beta-amyloid “load” in Alzheimer's disease and relation to dementia severity. *Lancet* 346, 1524–1528.
- Dickson, D.W., 1997. The pathogenesis of senile plaques. *J. Neuropathol. Exp. Neurol.* 56, 321–339.
- Dietzschold, B., Schwaebler, W., Schäfer, M.K.H., Hooper, D.C., Zehng, Y.M., Petry, F., Sheng, H., Fink, T., Loos, M., Koprowski, H., Weihe, E., 1995. Expression of C1q, a subcomponent of the rat complement system, is dramatically enhanced in brains of rats with either Borna disease or experimental allergic encephalomyelitis. *J. Neurol. Sci.* 130, 11–16.
- Fan, R., Tenner, A.J., 2003. Complement C1q expression induced by A $\beta$  in rat hippocampal organotypic slice cultures. *Exp. Neurol.* (in press).
- Fischer, B., Schmoll, H., Riederer, P., Bauer, J., Platt, D., Popa-Wagner, A., 1995. Complement C1q and C3 mRNA expression in the frontal cortex of Alzheimer's patients. *J. Mol. Med.* 73, 465–471.
- Gasque, P., Dean, Y.D., McGreal, E.P., VanBeek, J., Morgan, B.P., 2000. Complement components of the innate immune system in health and disease in the CNS. *Immunopharmacology* 49, 171–186.
- Goldsmith, S.K., Wals, P., Rozovsky, I., Morgan, T.E., Finch, C.E., 1997. Kainic acid and decorticating lesions stimulate the synthesis of C1q protein in adult rat brain. *J. Neurochem.* 68, 2046–2952.
- Griffin, W.S., Sheng, J.G., Royston, M.C., Gentleman, S.M., McKenzie, J.E., Graham, D.I., Roberts, G.W., Mrak, R.E., 1998. Glial–neuronal interactions in Alzheimer's disease: the potential role of a ‘cytokine cycle’ in disease progression. *Brain Pathol.* 8, 65–72.
- Head, E., Azizieh, B.Y., Lott, I.T., Tenner, A.J., Cotman, C.W., Cribbs, D.H., 2001. Complement association with neurons and  $\beta$ -amyloid deposition in the brains of aged individuals with Down Syndrome. *Neurobiol. Dis.* 8, 252–265.
- Henson, P.M., Bratton, D.L., Fadok, V.A., 2001. The phosphatidylserine receptor: a crucial molecular switch? *Nat. Rev., Mol. Cell Biol.* 2, 627–633.
- Jiang, H., Burdick, D., Glabe, C.G., Cotman, C.W., Tenner, A.J., 1994.  $\beta$ -Amyloid activates complement by binding to a specific region of the collagen-like domain of the C1q A chain. *J. Immunol.* 152, 5050–5059.
- Korb, L.C., Ahearn, J.M., 1997. C1q binding directly and specifically to surface blebs of apoptotic human keratinocytes. *J. Immunol.* 158, 4525–4528.
- Lee, C.K., Weindruch, R., Prolla, T.A., 2000. Gene-expression profile of the ageing brain in mice. *Nat. Genet.* 25, 294–297.
- Liu, L., Tornqvist, E., Mattsson, P., Eriksson, N.P., Persson, J.K., Morgan, B.P., Aldskogius, H., Svensson, M., 1995. Complement and clusterin in the spinal cord dorsal horn and gracile nucleus following sciatic nerve injury in the adult rat. *Neuroscience* 68, 167–179.
- McKinney, M.M., Parkinson, A., 1987. A simple, non-chromatographic procedure to purify immunoglobulins from serum and ascites fluid. *J. Immunol. Methods* 96, 271–278.
- Morris, J.C., 1993. The clinical dementia rating (CDR): current version and scoring rules. *Neurology* 43, 2412–2414.
- Nixon, R.A., 2000. A “protease activation cascade” in the pathogenesis of Alzheimer's disease. *Ann. N.Y. Acad. Sci.* 924, 117–131.
- Pasinetti, G.M., Tocco, G., Sakhi, S., Musleh, W.D., DeSimoni, M.G., Mascarucci, P., Schreiber, S., Baudry, M., Finch, C.E., 1996. Hereditary deficiencies in complement C5 are associated with intensified neurodegenerative responses that implicate new roles for the C-system in neuronal and astrocytic functions. *Neurobiol. Dis.* 3, 197–204.
- Rogers, J., Schultz, J., Brachova, L., Lue, L.-F., Webster, S., Bradt, B., Cooper, N.R., Moss, D.E., 1992. Complement activation and  $\beta$ -amyloid-mediated neurotoxicity in Alzheimer's disease. *Res. Immunol.* 143, 624–630.
- Rogers, J., Webster, S., Lue, L.F., Brachova, L., Civin, W.H., Emmerling, M., Shivers, B., Walker, D., McGeer, P., 1996. Inflammation and Alzheimer's disease pathogenesis. *Neurobiol. Aging* 17, 681–686.
- Shen, Y., Li, R., McGeer, E.G., McGeer, P.L., 1997. Neuronal expression of mRNAs for complement proteins of the classical pathway in Alzheimer brain. *Brain Res.* 769, 391–395.
- Shen, Y., Lue, L., Yang, L., Roher, A., Kuo, Y., Strohmeyer, R., Goux, W.J., Lee, V., Johnson, G.V., Webster, S.D., Cooper, N.R., Bradt, B., Rogers, J., 2001. Complement activation by neurofibrillary tangles in Alzheimer's disease. *Neurosci. Lett.* 305, 165–168.
- Singhrao, S.K., Neal, J.W., Morgan, B.P., Gasque, P., 1999. Increased complement biosynthesis by microglia and complement activation on neurons in Huntington's disease. *Exp. Neurol.* 159, 362–376.
- Stoltzner, S.E., Grenfell, T.J., Mori, C., Wisniewski, K.E., Wisniewski, T.M., Selkoe, D.J., Lemere, C.A., 2000. Temporal accrual of complement proteins in amyloid plaques in Down's syndrome with Alzheimer's disease. *Am. J. Pathol.* 156, 489–499.
- Tenner, A.J., 2001. Complement in Alzheimer's disease: opportunities for modulating protective and pathogenic events. *Neurobiol. Aging* 22, 849–861.
- Tenner, A.J., Volkin, D.B., 1986. Complement subcomponent C1q secreted by cultured human monocytes has subunit structure identical with that of serum C1q. *Biochem. J.* 233, 451–458.
- Tenner, A.J., Webster, S.D., 2001. Complement-mediated injury and inflammation in the pathogenesis of Alzheimer's Disease. In: Bondy, S.C., Campbell, A. (Eds.), *Inflammatory Events in Neurodegeneration*. Prominent Press, Scottsdale, AZ, pp. 119–138.
- Terai, K., Walker, D.G., McGeer, E.G., McGeer, P.L., 1997. Neurons express proteins of the classical complement pathway in Alzheimer disease. *Brain Res.* 769, 385–390.
- Troncoso, J.C., Cataldo, A.M., Nixon, R.A., Barnett, J.L., Lee, M.K., Checler, F., Fowler, D.R., Smialek, J.E., Crain, B., Martin, L.J., Kawas, C.H., 1998. Neuropathology of preclinical and clinical late-onset Alzheimer's disease. *Ann. Neurol.* 43, 673–676.

- Webster, S.D., Park, M., Fonseca, M.I., Tenner, A.J., 2000. Structural and functional evidence for microglial expression of C1qR<sub>p</sub>, the C1q receptor that enhances phagocytosis. *J. Leukoc. Biol.* 67, 109–116.
- Weggen, S., Eriksen, J.L., Das, P., Sagi, S.A., Wang, R., Pietrzik, C.U., Findlay, K.A., Smith, T.E., Murphy, M.P., Bulter, T., Kang, D.E., Marquez-Sterling, N., Golde, T.E., Koo, E.H., 2001. A subset of NSAIDs lower amyloidogenic Abeta42 independently of cyclooxygenase activity. *Nature* 414, 212–216.
- Wyss-Coray, T., Yan, F., Lin, A.H., Lambris, J.D., Alexander, J.J., Quigg, R.J., Masliah, E., 2002. Prominent neurodegeneration and increased plaque formation in complement-inhibited Alzheimer's mice. *Proc. Natl. Acad. Sci. U. S. A.* 99, 10837–10842.