

# UC Davis

## UC Davis Previously Published Works

### Title

Role of endoscopic ultrasound for pre-intervention evaluation in early esophageal cancer.

### Permalink

<https://escholarship.org/uc/item/8cg9p8r0>

### Journal

World Journal of Gastrointestinal Endoscopy, 15(6)

### ISSN

1948-5190

### Authors

Kahlon, Sartajdeep

Aamar, Ali

Butt, Zeeshan

et al.

### Publication Date

2023-06-16

### DOI

10.4253/wjge.v15.i6.447

Peer reviewed



Retrospective Cohort Study

# Role of endoscopic ultrasound for pre-intervention evaluation in early esophageal cancer

Sartajdeep Kahlon, Ali Aamar, Zeeshan Butt, Shiro Urayama

**Specialty type:** Gastroenterology and hepatology

**Provenance and peer review:** Unsolicited article; Externally peer reviewed.

**Peer-review model:** Single blind

**Peer-review report's scientific quality classification**

Grade A (Excellent): 0  
Grade B (Very good): B  
Grade C (Good): C  
Grade D (Fair): D  
Grade E (Poor): 0

**P-Reviewer:** Binda C, Italy; Edholm D, Sweden; Martino A, Italy

**Received:** February 24, 2023

**Peer-review started:** February 24, 2023

**First decision:** March 24, 2023

**Revised:** April 8, 2023

**Accepted:** May 12, 2023

**Article in press:** May 12, 2023

**Published online:** June 16, 2023



**Sartajdeep Kahlon, Ali Aamar, Shiro Urayama**, Department of Internal Medicine, University of California-Davis, Sacramento, CA 95817, United States

**Zeeshan Butt**, Department of Internal Medicine, Baystate Medical Center, Springfield, MA 01199, United States

**Corresponding author:** Shiro Urayama, MD, Professor, Department of Internal Medicine, University of California-Davis, 4150 V St Suite 3500, Sacramento, CA 95817, United States. [surayama@ucdavis.edu](mailto:surayama@ucdavis.edu)

## Abstract

### BACKGROUND

Endoscopic ultrasound (EUS) stands as an accurate imaging modality for esophageal cancer staging, however utilization of EUS in early-stage cancer management remains controversial. Identification of non-applicability of endoscopic interventions with deep muscular invasion with EUS in pre-intervention evaluation of early-stage esophageal cancer is compared to endoscopic and histologic indicators.

### AIM

To display the role of EUS in pre-intervention early esophageal cancer staging and how the index endoscopic features of invasive esophageal malignancy compare for prediction of depth of invasion and cancer management.

### METHODS

This was a retrospective study of patients who underwent pre-resection EUS after a diagnosis of esophageal cancer at a tertiary medical center from 2012 to 2022. Patient clinical data, initial esophagogastroduodenoscopy/biopsy, EUS, and final resection pathology reports were abstracted, and statistical analysis was conducted to assess the role of EUS in management decisions.

### RESULTS

Forty nine patients were identified for this study. EUS T stage was concordant with histological T stage in 75.5% of patients. In determining submucosal involvement (T1a vs T1b), EUS had a specificity of 85.0%, sensitivity of 53.9%, and accuracy of 72.7%. Endoscopic features of tumor size > 2 cm and the presence of esophageal ulceration were significantly associated with deep invasion of cancer on histology. EUS affected management from endoscopic mucosal resecti-

on/submucosal dissection to esophagectomy in 23.5% of patients without esophageal ulceration and 6.9% of patients with tumor size < 2 cm. In patients without both endoscopic findings, EUS identified deeper cancer and changed management in 4.8% (1/20) of cases.

### CONCLUSION

EUS was reasonably specific in ruling out submucosal invasion but had relatively poor sensitivity. Data validated endoscopic indicators suggested superficial cancers in the group with a tumor size < 2 cm and the lack of esophageal ulceration. In patients with these findings, EUS rarely identified a deep cancer that warranted a change in management.

**Key Words:** Endoscopic ultrasound; Esophageal early-stage cancer; Endoscopic intervention; Endoscopic indicators of invasive cancer; Cancer intervention; Endoscopy

©The Author(s) 2023. Published by Baishideng Publishing Group Inc. All rights reserved.

**Core Tip:** This study aims to convey the role of endoscopic ultrasound (EUS) for early esophageal cancer considered for endoscopic or surgical resection and how the index endoscopic features of esophageal malignancy compare for prediction of depth of invasion and cancer management. This was a retrospective study of 49 patients who underwent pre-resection EUS after diagnosis of esophageal cancer. EUS was reasonably specific in ruling out submucosal invasion but had relatively poor sensitivity. Data validated endoscopic features suggesting superficial cancers including a tumor size < 2 cm and the lack of esophageal ulceration. In patients with these findings, EUS rarely identified a deep cancer that warranted a change in management.

**Citation:** Kahlon S, Amar A, Butt Z, Urayama S. Role of endoscopic ultrasound for pre-intervention evaluation in early esophageal cancer. *World J Gastrointest Endosc* 2023; 15(6): 447-457

**URL:** <https://www.wjgnet.com/1948-5190/full/v15/i6/447.htm>

**DOI:** <https://dx.doi.org/10.4253/wjge.v15.i6.447>

## INTRODUCTION

Esophageal cancer is the eighth-most common cancer and sixth-most common cause of mortality globally[1]. In the United States, an estimated 20,640 cases of esophageal cancer are diagnosed in 2022, and 16,410 deaths are expected from the disease, highlighting the importance of its diagnosis and treatment[2,3].

With the advent of less invasive interventions including endoscopic mucosal resection (EMR) or submucosal dissection (ESD) for superficial cancers, accurate clinical staging of esophageal cancer becomes critical in selecting appropriate treatment options[1]. Pre-intervention tumor depth staging (T staging) is vital in assessing which patients without an evidence of metastasis, would benefit from endoscopic or surgical intervention. Tumors limited to mucosa can be completely resected with endoscopic therapy due to lower risk of incomplete resection or lympho-vascular invasion<sup>3</sup>. NCCN guideline recommends endoscopic resection in the management of T1a lesions and superficial T1b lesions, or T1b-sm<sup>1</sup> lesions that superficially invade the submucosa[4]. Tumors staged T1b-sm<sup>2</sup> or sm<sup>3</sup> have significant risk for recurrence and warrant evaluation for esophagectomy[5].

Endoscopic ultrasound (EUS) has been commonly utilized as the most accurate imaging study for staging primary esophageal cancer in comparison to other modalities[4]. Specifically, EUS has been shown to accurately assess T staging in the cancer (73.2%-80.6%), excelling in distinguishing T3/T4 Lesions from T1/T2[6-9]. EUS remains a key component of locoregional assessment to determine the depth of invasion and nodal involvement while also allowing the possibility of fine-needle aspiration sampling[10]. Classifying more superficial lesions into T1a, T1b-sm<sup>1</sup>, T1b-sm<sup>2</sup>, or T1b-sm<sup>3</sup> lesions, however, has proven difficult *via* EUS[11]. Currently for superficial cancers, EUS is readily combined with EMR or ESD to optimize the clinical management. Specifically, EUS allows exclusion of the presence of a deeper cancer invasion, which makes an EMR or ESD potentially unsafe and/or lead to an incomplete intervention.

There are several studies delineating the correlation of endoscopic and biopsy assessments as evidence for deeper invasion in esophagus cancer in lieu of EUS[12-15]. These suggest that EUS may not provide additional information in situations where endoscopic or pathologic parameters sufficiently characterize esophageal cancers and fully dictate management. Thus, controversy remains in the utility of EUS in patients who have suspected early-stage esophageal cancer and how it can affect management. Current study aims to display the role of EUS for early esophageal cancer staging and

how the index endoscopic indicators of invasive esophageal malignancy compare for assessment of depth of invasion and the cancer management.

## MATERIALS AND METHODS

### **Ethics**

This was a retrospective study of patients who underwent pre-intervention EUS with a diagnosis of esophageal cancer between January 2012 to January 2022 at a tertiary medical center. This study period was used to minimize the effect of incomplete data allocation from the period prior to establishment of electronic medical record. This study was approved on November 1, 2021 by the Institutional Review Board of the hospital in accordance with its ethical standards and assigned IRB protocol number 1816393-1.

### **Study population**

Ninety three patients were identified *via* EMR search conducted with assistance from the Clinical and Translational Science Center at University of California, Davis. The search was conducted at for patients with ICD-10 codes C15.0 to C15.9 logged for esophageal malignancies in their medical record and those with Current Procedural Terminology code 43242 logged for EUS procedures during the study period at our medical center. Patient's without electronic documentation of EUS procedure reports were excluded from the study. From this population, patients were ascertained who met the inclusion criteria of age over 18 years, established diagnosis from biopsies collected during index esophagogastroduodenoscopy (EGD), EUS conducted prior to any therapeutic intervention such as endoscopic/surgical resection. Exclusion criteria included: EUS was not conducted prior to any therapeutic interventions, EUS did not indicate staging, EUS did not yield a pathologic specimen, and patients treated with neoadjuvant treatment before esophagectomy. Forty nine patients met criteria for analysis. This is summarized in [Figure 1](#).

### **T staging by EUS and pathologic diagnosis**

EUS was performed with an Olympus radial echoendoscope (GF-UE160, Olympus America, Penn Valley, United States). EGD and EUS procedures were performed by a single endosonographer with over 10 years of experience at the beginning of the study period. Pre-operative T staging was made in accordance with TNM staging system for esophageal cancer with the 8th edition of the American Joint Committee on Cancer (AJCC) classifications for staging of epithelial cancers of the esophagus and esophagogastric junction[16]. As this classification was updated in 2017 to differentiate T1a from T1b lesions, cases conducted prior to 2017 were staged in this study per the updated criteria based on findings present in EUS and pathology reports[17]. The level of tumor invasion was consistently described in both types of reports, allowing for pre-2017 to be classified using the 8<sup>th</sup> edition TNM staging. Descriptions of submucosal invasion as "irregularities between the mucosal and submucosal border" were used to determine T1b or beyond staging in written reports. The presence of notable para-esophageal lymph nodes on EUS was also denoted in reports including comments regarding diagnostic value. Pathologic diagnosis was determined by pathologists' interpretation of tissue sample taken during endoscopy either by EMR, ESD, esophagectomy or forceps biopsy. For the purposes of this study, deep invasion (DI) was defined as a T2 lesion or more ([Figure 2](#)).

### **Outcomes**

Patient characteristics and clinical data were extracted from chart review including birth date, sex, ethnicity, type of esophageal cancer (adenocarcinoma, squamous cell carcinoma or other cancer), diagnosis of Barrett's esophagus. EGD/EUS written procedure reports were used to extract data for the following characteristics: Presence of esophageal ulceration, size of tumor, presence of notable para-esophageal lymph nodes, and T staging per EUS. If unavailable in the EUS report, the presence of ulceration and size of tumor was reported *via* an initial EGD report if done less than 3 mo prior to EUS procedure date. Either biopsy or resection method after EUS was recorded as well. Data from pathology after EMR, ESD, esophagectomy, or forceps biopsy included size and grade of tumor, lateral and deep margins status, the presence of lympho-vascular invasion, and TNM-staging identified on the specimen.

### **Statistical analysis**

IBM SPSS Statistics 20 was used for all statistical analysis. Frequencies and percentages were calculated for all nominal and ordinal variables. Sensitivity, Specificity, Positive Predictive Value, Negative Predictive Value and Accuracy of EUS in identifying sub-mucosal invasion in histological verified T1 tumors were calculated. Moreover, DI of tumor on histology (defined as T2 or beyond) and clinical characteristics significantly associated with DI were identified by using chi-square test. *P* value < 0.05 was considered significant for all comparisons.

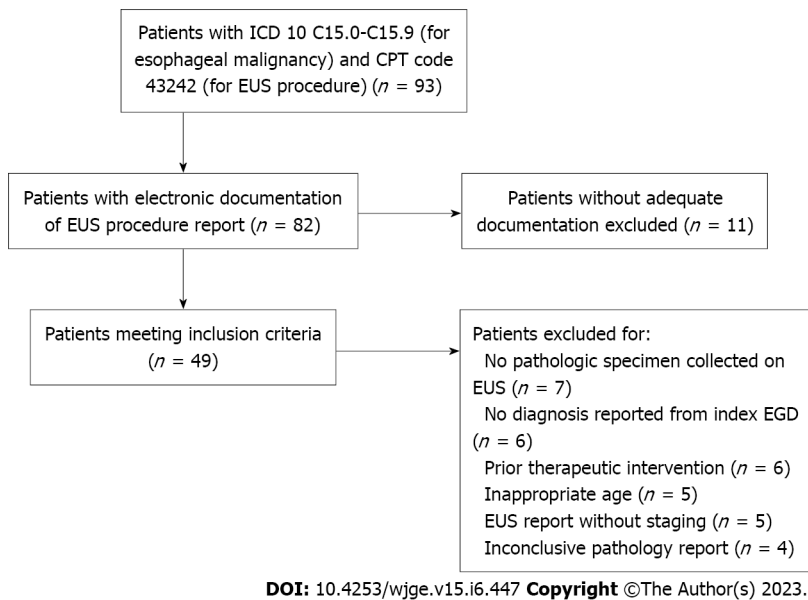


Figure 1 Patient recruitment with relevant exclusion criteria. EUS: Endoscopic ultrasound; EGD: Esophagogastroduodenoscopy.

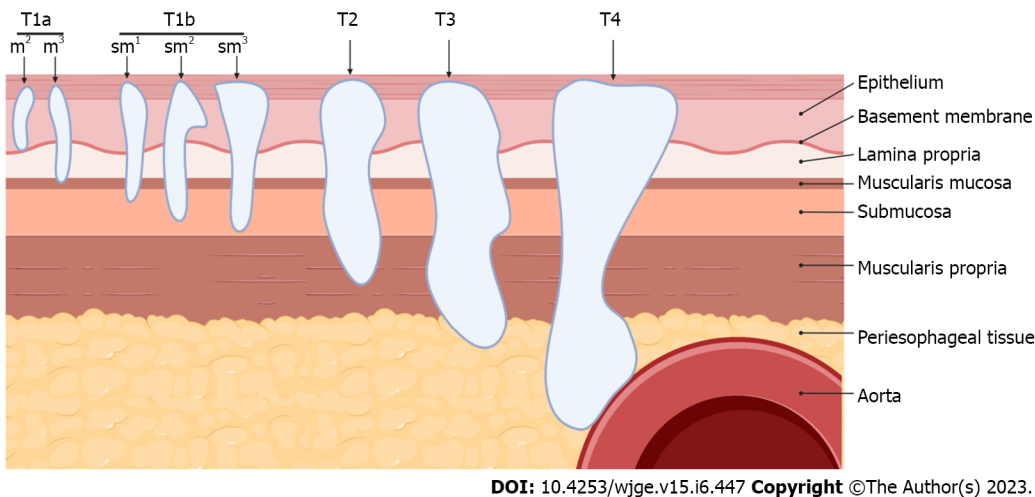


Figure 2 An illustration depicting the sub-classification of esophageal cancer stage. T1b lesion invades the submucosal layer and are stratified into sm<sup>1</sup>, sm<sup>2</sup>, and sm<sup>3</sup> lesions according to involvement of the first, middle, and deep one-thirds of the submucosa, respectively[16]. Image created in BioRender.

## RESULTS

A total of 49 patients were identified for the study. Table 1 summarizes the demographics and clinical characteristics of all patients. Majority of them were males and white, 85.7% and 87.5%, respectively. Adenocarcinoma was the predominant type of cancer (89.8%) among all patients. Prior diagnosis of Barrett’s esophagus was present in 65.3% patients. 30.6% of patients were noted to have esophageal ulceration during endoscopy. 39.6% of the patients had tumor size of > 2 cm on visual inspection. EUS identified non-diagnostic lymphadenopathy in 50% of patients, of which none had reported findings for diagnostic lymph node assessment per EUS criteria (*i.e.* size, shape, border, echogenicity)[18]. On EUS, 48.9%, 20.4%, 8.2% and 22.4% of patients had T1a, T1b, T2 and T3 tumors, respectively. Subsequently, patients underwent EMR (51%), ESD (10.2%), esophagectomy (30.6%), and diagnostic biopsy (8.2%). On histological examination, 40.8%, 26.5%, 10.2% and 22.4% of patients had T1a, T1b, T2 and T3 tumors. Lympho-vascular invasion was found in 24.4% of all patients.

Table 2 summarizes T stages on EUS against the stage found on final histology. Among all patients with histological T1a (*n* = 20), 85.0% were correctly labeled as T1a by EUS (17/20), while 15.0% (3/20) were labeled as T1b. Among 13 histologically verified T1b patients, only 46.2% (6/13) were correctly identified as T1b on EUS. Similarly, among 5 T2 patients, only 3 were correctly identified as T2 by EUS. All 11 T3 patients were correctly identified as T3 by EUS. Overall EUS T stage was concordant with histological T stage in 75.5% of patients (37/49).

**Table 1 Basic demographics and clinical characteristics of all patients**

Variable		Number/Total (n/N)	Percentage (%)
Gender	Males	42/49	85.7
Ethnicity	Caucasian	42/48	87.5
	Hispanic	1/48	2.1
	Asian	5/48	10.4
Type of cancer	Adenocarcinoma	44/49	89.8
	SCC	5/49	10.2
Degree of differentiation	Invasive well differentiated	18/39	46.2
	Invasive moderately differentiated	19/39	48.7
	Invasive poorly differentiated	4/39	10.3
History of Barrett's esophagus	Yes	32/49	65.3
Esophageal ulceration	Yes	15/49	30.6
Tumor size	< 1 cm	6/48	12.5
	1 - < 1.5 cm	12/48	25
	≥ 1.5 - < 2 cm	11/48	22.9
	≥ 2 cm	19/48	39.6
Lymphadenopathy	Yes (only non-diagnostic EUS features)	24/48	50.0
EUS stage	T1a	24/49	48.9
	T1b	10/49	20.4
	T2	4/49	8.2
	T3	11/49	22.4
	T4	0/49	0
Specimen collection method	Biopsy	4/49	8.2
	EMR	25/49	51.0
	ESD	5/49	10.2
	Esophagectomy	15/49	30.6
Lympho-vascular invasion	Yes	12/49	24.4
Pathological staging	T1a	20/49	40.8
	T1b	13/49	26.5
	T2	5/49	10.2
	T3	11/49	22.4
Tumor recurrence	Yes	5/44	11.4

n: Number of patients with demographic or clinical characteristic present; N: Number of patients with clinical data available regarding the presence or absence of each demographic or clinical characteristic. EMR: Endoscopic mucosal resection; ESD: Submucosal dissection; EUS: Endoscopic ultrasound; SCC: Squamous cell carcinoma.

Among these cancer patients, 33 out of 49, had either T1a or T1b cancer on histology. **Table 3** shows sensitivity, specificity, PPV, NPV, and diagnostic accuracy of EUS in identifying sub-mucosal invasion (T1b) in T1 Cancers. Although EUS was reasonably specific in ruling out sub-mucosal invasion when it was not present (85.0%), it had a poor sensitivity to identify sub-mucosal invasion when it truly was present (53.9%). EUS had an overall accuracy of 72.7% in identifying sub-mucosal invasion in T1 cancers.

DI of tumor on histology was defined as T2 or beyond and endoscopic characteristics significantly associated with DI are depicted in **Table 4**. Proportions of patients with DI having the significant endoscopic parameters were compared to patients without DI. Tumor size ≥ 2 cm on visual inspection was significantly associated with DI of cancer on histology. 50% of DI cancers and 21.2% of superficial

**Table 2** Frequencies and proportions of endoscopic ultrasound staging across pathological staging categories, *n* (%)

			Pathologic stage			
			T1a, N = 20	T1b, N = 13	T2, N = 5	T3, N = 11
EUS stage	T1a	<i>n</i> / <i>N</i> (%)	17/20 (85.7)	6/13 (46.2)	1/5 (20)	0/11 (0)
	T1b	<i>n</i> / <i>N</i> (%)	3/20 (14.2)	6/13 (46.2)	1/5 (20)	0/11 (0)
	T2	<i>n</i> / <i>N</i> (%)	0/20 (0)	1/13 (7.7)	3/5 (60)	0/11 (0)
	T3	<i>n</i> / <i>N</i> (%)	0/20 (0)	0/13 (0)	0/5 (0)	11/11 (100)

EUS: Endoscopic ultrasound.

**Table 3** Sensitivity, specificity and diagnostic accuracy of endoscopic ultrasound staging in identifying submucosal invasion (T1b) in T1 cancers

		Submucosal invasion on path						
		Yes (T1b), N = 13	No (T1a), N = 20	Sensitivity	Specificity	PPV	NPV	Accuracy
Submucosal invasion on EUS	Yes	7	3	53.9%	85.0%	70%	73.9%	72.7%
	No	6	17					

EUS: Endoscopic ultrasound.

**Table 4** Proportions of patients with deep invasion (T2 and beyond) having the significant endoscopic or pathologic parameter compared to proportions of patients without deep invasion

Deep invasion on pathology		Endoscopic parameter		
		Tumor size ≥ 2 cm on visual inspection	Presence of esophageal ulceration	Tumor size ≥ 2 cm on visual inspection & presence of esophageal ulceration
Yes (T2 and beyond)	<i>n</i> <sub>1</sub> / <i>N</i> <sub>1</sub> (%)	13/16 (81.2)	8/16 (50.0)	7/16 (43.8)
No (T1a and T1b)	<i>n</i> <sub>2</sub> / <i>N</i> <sub>2</sub> (%)	6/32 (18.8)	7/33 (21.2)	2/33 (6.1)
<i>P</i> value <sup>a</sup>		< 0.001	0.0403	0.0014
Deep invasion on pathology		Degree of differentiation on pathology		
		Well-Differentiated	Moderately to poorly differentiated	
Yes (T2 and beyond)	<i>n</i> <sub>1</sub> / <i>N</i> <sub>1</sub> (%)	2/12 (16.7)	10/12 (83.3)	
No (T1a and T1b)	<i>n</i> <sub>2</sub> / <i>N</i> <sub>2</sub> (%)	14/27 (53.6)	13/27 (46.4)	
<i>P</i> value <sup>a</sup>		0.0392	0.0392	

<sup>a</sup>*P* value derived from chi-square test to compare proportions in each column for patients with deep invasion (“Yes” row) for each endoscopic or pathologic parameter and without deep invasion (“No” row).

*n*<sub>1</sub>: Number of patients with factor being assessed and deep invasion on pathology; *N*<sub>1</sub>: Number of patients with deep invasion on pathology and clinical data available regarding the presence or absence of each factor; *n*<sub>2</sub>: Number of patients with factor being assessed and no deep invasion on pathology; *N*<sub>2</sub>: Number of patients without deep invasion on pathology and clinical data available regarding the presence or absence of each factor.

cancers had ulceration on EGD. Similarly, pathologic factors associated with DI are also noted. As the tumors’ degree of differentiation went from well- to poor-, likelihood of DI also significantly increased (*P* = 0.0392).

The EUS parameter associated with DI was the presence of notable (non-diagnostic) para-esophageal lymph node, as depicted in Table 5. Importantly, the presence of notable para-esophageal lymph nodes, whether characterized as lymphadenopathy or described as “prominent”, was typically without significant diagnostic findings including size, shape, border, or echogenicity. Thus, none of the reported notable lymph nodes met EUS criteria predictive for lymph node metastasis[18].

**Table 5 Proportions of patients with deep invasion (T2 and beyond) having the endoscopic ultrasound parameters assessed compared to proportions of patients without deep invasion**

Deep invasion on pathology		EUS parameter	
		Presence of notable (but non-diagnostic) para-esophageal lymph nodes on EUS	Presence of positive lymph nodes by EUS criteria
Yes (T2 and beyond)	$n_1/N_1$ (%)	13/16 (81.2)	0/16 (0)
No (T1a and T1b)	$n_2/N_2$ (%)	11/33 (33.3)	0/33 (0)
<i>P</i> value <sup>a</sup>		< 0.001	N/A

<sup>a</sup>*P* value derived from chi-square test done to compare proportion of patients with deep invasion for each endoscopic or pathologic parameter (“Yes” row) to proportion of patients without deep invasion (“No” row).

$n_1$ : Number of patients with factor being assessed AND deep invasion on pathology;  $n_2$ : Number of patients with factor being assessed AND no deep invasion on pathology;  $N_1$ : Number of patients with deep invasion on pathology and clinical data available regarding the presence or absence of each factor;  $N_2$ : Number of patients without deep invasion on pathology and clinical data available regarding the presence or absence of each factor. EUS: Endoscopic ultrasound; N/A: Not applicable.

Several studies indicate that endoscopic findings of tumor size  $\geq 2$  cm and the presence of ulceration are associated with deep invasive tumors that are staged T2 and beyond[13-15]. Thus, the lack of these findings on endoscopy would suggest more superficial cancers. Cases without these findings on endoscopy were assessed to identify if the addition of EUS identified DI, when a superficial cancer is suspected. This is critically important as DI warrants esophagectomy over EMR/ESD.

## DISCUSSION

The utility of pre-intervention EUS of the esophageal cancer is influenced by its accuracy in T staging. Early studies have reported the accuracy at 84%[19]. Additional studies reported the EUS accuracy ranging from 75%-82% for T1 esophageal cancer as compared to 88-100% for T4 lesions[20]. In current study including the sub-classification of T1a and T1b, EUS T staging was found to be concordant with histology 75.5% of the time.

In a study focusing on early-stage esophageal cancer subset, the lower accuracy of EUS reflects on the imprecision of distinguishing T1a and T1b lesions, which in turn reflects on its limitation of subclassifying a lesion into superficial (sm1) *vs* deep submucosal invasion (sm<sup>2</sup> and sm<sup>3</sup>) cancer. In a systematic review and subsequent meta-analysis, Thosani *et al*[21] reported sensitivities and specificities for EUS in determining T1a and T1b staging. For T1b, the sensitivity and specificity were both 0.86. In staging T1b lesions, our study indicated EUS was reasonably specific (0.83) in ruling out sub-mucosal invasion; however, it had relatively poor sensitivity (0.54) in identifying the invasion. Overall accuracy of EUS in staging T1b lesions in our study was 72.7%. Similar issues were highlighted by another retrospective cohort study involving 131 cases of patient undergoing EUS for early esophageal cancer staging. In the study, EUS found no submucosal involvement in 80% of cases, however, histopathological evaluation after EMR determined either submucosal invasion, positive resection margin for cancer, or lymphovascular invasion in 24% of these cases[11].

The value of pre-intervention EUS evaluation in suspected early-stage cancer relies on whether it provides change-of-management information for endoscopic intervention such as EMR or ESD. Clear evidence suggestive of deep muscular involvement (*i.e.* DI) or presence of significant adenopathy would preclude such endoscopic intervention.

Established endoscopic predictive signs of DI (*i.e.* T2 and beyond) include size  $\geq 2$  cm, moderate to poorly differentiated cancer, and the presence of ulceration[13-15]. In our study, 81.2% of lesions with deep invasion were  $\geq 2$  cm, validating this parameter association with deep invasion. The presence of esophageal ulceration had a similar trend with 50.0% of lesions with deep invasion having ulceration, significantly more than the 21.2% of superficial cancers with ulceration. Both endoscopic parameters of a tumor size  $\geq 2$  cm and the presence of esophageal ulceration were present in 43.8% of cases with DI and only 6.1% of cases without DI. The association between the investigated endoscopic features with deep invasive esophageal lesions is further cemented through these results. It was also found that the presence of moderate to poor differentiation was associated with deep invasion in 83.3% of cases. The presence of these parameters indicates a higher likelihood for deep invasion and EUS is warranted as prior studies and our study indicate its accuracy in staging lesions that are T2 and beyond. Particularly, size, ulceration, and degree of differentiation can be determined on initial diagnostic EGD with biopsy, highlighting their presence as determining indicators to pursue an EUS staging procedure. Differentiating between superficial and deep cancer helps to determine intervention and has significant implications downstream in survival, complications, and cost-saving measures[22].



**Table 6** Cases of endoscopic ultrasound concordance and discordance with endoscopic parameters suggesting superficial cancer

Endoscopic Parameter(s) Associated with superficial cancer	Cases of EUS revealing superficial cancer (leading to EMR or ESD)	Cases of EUS revealing DI (Esophagectomy performed)	Frequency EUS changes management (%)
Tumor size < 2 cm	27	2	6.9
Lack of ulceration	26	8	23.5
Tumor size < 2 cm & lack of ulceration	20	1	4.8

EUS: Endoscopic ultrasound; ESD: Submucosal dissection; EMR: Endoscopic mucosal resection; DI: Deep invasion.

If endoscopic parameters of a tumor size  $\geq 2$  cm and ulceration are not present, it could be inferred that the relevant lesion is more likely superficial. Thus, we reviewed the cases with lesions < 2 cm or ulceration among our group to see if EUS noted DI. Of 29 patients with tumors < 2 cm in size, EUS identified DI and suggested esophagectomy in 2. Of 34 patients without ulceration, EUS identified DI cancer and suggested esophagectomy in 8 of them. Seven of these patient's had other signs of deep invasion including tumor size  $\geq 2$  cm or moderately to poorly differentiated cancer. Of 21 patients without esophageal ulceration and with a tumor size < 2 cm, EUS identified 1 case of DI and changed management to esophagectomy, as noted in Table 6. Given the small sample size of these subgroups, significance is difficult to determine, however, we observed that EUS only infrequently changed the outcome in the patients based on prior endoscopic features.

The finding of any notable (non-diagnostic) para-esophageal lymph nodes on EUS was significantly associated with DI cancers per data presented in Table 5 above. In both deep and superficial cancers, all notable para-esophageal lymph nodes described in procedure reports were not malignant by EUS criteria (size great than 10 mm, round appearance, well-demarcated, and homogeneous hypoechogenic appearance) and did not significantly alter clinical management[18,23]. Among these patients, no lymph nodes were noted on the staging computed tomography imaging. In the 11 superficial cancers with non-diagnostic para-esophageal lymph nodes, the finding did not alter management after undergoing endoscopic intervention based on EUS findings. On follow up, all 11 patients had no additional treatment for esophageal cancer and no evidence of recurrence from the date of the studied EUS procedure (ranging from 01/2005 to 03/22022) until present day. In all 13 patients who had non-diagnostic para-esophageal lymph nodes in addition to deep invasion on pathology, endoscopic parameters associated with deep invasion (tumor size  $\geq 2$  cm, presence of ulceration, and moderate to poorly differentiated cancer) were present as well. All 13 patients were considered for esophagectomy, with a majority undergoing surgical resection. While non-diagnostic para-esophageal lymph nodes are more often present in deeper cancers, their presence does not appear to change management decisions.

The present study presents a limitation of a single-center retrospective study with a study population that lacks external validity. The volume of patients included in this study may not adequately depict the population of patients undergoing EUS procedures. Patients were predominantly white males, and as discussed, esophageal cancer occurs globally at higher rates in certain subpopulations throughout the world. Additionally, cases were analyzed using written reports of EUS procedures without any validation of the imaging findings directly. Written reports of submucosal invasion are limited by endoscopist interpretation without reviewing all imaging findings, which was not possible in all cases. Cases where EUS did not determine staging were excluded, thus limiting analysis of instances where EUS was not able to assess depth of invasion at all; however, the vast majority of cases where EUS did not yield staging did not visualize cancerous lesions on endoscopy. A majority of patients had T1a lesions, adding selection bias to our study limited by the types of patients referred to our single academic medical. Our study selects for patients living in the US with adequate access to care to undergo the aforementioned procedures.

To further substantiate our findings, a prospective multi-center analyses would be ideal to verify operability and accuracy. To improve on the limitation of endoscopic ultrasonography precision in detecting the subtle submucosal invasion further investigation may require applications of technologies such as photoacoustic or scanning laser acoustic microscopy or optical coherence tomography, which could provide higher axial resolution than ultrasonography at meaningful penetration depths of a few millimeters[24,25].

## CONCLUSION

In conclusion, EUS has limited effectiveness in distinguishing sublayer involvement of superficial esophageal lesions. Since pre-intervention EUS in evaluation of endoscopically and imaging suggested superficial cancer may be limited, we suggest that the role of EUS in this setting may be assessed with careful endoscopic examination and approached in the following way: When initial endoscopic

indicators suggest deep invasion, EUS has utility in investigating the DI cancer. In cases where deep cancer is not suspected based on the endoscopic parameters, one may consider directly proceeding with endoscopic intervention as it is cost effective and provides more accurate T staging by histology.

## ARTICLE HIGHLIGHTS

### **Research background**

Endoscopic ultrasound (EUS) has been utilized as the most accurate imaging modality for primary tumor staging in esophageal cancer. Primary tumor staging is key in management as cancers with submucosal invasion warrant esophagectomy while more superficial cancers are managed with endoscopic interventions like endoscopic mucosal resection (EMR) and endoscopic submucosal dissection (ESD). Studies exist that correlate endoscopic parameters with biopsy assessments to identify esophageal cancers with deep invasion in lieu of EUS.

### **Research motivation**

EUS has proven to be useful in identifying advanced stage tumors. Its usefulness in early-stage cancers has been more controversial. We wanted to assess how EUS influences management in early-stage esophageal cancers as the presence of submucosal invasion warrants surgery instead of endoscopic intervention.

### **Research objectives**

The objectives of this study included evaluating the diagnostic capabilities of EUS in primary staging of esophageal cancers. We also sought to identify if EUS could reliably discriminate between early-stage cancers with and without submucosal invasion. The study aimed to substantiate endoscopic parameters associated with deep esophageal cancer *vs* superficial esophageal cancer. Finally, our objective was to determine how often EUS changed management by identifying submucosal invasion in cancers with endoscopic parameters associated with superficial esophageal cancers.

### **Research methods**

A retrospective cohort study was utilized to assess patients who had undergone primary staging of esophageal cancer *via* EUS at a tertiary medical center. Case data was gathered *via* chart review and statistical analysis was conducted to assess the accuracy of EUS, endoscopic parameters associated with deep invasion, and the frequency EUS findings changed management when endoscopic parameters suggested a superficial cancer.

### **Research results**

In staging T1b lesions, EUS was specific in ruling in submucosal invasion but had relatively poor sensitivity in ruling out T1b lesions. Endoscopic parameters of tumor size > 2 cm and ulceration were associated with deep invasion (T2 and beyond). The EUS parameter of notable para-esophageal lymph was associated with deep invasion, while on pathology, moderate to poorly differentiated cancers were associated with deep invasion. When known endoscopic signs of deep invasion were not present, EUS altered management from EMR/ESD to esophagectomy in < 5% of cases.

### **Research conclusions**

EUS is accurate in staging deep invasive cancers (T2 or beyond) and reliably excludes deep invasive cancers from T1 Lesions. EUS is limited in distinguishing between T1a and T1b lesions. We reinforced that tumor size > 2 cm, lymph node involvement and poor differentiation are endoscopic parameters associated with deep invasion (T2 or beyond). EUS infrequently changes the outcome in the patients based on prior endoscopic features. While EUS may improve accuracy, our data indicates that it rarely finds deep submucosal invasion to warrant esophagectomy over EMR/ESD when endoscopic features suggest a superficial cancer (T1a or more superficial).

### **Research perspectives**

Future directions should focus on expanding the external validity of this study through either a larger sample size or prospective cohort analysis. This study also warrants further investigation on modalities for detecting the subtlety of submucosal invasion, including applications of technologies such as photoacoustic or scanning laser acoustic microscopy or optical coherence tomography.

## FOOTNOTES

**Author contributions:** Kahlon S, Aamar A, and Urayama S designed the research study; Kahlon S and Aamar A

performed the research; Kahlon S and Butt Z conducted the statistical analysis; Kahlon S and Urayama S analyzed the data and wrote the manuscript; All authors have read and approve the final manuscript.

**Institutional review board statement:** The study was reviewed and approved by the UC Davis Institutional Review Board [(Approval No. 1816393-1)].

**Informed consent statement:** Patients were not required to give informed consent to the study because the analysis used anonymous data that were obtained from electronic medical record. A HIPPA waiver was provided by institutional IRB.

**Conflict-of-interest statement:** Shiro Urayama, MD has financial relationships with the following entities: Olympus America Inc., Noah Medical. Neither entity is directly involved in this work and no financial and/or material support was received for this research or the creation of this work. All other authors have no relationships relevant to the contents of this paper to disclose.

**Data sharing statement:** Technical appendix, statistical code, and dataset available from the corresponding author at [sakahlon@ucdavis.edu](mailto:sakahlon@ucdavis.edu). Participants consent was not obtained but the presented data are anonymized and risk of identification is low.

**STROBE statement:** The authors have read the STROBE Statement – checklist of items, and the manuscript was prepared and revised according to the STROBE Statement – checklist of items.

**Open-Access:** This article is an open-access article that was selected by an in-house editor and fully peer-reviewed by external reviewers. It is distributed in accordance with the Creative Commons Attribution NonCommercial (CC BY-NC 4.0) license, which permits others to distribute, remix, adapt, build upon this work non-commercially, and license their derivative works on different terms, provided the original work is properly cited and the use is non-commercial. See: <https://creativecommons.org/licenses/by-nc/4.0/>

**Country/Territory of origin:** United States

**ORCID number:** Sartajdeep Kahlon 0000-0002-4857-7672; Ali Aamar 0000-0003-3593-6987; Zeeshan Butt 0000-0001-9739-3506; Shiro Urayama 0000-0001-6574-3161.

**Corresponding Author's Membership in Professional Societies:** American Gastroenterological Association, No. 101013.

**S-Editor:** Liu JH

**L-Editor:** A

**P-Editor:** Fan JR

## REFERENCES

- 1 Napier KJ, Scheerer M, Misra S. Esophageal cancer: A Review of epidemiology, pathogenesis, staging workup and treatment modalities. *World J Gastrointest Oncol* 2014; **6**: 112-120 [PMID: 24834141 DOI: 10.4251/wjgo.v6.i5.112]
- 2 Siegel RL, Miller KD, Fuchs HE, Jemal A. Cancer statistics, 2022. *CA Cancer J Clin* 2022; **72**: 7-33 [PMID: 35020204 DOI: 10.3322/caac.21708]
- 3 Pohl H, Sirovich B, Welch HG. Esophageal adenocarcinoma incidence: are we reaching the peak? *Cancer Epidemiol Biomarkers Prev* 2010; **19**: 1468-1470 [PMID: 20501776 DOI: 10.1158/1055-9965.EPI-10-0012]
- 4 Ajani JA, D'Amico TA, Bentrem DJ, Chao J, Corvera C, Das P, Denlinger CS, Enzinger PC, Fanta P, Farjah F, Gerdes H, Gibson M, Glasgow RE, Hayman JA, Hochwald S, Hofstetter WL, Ilson DH, Jaroszewski D, Johung KL, Keswani RN, Kleinberg LR, Leong S, Ly QP, Matkowskyj KA, McNamara M, Mulcahy MF, Paluri RK, Park H, Perry KA, Pimiento J, Poultsides GA, Roses R, Strong VE, Wiesner G, Willett CG, Wright CD, McMillian NR, Pluchino LA. Esophageal and Esophagogastric Junction Cancers, Version 2.019, NCCN Clinical Practice Guidelines in Oncology. *J Natl Compr Canc Netw* 2019; **17**: 855-883 [PMID: 31319389 DOI: 10.6004/jnccn.2019.0033]
- 5 Othman MO, Lee JH, Wang K. Clinical Practice Update on the Utility of Endoscopic Submucosal Dissection in T1b Esophageal Cancer: Expert Review. *Clin Gastroenterol Hepatol* 2019; **17**: 2161-2166 [PMID: 31401148 DOI: 10.1016/j.cgh.2019.05.045]
- 6 Heidemann J, Schilling MK, Schmassmann A, Maurer CA, Büchler MW. Accuracy of endoscopic ultrasonography in preoperative staging of esophageal carcinoma. *Dig Surg* 2000; **17**: 219-224 [PMID: 10867453 DOI: 10.1159/000018838]
- 7 Hu Y, Fu JH, Rong TH, Xu GL, Li XD, Zhang PY, Yang H, Zhu ZH, Zhang SY. [Application of endoscopic ultrasonography to preoperative clinical staging of esophageal cancer]. *Ai Zheng* 2005; **24**: 1358-1362 [PMID: 16552963]
- 8 Mennigen R, Tuebergen D, Koehler G, Sauerland C, Senninger N, Bruewer M. Endoscopic ultrasound with conventional probe and miniprobe in preoperative staging of esophageal cancer. *J Gastrointest Surg* 2008; **12**: 256-262 [PMID: 17823841 DOI: 10.1007/s11605-007-0300-2]
- 9 Shimpi RA, George J, Jowell P, Gress FG. Staging of esophageal cancer by EUS: staging accuracy revisited. *Gastrointest Endosc* 2007; **66**: 475-482 [PMID: 17725937 DOI: 10.1016/j.gie.2007.03.1051]
- 10 DaVeé T, Ajani JA, Lee JH. Is endoscopic ultrasound examination necessary in the management of esophageal cancer?

- World J Gastroenterol* 2017; **23**: 751-762 [PMID: 28223720 DOI: 10.3748/wjg.v23.i5.751]
- 11 **Pouw RE**, Helderdom N, Alvarez Herrero L, ten Kate FJ, Visser M, Busch OR, van Berge Henegouwen MI, Krishnadath KK, Weusten BL, Fockens P, Bergman JJ. Do we still need EUS in the workup of patients with early esophageal neoplasia? A retrospective analysis of 131 cases. *Gastrointest Endosc* 2011; **73**: 662-668 [PMID: 21272876 DOI: 10.1016/j.gie.2010.10.046]
  - 12 **Young PE**, Gentry AB, Acosta RD, Greenwald BD, Riddle M. Endoscopic ultrasound does not accurately stage early adenocarcinoma or high-grade dysplasia of the esophagus. *Clin Gastroenterol Hepatol* 2010; **8**: 1037-1041 [PMID: 20831900 DOI: 10.1016/j.cgh.2010.08.020]
  - 13 **Gamboa AM**, Kim S, Force SD, Staley CA, Woods KE, Kooby DA, Maithe SK, Luke JA, Shaffer KM, Dacha S, Saba NF, Keilin SA, Cai Q, El-Rayes BF, Chen Z, Willingham FF. Treatment allocation in patients with early-stage esophageal adenocarcinoma: Prevalence and predictors of lymph node involvement. *Cancer* 2016; **122**: 2150-2157 [PMID: 27142247 DOI: 10.1002/ncr.30040]
  - 14 **Krill T**, Baliss M, Roark R, Sydor M, Samuel R, Zaibaq J, Guturu P, Parupudi S. Accuracy of endoscopic ultrasound in esophageal cancer staging. *J Thorac Dis* 2019; **11**: S1602-S1609 [PMID: 31489227 DOI: 10.21037/jtd.2019.06.50]
  - 15 **Ruan R**, Chen S, Tao Y, Yu J, Zhou D, Cui Z, Shen Q, Wang S. Retrospective analysis of predictive factors for lymph node metastasis in superficial esophageal squamous cell carcinoma. *Sci Rep* 2021; **11**: 16544 [PMID: 34400710 DOI: 10.1038/s41598-021-96088-y]
  - 16 **Rice TW**, Patil DT, Blackstone EH. 8th edition AJCC/UICC staging of cancers of the esophagus and esophagogastric junction: application to clinical practice. *Ann Cardiothorac Surg* 2017; **6**: 119-130 [PMID: 28447000 DOI: 10.21037/acs.2017.03.14]
  - 17 **Zhang D**, Zheng Y, Wang Z, Huang Q, Cao X, Wang F, Liu S. Comparison of the 7th and proposed 8th editions of the AJCC/UICC TNM staging system for esophageal squamous cell carcinoma underwent radical surgery. *Eur J Surg Oncol* 2017; **43**: 1949-1955 [PMID: 28716377 DOI: 10.1016/j.ejso.2017.06.005]
  - 18 **Catalano MF**, Sivak MV Jr, Rice T, Gragg LA, Van Dam J. Endosonographic features predictive of lymph node metastasis. *Gastrointest Endosc* 1994; **40**: 442-446 [PMID: 7926534 DOI: 10.1016/s0016-5107(94)70206-3]
  - 19 **Saunders HS**, Wolfman NT, Ott DJ. Esophageal cancer. Radiologic staging. *Radiol Clin North Am* 1997; **35**: 281-294 [PMID: 9087204 DOI: 10.1016/S0033-8389(22)00708-4]
  - 20 **Dhupar R**, Rice RD, Correa AM, Weston BR, Bhutani MS, Maru DM, Betancourt SL, Rice DC, Swisher SG, Hofstetter WL. Endoscopic Ultrasound Estimates for Tumor Depth at the Gastroesophageal Junction Are Inaccurate: Implications for the Liberal Use of Endoscopic Resection. *Ann Thorac Surg* 2015; **100**: 1812-1816 [PMID: 26233274 DOI: 10.1016/j.athoracsur.2015.05.038]
  - 21 **Thosani N**, Singh H, Kapadia A, Ochi N, Lee JH, Ajani J, Swisher SG, Hofstetter WL, Guha S, Bhutani MS. Diagnostic accuracy of EUS in differentiating mucosal versus submucosal invasion of superficial esophageal cancers: a systematic review and meta-analysis. *Gastrointest Endosc* 2012; **75**: 242-253 [PMID: 22115605 DOI: 10.1016/j.gie.2011.09.016]
  - 22 **Thakkar S**, Kaul V. Endoscopic Ultrasound Staging of Esophageal Cancer. *Gastroenterol Hepatol (N Y)* 2020; **16**: 14-20 [PMID: 33867884]
  - 23 **Badreddine RJ**, Prasad GA, Lewis JT, Lutzke LS, Borkenhagen LS, Dunagan KT, Wang KK. Depth of submucosal invasion does not predict lymph node metastasis and survival of patients with esophageal carcinoma. *Clin Gastroenterol Hepatol* 2010; **8**: 248-253 [PMID: 19948247 DOI: 10.1016/j.cgh.2009.11.016]
  - 24 **Zhang K**, Qiu J, Yang F, Wang J, Zhao X, Wei Z, Ge N, Chen Y, Sun S. Photoacoustic endoscopy and EUS: Shaking the future of multimodal endoscopy. *Endosc Ultrasound* 2022; **11**: 1-3 [PMID: 35229746 DOI: 10.4103/EUS-D-22-00011]
  - 25 **Tsai TH**, Fujimoto JG, Mashimo H. Endoscopic Optical Coherence Tomography for Clinical Gastroenterology. *Diagnostics (Basel)* 2014; **4**: 57-93 [PMID: 26852678 DOI: 10.3390/diagnostics4020057]



Published by **Baishideng Publishing Group Inc**  
7041 Koll Center Parkway, Suite 160, Pleasanton, CA 94566, USA  
**Telephone:** +1-925-3991568  
**E-mail:** [bpgoffice@wjgnet.com](mailto:bpgoffice@wjgnet.com)  
**Help Desk:** <https://www.f6publishing.com/helpdesk>  
<https://www.wjgnet.com>

