

UCLA

UCLA Previously Published Works

Title

Use of an aortic balloon to achieve uterine conservation in a case of placenta accreta spectrum: A case report.

Permalink

<https://escholarship.org/uc/item/8d91f058>

Authors

Bartels, Helena C
Brophy, David P
Moriarty, John M
[et al.](#)


Publication Date

2023-03-01

DOI

10.1016/j.crwh.2023.e00497

Peer reviewed



Use of an aortic balloon to achieve uterine conservation in a case of placenta accreta spectrum: A case report

Helena C. Bartels^a, David P. Brophy^b, John M. Moriarty^c, Tony Geoghegan^d, Gabriela McMahon^e, Jennifer Donnelly^{e,f}, Claire Thompson^g, Donal J. Brennan^{a,g,*}

^a Dept of UCD Obstetrics and Gynaecology, School of Medicine, University College Dublin, National Maternity Hospital, Holles Street, Dublin 2, Ireland

^b Department of Radiology, St Vincent's University Hospital, Dublin, Ireland

^c Division of Interventional Radiology, Department of Radiological Sciences David Geffen School of Medicine at UCLA, Los Angeles, CA, United States of America

^d Department of Radiology, Mater Misericordiae University Hospital, Dublin, Ireland

^e Department of Obstetrics and Gynaecology, Rotunda Hospital, Dublin, Ireland

^f UCD School of Medicine, Mater Misericordiae University Hospital Dublin, Ireland

^g University College Dublin Gynaecological Oncology Group (UCD-GOG), UCD School of Medicine, Mater Misericordiae University Hospital Dublin, Ireland

ARTICLE INFO

Keywords:

Intravascular ultrasound
Aortic balloon
Placenta accreta spectrum
Case report

ABSTRACT

Placenta accreta spectrum (PAS) is a rare complication of pregnancy associated with a high risk of massive haemorrhage and caesarean hysterectomy. This is a case report of abdominal aortic balloon occlusion, using intravascular ultrasound, to achieve uterine conservation in a case of severe PAS. The patient was a 34-year-old woman, G2P1, with one prior caesarean section. Antenatal imaging, consisting of transabdominal and transvaginal ultrasound, and magnetic resonance imaging, showed features of PAS. The risk of caesarean hysterectomy with PAS was explained, but the patient declared a desire to retain fertility. Following multi-disciplinary discussion, it was considered appropriate to attempt uterine conservation using en-bloc myometrial and placental resection. An elective caesarean delivery was performed at 36 weeks of gestation. An aortic balloon was inserted prior to surgery using intravascular ultrasound, which allowed for radiation-free, point-of-surgery, accurate balloon sizing, by measuring the aortic diameter, and correct placement of the balloon in the abdominal aorta below the renal vessels. Intraoperative findings confirmed PAS, and a myometrial resection was performed. There were no intraoperative complications. Estimated blood loss was 1000 mL and the patient had an uncomplicated postoperative course. This case demonstrates how the use of an intravascular intraoperative aortic balloon can facilitate uterine conservation in a case of severe PAS.

1. Introduction

Placenta accreta spectrum (PAS) is a term used to describe abnormal trophoblastic invasion into the myometrium and sometimes to or beyond the uterine serosa [1]. The condition is associated with a significant risk of massive haemorrhage and a high rate of patients undergoing caesarean hysterectomy [2–4]. More recently, uterus-preserving techniques, such as en-bloc myometrial and placental resection, have been described as an alternative to caesarean hysterectomy [5]. Several studies have reported an increase in the rate of uterine conservation when intra-aortic balloon occlusion is performed for PAS

cases [6–9]. Intra-aortic balloon occlusion has gained popularity for PAS cases, possibly as a result of several prospective and retrospective studies demonstrating that internal iliac occlusion does not reduce blood loss, transfusion requirements or uterine conservation rates in PAS [10–12]. This may be a result of the rich anastomosis in the gravid pelvis with collateral circulations, meaning occlusion at the level of the internal iliac arteries is unlikely to create significant haemostasis. Moving proximally, occlusion of the infra-renal aorta may be a more suitable approach to reduced pulse pressures in collateral pelvic circulations. Two recent meta-analyses demonstrated that aortic balloon occlusion reduced intraoperative blood loss, transfusion requirements and the

Abbreviations: PAS, Placenta accreta spectrum; FIGO, The International Federation of Gynaecology and Obstetrics; MDT, Multi-disciplinary team; IVUS, Intravascular ultrasound.

* Corresponding author at: University College Dublin Gynaecological Oncology Group (UCD-GOG), UCD School of Medicine, Mater Misericordiae University Hospital Dublin, Ireland.

E-mail address: donal.brennan@ucd.ie (D.J. Brennan).

<https://doi.org/10.1016/j.crwh.2023.e00497>

Received 3 March 2023; Received in revised form 12 March 2023; Accepted 13 March 2023

Available online 16 March 2023

2214-9112/© 2023 Published by Elsevier B.V. This is an open access article under the CC BY-NC-ND license (<http://creativecommons.org/licenses/by-nc-nd/4.0/>).

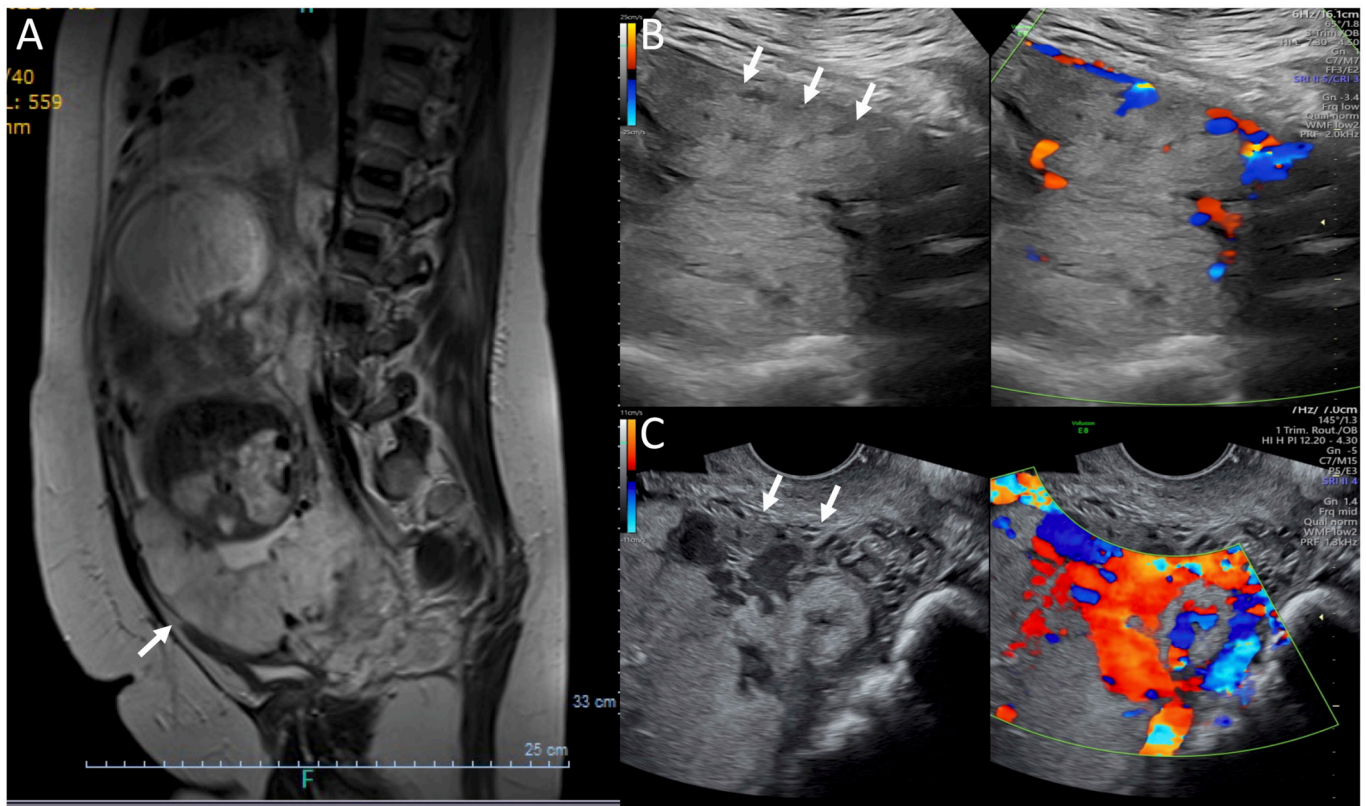


Fig. 1. Antenatal imaging.

Ultrasound and MRI images

A: MRI at 28+3 weeks gestation. Complete anterior placenta previa. Minimal heterogeneity seen throughout the placenta. Area of thinned myometrium anteriorly, approx. 3cm above internal os (arrows). B: 29+6 weeks gestation. Transabdominal ultrasound demonstrating loss of retroplacental clear zone and thinned myometrium (arrows). C: 31+6 weeks gestation. Transvaginal ultrasound shows thinned myometrium (arrows) and multiple placental lacunae.

Left image with with colour Doppler applied shows vascularity of the placental lacunae.

need for caesarean hysterectomy in PAS with low procedure-related complication rates, ranging from 1.7% to 2.2% [6,7]. Widespread adoption of this technique has been limited by the need for access to interventional radiology expertise, equipment and angiography suites, along with ionizing radiation exposure to staff, patient and fetus [13]. Here, a safe and practical technique is presented using intravascular ultrasound (IVUS) for aortic balloon insertion to facilitate uterine conservation in a case of severe PAS.

2. Case Presentation

2.1. Antenatal Care

This is a case of a 34-year-old woman, G2P1, with a body mass index of 33 kg/m², with no significant medical or family history. She had had one prior pregnancy, which was uncomplicated and resulted in a live birth at 39 weeks of gestation by elective caesarean section for breech presentation. The index pregnancy was a planned, spontaneous conception with no early pregnancy complications. A 20-week anatomy ultrasound demonstrated no fetal anomalies; however, the placenta was noted to be low lying and she was referred for fetal-medicine opinion to rule out PAS, given her history of a prior caesarean delivery.

Subsequent ultrasound scans at 24 and 26 weeks of gestation found an anterior placenta previa completely covering the internal os. Features consistent with PAS were seen on transabdominal and transvaginal ultrasound, including loss of the retroplacental clear zone and thinning of the myometrium, multiple vascular placental lacunae, and utero-vesical hypervascularity [14]. The diagnosis and potential implications of PAS, including caesarean hysterectomy, were explained to the woman and

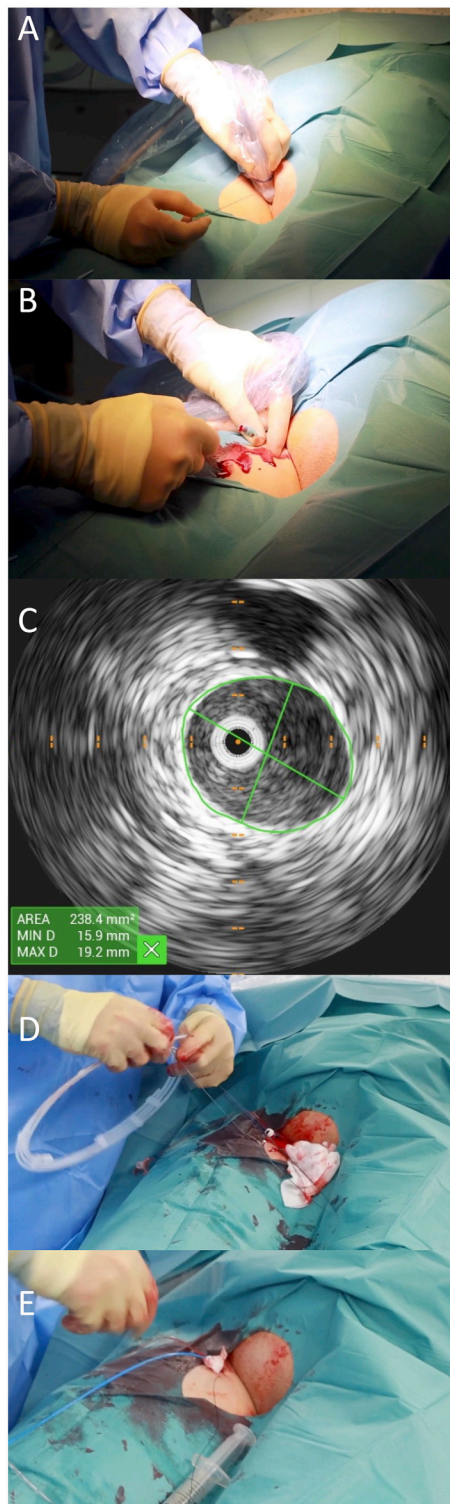
her partner, who expressed a strong desire to explore fertility-preserving techniques. The case was referred for discussion at the PAS multidisciplinary team meeting (MDT) [15]. A magnetic resonance scan performed at 28 weeks of gestation demonstrated a complete placenta previa, thinning of the myometrium anteriorly and dark T2 bands (Fig. 1a). There was minimal heterogeneity of the placental signal and it appeared the distal end defect was >2 cm away from the internal cervical os.

Further transabdominal and transvaginal ultrasound at 29 + 6 (Fig. 1b) and 31 + 6 weeks of gestation (Fig. 1c) found an anterior placenta previa with multiple vascular, placental lacunae. There was loss of the retroplacental clear zone and a very thinned myometrium in areas, although the defect appeared limited to a 5 cm area. The fetus was appropriate for gestational age with an estimated weight of 2023 g (65th percentile) at 31 + 6.

Following MDT discussion it was considered safe to attempt uterine conservation in this case due to the relatively focal defect and the presence of normal myometrium in the lower uterine segment which would facilitate reconstruction of the uterus. A recommendation to use an aortic balloon to facilitate this approach and reduce potential blood loss was also made. The woman was counselled on the risk of uterine conservation being unsuccessful, such as in the event of massive haemorrhage, and the possibility of requiring caesarean hysterectomy.

2.2. Aortic Balloon and Delivery

An elective delivery was performed at 36 + 1 weeks of gestation under general anaesthesia. A combined-spinal epidural was inserted for post-operative pain relief.



(caption on next column)

Fig. 2 summarizes the steps for insertion of the aortic balloon. The aortic balloon was inserted in a standard operating theatre, in the supine position. The IVUS device (Volcano PV 038, Phillips, NJ) was inserted via standard seldinger technique through a single 8 French common femoral arterial sheath (**Fig. 2a**). Once the balloon was sited, a pulse oximeter was placed on the left great toe, and the woman was placed in dorsal lithotomy position, cleaned and draped. A midline laparotomy

Fig. 2. Steps for aortic balloon insertion.

1. Supine position. Using an ultrasound guided micropuncture, access is made into the right common femoral at the level of the femoral head using a single wall puncture technique (**A**). An 8Fr sheath is then positioned. A guide wire is threaded through the cannula (**B**).
2. Intravascular ultrasound (IVUS) (PV035 Volcano, Phillips Volcano, San Diego, CA) is used to localise the level of the lowest renal artery, size the infrarenal aorta diameter (**C**) and measure the distance from the fully inserted sheath hub to the most inferior renal artery (video). A valvuloplasty balloon is 1:1 sized to the diameter of the infrarenal aorta. The length of the balloon catheter to be inserted is measured with distance, to allow maximum insertion length while avoiding renal artery occlusion. The length is marked on the catheter shaft with a Steri-Strip.
3. Low pressure tubing is connected and passed above shoulder level for ease of access of the anaesthesiologist/interventionalist out of the way of the operators (**D**). The volume of saline required to expand the balloon to nominal size is then measured, the balloon deflated, and the sheath and occlusion balloon affixed to the skin with sutures and ON Tegaderm (**E**). Fetal well-being was checked by auscultating the fetal heart after the balloon was secured in place.
4. A pulse oximetry is placed onto either the right or left great toe. After delivery of the baby, once the balloon is inflated, pulse oximetry flatline should be observed within seconds. After balloon deflation, a return to normal baseline oximetry should be observed within seconds.
5. At the end of the procedure, a biodegradable closure device is utilised for haemostasis after wire removal of the IVUS and sheath.

was performed, and intraoperative findings confirmed PAS (**Fig. 3a**). Clinical findings were consistent with FIGO grade 3 [1]; the lower uterine segment was bulging and distended in an area measuring 5 cm × 3 cm, with multiple large dilated vessels, and minimal overlying serosa (**Fig. 3a**). After careful bladder dissection, >2 cm of normal-appearing myometrium was present between the most inferior margin of the defect and the cervix, consistent with pre-operative imaging findings. A transverse uterine incision was made superior the defect. A female infant weighing 2320 g was delivered, with Apgar scores of 2 at 1, and 8 at 5 min of life.

After delivery, a test balloon inflation was performed. Within seconds of inflation, flat-line oximetry was observed on the pulse oximeter, confirming aortic occlusion. A myometrial resection was completed, excising the area of abnormal placentation, and the uterus was reconstructed in two layers using interrupted 0 vicryl sutures. Intraoperatively, the aortic balloon was inflated with saline to the pre-measured nominal aortic occlusive diameter at the discretion of the operating surgeon. Balloon inflation was limited to times when anticipated blood loss was highest. To minimize lower-extremity ischemic times, maximum inflation times of 10–15 min were applied with intermittent deflation for 1–2 min and observation of normal pulse oximetry baseline pattern. The aortic balloon was inflated three times (total 34 min) during the procedure. Once the surgery was completed, the IVUS catheter and sheath were removed, and arterial closure performed using a bioabsorbable closure device (Angio-Seal®VIP) allowing for immediate mobilization.

The estimated blood loss was 1000 mL, and the woman was admitted to a high-dependency unit for 24 h. She had an uncomplicated post-operative course. Mother and infant were discharged home together on day 5 post-operatively. Histopathology was consistent with FIGO grade 3a [1], with the extent of myometrial invasion >75% and myometrium focally thinned to 1 mm (**Fig. 3b**).

3. Discussion

This is a case of FIGO grade 3 PAS where use of an aortic balloon facilitated uterine conservation. The delivery was carefully planned with a specialist PAS MDT. The described technique of aortic balloon occlusion using IVUS has significant benefits, in terms of both patient safety and logistical considerations.

The technique presented here has numerous advantages over other

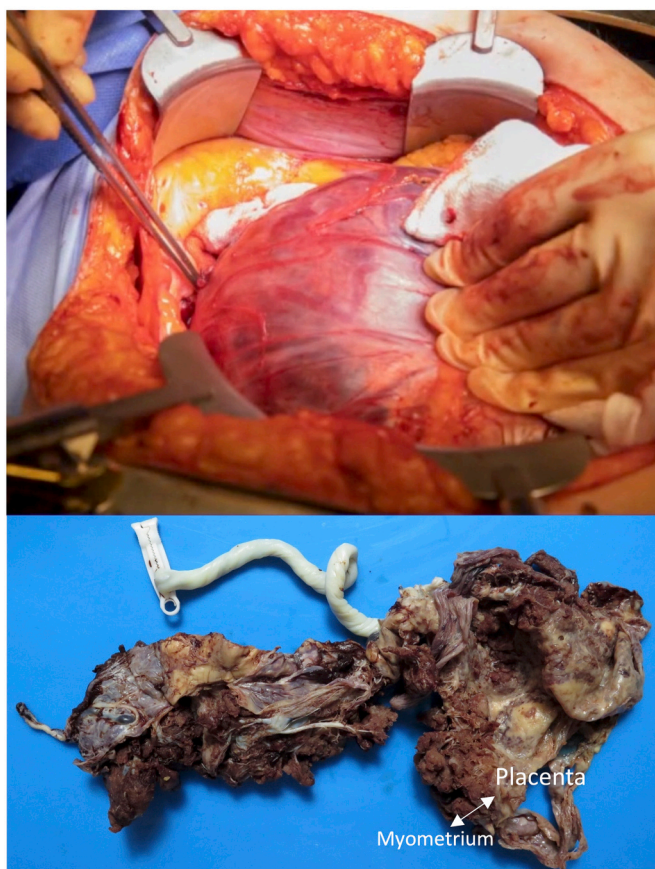


Fig. 3. Intraoperative findings and histopathology.

A: Anterior view of the uterus with placenta in situ following bladder dissection. Intraoperative finding of FIGO grade 3 PAS; the lower uterine segment is bulging and distended, with very thinned uterine serosa remaining over the area of the defect. There was no breach of the uterine serosa or other organ involvement. There was >2cm of normal myometrium present between the internal cervical os and the defect.

B: Gross specimen of myometrial resection with attached placenta. The final histopathological classification was PAS FIGO grade 3A. The extent of myometrial invasion was >75% (arrow), with the myometrium focally thinned to 1mm. There was no invasion into uterine serosa

On microscopy, abnormal implantation of the chorionic villi onto the superficial myometrium without an intervening decidual layer was seen.

approaches. The procedure can be performed in a standard operating theatre, which eliminates the need for multiple patient transfers between the interventional radiology suite and the operating theatre or use of highly utilized and under-available hybrid operating rooms, allowing for resource optimization. Balloon placement is confirmed using IVUS; hence, unlike with other reported techniques [13,16], there is no requirement for further imaging to confirm correct placement which would result in potential radiation exposure for the patient, fetus and staff. The aortic balloon can be inserted via a single, femoral access site and no contrast is used.

Aortic balloon occlusion in PAS has been shown to reduce blood loss, transfusion requirements and increase rates of uterine conservation [7,16,17]. In contrast, internal iliac artery occlusion typically requires placement in an interventional radiology suite due to the need for selective arterial catheterization and bilateral femoral artery access; it also presents radiation burden to the woman and fetus [18]; and perhaps most importantly, multiple randomized control trials have shown no benefit in reducing maternal morbidity [10–12].

PAS is associated with a high rate of caesarean hysterectomy [2,4,19]. While this may be the safest approach in some cases, uterus-

conserving approaches have several benefits. En-bloc myometrial and placental resection may be associated with a lower intraoperative morbidity, including reduced blood loss [20,21], blood transfusion requirements and the need for vascular interventions [5]. Furthermore, as in the case presented here, women may desire further pregnancies and therefore hysterectomy is an undesirable option. Uterine conservation does not appear to increase the risk of future PAS in subsequent pregnancies; a case series of over 200 women with PAS managed with myometrial resection who had a subsequent pregnancy reported that 90% of them delivered after 37 weeks and no recurrences of PAS [22]. The potential emotional and psychosexual consequences of undergoing caesarean hysterectomy for PAS should not be underestimated, with some women reporting long-lasting psychological sequelae, feelings of loss of womanhood, shame and stigma [23]. Therefore alternative treatment options to caesarean hysterectomy should be explored in suitable cases. Where this approach is planned, women should be counselled on the risk of requiring caesarean hysterectomy.

In summary, the described technique for aortic balloon inclusion is a safe and logistically practical approach for PAS cases. Use of this approach facilitated uterine conservation in a case of severe PAS with moderate blood loss and no intraoperative complications. Uterine conservation is challenging in women with PAS and when desired and considered a possibility, prophylactic aortic balloon occlusion should be considered to optimize the chances of success. This approach can be considered in select cases under the care of a multi-disciplinary team.

Contributors

Helena C Bartels contributed to patient care, conception of the case report, undertaking the literature review and revising the article critically for important intellectual content, acquiring and interpreting the data, and drafting the manuscript.

David P Brophy contributed to conception of the case report, acquiring and interpreting the data, drafting the manuscript, and preparation of figures.

John M Moriarty contributed to patient care, conception of the case report, acquiring and interpreting the data, and reviewing the manuscript.

Tony Geoghegan contributed to patient care, drafting the manuscript, preparation of figures, and manuscript review.

Gabriela McMahon contributed to patient care, conception of the case report, acquiring and interpreting the data, and preparation of figures.

Jennifer Donnelly contributed to patient care, conception of the case report, acquiring and interpreting the data, reviewing the manuscript, and preparation of figures.

Claire Thompson contributed to patient care, acquiring and interpreting the data, reviewing the manuscript, and preparation of figures.

Donal J Brennan contributed to patient care, conception of the case report, acquiring and interpreting the data, drafting the manuscript, and preparation of figures.

All authors approved the final submitted manuscript.

Funding

This work did not receive any specific grant from funding agencies in the public, commercial, or not-for-profit sectors.

Patient consent

Informed and written consent was obtained from the patient to participate in a prospective database (Ethics REF: RAG 2019-10) and consent was obtained for publication of associated images and videos.

Provenance and peer review

This article was not commissioned. Peer review was directed by Professor Margaret Rees independently of Donal Brennan, an author and editorial board member of *Case Reports in Women's Health*, who was blinded to the process.

Conflict of interest statement

The authors declare that they have no conflict of interest regarding the publication of this case report.

References

- [1] E. Jauniaux, D. Ayres-de-Campos, J. Langhoff-Roos, K.A. Fox, S. Collins, FIGO classification for the clinical diagnosis of placenta accreta spectrum disorders, *Int. J. Gynaecol. Obstetr. Official Organ Int. Fed. Gynaecol. Obstetr.* 146 (1) (2019) 20–24.
- [2] A.A.F.K. Shamshirsaz, H. Erfani, S.L. Clark, B. Salmanian, B.W. Baker, M. Coburn, A.A. Shamshirsaz, Z.H. Bateni, J. Espinoza, A.A. Nassr, E.J. Popek, S.K. Hui, J. Teruya, C.S. Tung, J.A. Jones, M. Rac, G.A. Dildy, M.A. Belfort, Multidisciplinary team learning in the management of the morbidly adherent placenta: outcome improvements over time, *Am. J. Obstet. Gynecol.* 216 (6) (2017) 612.e1–612.e5.
- [3] H.C. Bartels, A.C. Rogers, D. O'Brien, R. McVey, J. Walsh, D.J. Brennan, Association of implementing a multidisciplinary team approach in the management of morbidly adherent placenta with maternal morbidity and mortality, *Obstet. Gynecol.* 132 (5) (2018) 1167–1176.
- [4] M.A. Scaglione, A.A. Allshouse, D.R. Canfield, H.D. McLaughlin, A.M. Bruno, I. A. Hammad, et al., Prophylactic ureteral stent placement and urinary injury during hysterectomy for placenta accreta spectrum, *Obstet. Gynecol.* 140 (5) (2022) 806–811.
- [5] A.J. Nieto-Calvache, J.M. Palacios-Jaraquemada, R. Aryananda, N. Basanta, R. Aguilera, J.P. Benavides, et al., How to perform the one-step conservative surgery for placenta accreta spectrum move by move, *Am. J. Obstet. Gynecol. MFM.* 5 (2) (2023), 100802.
- [6] L. Chen, X. Wang, H. Wang, Q. Li, N. Shan, H. Qi, Clinical evaluation of prophylactic abdominal aortic balloon occlusion in patients with placenta accreta: a systematic review and meta-analysis, *BMC Pregnancy Childbirth.* 19 (1) (2019) 30.
- [7] Q. He, Y.L. Li, M.J. Zhu, X.C. Peng, X.Y. Liu, H.L. Hou, et al., Prophylactic abdominal aortic balloon occlusion in patients with pernicious placenta previa during cesarean section: a systematic review and meta-analysis from randomized controlled trials, *Arch. Gynecol. Obstet.* 300 (5) (2019) 1131–1145.
- [8] M. Chen, L. Xie, Clinical evaluation of balloon occlusion of the lower abdominal aorta in patients with placenta previa and previous cesarean section: a retrospective study on 43 cases, *Int. J. Surg.* 34 (2016) 6–9.
- [9] X. Duan, P. Chen, X. Han, Y. Wang, Z. Chen, X. Zhang, et al., Intermittent aortic balloon occlusion combined with cesarean section for the treatment of patients with placenta previa complicated by placenta accreta: a retrospective study, *J. Obstet. Gynaecol. Res.* 44 (9) (2018) 1752–1760.
- [10] A.M. Hussein, D.M.R. Dakhly, A.N. Raslan, A. Kamel, A. Abdel Hafeez, M. Moussa, et al., The role of prophylactic internal iliac artery ligation in abnormally invasive placenta undergoing caesarean hysterectomy: a randomized control trial, *J. Matern. Fetal Neonat. Med. Off. J. Eur. Assoc. Perinat. Med. Fed. Asia Ocean. Perinat. Soc. Int. Soc. Perinat. Obstet.* 32 (20) (2019) 3386–3392.
- [11] R. Salim, A. Chulski, S. Romano, G. Garmi, M. Rudin, E. Shalev, Precesarean prophylactic balloon catheters for suspected placenta accreta: a randomized controlled trial, *Obstet. Gynecol.* 126 (5) (2015) 1022–1028.
- [12] M. Chen, X. Liu, Y. You, X. Wang, T. Li, H. Luo, et al., Internal iliac artery balloon occlusion for placenta previa and suspected placenta accreta: a randomized controlled trial, *Obstet. Gynecol.* 135 (5) (2020) 1112–1119.
- [13] A.J. Nieto-Calvache, L.F. Salas, E.J. Duran, S.O. Benavides, C.A. Ordoñez-Delgado, F. Rodriguez-Holguin, Estimation of fetal radiation absorbed dose during the prophylactic use of aortic occlusion balloon for abnormally invasive placenta, *J. Matern. Fetal Neonat. Med. Off. J. Eur. Assoc. Perinat. Med. Fed. Asia Ocean. Perinat. Soc. Int. Soc. Perinat. Obstet.* 34 (19) (2021) 3181–3186.
- [14] S.L. Collins, A. Ashcroft, T. Braun, P. Calda, J. Langhoff-Roos, O. Morel, et al., Proposal for standardized ultrasound descriptors of abnormally invasive placenta (AIP), *Ultrasound Obstetr. Gynecol. Off. J. Int. Soc. Ultrasound Obstetr. Gynecol.* 47 (3) (2016) 271–275.
- [15] H.C. Bartels, K.M. Mulligan, S. Craven, A.C. Rogers, S. Higgins, D.J. O'Brien, et al., Maternal morbidity in placenta accreta spectrum following introduction of a multidisciplinary service compared to standard care: an Irish perspective, *Ir. J. Med. Sci.* 190 (4) (2021) 1451–1457.
- [16] W. Sun, S. Duan, G. Xin, J. Xiao, F. Hong, H. Hong, et al., Safety and efficacy of preoperative abdominal aortic balloon occlusion in placenta increta and/or percreta, *J. Surg. Res.* 222 (2018) 75–84.
- [17] M. Dai, F. Zhang, K. Li, G. Jin, Y. Chen, X. Zhang, The effect of prophylactic balloon occlusion in patients with placenta accreta spectrum: a Bayesian network meta-analysis, *Eur. Radiol.* 32 (5) (2022) 3297–3308.
- [18] Y. Ono, Y. Murayama, S. Era, S. Matsunaga, T. Nagai, H. Osada, et al., Study of the utility and problems of common iliac artery balloon occlusion for placenta previa with accreta, *J. Obstet. Gynaecol. Res.* 44 (3) (2018) 456–462.
- [19] D.J. Brennan, B. Schulze, N. Chetty, A. Crandon, S.G. Petersen, G. Gardener, et al., Surgical management of abnormally invasive placenta: a retrospective cohort study demonstrating the benefits of a standardized operative approach, *Acta Obstet. Gynecol. Scand.* 94 (12) (2015) 1380–1386.
- [20] S.H. Mohamed Siraj, K.H. Tan, A.M. Wright, Conservative surgical approach towards placenta accreta spectrum disorders for uterine preservation, *BMC Pregnancy Childbirth.* 23 (1) (2023) 28.
- [21] J.M. Palacios-Jaraquemada, A. Fiorillo, J. Hamer, M. Martínez, C. Bruno, Placenta accreta spectrum: a hysterectomy can be prevented in almost 80% of cases using a resective-reconstructive technique, *J. Matern. Fetal Neonat. Med. Off. J. Eur. Assoc. Perinat. Med. Fed. Asia Ocean. Perinat. Soc. Int. Soc. Perinat. Obstet.* 35 (2) (2022) 275–282.
- [22] J.M. Palacios-Jaraquemada, N. Basanta, C. Labrousse, M. Martínez, Pregnancy outcome in women with prior placenta accreta spectrum disorders treated with conservative-reconstructive surgery: analysis of 202 cases, *J. Matern. Fetal Neonat. Med. Off. J. Eur. Assoc. Perinat. Med. Fed. Asia Ocean. Perinat. Soc. Int. Soc. Perinat. Obstet.* 35 (25) (2022) 6297–6301.
- [23] H.C. Bartels, A. Horsch, N. Cooney, D.J. Brennan, J.G. Lalor, Living beyond placenta accreta spectrum: parent's experience of the postnatal journey and recommendations for an integrated care pathway, *BMC Pregnancy Childbirth.* 22 (1) (2022) 397.