

## Accelerated cerebral white matter development in preterm infants: A voxel-based morphometry study with diffusion tensor MR imaging

Mónica Giménez,<sup>a,b,\*</sup> Maria J. Miranda,<sup>c,d</sup> A. Peter Born,<sup>c</sup> Zoltan Nagy,<sup>e</sup>  
Egill Rostrup,<sup>c</sup> and Terry L. Jernigan<sup>c,f</sup>

<sup>a</sup>Department of Psychiatry and Clinical Psychobiology, Faculty of Medicine, University of Barcelona, C/ Casanova 143, 08036, Barcelona, Spain

<sup>b</sup>Institut d'Investigacions Biomèdiques August Pi i Sunyer (IDIBAPS), Hospital Clinic, Faculty of Medicine, University of Barcelona, Spain

<sup>c</sup>Danish Research Centre for Magnetic Resonance, Copenhagen University Hospital Hvidovre, Dep. 340, Kettegaard Alle 30, DK-2650 Hvidovre, Denmark

<sup>d</sup>Department of Pediatrics, Copenhagen University Hospital Hvidovre, Kettegaard Alle 30, DK-2650 Hvidovre, Denmark

<sup>e</sup>Department of Woman and Child Health, Neonatal Unit & Department of Medical Physics, MRI Unit, Karolinska Institute, 171 76 Stockholm, Sweden

<sup>f</sup>Laboratory of Cognitive Imaging, University of California, San Diego, La Jolla, CA 92093-0949 USA

Received 28 October 2007; revised 11 February 2008; accepted 12 February 2008  
Available online 4 March 2008

**Twenty-seven preterm infants were compared to 10 full-term infants at term equivalent age using a voxel-based analysis of diffusion tensor imaging of the brain. Preterm infants exhibited higher fractional anisotropy values, which may suggest accelerated maturation, in the location of the sagittal stratum. While some earlier findings in preterm infants have suggested developmental delays, the results of this study are more consistent with accelerated white matter development, possibly as a result of increased sensorimotor stimulation in the extrauterine environment. These results are the first to suggest that the increased intensity of stimulation associated with preterm birth may advance the process of white matter maturation in the human brain. Questions remain about whether these findings reflect acceleration of the process of white matter maturation generally, or localized alterations induced specifically by activity in affected pathways.**

© 2008 Elsevier Inc. All rights reserved.

### Introduction

Functional development and organization in the brain are facilitated by appropriate stimulation. This has been firmly established for the visual system, both in animal models and in man (Hubel and Wiesel, 1998). Before term, the normal physiological environment is the uterus, where the baby is relatively well protected from external stimuli. Instead, the premature infant is exposed to profoundly different acoustic, visual, and somatosensory stimuli. So far, it has not been established what effect this early stimulation might have on

the developing human brain. It is possible that maturation is actually accelerated by the extrauterine environment. At the same time, the preterm infant is at risk of serious insults to the brain: from maternal infections, high vulnerability to inflammatory mechanisms (Dammann and Leviton, 1997; Dammann et al., 2002; du Plessis and Volpe, 2002), and oxidative processes (Haynes et al., 2005), as well as other perinatal complications (Volpe, 2001). When studying groups of typical preterm infants, the effects of prematurity per se may be masked by those associated with neurological risk factors.

Most previous studies of preterm infants have highlighted the increased neurological risks associated with prematurity. MR studies in recent years have linked premature birth to white matter (WM) abnormalities or myelination delays (Maalouf et al., 1999; Miller et al., 2002; Arzoumanian et al., 2003), and to abnormalities of gray matter development (Inder et al., 2005). These effects have sometimes been observed as early as term-equivalent age.

*In vivo* diffusion tensor imaging (DTI) may be used to assess the integrity of WM tracts, as reflected by the apparent diffusion coefficient (ADC) and fractional anisotropy (FA) (Basser et al., 1994; for recent review, see Mori and Zhang, 2006). Mature WM tracts exhibit high anisotropy values and increasing anisotropy has been linked to myelination and brain maturation (Miller et al., 2002; Mukherjee et al., 2002; Schneider et al., 2004; Berman et al., 2005; Drobyshevsky et al., 2005) (for reviews, see Hüppi and Dubois, 2006; Mukherjee and McKinstry, 2006). In healthy preterm infants, FA increase is observed in motor and sensory tracts with increasing postnatal age (PNA, i.e., age in weeks since birth). Commissural tracts and deep projections seem to mature earlier than subcortical and associative pathways (Partridge et al., 2004). Comparison of FA values is therefore useful in demonstrating differences in brain structural development between groups.

The effect of preterm birth, per se, on the rate of WM maturation has not yet been studied systematically. A recent long-term study of a group of preterm infants showed that an individualized develop-

\* Corresponding author. Department of Psychiatry and Clinical Psychobiology, University of Barcelona (IDIBAPS), Casanova 143, Postal Code: 08036 Barcelona, Spain. Fax: +34 93 403 52 94.

E-mail address: monicaaab@hotmail.com (M. Giménez).

Available online on ScienceDirect (www.sciencedirect.com).

mental care and assessment program that emphasized the behavioral individuality of each infant and provided “age appropriate stimuli” seemed to promote brain maturation (Als et al., 2004). The authors reported higher relative increase in diffusion anisotropy in specific brain areas (using a region of interest [ROI] analysis) in a preterm subgroup exposed to the program compared to preterm infants with no individual developmental care program. Other studies have demonstrated positive behavioral effects of sensory experiences in the neonatal intensive care unit environment (Westrup et al., 2000; Kleberg et al., 2002). These studies suggest that the extrauterine environment might in some cases stimulate development in preterm infants; however earlier authors have concluded that postnatal stimulation in preterm infants is generally deleterious (Duffy et al., 1990).

Only one previous study compared anisotropy in premature and full-term infants at the same post-conceptual age. In this study, decreased anisotropy was found in the internal capsule (IC), indicating delayed maturation in premature infants at term (Hüppi et al., 1998). Earlier studies used a ROI approach, where anisotropy was measured in a limited number of WM structures, often manually traced by one or more observers. Voxel-based morphometry (VBM) (Ashburner and Friston, 2000) is a technique for comparison of volumes between groups without the need to define regions of interest. VBM has recently been applied to data in adults and older children (Buchel et al., 2004; Leung et al., 2004; Park et al., 2004). The present study is the first to apply VBM to DTI data from infants. To accomplish this, we optimized the approach for normalizing infant brains to the same stereotactic space. The aim was to detect possible differences in FA between healthy preterm infants and healthy full-term controls at term-equivalent age.

## Subjects and methods

### Subjects

The sample consisted of 37 healthy infants born at the Copenhagen University Hospital, Hvidovre, Denmark. Twenty-seven infants (GA range: 28 to 34 weeks) were born preterm and 10 infants (GA range: 37 to 42 weeks) were term-born controls from the nursery. Early ultrasound measurements were used to assess GA. All infants were MR scanned around term or term-equivalent age, as a part of a larger preterm cohort study. Birth weight for the preterm groups ranged between 800 and 2160 g (mean 1554 g). All infants had an uncomplicated delivery and neonatal period; no asphyxia was observed or resuscitation was needed. Malformations were not detected. Apgar scores (Apgar score 5 min ranged 7–10) and umbilical cord pHs were within normal ranges in both groups. All preterm infants were clinically stable throughout the neonatal period; no severe infections or other serious events occurred. Infants had routine cerebral ultrasound examinations without indication of major lesions. Conventional MRI images of all infants were systematically reviewed by two experienced pediatric neuroradiologists and a pediatrician experienced in neonatal MRI. Images were scored according to the description by Rutherford, (2002) for the following parameters: myelination degree, ventricle size and extracerebral spaces, signal intensity changes in WM, germinal matrix/intraventricular hemorrhages, and other WM lesions as hemorrhagic infarction or periventricular leukomalacia. Agreement was reached between the observers. With the exception of two children with minimal germinal matrix hemorrhages and one child with a slightly

Table 1  
Demographic and clinical data

	Control infants	Preterm infants
	Mean (range), <i>n</i> =10	Mean (range), <i>n</i> =27
Gender (M/F)	9/1	15/12
Gestational age	39 weeks (37–42)	31 weeks (28–34)**
Postmenstrual age at the time of MR examination	40 weeks (38–42)	41 weeks (38–46)*
Postnatal age at MR time	2 days (0–4)	67 days (42–97)**
Birth weight	3259 g (2000–4336)	1554 g (800–2160)**

\*  $P < 0.05$ .

\*\*  $P < 0.001$ .

enlarged ventricle size (however, within normal limits), no other abnormalities were detected. All infants were discharged from hospital at the latest 36 weeks postmenstrual age (PMA). Table 1 summarizes characteristics of the groups. The local ethics committee accepted the study and informed parental consent was obtained in all cases.

### MRI data acquisition

For the MR examination, infants were unsedated, sleeping naturally after a feed, and wrapped in blankets and a deflated vacuum pillow. Padded silicone ear cups were used for noise protection. Data acquisition was performed on a Siemens Magnetom Trio 3 T scanner (see Gilmore et al., 2004, about the feasibility of using a 3T scanner for DTI studies of unsedated neonate samples) using a DTI sequence in transverse plane with the following parameters: scan time: 3:07 min, echo planar spin echo imaging (EPI), with 3 diffusion weightings, *b*-values: 0, 500, and 1000  $s/mm^2$ , 6 diffusion directions, 16 slices of 3.4 mm with gap distance factor 30% interleaved, repetition time (TR): 3500 ms, echo time (TE): 92 ms, voxel size  $1.8 \times 1.8 \times 3.4$  mm, field of view (FOV) read/phase=230 mm/100%. To improve the signal to noise ratio, 4 acquisitions were averaged for both the diffusion-weighted and the *b*=0 images. The MR protocol included the acquisition of turbo spin-echo (TSE) T2-weighted images (T2W) to be used for anatomical reference and for spatial normalization of each brain. The TSE acquisition parameters were: transverse plane, scan time: 3:02 min, 20 slices, slice thickness=4 mm (distance factor=10%), TR=4500 ms, TE (1)=15 ms, TE (2)=155 ms, flip angle=150, voxel size= $0.7 \times 0.7 \times 4.0$  mm, FOV read/phase=180/135 mm. An Inversion Recovery (IR) SE sequence in coronal plane (TR: 6260 ms, TE: 15 ms, TI: 1500 ms), along with the TSE images, was used for routine anatomical study of the infants' brain.

### Processing and data analysis of the diffusion images

For the current study, only images with a *b*-value of 1000 were used. The first step was to ascertain the quality of the raw images. Images with reduced quality because of movement or susceptibility artifacts were excluded from further analysis. Before calculating the tensors, the 6 diffusion images were realigned to each other and then registered with the non-diffusion-weighted image. The images were corrected for eddy currents and movement (Andersson and Skare, 2002). A diffusion tensor in each voxel was fitted to the log of the data with least squares (Anton, 2005) and from the tensor elements FA maps were calculated (Basser and Pierpaoli, 1996) and smoothed with a 2 mm Gaussian filter.

### VBM procedure

The automated image processing by VBM was done through SPM2 (<http://www.fil.ion.ucl.ac.uk/spm/software/spm2>), running in Matlab 6.5 (MathWorks, Natick, MA). The VBM applied to images was based on an optimized method (Good et al., 2001). In order to obtain an optimal and unbiased spatial normalization, we chose to create a study specific template, which was based on the normalization of individual scans to an anatomical infant-brain

template (referred to as the T2W anatomical template), also created specifically for the study.

### Creation of a T2W anatomical template

Appropriate T2W brain templates from larger groups of neonates are not available. Therefore, the first step was to create a template from 5 preterm and 5 control infants. These infants were imaged as a part of the whole preterm cohort, but did not have

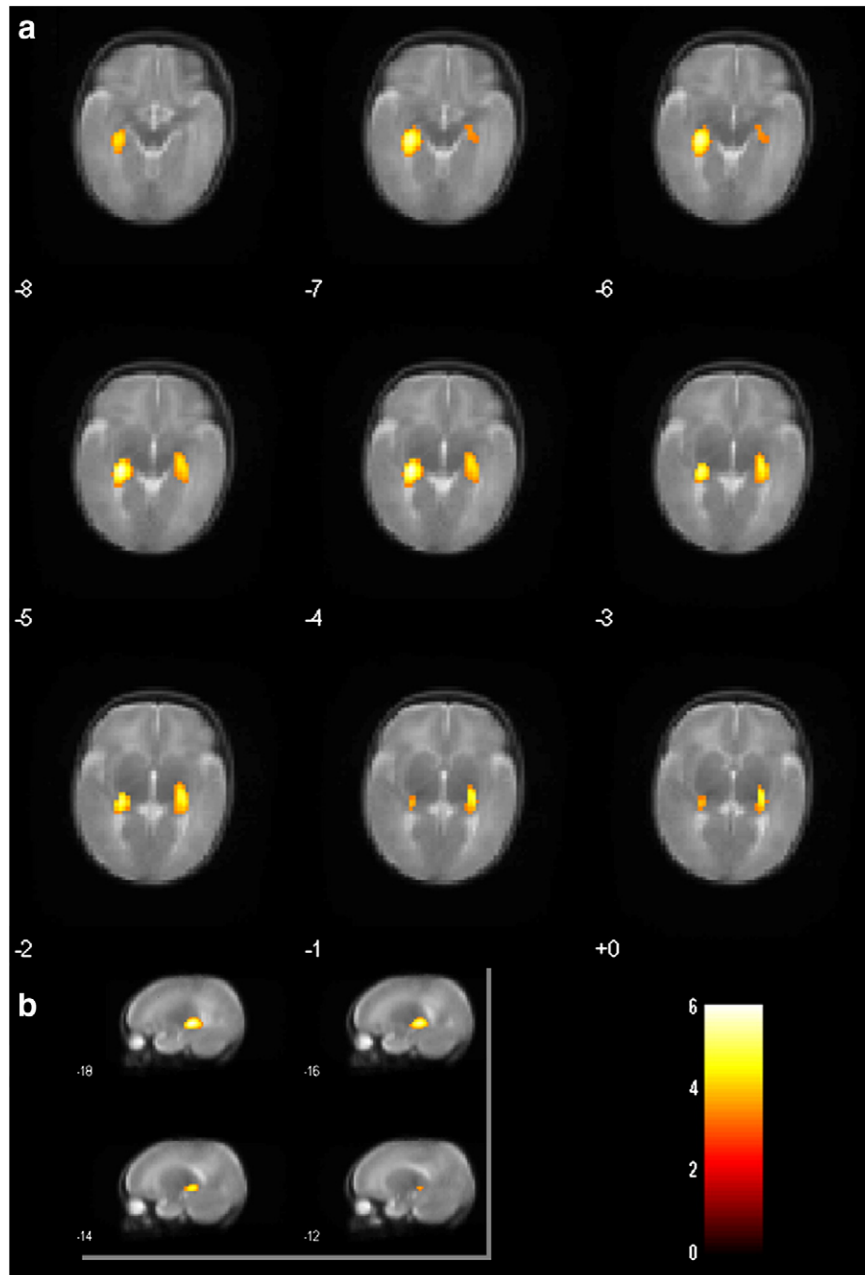


Fig. 1. Sections of images illustrating an increase in FA values mainly in the sagittal stratum region, bilaterally, in the preterm infant group compared to controls. The clusters include the inferior fronto-occipital fasciculi, the stria terminalis, the fornix, the optic radiation, inferior longitudinal fasciculus, and the lateral geniculate nucleus. (a) Axial sections with representative slices at a 1-slice interval. (b) Sagittal view of the right cluster with representative slices at a 2-slice interval. Differences are overlaid on the anatomic T2 mean of the sample. The color bar shows coding of the  $t$ -statistics. Results displayed are thresholded at voxel uncorrected  $P$  threshold of  $<0.001$ . Images are shown with the subject's left side on the right side of the figure (radiological convention).

Table 2  
Increase in the FA values in the preterm group compared to control infants

	Cluster size (mm <sup>3</sup> )	<i>t</i> -statistics
<i>Two-sample t-test comparison</i>		
Left cluster	760	4.94*
Right cluster	912	6.05*
<i>Analysis of covariance (postmenstrual age as a covariate)</i>		
Left cluster	568	4.68*
Right cluster	640	5.41*

\*  $P < 0.0001$  at global maxima coordinates.

usable DTI data and could therefore not be included in the present DTI comparisons. All had normal MR imaging and had an uneventful neonatal period.

The anterior and posterior commissures were manually determined by a single investigator (M.G.) in all 10 cases. One infant brain with symmetrical features was selected as reference, and following a previous study (Leung et al., 2004), a 12-parameter affine transformation was applied to spatially normalize the other 9 infant brains to this

reference. All T2W files were averaged and the mean was smoothed with a full-width at half-maximum (FWHM) isotropic Gaussian kernel of 5 mm. All 10 brains were normalized to the previous smoothed mean. A new mean was calculated from the normalized files and a smoothing of 5 mm was applied to form the T2W anatomical template.

#### Voxel-based morphometry steps

The T2W and DTI images were adjusted to a standard orientation after manual determination of the anterior and posterior commissures.

For each infant, the  $b_0$  images (i.e., reference scans with  $b \approx 0$  s/mm<sup>2</sup>) were co-registered to their corresponding T2W anatomical image, and the transformation was applied to the FA images. The T2W images were normalized to the T2W anatomical template, by a 12-parameter normalization step.

A study-specific template was created by averaging the 37 normalized T2W images, and the original  $b_0$  images were then normalized to this template, creating the final set of spatial transformation matrices. These transformations were used to reslice the corresponding FA images for each subject. A final smoothing with an 8 mm FWHM isotropic Gaussian kernel was applied to the FA maps before statistical analysis.

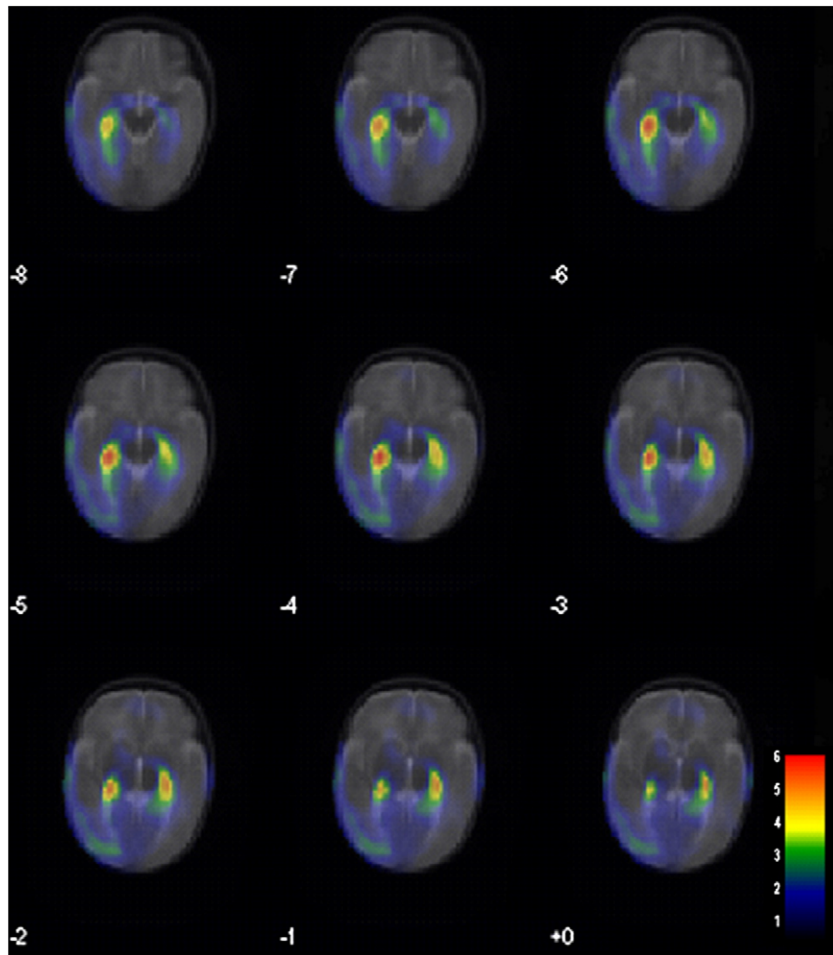


Fig. 2. Effect-size map of the contrast: preterm infants > control infants, in the FA comparison. Differences are overlaid on the anatomic T2 mean of the sample. The color bar represents the variability in *t*-statistics. All voxels with  $t \geq 0.5$  are colored. Images are shown with the subject's left side in the right side of the figure (radiological convention).



### Statistical procedure

A binarized brain mask, obtained by thresholding the study-specific template, was used as an explicit mask in all analyses.

The processed FA images were analyzed using the *t*-test group comparison in SPM2. Specifically, we performed two one-sided comparisons to detect anisotropy differences between groups (contrasts: control infants > preterm infants; preterm infants > control infants). The principal test for the presence of significant differences in FA between the groups employed the family-wise error-correction ( $P < 0.05$ ) (Nichols and Hayasaka 2003). Because this is a very conservative test, an effect-size map is also presented to provide further information about the likely anatomical distribution of the effects detected (Jernigan et al., 2003).

As the PMA was slightly higher in the preterm group (see Table 1), we also performed an ANCOVA, including the PMA as a covariate in the group comparison.

Moreover, as the gender distribution differed between groups (see Table 1), FA maps in males and females in the preterm group were compared.

## Results

### Voxel-based morphometry approach

After application of family-wise error-correction at  $P < 0.05$ , a significant increase in tissue anisotropy in the preterm group was observed in the right (cluster size = 200 mm<sup>3</sup>) and left (cluster size = 16 mm<sup>3</sup>) sagittal stratum region. The clusters were significant at corrected cluster level,  $P = 0.010$  and  $P = 0.037$ , respectively. They appeared to be within the sagittal stratum, as illustrated in the atlas of Mori et al. (2005). The main constituent of this structure is the inferior fronto-occipital fasciculus (IFOF). Structures situated in close proximity include the stria terminalis, the fornix, the optic radiation, a part of the inferior longitudinal fasciculus (ILF), and the adjacent lateral geniculate nucleus (LGN) within the posterior thalamus.

The results obtained using an uncorrected voxel threshold of  $P < 0.001$  are shown in Fig. 1. Table 2 provides cluster sizes and statistics obtained using this statistical criterion.

After correction for PMA (i.e., GA plus the time elapsed after birth) in the analysis of covariance (ANCOVA), the group differences remained significant at uncorrected voxel level  $P < 0.001$  (see Table 2); however, after application of family-wise error-correction at  $P < 0.05$ , only the right cluster survived the threshold (cluster size: 48 mm<sup>3</sup>;  $t = 5.41$ ; corrected cluster  $P = 0.027$ ).

No significant clusters were found to show an increase in anisotropy in the contrast controls > preterms.

In addition, we obtained the mean FA value of each of the clusters described in Table 2 for each group: *preterm infants*: left cluster = 0.2182; right cluster = 0.2102; *control infants*: left cluster = 0.1836; right cluster = 0.1701.

Comparison of male with female preterm infants yielded no significant differences in the FA maps. Hence it is unlikely that the group effects are due to uneven gender distribution.

### Effect size map

We display the effect-size map of the *t*-values for illustrative purposes (Fig. 2). The map suggests bilateral effects in the sagittal stratum area that are likely to extend beyond the significant clusters but are relatively circumscribed.

## Discussion

The present study used a mapping approach to detect differences on DTI between preterm and full-term infants at term equivalent age. Quantitative analysis of the FA maps using VBM provided evidence supporting the hypothesis that the healthy preterm infants showed accelerated cerebral WM development in some regions. Significant brain FA increases were found in the preterm group in two clusters in the region of the left and right sagittal stratum and in a position adjacent to the LGN of the posterior thalamus. These differences persisted when PMA was included in a covariance analysis. Several fiber tracts traverse this region within sagittal stratum, including the IFOF and ILF (Kier et al., 2004; Wakana et al., 2004; Mori et al., 2005). Precise localization of the effects is not possible from the present results; however, they would appear to involve important components of the visual system (specifically the LGN and optic radiations). Also, fibers from the medial geniculate nucleus and portions of the IC carrying somatosensory fibers lie near the identified cluster, so the affected tracts could include fibers from multiple sensory and motor systems. Prominent alterations of FA in this region have also been observed in normally developing full-term infants during the first 3 months of life (Schneider et al., 2004); however, the full regional extent of the changes was difficult to determine in this study. The present observations are important because they suggest that maturation of brain tissues may be accelerated by factors associated with preterm birth, perhaps directly by the effects of the extrauterine environment.

It is not known whether the timing and sequence of maturational changes that occur in the infant brain are under strong genetic control or whether, and to what extent, they depend on ongoing stimulation and activity in the brain. An important question is therefore whether the effects observed here reflect a more general stimulus to the progression of maturational events, or whether they arise more specifically as a result of increased activity in particular pathways. Although it is not possible to address the functional consequences of these changes with the present study, future studies may also define the behavioral correlates of increased FA in preterm infants.

In a previous study (Als et al., 2004), an attempt to modify the sensorimotor experiences of newborn preterm infants appeared to produce increased anisotropy in the IC and was associated with higher neurobehavioral outcome scores. Since the treatment administered in that study (NIDCAP) was described as reducing stimulation and calming the infant, it might seem as though the previously reported effects are inconsistent with acceleration of fiber tract maturation (presumably due to exposure to the extrauterine environment) in the present study. However, the findings of the two studies, while not directly comparable, are not inconsistent. First, it should be emphasized that although the care provided to the infants in the present study was not precisely the NIDCAP approach used by Als et al., it was a similar program with individualized conditions that involved family members, attempted to reduce stress, and provided a calming environment for the infants. Thus, the results of both studies are consistent with the notion that, under these conditions, and in the absence of significant complications, FA increases occur in sensorimotor fiber tracts in preterm infants. Since there were no full-term controls in the Als et al. study, it is not possible to say whether FA had increased in these infants at term to higher levels than are present in full-term infants, but the results of our study suggest that this may have been the case. The methods applied in the two studies make it difficult to compare the regional patterns of the reported effects. In the Als et al. study, significantly

increased FA was observed in ROIs in the IC and to a lesser extent, in ROIs in frontal areas. They did not examine ROIs in the posterior regions where maximum group effects were observed in the present study, though they did see effects in the adjacent IC. However, since Als et al. compared 2 subgroups of preterm infants, while in the present study preterm infants were compared to full term infants, it is not clear that similar patterns would be expected in any event.

The present findings differ more significantly from those of some previous studies. Evidence for WM damage or delayed WM maturation has been reported in preterm infants (Hüppi et al., 1998, 2001; Arzoumanian et al., 2003). Several factors may account for the discrepancies. In previous studies, specific brain regions were examined with ROI analyses, and thus the sensitivity and specificity of the WM measures in these studies differed from those in the present study, which used a mapping approach. Furthermore, the infants included in the present study had somewhat higher GAs (not less than 28 weeks) and may have been more stringently screened for perinatal complications than those in previous studies. Thus the results of previous studies may have been more strongly influenced by the effects of risk factors associated with preterm birth, but the results of the present study may provide more information about the effects of earlier extrauterine life, per se.

There were several limitations of the present study that should be considered. In spite of attempts to image the infants in the two groups at comparable PMA, the preterm infants had somewhat higher PMAs than did the full-term infants. The effects of this variable have been controlled in the statistical analysis, and the results do not appear to be attributable to it; however, such effects cannot be entirely ruled out. Another issue relates to the necessity of applying spatial normalization to the images in order to perform group analyses. It is possible that subtle differences in brain morphology between the two groups of infants could give rise to apparent differences in FA that actually represent misregistration of homologous structures. Every attempt has been made to optimize the spatial normalization process in the present study. A T2-weighted anatomical template was specifically constructed for the present study using brains from normally developing preterm and term born infants. Using this template, a study-specific template was then constructed to reduce bias in the spatial normalization process. Thus, it is unlikely that the effects are mediated by misregistration errors; however, such effects cannot be entirely dismissed. It should be noted that results from ROI approaches to the analysis of DTI data are also subject to such doubts, given that strict anatomical definition of the boundaries of WM structures is not possible with MRI.

It should be noted that head shape distortion is not uncommon in newborn infants, and previous authors have reported that preterm infants kept in incubators can exhibit flattening of the skull (Schwirian et al., 1986; Cartlidge and Rutter, 1988). Thus, systematic differences in head shape and/or in the positions of sinuses known to produce MR signal distortion should be considered as sources of spurious effects in this population. Subjectively, we observed no evidence for systematic head shape differences in our preterm relative to our full-term newborn infants. The preterm newborns of the current sample were moved into different positions inside the incubator to prevent skull or head shape deformations. While we think that any effects of systematic differences in head shape are likely to be very modest in our study, we cannot rule out the possibility that such differences could have exaggerated or partly obscured the group effects. Head shape variability in newborn infants is an issue that merits further scrutiny in future studies.

Finally, despite our attempts to include infants of both genders, the groups differed in gender distribution. This was in part because the DTI data were technically unacceptable in several female infants in the full-term group. Though we found no evidence that gender mediated the group differences reported here, this imbalance in the groups is a weakness of the study.

In conclusion, the present results provide evidence that earlier extrauterine life, or other factors associated with preterm birth, can result in acceleration of maturational changes in at least some brain regions in preterm infants. Future studies may reveal which environmental factors mediate these effects and what the functional correlates may be.

### Acknowledgments

We are grateful to P. Olsen for critical assistance in scanning the neonates. We acknowledge and thank the participants and their parents for their essential involvement in this study. We are also thankful to L. Hanson for assistance in technical aspects of DTI at 3T and for creating the original images. We thank Professor O. Paulson for making this collaboration possible. The support of the Danish Medical Research Council is gratefully acknowledged, as is the Elsass Foundation for grants to M.J.M. research. This study was partially supported by grant AP2002-0737 (Ministerio de Educación, Cultura y Deporte) to M.G.

### References

- Als, H., Duffy, F.H., McAnulty, G.B., Rivkin, M.J., Vajapeyam, S., Mulkern, R.V., Warfield, K., Hüppi, P.S., Butler, S.C., Conneman, N., Fischer, C., Eichenwald, E.C., 2004. Early experience alters brain function and structure. *Pediatrics* 113, 846–857.
- Andersson, J.L., Skare, S., 2002. A model-based method for retrospective correction of geometric distortions in diffusion-weighted EPI. *NeuroImage* 16, 77–199.
- Anton, H., 2005. *Elementary linear algebra*, 9th ed. Hoboken, NJ, Wiley.
- Arzoumanian, Y., Mirmiran, M., Barnes, P.D., Woolley, K., Ariagno, R.L., Moseley, M.E., Fleisher, B.E., Atlas, S.W., 2003. Diffusion tensor brain imaging findings at term-equivalent age may predict neurologic abnormalities in low birth weight preterm infants. *Am. J. Neuroradiol.* 24, 1646–1653.
- Ashburner, J., Friston, K.J., 2000. Voxel-based morphometry—the methods. *NeuroImage* 11, 805–821.
- Basser, P.J., Mattiello, J., LeBihan, D., 1994. MR diffusion tensor spectroscopy and imaging. *Biophys. J.* 66, 259–267.
- Basser, P.J., Pierpaoli, C., 1996. Microstructural and physiological features of tissues elucidated by quantitative-diffusion-tensor MRI. *J. Magn. Reson. B.* 111, 209–219.
- Berman, J.I., Mukherjee, P., Partridge, S.C., Miller, S.P., Ferriero, D.M., Barkovich, A.J., Vigneron, D.B., Henry, R.G., 2005. Quantitative diffusion tensor MRI fiber tractography of sensorimotor white matter development in premature infants. *NeuroImage* 27, 862–871.
- Buchel, C., Raedler, T., Sommer, M., Sach, M., Weiller, C., Koch, M.A., 2004. White matter asymmetry in the human brain: a diffusion tensor MRI study. *Cereb. Cortex* 14, 945–951.
- Cartlidge, P.H., Rutter, N., 1988. Reduction of head flattening in preterm infants. *Arch. Dis. Child.* 63, 755–757.
- Dammann, O., Leviton, A., 1997. Maternal intrauterine infection, cytokines, and brain damage in the preterm newborn. *Pediatr. Res.* 42, 1–8.
- Dammann, O., Kuban, K.C., Leviton, A., 2002. Perinatal infection, fetal inflammatory response, white matter damage, and cognitive limitations in children born preterm. *Ment. Retard. Dev. Disabil. Res. Rev.* 8, 46–50.
- Drobyshevsky, A., Song, S.K., Gamkrelidze, G., Wyrwicz, A.M., Derrick, M., Meng, F., Li, L., Ji, X., Trommer, B., Beardsley, D.J.,

- Luo, N.L., Back, S.A., Tan, S., 2005. Developmental changes in diffusion anisotropy coincide with immature oligodendrocyte progression and maturation of compound action potential. *J. Neurosci.* 25, 5988–5997.
- Duffy, F.H., Als, H., McAnulty, G.B., 1990. Behavioral and electrophysiological evidence for gestational age effects in healthy preterm and full-term infants studied two weeks after expected due date. *Child. Dev.* 61, 271–286.
- du Plessis, A.J., Volpe, J.J., 2002. Perinatal brain injury in the preterm and term newborn. *Curr. Opin. Neurol.* 15, 151–157.
- Gilmore, J.H., Zhai, G., Wilber, K., Smith, J.K., Lin, W., Gerig, G., 2004. 3 Tesla magnetic resonance imaging of the brain in newborns. *Psychiatry Res.* 132, 81–85.
- Good, C.D., Johnsrude, I.S., Ashburner, J., Henson, R.N., Friston, K.J., Frackowiak, R.S., 2001. A voxel-based morphometric study of ageing in 465 normal adult human brains. *NeuroImage* 14, 21–36.
- Haynes, R.L., Baud, O., Li, J., Kinney, H.C., Volpe, J.J., Folkerth, D.R., 2005. Oxidative and nitrative injury in periventricular leukomalacia: a review. *Brain Pathol.* 15, 225.
- Hubel, D.H., Wiesel, T.N., 1998. Early exploration of the visual cortex. *Neuron* 20, 401–412.
- Hüppi, P.S., Dubois, J., 2006. Diffusion tensor imaging of brain development. *Semin. Fetal. Neonatal. Med.* 11, 489–497.
- Hüppi, P.S., Maier, S.E., Peled, S., Zientara, G.P., Barnes, P.D., Jolesz, F.A., Volpe, J.J., 1998. Microstructural development of human newborn cerebral white matter assessed in vivo by diffusion tensor magnetic resonance imaging. *Pediatr. Res.* 44, 584–590.
- Hüppi, P.S., Murphy, B., Maier, S.E., Zientara, G.P., Inder, T.E., Barnes, P.D., Kikinis, R., Jolesz, A., Volpe, J.J., 2001. Microstructural brain development after perinatal cerebral white matter injury assessed by diffusion tensor magnetic resonance imaging. *Pediatrics* 107, 455–460.
- Inder, T.E., Warfield, S.K., Wang, H., Hüppi, P.S., Volpe, J.J., 2005. Abnormal cerebral structure is present at term in premature infants. *Pediatrics* 115, 286–294.
- Jernigan, T.L., Gamst, A.C., Fennema-Notestine, C., Ostergaard, A.L., 2003. More “mapping” in brain mapping: statistical comparison of effects. *Hum. Brain. Map.* 19, 90–95.
- Kier, E.L., Staib, L.H., Davis, L.M., Bronen, R.A., 2004. MR imaging of the temporal stem: anatomic dissection tractography of the uncinate fasciculus, inferior occipitofrontal fasciculus, and Meyer’s loop of the optic radiation. *Am. J. Neuroradiol.* 25, 677–691.
- Kleberg, A., Westrup, B., Stjernqvist, K., Lagercrantz, H., 2002. Indications of improved cognitive development at one year of age among infants born very prematurely who received care based on the Newborn Individualized Developmental Care and Assessment Program (NIDCAP). *Early Hum. Dev.* 68, 83–91.
- Leung, L.H., Ooi, G.C., Kwong, D.L., Chan, G.C., Cao, G., Khong, P.L., 2004. White-matter diffusion anisotropy after chemo-irradiation: a statistical parametric mapping study and histogram analysis. *NeuroImage* 21, 261–268.
- Maalouf, E.F., Duggan, P.J., Rutherford, M.A., Counsell, S.J., Fletcher, A.M., Battin, M., Cowan, F., Edwards, A.D., 1999. Magnetic resonance imaging of the brain in a cohort of extremely preterm infants. *J. Pediatr.* 135, 351–357.
- Miller, S.P., Vigneron, D.B., Henry, R.G., Bohland, M.A., Ceppi-Cozzio, C., Hoffman, C., Newton, N., Partridge, J.C., Ferriero, D.M., Barkovich, A.J., 2002. Serial quantitative diffusion tensor MRI of the premature brain: development in newborns with and without injury. *J. Magn. Reson. Imaging* 16, 621–632.
- Mori, S., Zhang, J., 2006. Principles of diffusion tensor imaging and its applications to basic neuroscience research. *Neuron* 51, 527–539.
- Mori, S., Wakana, S., Nagae-Poetscher, L.M., van Zijl, P.C.M., 2005. *MRI Atlas of Human White Matter*. Amsterdam, Elsevier.
- Mukherjee, P., McKinstry, R.C., 2006. Diffusion tensor imaging and tractography of human brain development. *Neuroimaging Clin. N. Am.* 16, 19–43.
- Mukherjee, P., Miller, J.H., Shiminy, J.S., Philip, J.V., Nehra, D., Snyder, A.Z., Conturo, T.E., Neil, J.J., McKinstry, R.C., 2002. Diffusion-tensor MR imaging of gray and white matter development during normal human brain maturation. *Am. J. Neuroradiol.* 23, 1445–1456.
- Nichols, T., Hayasaka, S., 2003. Controlling the familywise error rate in functional neuroimaging: a comparative review. *Stat. Methods Med. Res.* 12, 419–446.
- Park, H.J., Westin, C.F., Kubicki, M., Maier, S.E., Niznikiewicz, M., Baer, A., Frumin, M., Kikinis, R., Jolesz, F.A., McCarley, R.W., Shenton, M.E., 2004. White matter hemisphere asymmetries in healthy subjects and in schizophrenia: a diffusion tensor MRI study. *NeuroImage* 23, 213–223.
- Partridge, S.C., Mukherjee, P., Henry, R.G., Miller, S.P., Berman, J.I., Jin, H., Lu, Y., Glenn, O.A., Ferriero, D.M., Barkovich, A.J., Vigneron, D.B., 2004. Diffusion tensor imaging: serial quantitation of white matter tract maturity in premature newborns. *NeuroImage* 22, 1302–1314.
- Rutherford, M. (Ed.), 2002. *MRI of the Neonatal Brain*. Saunders, London, pp. 25–49.
- Schneider, J.F., Il’yasov, K.A., Hennig, J., Martin, E., 2004. Fast quantitative diffusion-tensor imaging of cerebral white matter from the neonatal period to adolescence. *Neuroradiology* 46, 258–266.
- Schwirian, P.M., Eesley, T., Cuellar, L., 1986. Use of water pillows in reducing head shape distortion in preterm infants. *Res Nurs. Health* 9, 203–207.
- Volpe, J.J., 2001. *Neurology of the Newborn*. WB Saunders, Philadelphia.
- Wakana, S., Jiang, H., Nagae-Poetscher, L.M., van Zijl, P.C., Mori, S., 2004. Fiber tract-based atlas of human white matter anatomy. *Radiology* 230, 77–87.
- Westrup, B., Kleberg, A., von Eichwald, K., Stjernqvist, K., Lagercrantz, H., 2000. A randomized, controlled trial to evaluate the effects of the newborn individualized developmental care and assessment program in a Swedish setting. *Pediatrics* 105, 66–72.