

Disseminated cryptococcosis presenting with cutaneous involvement in an immunocompromised patient

Redina Bardhi¹ BS, Kelsey Lawrence² MD, Lisa M Bedford² MD, Hany Deirawan² MD, Meena Moossavi² MD MPH

Affiliations: ¹School of Medicine, Wayne State University, Detroit, Michigan, USA, ²Department of Dermatology, Wayne State University, Detroit, Michigan

Corresponding Author: Kelsey Lawrence, 6497 Cranberry Drive, Holly, MI 48442, Tel: 810-444-7402, Email: kllawrence89@gmail.com

Abstract

Cryptococcosis is a fungal infection that typically affects immunocompromised patients. It most commonly affects the lungs and may then disseminate to the central nervous system, bone, skin, and adrenal glands. Herein, we describe a 69-year-old man who presented with skin lesions as the initial manifestation of disseminated cryptococcosis. Initial workup led to an assumption that the patient was immunocompetent. Later in the clinical course, idiopathic depletion of CD4 T cells was discovered. This case highlights that disseminated cryptococcosis may present with cutaneous symptoms even when there is no evidence of pulmonary or central nervous system involvement and may be the first sign of an underlying cellular immune dysfunction.

Keywords: cryptococcus neoformans, disseminated cryptococcosis, cutaneous cryptococcosis, immunocompetent

Introduction

Cryptococcus neoformans is an encapsulated yeast that causes cryptococcosis and colonizes pigeon excrement, soil, and dust [1-3]. It most often affects patients with impaired cell-mediated immunity, such as those with HIV [3]. The lungs are usually the primary site of infection, where it can remain localized or spread hematogenously to other organs such as the central nervous system (CNS) and skin [3-5]. Disseminated *C. neoformans* infection in

immunocompetent individuals is extremely rare and usually involves the lungs and CNS [1,6]. Cutaneous cryptococcal infection can be an early sign of disseminated disease or it can occur via primary inoculation [3-5]. Primary cutaneous cryptococcal infection caused by local inoculation usually presents as a solitary lesion [3,5]. Disseminated cryptococcosis presents as multiple lesions, which may be the first indication of disseminated infection [6].

Case Synopsis

A 69-year-old man presented with a three-week history of a rapidly growing ulcerating lesion on the right upper back. The plaque was draining and painful. He denied any history of trauma. He denied ownership of pets, recent travel outside Michigan, and exposure to birds, soil, or dust. He denied fever, malaise, chest pain, shortness of breath, cough, weight loss, vision changes, and headache. He had a history of basal cell carcinoma and type two diabetes mellitus. He did not have a history of liver disease and had recently tested negative for Hepatitis A, B, and C. At the time of presentation, there was no indication that the patient was immunosuppressed. In addition, the patient did not have a history of increased incidence of infection suggesting antibody deficiency. The right upper back exhibited a 4.0cm ulcerated plaque with heaped edges and granulation tissue at the base (**Figure 1**). Minimal serosanguinous discharge was noted. The patient also had five scattered papules and plaques on the

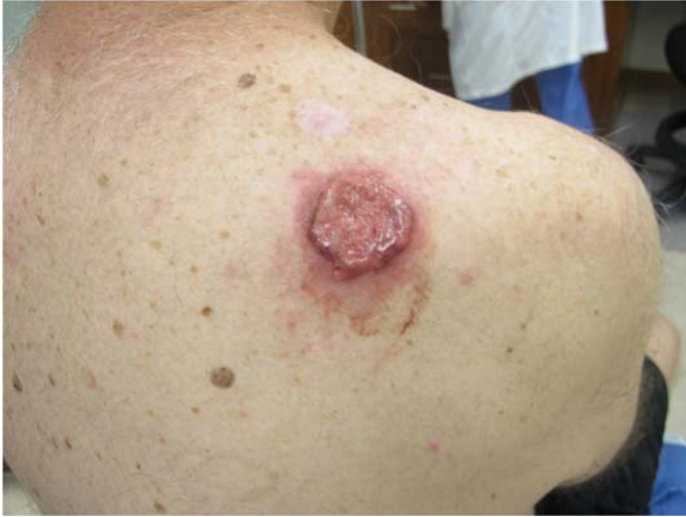

Figure 1. The right upper back shows a 4.0cm ulcerated plaque with heaped edges and granulation tissue at the base.

scalp and neck with central ulceration and overlying crust. Two biopsies were obtained from an ulcerated plaque on the back, one for tissue culture and one for histological examination.

On histopathology the epidermis was ulcerated. The dermis and subcutis were replaced by diffuse infiltration of pleomorphic micro-organisms in colony-like groups. The morphology of the microorganism was that of round, medium sized, structures surrounded by a gelatinous capsule consistent with a fungal yeast element (**Figure 2**). This capsule was histochemically shown to be rich in mucin, which stained pink with mucicarmine (**Figure 3**). Tissue cultures grew *Cryptococcus neoformans*. Cryptococcal antigen in the serum was positive, with a titer of >1:64, consistent with disseminated disease. Chest X-ray demonstrated no active disease in the lungs. Cryptococcal antigen and fungal culture from the cerebrospinal fluid were negative. Complete blood count and comprehensive metabolic panel were unremarkable. HIV antibody screen was nonreactive. No additional studies of immunosuppression were performed at the time. Based on recommendations from an infectious disease consultant, the patient was treated with fluconazole 400mg daily for six months. His skin lesions started to resolve within a few weeks and were completely resolved in 6 months. However, four months after finishing treatment, the patient presented to a different hospital with atypical

pneumonia, which was diagnosed as pneumocystis pneumonia. He was subsequently diagnosed with CD4 count depletion without HIV, and unfortunately passed away two months later from an upper GI bleed secondary to a duodenal ulcer.

Case Discussion

Cryptococcosis is a fungal infection caused by *Cryptococcus neoformans*, an opportunistic pathogen that typically affects immunocompromised patients. *Cryptococcus neoformans* is divided into five serotypes: A, D, AD (*C. neoformans* var. *neoformans*) and B or C (*C. gattii*, formerly *C. neoformans* var. *gattii*). Serotype A is found worldwide, serotype D is typically found in Europe, and serotypes B and C are limited to tropical and subtropical regions [5].

Cryptococcus neoformans is an encapsulated yeast that is typically found in bird feces, soil, and dust. Other common sources include tree branches, fruit, and vegetables. Disease can be spread through inhalation of the fungi, which usually leads to asymptomatic pulmonary infection, or through direct inoculation via the skin, which presents as primary cutaneous cryptococcosis. Hematogenous dissemination from the lungs primarily affects the meninges, with the skin, bones, prostate, and other organs less commonly affected [1]. Direct

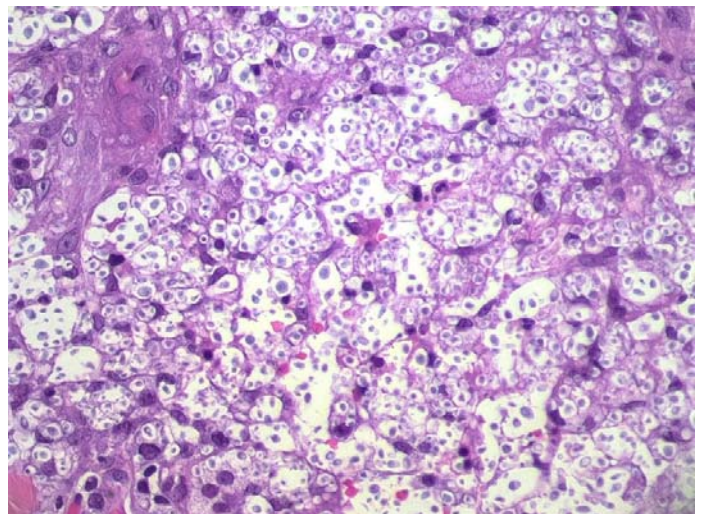


Figure 2. Hematoxylin-eosin stain demonstrates numerous grouped pleomorphic intracellular yeast organisms, 40x.

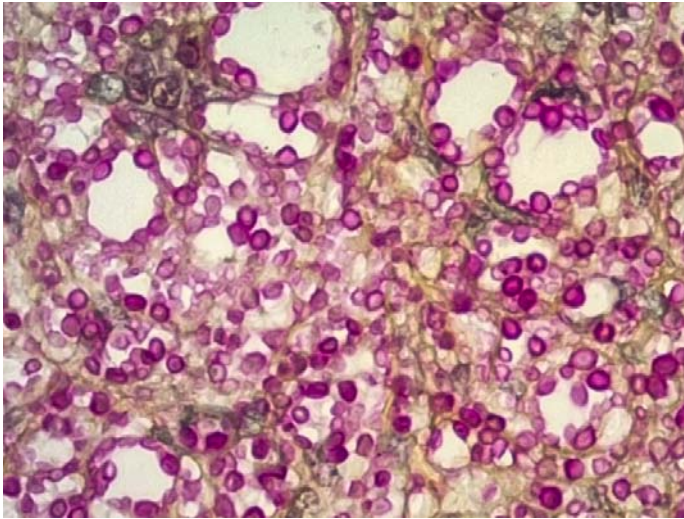


Figure 3. Mucicarmine stain reveals a bright red staining of the gelatinous capsule, 100x.

inoculation typically presents as a single cutaneous lesion without systemic dissemination [5].

Skin involvement occurs in about 10-15% of patients with disseminated cryptococcosis and may be an *early manifestation of the disease* [1,5]. The morphology of cutaneous lesions varies; they may be ulcerated, umbilicated, acneiform, nodular, purpuric, granulomatous, herpetiform, or cellulitis-like and affect exposed and unexposed areas [1]. Cutaneous cryptococcosis can mimic a wide range of cutaneous infections such as bacterial, mycobacterial, and other fungal infections, such as coccidioidomycosis, blastomycosis, and histoplasmosis [7]. Vesiculopustular skin lesions of cryptococcosis may resemble varicella [8]. Cutaneous cryptococcosis can also mimic basal cell carcinoma when it presents with a pearly border and a central crust [9]. Other disorders in the differential diagnosis include leishmaniasis, Kaposi sarcoma, and molluscum contagiosum [10-12].

Treatment of disseminated cryptococcosis in immunocompetent patients without CNS

involvement is oral fluconazole 400mg/day for 6-12 months. Amphotericin B can be used in more severe cases of disseminated cryptococcosis with involvement of other organ systems and in immunocompromised patients [2].

In this case, the patient was diagnosed with immunodeficiency later in his clinical course. The infection most likely entered the lungs and disseminated to the skin. The cutaneous cryptococcal lesions were the only manifestation of his disseminated disease. It is rare for disseminated cryptococcosis to present as multiple lesions in the skin without involvement of other organs. Cryptococcosis should be included in the differential diagnosis of ulcerated skin lesions, even in otherwise healthy and asymptomatic patients.

Conclusion

Disseminated cryptococcosis may be the first sign of T cell-mediated immunosuppression in patients. Ulcerating papules and plaques of the skin can be the initial manifestations of disseminated cryptococcosis in immunosuppressed patients, even when there is no evidence of pulmonary or CNS involvement. Cutaneous manifestations of cryptococcosis are important to recognize to initiate timely treatment. Biopsies for histologic examination and tissue culture of the lesions are essential to establishing the diagnosis. Patients with cutaneous cryptococcosis should be worked up for disseminated disease with chest X-ray and evaluation for cryptococcal antigen in the serum and cerebrospinal fluid.

Potential conflicts of interest

The authors declare no conflicts of interests.

References

1. Ruan Q, Zhu Y, Chen S, et al. Disseminated cryptococcosis with recurrent multiple abscesses in an immunocompetent patient: a case report and literature review. *BMC Infect Dis.* 2017;17:369. [PMID: 28558705].
2. Yamaguchi H, Komase Y, Ikehara M, Yamamoto T, Shinagawa T. Disseminated cryptococcal infection with eosinophilia in a healthy person. *J Infect Chemother.* 2008;14:319-24. [PMID: 18709538].
3. Wlodek C, Ng Y, Bovill B, et al. An Unusual Cause of Cutaneous Ulceration. *Clin Exp Dermatol.* 2017;42:226-229. [PMID: 28044361].
4. Christianson JC, Engber W, Andes D. Primary cutaneous cryptococcosis in immunocompetent and immunocompromised

- hosts. *Med Mycol.* 2003;41:177-88. [PMID: 12964709].
5. Amaral DM, Rocha RC, Carneiro LE, Vasconcelos DM, Abreu MA. Disseminated cyptococcosis manifested as a single tumor in an immunocompetent patient, similar to the primary cutaneous forms. *An Bras Dermatol.* 2016;91:29-31. [PMID: 28300886].
 6. Mada P, Nowack B, Cady B, Joel Chandranesan AS. Disseminated cryptococcosis in an immunocompetent patient. *BMJ Case Rep.* 2017;2017:bcr2016218461. [PMID: 28720691].
 7. Mayers DL, Martone WJ, Mandell GL. Cutaneous Cryptococcosis Mimicking Gram-Positive Cellulitis in a Renal Transplant Patient. *South Med J.* 1981;74:1032-3. [PMID: 7022667].
 8. Yantsos, VA, Carney J, Greer DL. Review of the Morphological Variations in Cutaneous Cryptococcosis with a New Case Resembling Varicella. *Cutis.* 1994;54:343-7. [PMID: 7835064].
 9. Ingleton R, Koestenblatt E, Don P, et al. Cutaneous Cryptococcosis Mimicking Basal Cell Carcinoma in a Patient with AIDS. *J Cutan Med Surg.* 1998;3:43-45. [PMID: 9677260].
 10. Moretti de Lima A, Rodrigues MM, Santiago Reis CM. Cutaneous Cryptococcosis Mimicking Leishmaniasis. *Am J Trop Med Hyg.* 2018;98:3-4. [PMID: 29342402].
 11. Blauvelt A, Kerdel FA. Cutaneous cryptococcosis mimicking Kaposi's sarcoma as the initial manifestation of disseminated disease. *Int J Dermatol.* 1992;31:279-280. [PMID: 1634295].
 12. Ramdial PK, Calonje E, Sing Y, Chotey NA, Aboobaker J. Molluscum-like cutaneous cryptococcosis: a histopathological and pathogenetic appraisal. *J Cutan Pathol.* 2008;35:1007-13. [PMID: 18537859].