

UC San Diego

UC San Diego Previously Published Works

Title

Anterior cruciate ligament tear: indirect signs at MR imaging.

Permalink

<https://escholarship.org/uc/item/8qw8v2dr>

Journal

Radiology, 193(3)

ISSN

0033-8419

Authors

Gentili, A
Seeger, LL
Yao, L
[et al.](#)

Publication Date

1994-12-01

DOI

10.1148/radiology.193.3.7972834

Peer reviewed

Anterior Cruciate Ligament Tear: Indirect Signs at MR Imaging¹

PURPOSE: To establish the sensitivity and specificity of indirect signs at magnetic resonance (MR) imaging of anterior cruciate ligament (ACL) tear.

MATERIALS AND METHODS: MR images of the knees of 89 consecutive patients (54 with torn and 35 with normal ACLs) were reviewed.

RESULTS: The indirect signs were as follows (first percentage is sensitivity; the second, specificity): angle between lateral tibial plateau and ACL less than 45° (90%, 97%); angle between Blumenstaat line and ACL more than 15° (89%, 100%); bone contusions in lateral compartment (54%, 100%); position of posterior cruciate ligament (PCL) line (52%, 91%); PCL angle less than 107° (52%, 94%); PCL bowing ratio more than 0.39 (34%, 100%); posterior displacement of lateral meniscus more than 3.5 mm (44%, 94%); anterior displacement of tibia more than 7 mm (41%, 91%); and lateral femoral sulcus deeper than 1.5 mm (19%, 100%).

CONCLUSION: Because the specificity is high, the presence of indirect signs corroborates the diagnosis of ACL tear. Because the sensitivity is low, the absence of these signs does not exclude the diagnosis of ACL tear.

Index terms: Knee, ligaments, menisci, and cartilage, 4526.4857 • Knee, MR, 4526.1214 • Ligaments, injuries, 4526.4857 • Ligaments, MR, 4526.1214

Radiology 1994; 193:835-840

¹ From the Department of Radiological Sciences, University of California Los Angeles Center for the Health Sciences (A.G., L.L.S., L.Y., H.M.D.), and the Department of Radiology (W114), West Los Angeles Veterans Administration Medical Center, Wilshire and Sawtelle Blvds, Los Angeles, CA 90073 (A.G.). From the 1993 RSNA scientific assembly. Received April 28, 1994; revision requested June 23; revision received July 19; accepted July 25. Address reprint requests to A.G.

¹ RSNA, 1994

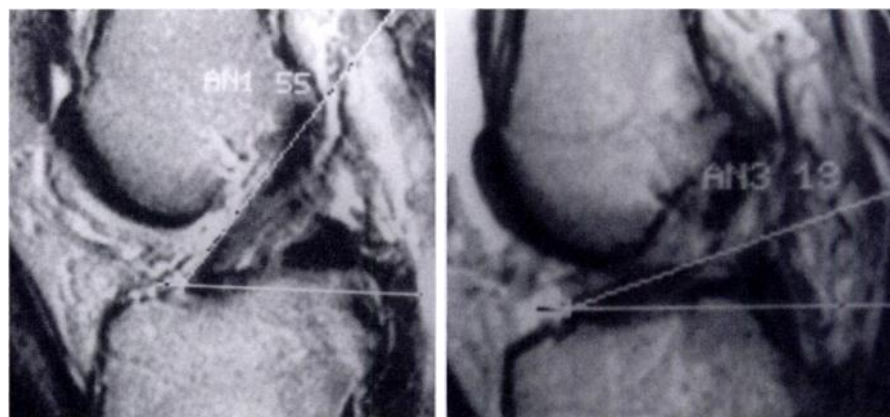


Figure 1. The ACL angle is measured between the anterior surface of the ACL and a reference line parallel to the midlateral tibial plateau. The reference line is drawn on an image through the midlateral tibial plateau and reported on the image showing the ACL. (a) Sagittal (2,100/90) MR image shows ACL angle of 55° (AN1 55) measured in a 55-year-old man with an intact ACL at arthroscopy. (b) Sagittal (2,000/80) MR image shows ACL angle of 19° (AN3 19) measured between the anterior surface of the ACL and a reference line parallel to the lateral tibial plateau in a 35-year-old man with an ACL tear at arthroscopy.

MAGNETIC resonance (MR) imaging has been reported to be accurate in helping make the diagnosis of complete anterior cruciate ligament (ACL) tear. In most reports the diagnosis of ACL tears is based on sagittal images that show a disrupted ACL (1,2). Direct signs of ACL tear include wavy contour of the ACL, focal or diffuse high signal intensity within the substance of the ACL on T2-weighted images, and lack of continuity of the ACL (3,4). Although MR imaging is accurate, false-positive and false-negative diagnoses have been reported (5). T2-weighted images; oblique sagittal, coronal, and axial images; and gradient-echo images have been obtained to improve results (6).

The use of secondary (indirect) signs of ACL tear has been advocated to improve accuracy. Numerous indirect signs have been described. These include orientation of the ACL (6,7), bone contusions and osteochondral fractures (7-11), posterior cruciate

ligament (PCL) line (7,12), PCL angle (13), PCL bowing (3,13,14), deep lateral femoral sulcus (7,15,16), anterior drawer sign (7,14,17-19), and posterior displacement of the lateral meniscus (13). The purpose of this study was to compare the sensitivity and specificity of indirect signs of ACL tear.

MATERIALS AND METHODS

We performed a retrospective review of the images of 89 consecutively evaluated patients who underwent MR imaging of the knee followed by arthroscopy. The mean age of the patients was 30 years 11 months (range, 16-75) years. Sixty-two patients were men and 27 were women.

Arthroscopy was performed by 14 orthopedic surgeons. Two orthopedic surgeons who specialized in sports medicine performed 72 of the 89 procedures (81%).

Abbreviations: ACL = anterior cruciate ligament, PCL = posterior cruciate ligament.

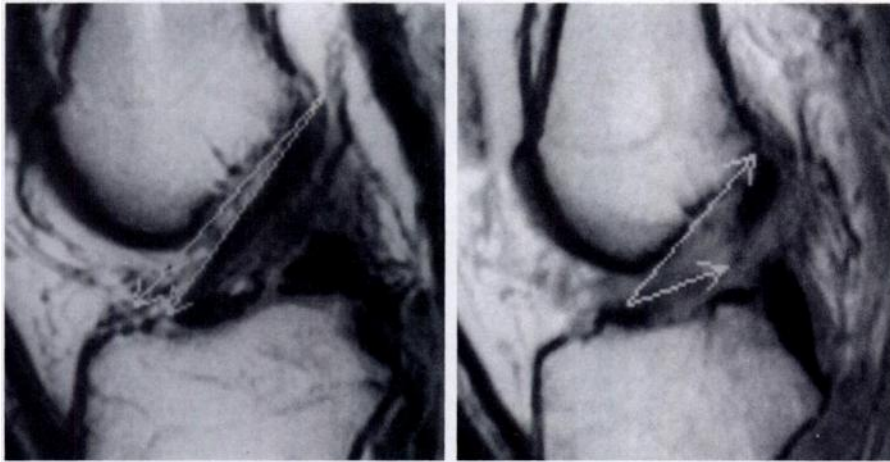


Figure 2. The ACL-Blumensaat line angle is measured between the posterior surface of the femur and the distal portion of the ACL. The angle has a negative value when the apex points superiorly and a positive value when the apex points inferiorly. **(a)** Sagittal (2,100/20) MR image shows ACL-Blumensaat line angle of -7° in a 55-year-old man with intact ACL at arthroscopy. **(b)** Sagittal (2,000/30) MR image shows ACL-Blumensaat line angle of $+32^\circ$ in a 35-year-old man with ACL tear at arthroscopy.

At arthroscopy, 54 patients had a torn ACL and 35 had a normal ACL. Of the 54 ACL tears, 49 were complete and five were partial. Review of the patient charts and of questionnaires administered to the patients before MR images were obtained showed that 33 ACL tears (28 complete and five partial) were acute (less than 1 month old), nine were subacute (between 1 and 3 months old), and 13 were chronic (more than 3 months old). MR imaging of the knee was performed with a 1.5-T unit (Signa, GE Medical Systems, Milwaukee, Wis, or Magnetom, Siemens, Erlangen, Germany) with a dedicated extremity coil. The knee was positioned in full extension with approximately 15° of external rotation. For all patients sagittal multiecho acquisitions (repetition time msec/echo time = 1500–2500/20, 70–90) were obtained. T1-weighted (400–500/20–30) or multiecho (1,500–2,500/20 or 70–90) coronal acquisitions also were obtained.

Each study was reviewed retrospectively without knowledge of the arthroscopic findings, clinical history, or initial MR imaging interpretations. Because this was a retrospective study all measurements were made on the hard copy. Primary signs and nine different indirect signs were considered. *P* values for group comparison were based on results of the unpaired *t* test.

The ACL was considered normal if it was depicted as a continuous linear band of low signal intensity on either proton-density- or T2-weighted images. The ACL was considered torn if it had a wavy contour, had a focal or diffuse high signal intensity within the substance of the ligament on T2-weighted images, or lacked continuity.

The orientation of the ACL was measured in two different ways: (a) with respect to the lateral tibial plateau (the ACL angle) (Fig 1) and (b) with respect to the Blumensaat line (Fig 2).

The presence and location of bone contusions and osteochondral fractures were noted. On T2-weighted images, bone contusions were defined as areas of geographic or reticular, nonlinear high signal intensity that involved subcortical bone; on either proton-density- or T1-weighted images, contusions were areas of low signal intensity. Bone contusions and osteochondral fractures were considered positive for ACL tear if they were present in the lateral femoral condyle above the lateral femoral sulcus or in the posterior aspect of the lateral tibial plateau.

The position of the PCL line as described by Schweitzer et al (12) in relation to the distal femur was used as an indirect sign. The image was selected that best demonstrated the distal portion of the PCL. A line was drawn tangent to the posterior margin of the linear portion of the distal PCL and extended proximally. The sign was considered positive if the proximal extension of the PCL line did not cross the medullary cavity of the distal femur. This sign was considered negative if the proximal extension of the PCL line did cross the medullary cavity of the distal 5 cm of the femur.

The PCL angle was the angle measured between a line through the center of the proximal and a line through the distal portion of the PCL (Fig 3) (13).

The PCL bowing ratio was the ratio between the distance of the anterior surface of the PCL and a line connecting the most anterior points of attachment of the PCL on the femur and tibia divided by the distance between the most anterior points of attachment of the PCL on the femur and the tibia (14).

Posterior displacement of the lateral meniscus was measured as displacement of the posterior horn of the lateral meniscus behind the most posterior margin of the tibial plateau (Fig 4).

We measured anterior tibial displace-

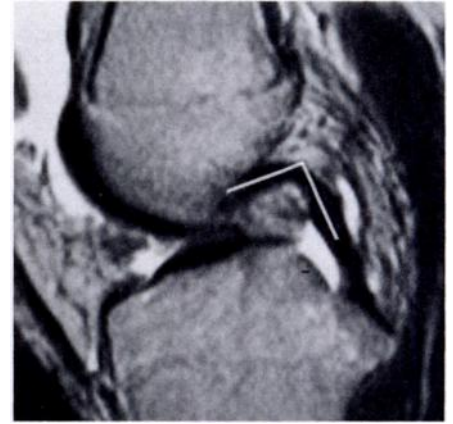


Figure 3. Sagittal (2,000/80) MR image of a 35-year-old man with ACL tear at arthroscopy. The PCL angle measured between a line through the center of the proximal portion of the PCL and a line through the center of the distal portion of the PCL is 96° .

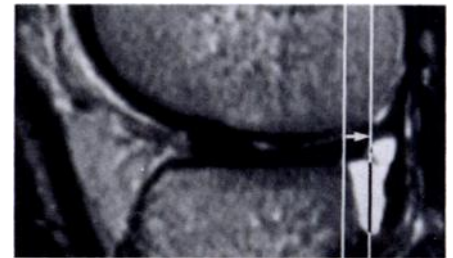


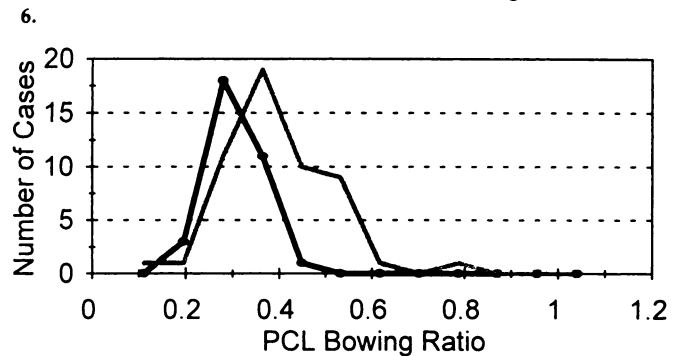
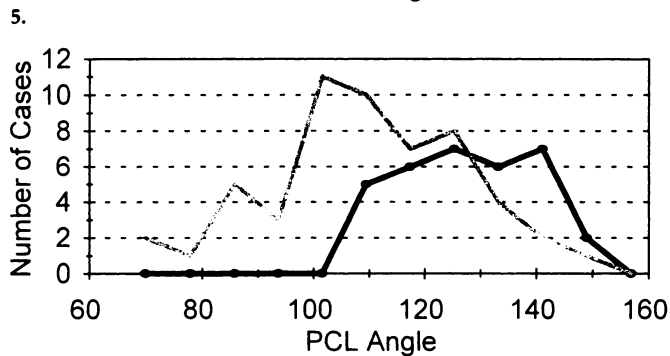
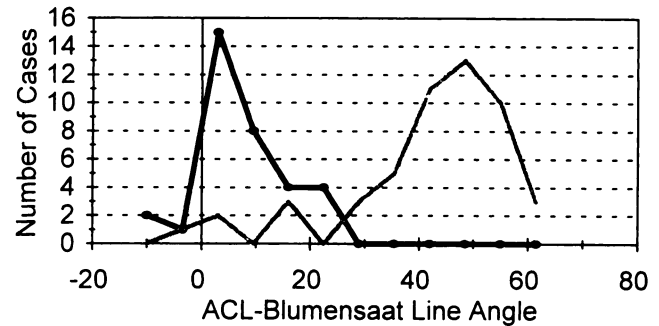
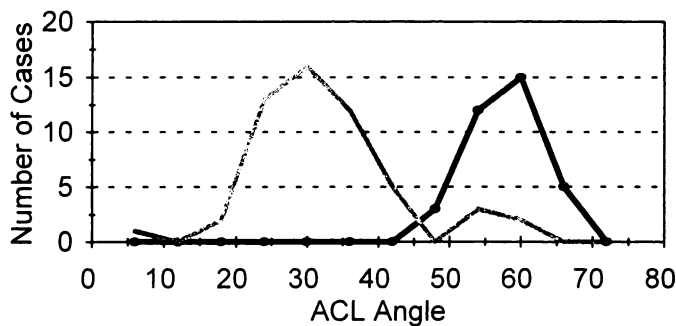
Figure 4. Sagittal (2,000/80) MR image of a 35-year-old man with ACL tear at arthroscopy. The posterior displacement of the lateral meniscus is measured as the distance (arrow) between two lines parallel to the tibia. The first line passes through the posterior corner of the lateral tibial plateau, and the second line is tangent to the most posterior aspect of the posterior horn of the lateral meniscus. The posterior displacement of the lateral meniscus is 6 mm.

ment (anterior drawer sign) by drawing a line tangent to the posterior margin of the cortex of the lateral femoral condyle and parallel to the long axis of the tibia (5).

The depth of the lateral sulcus was measured according to the method of Warren et al (15) and Cobby et al (16). A line drawn tangent to the articular surface served as the reference, and the depth of the sulcus was measured perpendicular to this line.

RESULTS

The mean ACL angle for patients without an ACL tear was 55.6° . The mean ACL angle for patients with an ACL tear was a significantly smaller 29.9° ($P < .001$). There was no significant difference between the ACL angle in acute tears and that in chronic tears (Table 1). There was only minimal overlap in the value of the ACL angle between patients with an ACL tear and patients with a nor-



Figures 5–8. (5) Frequency distribution of ACL angle. There is good separation between patients with a normal ACL (black line) and patients with a torn ACL (gray line). (6) Frequency distribution of ACL–Blumensaat line angle. There is good separation between patients with a normal ACL (black line) and patients with a torn ACL (gray line). (7) Frequency distribution of PCL angle. Overlap is seen between patients with a normal ACL (black line) and patients with a torn ACL (gray line). (8) Frequency distribution of PCL bowing ratio. Overlap is seen between patients with a normal ACL (black line) and patients with a torn ACL (gray line).

Table 1
Comparison between Acute and Chronic ACL Tear

Sign	Acute ACL Tears (mean)	Chronic ACL Tears (mean)	P Value	Sensitivity for Acute ACL Tears (%)	Sensitivity for Chronic ACL Tears (%)
ACL angle	30.7°	27.2°	NS	87	100
ACL–Blumensaat line angle	26.6°	27°	NS	87	100
Bone contusion	NA	NA	NA	76	25
PCL line	NA	NA	NA	45	76
PCL angle	109°	95°	<.001	42	84
PCL bowing ratio	0.24	0.29	<.05	12	42
Posterior displacement of lateral meniscus (mm)	2.1	5.1	.001	30	76
Anterior drawer (mm)	5.4	8.7	<.001	27	61
Depth of lateral femoral sulcus (mm)	0.827	0.419	NS	18	7

Note.—NA = not applicable, NS = not significant.

mal ACL (Fig 5). When an angle of less than 45° was used as a cutoff value, the sensitivity of the presence of this sign was 91% and the specificity was 97%. When the cutoff angle was less than 40°, the sensitivity decreased to 89% and the specificity increased to 100%.

The mean angle between the ACL and the Blumensaat line for patients without an ACL tear was –1.6°. The mean ACL–Blumensaat line angle for patients with an ACL tear was a significantly greater 25.8° ($P < .001$). There was no significant difference

between the ACL–Blumensaat line angle in acute tears and that in chronic tears (Table 1). There was only minimal overlap in the value of the ACL–Blumensaat line angle between patients with an ACL tear and patients with a normal ACL (Fig 6). When an angle more than 9° was used as the cutoff value, the sensitivity was 91% and the specificity was 86%. When a cutoff angle more than 15° was used, the sensitivity decreased to 89% and the specificity increased to 100%.

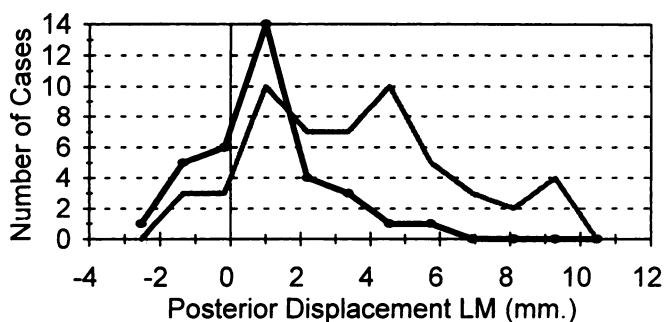
The presence of bone contusions in

the lateral femoral condyle above the femoral sulcus had a sensitivity of 51% and a specificity of 100%. The presence of bone contusions in the posterior aspect of the lateral tibial plateau had a sensitivity of 51% and a specificity of 100%. When bone contusions in either the tibial plateau or the femoral condyle were considered, the sensitivity was 58% and the specificity was 100%. Among the 33 patients with acute ACL tears, the sensitivity was 76%.

A positive PCL line sign had a sensitivity of 51% and a specificity of 91%. The sensitivity was 76% for chronic tears and was 45% for acute tears.

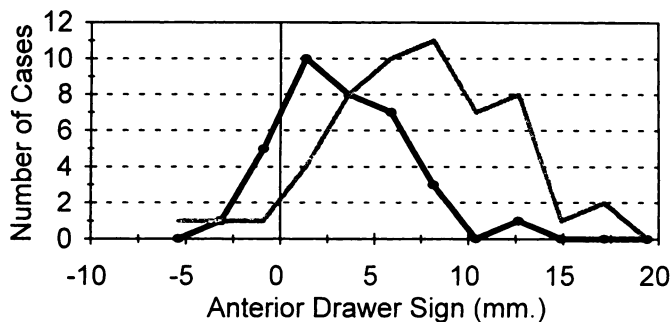
The mean PCL angle for patients without an ACL tear was 123°. The mean PCL angle for patients with an ACL tear was a significantly smaller 106° ($p < .001$). There was, however, overlap in the value of the PCL angle between patients with an ACL tear and patients with a normal ACL (Fig 7). When the cutoff angle was less than 107°, the sensitivity was 52% and the specificity 94%. When the cutoff angle was less than 100°, the sensitivity decreased to 37% and the specificity increased to 100%. The PCL angle in acute tears was significantly different from that in chronic tears (Table 1).

The mean PCL bowing ratio for patients without an ACL tear was

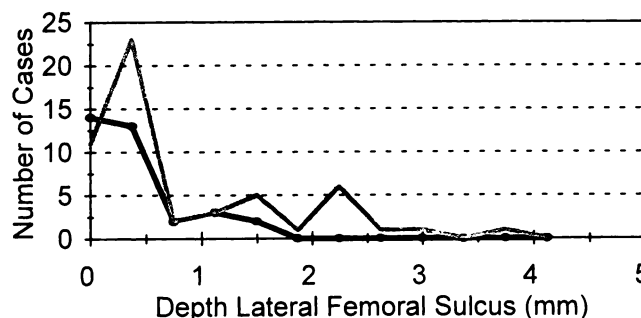


9.

Figures 9–11. (9) Frequency distribution of posterior displacement of lateral meniscus (LM). Overlap is seen between patients with a normal ACL (black line) and patients with a torn ACL (gray line). (10) Frequency distribution of anterior drawer sign. Overlap is seen between patients with a normal ACL (black line) and patients with a torn ACL (gray line). (11) Frequency distribution of lateral femoral sulcus depth. Overlap is seen between patients with a normal ACL (black line) and patients with a torn ACL (gray line).



10.



11.

0.19. The mean PCL bowing ratio for patients with an ACL tear was a significantly larger 0.26 ($P < .001$). There was overlap in the value of the PCL bowing ratio between patients with an ACL tear and patients with a normal ACL (Fig 8). When a ratio of more than 0.39 was considered abnormal, the sensitivity was 34% and the specificity was 100%. The PCL bowing ratio in acute tears was significantly different from that in chronic tears (Table 1).

The mean posterior displacement of the lateral meniscus for patients without an ACL tear was 0.54 mm. The mean posterior displacement of the lateral meniscus for patients with an ACL tear was a significantly greater 3.05 mm ($P < .001$). There was overlap in the posterior displacement of the lateral meniscus between patients with an ACL tear and patients with a normal ACL (Fig 9). When more than 3.5 mm of posterior displacement of the lateral meniscus was considered abnormal, the sensitivity was 44% and the specificity 94%. When greater than 5 mm of posterior displacement of the lateral meniscus was used as the cutoff value, the sensitivity decreased to 20% and the specificity increased to 100%. The PCL bowing ratio in acute tears was significantly different from that in chronic tears (Table 1).

The mean anterior displacement of the tibia (anterior drawer sign) for patients with an intact ACL was 2.17 mm. The mean anterior displacement of the tibia for patients with an ACL tear was a significantly larger 6.18 mm ($P < .001$). There was overlap in the value of the anterior displacement of the tibia between patients with an ACL tear and patients with a normal

ACL (Fig 10). When more than 5 mm of anterior displacement of the tibia was considered abnormal, the sensitivity was 63% and the specificity 80%. When the cutoff value was more than 7 mm, the sensitivity decreased to 41% and the specificity increased to 91%. The anterior displacement of the tibia in acute tears was significantly different from that in chronic tears (Table 1).

The mean depth of the lateral femoral sulcus for patients without an ACL tear was 0.35 mm. The mean depth of the lateral femoral sulcus for patients with an ACL tear was a significantly greater 0.74 mm ($P < .02$). There was overlap in the value of depth of the lateral femoral sulcus between patients with an ACL tear and patients with a normal ACL (Fig 11); most patients had a sulcus less than 1 mm deep. When a depth of the lateral femoral sulcus more than 1 mm was considered abnormal, the sensitivity was 30% and the specificity 94%. When a depth more than 1.5 mm was used as the cutoff value, the sensitivity decreased to 19% and the specificity increased to 100%. The depth of the lateral femoral sulcus in acute tears was *not* significantly different from that in chronic tears (Table 1).

Direct signs of ACL tear had a sensitivity of 93% and a specificity of 97%. There were one false-positive and four false-negative diagnoses. In the one false-positive diagnosis, all secondary signs were negative; the

apparent disruption of the ACL was due to a partial volume effect. Of the four false-negative diagnoses, three were partial tears and one was a complete tear. Of the three false-negative partial tears, a bone contusion was present in the lateral femoral condyle in one patient; otherwise, the indirect signs were all negative. The patient with the false-negative diagnosis who had a complete tear had a positive ACL angle, ACL-Blumensaat line angle, posterior displacement of the lateral meniscus, and anterior drawer sign.

DISCUSSION

The MR imaging diagnosis of ACL tear is usually based on direct signs of tear. These signs include a wavy contour of the ACL, focal or diffuse high signal intensity within the substance of the ACL on T2-weighted images, discontinuity of the ACL, or a combination of these signs. These direct signs are usually sufficient for an accurate diagnosis. High sensitivity and specificity have been reported for these primary signs. Only two patients in our series had positive indirect signs and negative direct signs. Several indirect signs of ACL tear have been reported in the literature (Table 2).

A normal ACL is taut when the angle between the femur and the articular surface of the lateral tibial plateau is approximately 55° (M. Shapiro, oral communication, 1994). When the

Table 2
Indirect Signs of ACL Tear: Review of the Literature

Reference	Sign	No. with ACL Tear	No. without ACL Tear	Sensitivity (%)	Specificity (%)
7	Tibial bone contusion	43	60	40.5*	97.5*
7	Femoral bone contusion	43	60	37.5*	98.5*
13	Bone contusion	39	29	48*	97*
14	Bone contusion	50	53	44	96
9	Bone injury to tibia or femur	32	NDA	100	NDA
8	Bone injury < 4 wk earlier	100	200	56	100
10	Bone injury < 3 wk earlier	75	NDA	85	NDA
11	Bone injury	98	NDA	48	NDA
11	Bone injury < 6 wk earlier	47	NDA	71	NDA
7	PCL line	43	60	66*	85.5*
12	PCL line	22	59	86	94
7	PCL bowing	43	60	58*	90*
18	PCL bowing	60	29	17	100
14	PCL curvature > 0.39°	50	53	44	96
13	PCL angle < 105°	39	29	73*	82.5*
7	ACL parallel to Blumensaat line	43	60	79*	86*
13	Posterior displacement of lateral meniscus	39	29	56*	98.5*
14	Posterior displacement of lateral meniscus	50	53	44	96
7	Anterior drawer sign	43	60	60	88
17	Anterior drawer sign	10	52	100	100
18	Anterior drawer > 5 mm	60	29	58	93
18	Anterior drawer > 7 mm	60	29	38	100
19	Anterior drawer > 5 mm	21	91	86	99
15	Lateral femoral sulcus > 1.5 mm deep	153	47	10	98
16	Lateral femoral sulcus > 1 mm deep	41	62	29	97
16	Lateral femoral sulcus > 1.5 mm deep	41	62	12	100

Note.—NDA = no data available.

* Average of scores of two independent observers.

tibia and femur are at this angle, the ACL is parallel to the posterior surface of the femoral notch (7). When torn, the ACL assumes a more horizontal orientation. In our experience, the change in orientation of the ACL is one of the best indirect signs of an ACL tear; it has a high sensitivity and a high specificity.

Bone contusions are most likely caused by anterior subluxation of the tibia at the time of tear of the ACL accompanied by impaction of the middle portion of the lateral femoral condyle against the posterior portion of the lateral tibial plateau (8). The signal-intensity abnormalities of bone contusions are probably due to edema, hemorrhage, and possibly microfracture. Pathologic correlation is usually not available because these abnormalities resolve spontaneously. In one case described by Rosen et al (10), a biopsy performed at the time of preparation of a tunnel for reconstruction of the ACL demonstrated edema and hemorrhage in the bone marrow. Bone contusions are seen immediately after injury. As reported by Graf et al (11), they are not seen in

patients with injuries that occurred more than 6 weeks earlier (11).

When the ACL is deficient, the tibia may become displaced anteriorly. This anterior displacement of the tibia may be measured directly as the anterior drawer sign. This sign has a high specificity (91%), although the sensitivity is only 41% when at least 7 mm of anterior displacement of the tibia is present. PCL bowing is an indirect sign of anterior displacement of the tibia. The assessment of bowing is subjective and has a low sensitivity for ACL tear (17%) (5). The PCL line, PCL angle, and PCL bowing ratio have been introduced to make assessment of PCL bowing less subjective. In our experience these three signs have a high specificity (91%–100%) but only a moderate sensitivity (34%–52%). Positioning the patient in the MR unit and selection of the sagittal plane of imaging can affect the degree of bowing of the PCL. Even a mild genu recurvatum deformity may make the PCL appear bowed. The significant difference in the value of PCL angle, PCL bowing ratio, posterior displacement of the lateral menis-

cus, anterior drawer sign, and PCL line between patients with acute and patients with chronic ACL tears can be explained by delayed failure of secondary restraints of the knee. This failure of secondary restraints allows increased anterior displacement of the tibia in patients with chronic tears (20).

Posterior displacement of the lateral meniscus is a sign of anterior displacement of the tibia. When the tibia becomes displaced anteriorly, the lateral meniscus remains with the femur, resulting in posterior displacement of the posterior horn of the lateral meniscus with respect to the tibia (13).

The increased depth of the lateral femoral sulcus in patients with an ACL tear is due to impacted fracture, similar to a Hill-Sachs lesion of the humerus. This impaction occurs when the tibia becomes displaced anteriorly and the lateral femoral sulcus pushes against the posterior rim of the tibial plateau. This is the same mechanism that causes bone contusions in the region of the femoral sulcus and posterolateral tibial plateau.

In conclusion, the diagnosis of ACL tear can be made on the basis of primary signs alone, but the presence of indirect signs corroborates the diagnosis. Except for ACL angle and ACL-Blumensaat line angle, because indirect signs have a low sensitivity, the absence of such signs does not exclude the diagnosis of ACL tear. ■

References

1. Beltran J, Noto AM, Mosure JC, Weiss KL, Zuelzer W, Christoforidis AJ. The knee: surface-coil MR imaging at 1.5 T. *Radiology* 1986; 159:747–751.
2. Reicher MA, Hartzman S, Basset LW, Mandelbaum B, Duckwiler G, Gold RH. MR imaging of the knee. I. Traumatic disorders. *Radiology* 1987; 162:547–551.
3. Lee JK, Yao L, Phelps CT, Wirth CR, Czajka J, Lozman J. Anterior cruciate ligament tears: MR imaging compared with arthroscopy and clinical tests. *Radiology* 1988; 166: 861–864.
4. Remer EM, Fitzgerald SW, Friedman H, Rogers LF, Hendrix RW, Schafer MF. Anterior cruciate ligament injury: MR imaging diagnosis and pattern of injury. *RadioGraphics* 1992; 12:901–915.
5. Vahey TN, Broome DR, Kayes KJ, Shelbourne KD. Acute and chronic tears of the anterior cruciate ligament: differential features at MR imaging. *Radiology* 1991; 181:251–253.
6. Fitzgerald SW, Remer EM, Friedman H, Rogers LF, Hendrix RW, Schafer MF. MR evaluation of the anterior cruciate ligament: value of sagittal images with coronal and axial images. *AJR* 1993; 160:1233–1237.
7. Robertson PL, Schweitzer ME, Bartolozzi AR. Anterior cruciate ligament tears: MR imaging evaluation. *Radiology* 1994; 193: 829–834.
8. Kaplan PA, Walker CW, Kilcoyne RF, Brown DE, Tusek D, Dussault RG. Occult

- fracture patterns of the knee associated with anterior cruciate ligament tears: assessment with MR imaging. *Radiology* 1992; 183:835-838.
9. Murphy BJ, Smith RL, Uribe JW, Janecki CJ, Hechtman KS, Mangasarian RA. Bone signal abnormalities in the posterolateral tibia and lateral femoral condyle in complete tears of the anterior cruciate ligament: a specific sign? *Radiology* 1992; 182: 221-224.
 10. Rosen MA, Jackson DW, Berger PE. Occult lesions documented by magnetic resonance imaging associated with anterior cruciate ligament ruptures. *Arthroscopy* 1991; 7:45-51.
 11. Graf BK, Cook DA, De Smet AA, Keene JS. "Bone bruises" on magnetic resonance imaging evaluation of anterior cruciate ligament injuries. *Am J Sports Med* 1993; 21: 220-223.
 12. Schweitzer ME, Cervilla V, Kursunoglu-Brahme S, Resnick D. The PCL line: an indirect sign of anterior cruciate ligament injury. *Clin Imaging* 1992; 16:43-48.
 13. McCauley TR, Moses M, Kier R, Lynch JK, Barton JW, Joki P. MR diagnosis of tears of anterior cruciate ligament of the knee: importance of ancillary findings. *AJR* 1994; 162:115-119.
 14. Tung GA, Davis LM, Wiggins ME, Fadale PD. Tears of the anterior cruciate ligament: primary and secondary signs at MR imaging. *Radiology* 1993; 188:661-667.
 15. Warren RF, Kaplan N, Bach BR. The lateral notch sign of anterior cruciate ligament insufficiency. *Am J Knee Surg* 1988; 1:119-124.
 16. Cobby MJ, Schweitzer ME, Resnick D. The deep lateral femoral notch: an indirect sign of a torn anterior cruciate ligament. *Radiology* 1992; 184:855-858.
 17. Chan WP, Fritz RC, Stoller DW, Genant HK. MR "anterior drawer" sign: a useful sign in the diagnosis of complete anterior cruciate ligament tear (abstr). *Radiology* 1991; 181:178-179.
 18. Vahey TN, Hunt JE, Shelbourne KD. Anterior translocation of the tibia at MR imaging: a secondary sign of anterior cruciate ligament tear. *Radiology* 1993; 187:817-819.
 19. Chan WP, Peterfy C, Fritz RC, Genant HK. MR diagnosis of complete tears of the anterior cruciate ligament of the knee: importance of anterior subluxation of the tibia. *AJR* 1994; 162:355-360.
 20. Fetto JF, Marshall J. The natural history and diagnosis of anterior cruciate ligament insufficiency. *Clin Orthop* 1980; 147:29-38.