

# UC Irvine

## UC Irvine Previously Published Works

### Title

Clinical Significance of Preoperative CT and MR Imaging Findings in the Prediction of Postoperative Recurrence of Spinal Giant Cell Tumor of Bone

### Permalink

<https://escholarship.org/uc/item/8hq0c8sz>

### Journal

Orthopaedic Surgery, 13(8)

### ISSN

1757-7853

### Authors

Wang, Qi-zheng  
Zhang, En-long  
Xing, Xiao-ying  
et al.

### Publication Date

2021-12-01




### DOI

10.1111/os.13173

Peer reviewed

## CLINICAL ARTICLE

# Clinical Significance of Preoperative CT and MR Imaging Findings in the Prediction of Postoperative Recurrence of Spinal Giant Cell Tumor of Bone

Qi-zheng Wang, BM<sup>1</sup> , En-long Zhang, MS<sup>2</sup> , Xiao-ying Xing, MD<sup>1</sup>, Min-ying Su, PhD<sup>3</sup>, Ning Lang, MD<sup>1</sup> 

<sup>1</sup>Department of Radiology, Peking University Third Hospital and <sup>2</sup>Department of Radiology, Peking University International Hospital, Beijing, China and <sup>3</sup>Department of Radiological Sciences, University of California, Irvine, California, USA

**Objectives:** To explore the predictive value of preoperative imaging in patients with spinal giant cell tumor of bone (GCTB) for postoperative recurrence and risk stratification.

**Methods:** Clinical data for 62 cases of spinal GCTB diagnosed and treated at our hospital from 2008 to 2018 were identified. All patients were followed up for more than 2 years according to the clinical guidelines after surgery. Medical history data including baseline demographic and clinical characteristics, computed tomography (CT) and magnetic resonance imaging (MRI) findings of recurrent and non-recurrent patients were compared. Two musculoskeletal radiologists read the images and were blinded to the clinical data. The imaging features associated with postoperative recurrence were analyzed by multivariate logistic regression, and receiver operating characteristic (ROC) curve analysis was performed to determine the optimal cutoff value of the largest lesion diameter predicting recurrence after surgery.

**Results:** According to whether the disease recurred within the follow-up period, patients were divided into the recurrence group and the non-recurrence group. Of 62 patients (29 males and 33 females), 17 had recurrence and 45 did not. The recurrence rate was 27.4%. The mean follow-up time was 73.66 ( $\pm$  32.92) months. The three major treatments were total *en bloc* spondylectomy ( $n = 26$ ), intralesional spondylectomy ( $n = 20$ ), and curettage ( $n = 16$ ). A total of 16 CT and MRI features were analyzed. A univariate analysis showed no significant difference in age, sex, treatment, multi-vertebral body involvement, location, boundary, expansile mass, residual bone crest, paravertebral soft tissue mass, CT value, and MRI signal on T1-weighted imaging (WI), T2-WI, and T2-WI fat suppression (FS) sequences ( $P > 0.05$ ). The largest lesion diameter [(4.68  $\pm$  1.79) vs (5.92  $\pm$  2.17) cm,  $t = 2.287$ ,  $P = 0.026$ ] and the vertebral compression fracture (51% vs 82%,  $\chi^2 = 5.005$ ,  $P = 0.025$ ) were significantly different between the non-recurrence and recurrence groups. Logistic regression analysis showed that both largest lesion diameter (odds ratio [OR], 1.584; 95% confidence interval [CI], 1.108–2.264;  $P = 0.012$ ) and compression fracture (OR, 8.073; 95%CI, 1.481–11.003;  $P = 0.016$ ) were independent predictors of postoperative recurrence. When we set the cutoff value for the largest lesion diameter at 4.2 cm, the sensitivity and specificity for distinguishing the recurrence and non-recurrence of GCTB were 94.1% and 42.2%, respectively, and the area under the curve (AUC) was 0.671. The combined model achieved a sensitivity, specificity and accuracy of 47.1%, 97.8% and 83.9%, respectively.

**Conclusions:** In spinal GCTB, maximum lesion diameter and the vertebral compression fracture are associated with tumor recurrence after surgery, which may provide helpful information for planning personalized treatment.

**Key words:** Giant cell tumor; Magnetic resonance imaging; Prognosis; Recurrence; Tomography

**Address for correspondence** Ning Lang, MD, Department of Radiology, Peking University Third Hospital, 49 North Garden Road, Haidian District, Beijing, China 100191; Tel: (0086) 10-82265571; Fax: (0086) 10-82265571; Email: langning800129@126.com

**Disclosure:** No benefits in any form have been or will be received from a commercial party related directly or indirectly to the subject of this manuscript.

Received 1 October 2020; accepted 19 October 2021

Orthopaedic Surgery 2021;13:2405-2416 • DOI: 10.1111/os.13173

This is an open access article under the terms of the Creative Commons Attribution-NonCommercial-NoDerivs License, which permits use and distribution in any medium, provided the original work is properly cited, the use is non-commercial and no modifications or adaptations are made.

## Introduction

Giant cell tumor of bone (GCTB) is currently classified as an intermediate tumor in clinical practice because its biological behavior is borderline or hard to distinguish. GCTB primarily affects the young adult patient population. Although GCTB is a relatively common skeletal neoplasm, the incidence of mobile spinal involvement above the sacrum is 1.4%–9.4%<sup>1</sup>, and there are few cases in the literature with large samples and long-term follow-up in the literature. Historically, GCTB is mainly composed of stromal cells, multi-nucleated giant cells and monocytes. Monocytes account for a small proportion of cells and are considered tumor cells, while multi-nucleated giant cells are considered major cell components and are similar to osteoclasts<sup>2,3</sup>. Multi-nucleated giant cells are mainly responsible for the extensive bone resorption of tumors. However, spindle-shaped monocytes chiefly direct tumor pathology mainly by recruiting monocytes and promoting their fusion into giant cells. Stromal cells also enhance the absorptive capacity of multi-nucleated giant cells.

Currently, the biggest challenge in GCTB management is the recurrence rate after surgery. Researchers have gradually realized the importance of risk stratification in spinal GCTB<sup>4</sup>, because the postoperative recurrence rate of spinal GCTB can reach 70%<sup>5</sup>, and sarcomatous malignant transformation or metastasis may occur<sup>6</sup>. The prognosis of spinal GCTB is worse compared with GCTB in the extremities. A high recurrence rate is a typical feature of spinal GCTB and also an important factor influencing the prognosis. However, research on spinal GCTB has been slow, and there is no consensus on which patients are at high risk of recurrence and metastasis<sup>7</sup>. There is no well-established guideline based on clinical, histological, imaging or morphological evaluation methods that can accurately predict recurrence<sup>8</sup>.

The key to reducing spinal GCTB recurrence is to identify the risk factors, which can be used to guide the choice of optimal treatment, clinical expectation, and appropriate follow-up plan. Patients at a high risk of recurrence should consider more thorough surgical methods during clinical treatment. In these patients, it is necessary to consider adjuvant therapy and closer follow up after surgery<sup>9</sup>. Previous studies have suggested some risk factors for recurrence, of which pathological features and molecular biomarkers are extremely important, such as matrix metalloproteinase (MMP)<sup>10</sup>, nuclear factor kappa B receptor activation factor/nuclear factor kappa B receptor activation factor ligand/osteoprotegerin (RANK/RANKL/OPG)<sup>11</sup>, vascular endothelial growth factor (VEGF)<sup>12</sup> and gene p53<sup>13,14</sup>. These markers reflect tumor aggressiveness to a certain degree and may be used to predict the prognosis of patients with GCTB. However, the pathological examination requires tissue biopsy, and preoperative puncture may cause compression fracture especially in osteolytic lesions or tumor dissemination via the biopsy channel. Furthermore, pathological evaluation may be limited by insufficient sampling of needle biopsy tissue. Importantly, overall tumor heterogeneity

cannot be assessed. Owing to the disorderly distribution of benign and malignant tissue inside the tumor, failure to comprehensively sample tumors may lead to misdiagnoses of tumor aggressiveness. If malignant tissue is not detected during sampling, a pathologist may underestimate the malignancy of the tumor. Compared with genetic testing or pathological analysis, which require analysis of tissue samples, developing non-invasive imaging methods to predict recurrence in patients before surgery can aid in the development of personalized treatment plans, including surgical methods and adjuvant treatment.

As a non-invasive preoperative examination method, preoperative computed tomography (CT) has been widely used in clinical diagnosis and follow-up. It can outline the cortical alterations of lesions more accurately, and the cost is low. Radiographically, GCTB includes eccentric lytic lesions with no sclerosis and well-defined margins. It can also show aggressive features including wide transition areas, cortical thinning and remodeling, and cortical bone destruction with a related soft tissue mass. Magnetic resonance imaging (MRI) is also increasingly used before surgery, and it is more sensitive to detection of soft tissue diseases. It may provide information about tumor boundaries including the zone of transition, adjacent soft tissue invasion, and cystic changes. Both CT and MRI are valuable for the diagnosis and evaluation of bone tumors and are important for the preoperative evaluation of spinal GCTB. Biological aggressive and prognostic markers related to the molecular expression of GCTB may also be revealed on CT and MRI characteristics. At the same time, radiologically characteristic imaging of GCTB can evaluate the overall tumor performance, so it can supplement the limitations of pathological evaluation. However, the value of preoperative imaging for the prognostic evaluation of patients with spinal GCTB has not yet been fully studied and needs further research.

In this study, patients diagnosed with spinal GCTB by pathology were reviewed and analyzed to explore the predictive value of preoperative imaging characteristics for postoperative recurrence, to evaluate the aggressiveness of GCTB before surgery in a non-invasive way. The objective of the current study was to: (i) explore the imaging features of preoperative CT and MRI and improve clinicians' awareness of the imaging manifestations of spinal GCTB; (ii) help to identify at-risk populations for giant cell tumor of bone, which contribute to orthopedic surgeons planning surgical methods and adjuvant therapy to effectively treat spinal GCTB; and (iii) be conducive to providing reasonable clinical survival expectations for patients and paying attention to follow-up plan adjustment to improve patient survival outcomes.

## Materials and Methods

### Subjects

A retrospective review of medical records identified 62 patients with pathologically confirmed spinal GCTB by pathology from March 2008 to February 2018 at our hospital. The inclusion

criteria were as follows: (i) patients confirmed spinal GCTB by postoperative or biopsy pathology in our institution; (ii) received surgical treatment in our hospital; (iii) CT with/without MRI examination before operation; and (iv) complete medical records to determine if recurrence after surgery. The exclusion criteria were as follows: (i) poor image quality; (ii) previous surgery or other treatment for the tumor at other institutions; and (iii) the postoperative follow-up time is less than 2 years. The research was approved by the Medical Science Research Ethics Committee of our hospital, and the requirement for informed consent was waived. Figure 1 shows the subject identification flowchart.

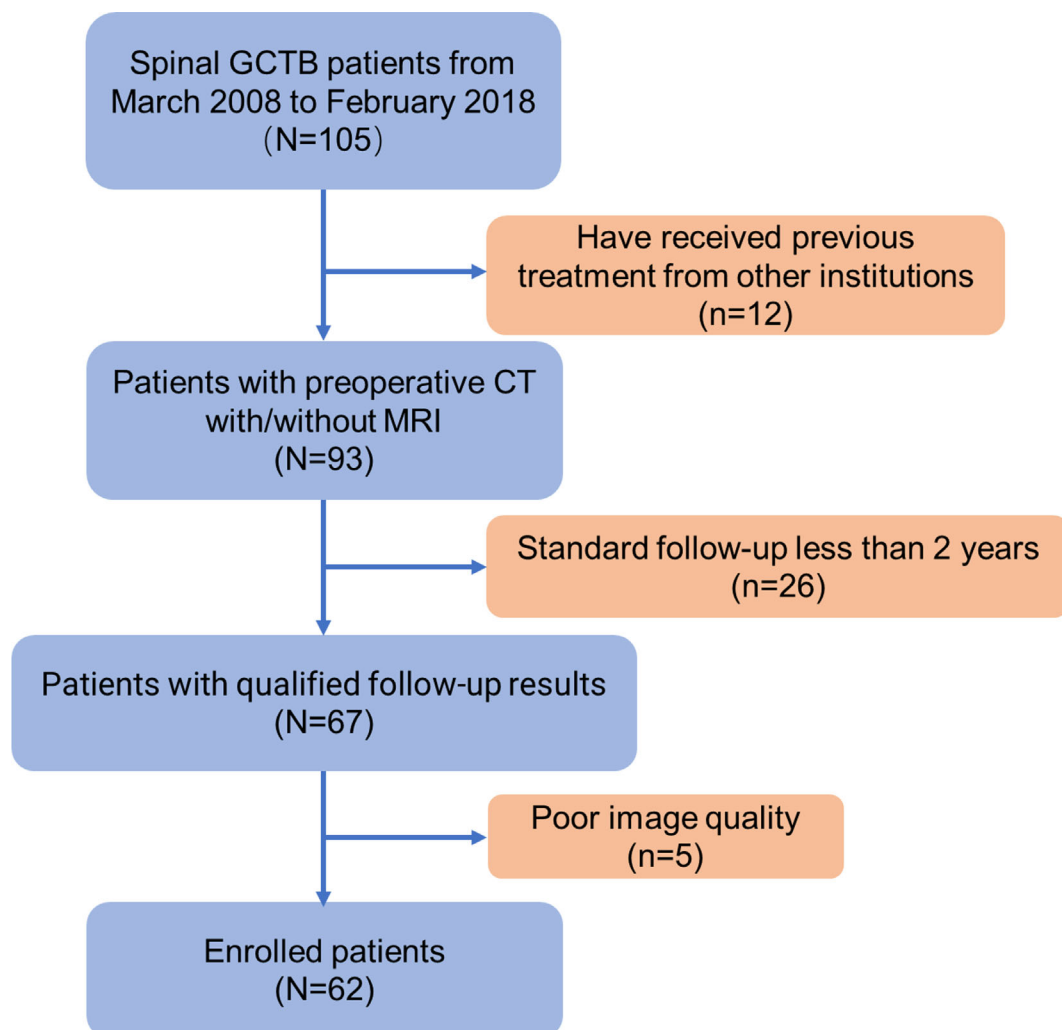
As for the follow-up plan, all patients were followed up according to the clinical guidelines: once every 3 months in the first 2 years, once every 6 months after 3–5 years, and annually after 5 years. The follow-up procedures included: physical examination and imaging of the operation site (X-ray, CT, or MRI). Local recurrence was confirmed on CT or MRI. If a new lesion, such as a soft tissue mass with an uneven density and invasive growth, was found at the tumor resection site, it

was considered as recurrence. Figure 2 shows images of a spinal GCTB patient. Figure 3 shows the follow-up data of a patient with recurrence and metastasis after surgery.

Clinical information that may have related to recurrence was obtained, including: age, sex, treatment, lesion location, and multi-vertebral involvement. Among them, the treatment methods were divided into three categories according to the patient's medical records: total *en bloc* spondylectomy (total removal of the vertebral body where the lesion is located), intralesional spondylectomy (local removal of the tumor), and other treatment methods (curettage with or without extensive procedures/radiotherapy). Figure 4 shows a patient without recurrence after intralesional spondylectomy.

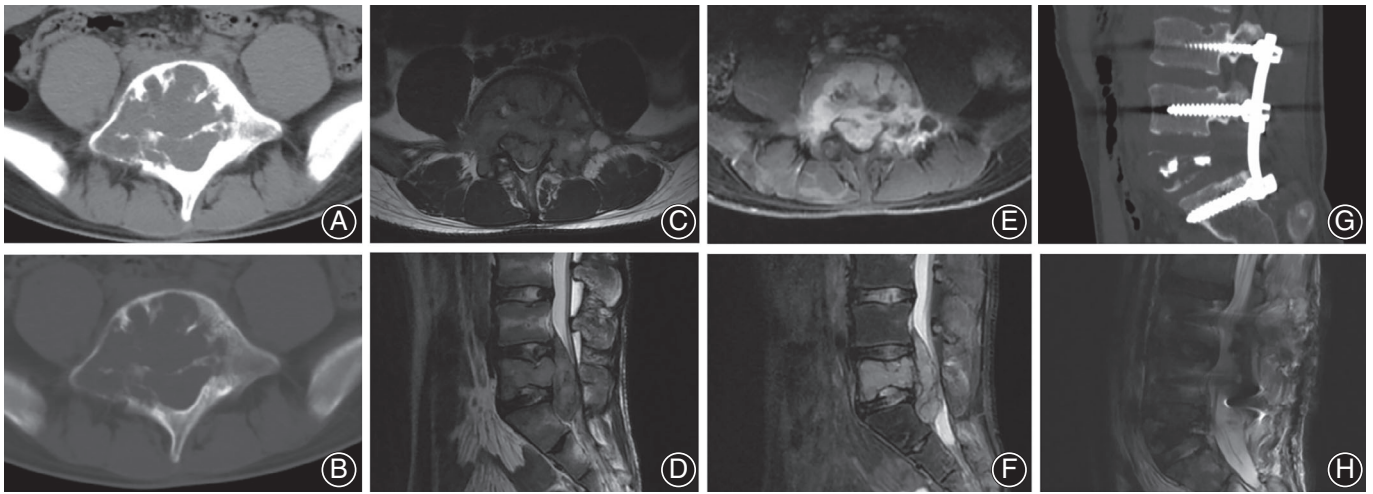
#### Imaging acquisition

All 62 patients underwent preoperative CT examination; 47 patients also underwent MR examination. CT was performed using a GE LightSpeed 64 Slice spiral CT scanner (GE Medical System, Chalfont St Giles, UK) or a Siemens SOMATOM

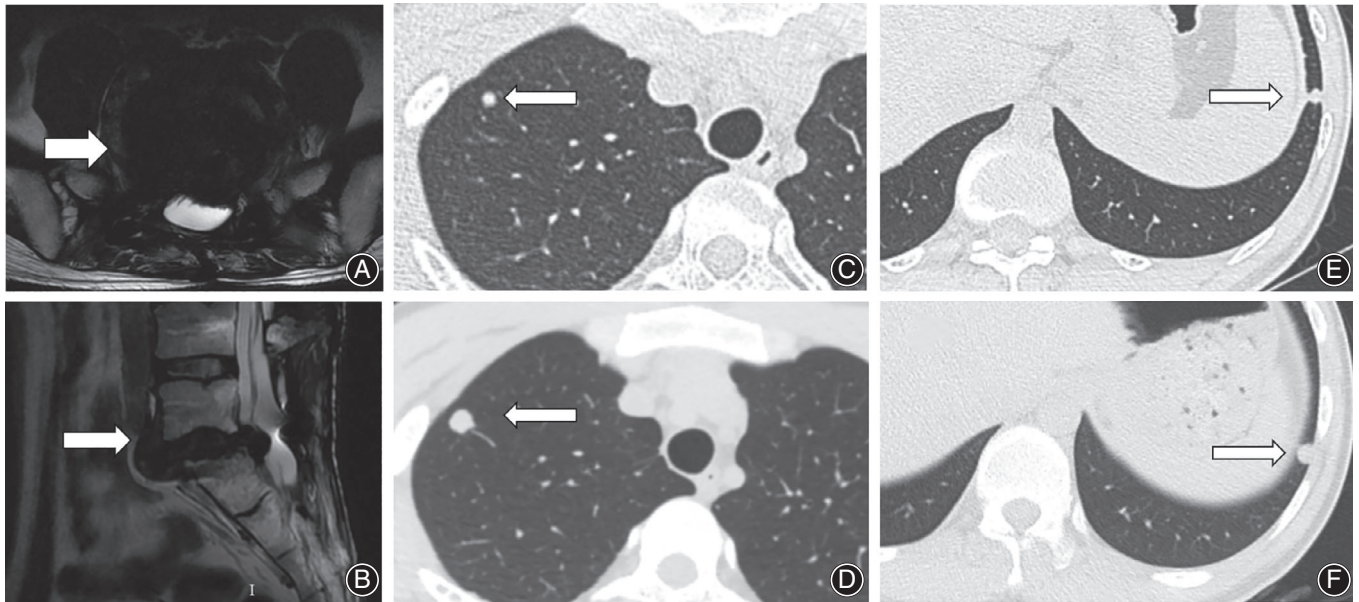


**Fig. 1** Flowchart of the enrolled patients. GCTB, giant cell tumor of bone; MRI, magnetic resonance imaging; CT, computed tomography.





**Fig. 2** A 16-year-old man with giant cell tumor of L<sub>5</sub>. (A, B) Axial CT images, bony septa are seen at the border of the tumor. (C, D) T2 weighted MRI showed an expansile mass with heterogeneous low-to-iso signal intensity with cystic areas. (E, F) Enhanced MRI shows obvious lesion enhancement. (G, H) Managed with intralesional spondylectomy.

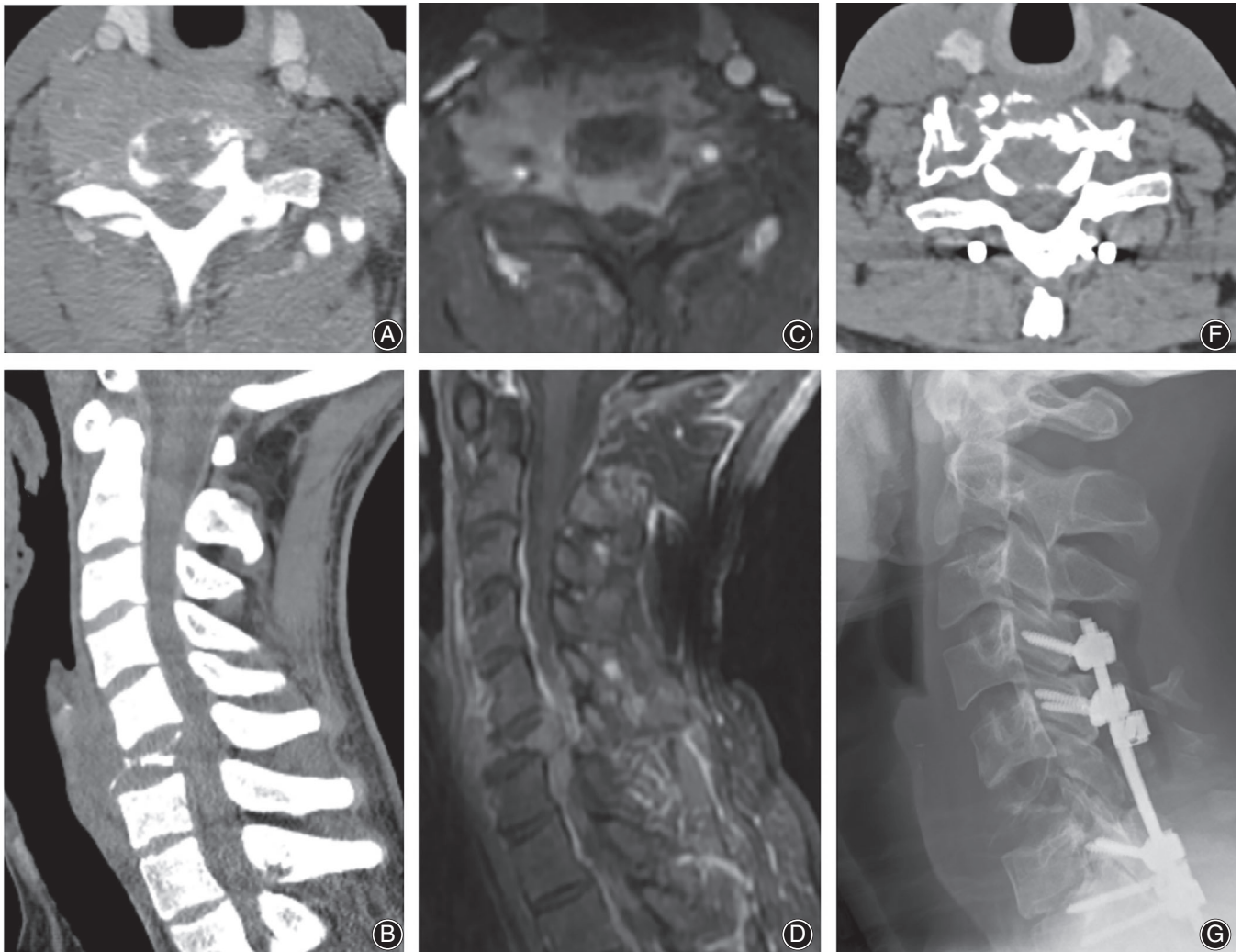


**Fig. 3** T2-weighted MR image (A, B) at 14-month follow-up, local recurrence was detected, and confirmed by pathology with puncture. Lung metastases (C–F) were discovered after 18 months and progressed during follow-up.

Definition Flash dual-source CT scanner (Siemens, Erlangen, Germany). The collimator widths were 0.625 and 0.60 mm, respectively, and the pitch was 1.0; the slice thickness of reconstruction was 3 mm, and interlayer distance was 3 mm.

MR examinations were performed on Siemens Trio 3.0 Tesla(T) MR scanner (2008–2013) and a GE Discovery MR750 3.0T scanner (2013–2018), using a similar protocol. When changing the scanner from Siemens to GE, one major requirement was to make the image contrast and quality of the GE scanner consistent with those of the Siemens scanner.

The scanning sequence and parameters were: sagittal T1-weighted imaging (T1WI) sequence, TR = 550 ms, TE = 11 ms; sagittal T2WI sequence, TR = 2800 ms, TE = 109 ms; sagittal T2-weighted imaging (T2WI) with fat suppression (FS) sequence, TR = 3440 ms, TE = 102 ms; FOV = 280 mmc × 280 mm; axial T2WI sequence, TR = 504 ms, TE = 14 ms, FOV = 160 mm × 160 mm; thickness = 3 mm, spacing = 0.3 mm, with body surface coil. Axial and sagittal scanning was routinely performed, and coronary scanning was added when necessary.



**Fig. 4** A 24-year-old man, (A, B) sagittal and axial CT images showed destruction area of C6 vertebra with obvious vertebral compression. (C, D) MRI images showed the lesion with extension into the spinal canal is mainly located in the vertebral body. (E, F) The patient managed with intralesional spondylectomy by post-access surgery. Bilateral lamina and right side attachment were removed and internally fixed, during the 5-year follow-up period, there was no evidence of recurrence, and now the patient is still on visit.

### **Imaging analysis methods**

Two musculoskeletal radiologists with more than 10 years of diagnostic experience evaluate the images and were blinded to the clinical data of the patients. When the two observers disagreed, agreement was reached through consultation.

### **CT imaging features**

The parameters interpreted and measured in CT images are defined as follows.

#### **Main Position of the Lesion**

The location of the lesion may be related to the prognosis of the patient. According to the lesion mainly located in the vertebral body or vertebral arch, it is divided into vertebral

body/vertebral arch. Note whether the center of the lesion is located in the posterior element.

#### **Compression Fracture**

Using Genant visual semi-quantitative determination method: the height of the most obvious compressed vertebral body is compared with the posterior height of the same vertebral body; if the entire vertebral body is compressed, the height of the most obvious compressed vertebral body is compared with the posterior height of the adjacent vertebral body. When the lesion meets one of the above conditions, it is classified as compression fracture. Vertebral compression indicates that the spine is unstable and may have a worse prognosis compared to patients without compression, so this sign needs to be analyzed.

### *Lesion Boundary*

The boundary of the lesion is a common evaluation criterion for tumor-related lesions, which represents the invasion of adjacent structures by the tumor. According to whether the tumor boundary can be clearly defined, the cases are divided into clear/unclear. Whether it is on the soft tissue window or the bone window, only when the boundary of the lesion can be clearly delineated, can it be determined that the lesion has a clear boundary.

### *Expansile Mass*

If the tumor has an osteolytic and expansile lesion with a “bubble” lytic appearance, it is defined as an expansive growth mass. This sign should be combined with a comprehensive assessment of the axial, sagittal and coronal CT imaging, and compare the lesion side and the healthy side. When it is found that the bone cortex of the lesion is more swollen, it is defined as a positive sign. According to clinical experience, the expansile mass may represent a benign biological behavior and may indicate a better prognosis, but this requires more research support.

### *Bony Septa Inside the Lesion*

Bone septa is defined as the remaining bone tissue around the tumor, which is elongated and protrudes from the cortex of the vertebral body. It is necessary to combine multi-directional CT to find whether there is a strip of residual bone in the lesion connected with the peripheral bone cortex of the lesion. Some clinicians believe that the small number of bony septa inside the lesion indicates that the tumor is more aggressive.

### *A Paravertebral Soft Tissue Mass*

When the tumor has completely broken through the vertebral body, the tumor will invade adjacent structures and form paravertebral soft tissue masses. The uniform or uneven soft tissue density next to the diseased vertebral body can be observed on CT. The appearance of a soft tissue mass indicates that the tumor is growing actively.

### *CT Value*

CT value of the lesion was measured using a manual region of interest (ROI), excluding regions with calcification, obvious necrosis, and hemorrhage. If the difference between the measured values of the two observers exceeds 10 HU (Hounsfield unit), the measurement should be performed again. Take the average of the measured values of two observers for analysis.

### *The Largest Diameter*

First, select the layer with the largest section of the lesion on the axial and sagittal CT images, and then measure the largest diameter of this section to obtain two measured values. Finally, the larger diameter of the axial and sagittal positions is selected as the largest diameter of the lesion. The average of the maximum tumor diameter from the two observers

were used in the analysis. Generally speaking, there is no close relationship between the degree of malignancy of a tumor and the size of the tumor. The most important thing is to observe the biological behavior of the tumor to determine its degree of malignancy and prognosis. But under normal circumstances, the more active the tumor grows, the more likely it is to cause invasion of surrounding tissues, which may affect the prognosis.

### *MRI features*

For MRI, the lesion signals on T1-weighted imaging (WI), T2-WI, and T2-WI fat suppression (FS) sequences were analyzed on preoperative MRI. The definitions of the eight MRI features we interpreted are introduced as follows.

#### *Uniform Lesion Signal*

If the signal of the lesion is uniform, it is defined as positive, if there are two or more different MRI signals inside the lesion, it is considered as negative. The uniform signal indicates that the composition of the tumor tissue is more consistent. On the contrary, it means that the composition of the diseased tissue is complicated, which may interfere with the diagnosis.

#### *Signal Intensity*

The signal intensity of the lesion on T1-WI and T2-WI were evaluated by comparing it to the intensity of the spinal cord, and determining the intensity as “low,” “iso,” or “slightly high” when the intensity of the lesion was lower than, equal to, or slightly higher than that of the spinal cord, respectively. For the signal intensity of the lesion on T2-WI FS, because the signal of cerebrospinal fluid (CSF) was higher than that of the spinal cord, we added one more category as “high” when the intensity of the lesion was comparable to that of the CSF on T2-WI FS.

#### *Spinal Canal Involvement*

The corresponding segment of the dural sac caused by the tumor is compressed, and the diameter of the spinal canal is shortened, which can be comprehensively evaluated on the sagittal and axial T2-WI sequence. This sign indicates that the tumor has caused compression of the nerve structure in the spinal canal, which is related to the postoperative prognosis of patients.

#### *Nerve Root Compression*

On the T2-WI sequence, it can be observed whether the nerve root is compressed by the tumor. If the nerve root is closely related to the tumor, it can be defined as the nerve root compression, which may affect the movement and sensation of the corresponding area of the patient after surgery.

#### *Fluid-fluid Levels*

If the different signal levels inside the lesion are observed on the T2-WI FS sequence, it can be clear that the sign is positive. This sign appears in the lesion to indicate the occurrence



of cystic degeneration. This sign that appears in the cystic area may be caused by the deposition of necrotic tissue debris or blood cells, which can vary with body position. On T1WI, the signal in the lower part is often higher than that in the upper part, while the T2WI sequence is the opposite.

#### *Intralesional Hemorrhage*

The accuracy and feasibility of MRI scanning on determination of hemorrhage inside the tumor. High signal in T1-WI sequence inside the lesion indicates bleeding in the lesion. If there are hemosiderin deposits in the tumor, the signal is low on T1WI and T2WI.

#### *Statistical Analysis*

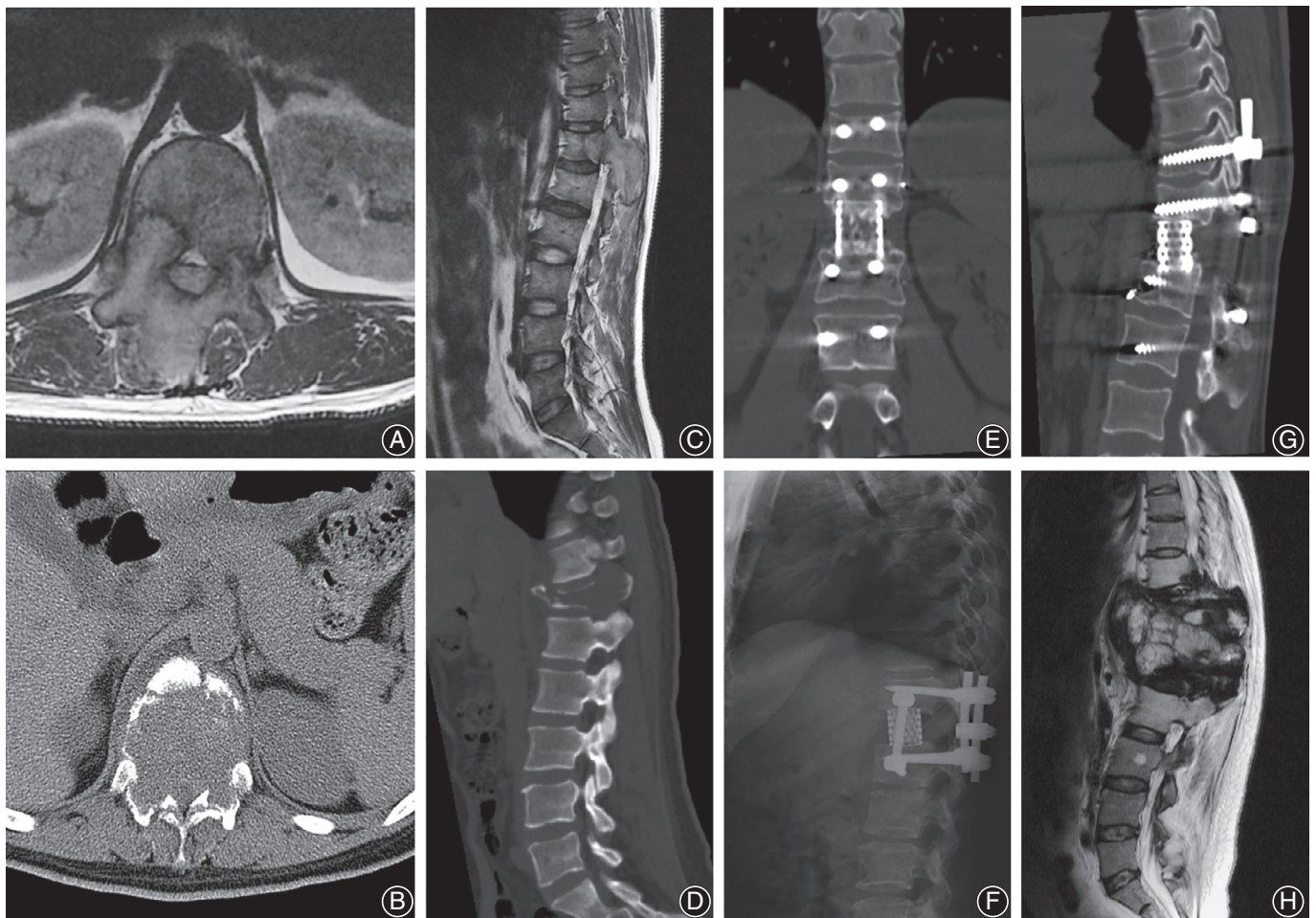
SPSS 18.0 software (IBM, Armonk, NY, USA) was used for statistical analysis. Continuous measurement variables are expressed as mean  $\pm$  standard deviation, and an independent-

samples *t*-test was used for group comparisons. For categorical count data, the  $\chi^2$  test was used to compare the difference between the recurrence group and the non-recurrence group. Features showing significant differences in the univariate analysis were included in the multivariate logistic regression model to identify independent risk factors for postoperative recurrence. A *P* value  $< 0.05$  was considered statistically significant. Receiver operating characteristic (ROC) curve analysis was performed to determine the optimal cutoff value of the largest lesion diameter predicting recurrence after surgery. Two cases in our study cohort are shown in Fig. 5.

## Results

#### *Baseline Demographic and Clinical Characteristics*

The mean follow-up time of these 62 patients was 73.66 ( $\pm 32.92$ ) months. According to whether the disease recurred



**Fig. 5** Top panel: A 35-year-old man, sagittal (A) and axial (B) MR images showed a mass on the T<sub>12</sub> vertebra, bilateral pedicle and lamina with extension into the spinal canal, maximum diameter of lesion is 42 mm, managed with *en bloc* resection (C), at a 36-month follow-up review, there was no evidence of recurrence (D). Bottom panel: A 35-year-old woman, sagittal CT images showed maximum diameter of lesion is 55 mm (E), with pathologic fracture of the T<sub>12</sub> vertebra (F), managed with *en bloc* resection (G), sagittal MR image showed tumor of both vertebral body and posterior element of T<sub>12</sub>. The sagittal T2-weighted MR image at 12-month follow-up, recurrence was detected (H), and confirmed by pathology with puncture.



**TABLE 1 Baseline demographic and clinical characteristics of patients with and without recurrence (n = 62)**

Characteristics	Non-recurrence group (n = 45)	Recurrence group (n = 17)	t/ $\chi^2$ value	P value
Age (years)	31.93 ± 14.01	32.74 ± 10.78	0.221	0.826
Gender			0.295	0.587
Male	22 (49%)	7 (41%)		
Female	23 (51%)	10 (59%)		
Location			1.959	0.581
Cervical spine	15 (33%)	6 (35%)		
Thoracic spine	18 (40%)	5 (29.5%)		
Lumbar spine	7 (16%)	5 (29.5%)		
Sacral spine	5 (11%)	1 (6%)		
Multi-vertebral involvement			1.393	0.238
No	43 (96%)	14 (82%)		
Yes	2 (4%)	3 (18%)		
Treatment			1.122	0.571
Total <i>en bloc</i> spondylectomy	20 (45%)	6 (35%)		
Piecemeal spondylectomy	15 (33%)	5 (30%)		
Other treatments	10 (22%)	6 (35%)		

within the 2-year follow-up period, patients were divided into the recurrence group ( $n = 17$ ) and the non-recurrence group ( $n = 45$ ). The postoperative recurrence rate was 27.4%. For all analyzed demographic and clinical characteristics, including age ( $P = 0.826$ ), gender ( $P = 0.587$ ), lesion location ( $P = 0.581$ ), multi-vertebral involvement ( $P = 0.238$ ) and treatment methods ( $P = 0.571$ ), there was no significant difference between the recurrence group and the non-recurrence group (Table 1).

### Preoperative CT Imaging Features

A total of eight CT imaging features were analyzed (Table 2). The largest lesion diameter [(4.68 ± 1.79) vs (5.92 ± 2.17) cm,  $t = 2.287$ ,  $P = 0.026$ ] and the presence of vertebral compression fracture (51% vs 82%,  $\chi^2 = 5.005$ ,  $P = 0.025$ ) were significantly different between the non-recurrence and recurrence groups. When we set the cutoff value for the largest lesion diameter at

4.2 cm, the sensitivity and specificity for distinguishing the recurrence and non-recurrence of GCTB were 94.1% and 42.2%, respectively, and the area under the curve (AUC) was 0.671. In addition, the difference in CT value between the two groups is very small [(48.89 ± 9.67) vs (47.08 ± 8.11) HU,  $P = 0.495$ ]. In the non-recurrence group and the recurrence group, there was no statistical difference in the proportion of the main tumor in the vertebral body or vertebral attachment (76% vs 88%,  $P = 0.274$ ). In addition, whether the boundary of the lesion is unclear (93% vs 88%,  $P = 0.839$ ), whether it is accompanied by residual bone septa (62% vs 71%,  $P = 0.539$ ), and whether the performance of expansive growth (87% vs 94%,  $P = 0.706$ ) are not statistically different between the two groups. The incidence of paravertebral soft tissue masses is very high (96% vs 100%,  $P = 0.539$ ), but the difference between the non-recurrence and the recurrence group was not statistically significant.

**TABLE 2 CT imaging characteristics of patients with and without recurrence (N = 62)**

Imaging characteristics	Non-recurrence group (n = 45)	Recurrence group (n = 17)	t/ $\chi^2$ value	P value
CT value (HU)	48.89 ± 9.67	47.08 ± 8.11	0.687	0.495
Largest diameter of the lesion (cm)	4.68 ± 1.79	5.92 ± 2.17	2.287	0.026
Position			0.554	0.274
Vertebral body	34 (76%)	15 (88%)		
Vertebral arch	15 (24%)	2 (12%)		
Vertebral compression			5.005	0.025
Negative	22 (49%)	3 (18%)		
Positive	23 (51%)	14 (82%)		
Boundary			0.018	0.839
Unclear	42 (93%)	15 (88%)		
Clear	3 (7%)	2 (12%)		
Expansile mass			0.142	0.706
No	6 (13%)	1 (6%)		
Yes	39 (87%)	16 (94%)		
Bony septa			0.377	0.539
Negative	17 (38%)	5 (29%)		
Positive	28 (62%)	12 (71%)		
Paravertebral soft tissue mass			0.006	0.938
Negative	2 (4%)	0 (0%)		
Positive	43 (96%)	17 (100%)		

**TABLE 3 MRI characteristics of patients with or without recurrence (n = 47)**

Imaging characteristics	Non-recurrence group (n = 34)	Recurrence group (n = 13)	t/ $\chi^2$ value	P value
Uniform lesion signal			0.122	0.727
Negative	22 (65%)	7 (54%)		
Positive	12 (35%)	6 (46%)		
T1-WI signal			0.007	0.932
Low	2 (6%)	0 (0%)		
Iso	32 (94%)	13 (100%)		
T2-WI signal			0.910	0.635
Low	2 (6%)	0 (0%)		
Iso	26 (76%)	10 (77%)		
Slightly higher	6 (18%)	3 (23%)		
T2-WI FS signal			0.753	0.686
Iso	6 (18%)	1 (8%)		
Slightly higher	26 (76%)	11 (84%)		
High	2 (6%)	1 (8%)		
Spinal canal involvement			1.284	0.257
Negative	6 (18%)	0 (0%)		
Positive	28 (82%)	13 (100%)		
Nerve root compression			0.502	0.479
Negative	4 (12%)	0 (0%)		
Positive	30 (88%)	13 (100%)		
Fluid–fluid levels			0.212	0.646
Negative	32 (94%)	11 (85%)		
Positive	2 (6%)	2 (15%)		
Intralesional hemorrhage			0.502	0.479
Negative	30 (88%)	13 (100%)		
Positive	4 (12%)	0 (0%)		

**TABLE 4 Logistic regression analysis of postoperative recurrence predictive features**

Features	Partial regression coefficient	SE	Wald value	OR value	95%CI	P value
Largest diameter (cm)	0.460	0.182	6.369	1.584	1.108–2.264	0.012
Vertebral compression	2.088	0.865	5.827	8.073	1.481–11.003	0.016

### Preoperative MRI Features

A total of eight MRI features were analyzed (Table 3). In the non-recurrence group, the proportion of patients with uneven signals in the lesions (22/34, 65%) on the T1-WI, T2-WI and T2-WI FS sequences, was slightly higher than that in the recurrence group (7/13, 54%), but it was not statistically significant ( $P = 0.727$ ), so it was of little significance for prognostic evaluation. The two groups of patients are mainly iso signals (45/47, 95.7%) in the T1-WI sequence, iso signals (36/47, 76.6%) in the T2-WI sequence, and slightly higher signals (37/47, 78.7%) in the T2-WI FS sequence. The signal intensity of these sequences has no statistical difference between the non-recurrence group and the recurrence group. All 13 cases of recurrence had spinal canal involvement and nerve root compression. These two characteristics appear in a high proportion in the non-recurrence group, 82% and 88%, respectively. The difference between the two groups was not statistically significant ( $P = 0.257$  and  $P = 0.479$ , respectively). Fluid-fluid levels appear more in the recurrence group (15% vs 6%,  $P = 0.646$ ), and intralesional hemorrhage appear more in the non-recurrence group (12% vs 0%,  $P = 0.479$ ), but both

these two imaging features are not risk factors for local recurrence ( $P > 0.05$ ).

### Multivariate Logistic Regression Analysis

Significant features, including vertebral compression and largest lesion diameter, were included in the multivariate logistic regression model. Multivariate analysis demonstrated that the independent risk factors of recurrent spinal GCTB were largest diameter (odds ratio [OR], 1.584; 95% confidence interval [CI], 1.108–2.264) and vertebral compression (OR, 8.073; 95% CI, 1.481–11.003). The  $P$  values were 0.012 and 0.016, respectively. The sensitivity, specificity, and accuracy of the model were 47.1%, 97.8% and 83.9%, respectively (Table 4).

### Discussion

Predicting the prognosis of GCTB in the spine is a complex and difficult problem. How to use more effective personalized treatment plans to improve the prognosis of patients is an unmet clinical problem that needs to be addressed. Due to the dense distribution of spinal blood

vessels and nerves, complete surgical resection may not be possible, and the postoperative recurrence rate of spinal GCTB is high. In recurrent patients, disease progression often leads to a poor quality of life<sup>6</sup>. To date, there has not been a consensus guideline regarding the risk stratification criteria for patients with spinal GCTB. It is difficult for surgeons to accurately predict the risk of recurrence, so the optimal surgical procedures can be planned accordingly. In addition to choosing surgical procedures, whether adjuvant therapy, including chemotherapy and radiation therapy, is necessary also needs to be determined. In this study, we explored the predictive value of preoperative imaging for postoperative recurrence by analyzing the imaging characteristics of patients before surgery.

### **Surgical Approach and Recurrence**

Many other factors are still controversial on the prognosis of spinal GCTB, among which surgical methods are paid more attention. In previous studies, total vertebral resection was a more thorough surgical method, which improves treatment outcomes<sup>15,16</sup>. According to the findings of Charest-Morin *et al.*, *en bloc* resection with wide/marginal margins is associated with decreased local recurrence (LR), while intralesional resection is associated with increased LR<sup>17</sup>. But some researchers believe that the choice of preoperative surgical methods is affected by many factors and should be carefully considered. When facing the risk of serious complications, according to the proposed surgical resection classification, adolescent patients undergoing conservative nerve-sparing surgery for GCTB have acceptable clinical efficacy and neurological function<sup>18</sup>. Lin *et al.* found that surgical methods (no surgery, local excision and gross total resection) were not significantly associated with OS after adjusting for the available clinical variables<sup>19</sup>. In the present study, the recurrence rate of patients who underwent non-total vertebral resection was 44%, which was higher compared with patients who underwent total *en bloc* spondylectomy (30%), but this difference was not statistically significant; therefore, the surgical procedure was not a predictive factor between the recurrence and non-recurrence groups according to our research. In patients with low invasiveness or low level of malignancy, it is feasible to choose less aggressive surgical methods to preserve nerve function and avoid a compromising prognosis. Some researchers analyzed the impact of previous surgical history on postoperative recurrence<sup>17</sup>. Since our cohort were patients who underwent surgery for the first time without a previous history of surgery, we cannot evaluate the influence of the history of surgery on the prognosis, but at the same time our conclusions are not hampered by this factor.

### **Demographic and Clinical Characteristics**

In our study, sex, age, and lesion location were not related to postoperative recurrence. In previous studies, some researchers (but not others) reported that age affected postoperative recurrence<sup>20,21</sup>. For example, some studies believe that

patients younger than 55 years old and tumor location in the sacrum/coccyx were associated with poor prognosis<sup>22</sup>, but there are also research results that indicate tumor location in the cervical spinal is a risk factor for local recurrence, but age was not a significant risk factor for recurrence or death<sup>23</sup>. The different results might be due to the small sample size. Furthermore, age might be a factor when considering surgical procedures; thus, age is not an independent predictor.

### **CT Radiographic Findings**

Spinal GCTB is usually located in the vertebral body, but it is rarely observed in the vertebral body without involving the pedicle and lamina, or only in the vertebral arch<sup>24</sup>. Of the 62 patients in this study, 49 cases (79%) of GCTB were located in the vertebral body and 13 cases (21%) in the posterior element. This helps distinguish GCTB from osteoblastomas, primary aneurysmal bone cysts and tendon sheaths that are often located in the posterior. Although the percentage of cases of GCTB in the vertebral body was higher in the recurrent group (15/17, 88%) compared with the non-recurrent group (34/45, 76%), this difference was not significant. This also means that we cannot assess the benign or malignant biological behavior of the tumor by whether the tumor is located in the anterior vertebral body or the posterior element. Some researchers observed nine cases of spinal GCTB with multiple vertebral body invasion and found that the main primary lesions were all located in the vertebral body, and more invasive in the posterior part of adjacent vertebral bodies. However, they did not report the recurrence of these patients. In our research, we also analyzed the lesion boundary, expansibility, and the presence of residual bone crests, and we found no correlation between these parameters and recurrence. Most lesions showed swelling growth, and the boundary was not clear, which is consistent with previous research results<sup>25</sup>. These features can help us diagnose spinal GCTB, but are of limited use in assessing postoperative recurrence. Li *et al.* reported that the paravertebral soft tissue erosion is related to recurrence<sup>26</sup>. In their study, higher risk of local recurrence was found for soft tissue extension (hazard = 7.921, 95% CI 1.107 ~ 56.671), and the RFS (recurrence-free survival) of pathologic fracture patients with soft tissue extension was significantly lower than that of pathologic fracture patients without soft tissue extension. In our study, although the soft tissue mass was found in all recurrent patients (17/17), it was also seen in the majority of non-recurrent patients (43/45, 96%); thus, it is not a predictor. The difference in conclusions in this aspect may be due to the difference between cases that occur in the limbs and spine cases. This may also be caused by Berkson's bias, which can be minimized in a multi-center large sample study.

### **MRI Manifestations**

MRI signals can provide more detailed tissue information about the lesion and the surrounding bone marrow, edema, and CSF, which can be differentiated on images acquired

using different pulse sequences. Although the features of GCTB of the extremities have been well described in the literature, there are few reports for MRI of spinal lesions. These studies are limited to case reports and a few general reviews of spinal lesions. Our study shows that spinal GCTB presents as an intermediate signal intensity on T1-WI sequences. Generally, the solid components of GCTB demonstrate intermediate or slightly higher signal intensity on T2-WI images, and the slightly higher signal is dominant in T2-WI FS signals, often involving the spinal canal and accompanied by nerve root compression<sup>27</sup>. Although MRI can provide additional information about the lesion, it is helpful for tumor diagnosis but has little significance for predicting the recurrence of vertebral GCTB after surgery. Previous studies have not found any conclusions about the prognosis of different tumor signals in MRI. GCTB is generally considered as a highly vascularized tumor with a rich blood supply, which can cause intralesional hemorrhage and necrosis. In previous studies of giant cell tumor of limb bone, some researchers found a significant difference in the proportion of patient with cystic necrosis with recurrence<sup>28</sup>. In this study, we analyzed whether the lesions involved the spinal canal or nerve root, and whether there was fluid-fluid level or hemorrhage were related to postoperative recurrence. The results showed that fluid-fluid level and hemorrhage were rare in GCTB, and no correlation was observed with postoperative recurrence, consistent with previous findings<sup>29</sup>. The different results between the spine and the extremities may reflect their intrinsic differences due to the surrounding bone structures, and also could be due to the small sample size.

### Significant Recurrence Predictors

There were two significant recurrence predictors in our study, one was vertebral compression and the other was the largest lesion (>4.2 cm). When the vertebral body is invaded by tumor cells, the structure of bone trabecula or bone cortex becomes weakened, resulting in vertebral body compression fracture. Therefore, the degree of compression can reflect tumor invasion<sup>30</sup>. In previous studies, some researchers have come to the same conclusion, but they are not purely aimed at spine cases, but are drawn from the analysis of pathological fractures through Cox regression analysis<sup>31</sup>. They consider soft tissue extension as the independent variable that contributed to recurrence-free survival<sup>26</sup>. Our results suggest that when vertebral compression present, more thorough surgery or surgery combined with adjuvant therapy should be considered to reduce postoperative recurrence and improve survival. Previous studies suggested that spinal GCTB might appear more radiologically

atypical, and about 40% of the lesions may have at least one atypical feature. However, this study did not focus on postoperative recurrence<sup>32</sup>. Our study found that the lesions with compression fractures have higher risks of postoperative recurrence. This conclusion has greater significance for the clinical personalized diagnosis and treatment of spinal GCTB. Another aspect of the research results, larger tumors may indicate active proliferation, and the surrounding structures are more likely to be involved. In addition to being more aggressive, large tumors can be difficult to completely resect, and the residual tumor may lead to recurrence. This association between tumor size and recurrence was not found in any previous studies on appendicular GCTB<sup>33</sup>. It should be highlighted that due to the difference between the extremities and the spine, the surgical methods differed, and the results could not be directly comparable.

### Limitations

There were several limitations in this study. First, this retrospective study was performed at a single center. Although the sample size was greater than most previous related studies, selection bias should be considered. Second, we did not analyze the patient's enhanced CT performance because of the sample size of that (32 cases) was smaller than the sample size for plain CT (62 cases) and MRI (47 cases). However, with the higher rate of GCTB in Asia compared with Western countries, this dataset could provide unique information that is otherwise difficult to obtain. Third, we only analyzed the recurrence within 2 years; this was based on a large number of studies showing that the recurrence of GCTB usually occurs within 2 years<sup>34</sup>. We also observed that most cases of recurrence happened within 2 years at our hospital. Nonetheless, some patients continued with follow up, which may provide longer term prognostic results for future research.

### Conclusions

The largest tumor diameter and the vertebral compression are independent predictors of tumor recurrence after surgery, which may provide more helpful information for the development of personalized treatment plans, including the choice of optimal surgical procedure and adjuvant therapy to reduce the risk of recurrence and improve the quality of life for patients with spinal GCTB.

### Acknowledgments

This study received funding from the National Natural Science Foundation of China (81971578, 81871326), and the Key Clinical Projects of the Peking University Third Hospital (BYSY2018007).

### References

1. Goldenberg RR, Campbell CJ, Bonfiglio M. Giant-cell tumor of bone. An analysis of two hundred and eighteen cases. *J Bone Joint Surg Am*, 1970, 52: 619–664.
2. Wuelling M, Dellling G, Kaiser E. Differential gene expression in stromal cells of human giant cell tumor of bone. *Virchows Arch*, 2004, 445: 621–630.
3. Wüiling M, Dellling G, Kaiser E. The origin of the neoplastic stromal cell in giant cell tumor of bone. *Hum Pathol*, 2003, 34: 983–993.
4. Zambo I, Vesely K. WHO classification of tumours of soft tissue and bone 2013: the main changes compared to the 3rd edition. *Cesk Patol*, 2014, 50: 64–70.
5. Martin C, McCarthy EF. Giant cell tumor of the sacrum and spine: series of 23 cases and a review of the literature. *Iowa Orthop J*, 2010, 30: 69–75.
6. Siebenrock KA, Unni KK, Rock MG. Giant-cell tumour of bone metastasising to the lungs. A long-term follow-up. *J Bone Joint Surg Br*, 1998, 80: 43–47.



7. Kremen TJ Jr, Bernthal NM, Eckardt MA, Eckardt JJ. Giant cell tumor of bone: are we stratifying results appropriately. *Clin Orthop Relat Res*, 2012, 470: 677–683.
8. Wang H, Wan N, Hu Y. Giant cell tumour of bone: a new evaluating system is necessary. *Int Orthop*, 2012, 36: 2521–2527.
9. Prosser GH, Baloch KG, Tillman RM, Carter SR, Grimer RJ. Does curettage without adjuvant therapy provide low recurrence rates in giant-cell tumors of bone. *Clin Orthop Relat Res*, 2005; 435: 211–218.
10. Kumta SM, Huang L, Cheng YY, Chow LT, Lee KM, Zheng MH. Expression of VEGF and MMP-9 in giant cell tumor of bone and other osteolytic lesions. *Life Sci*, 2003, 73: 1427–1436.
11. Quattrini I, Pollino S, Pazzaglia L, et al. Prognostic role of nuclear factor/IB and bone remodeling proteins in metastatic giant cell tumor of bone: a retrospective study. *J Orthop Res*, 2015, 33: 1205–1211.
12. Hatano Y, Nakahama K, Isobe M, Morita I. Tumor associated osteoclast-like giant cells promote tumor growth and lymphangiogenesis by secreting vascular endothelial growth factor-C. *Biochem Biophys Res Commun*, 2014, 446: 149–154.
13. Yalcinkaya U, Ugras N, Kabul S, Ocakoglu G, Bilgen MS. Prognostic value of p53 protein expression in giant cell tumor of bone. *Pol J Pathol*, 2015, 66: 389–396.
14. Okubo T, Saito T, Mitomi H, et al. p53 mutations may be involved in malignant transformation of giant cell tumor of bone through interaction with GPX1. *Virchows Arch*, 2013, 463: 67–77.
15. Yokogawa N, Murakami H, Demura S, et al. Total spondylectomy for Enneking stage III giant cell tumor of the mobile spine. *Eur Spine J*, 2018, 27: 3084–3091.
16. Jia Q, Chen G, Cao J, et al. Clinical features and prognostic factors of pediatric spine giant cell tumors: report of 31 clinical cases in a single center. *Spine J*, 2019, 19: 1232–1241.
17. Charest-Morin R, Fisher CG, Varga PP, et al. En bloc resection versus Intralesional surgery in the treatment of giant cell tumor of the spine. *Spine (Phila Pa 1976)*, 2017, 42: 1383–1390.
18. Wang J, Du Z, Yang R, Tang X, Yan T, Guo W. Analysis of clinical outcome for adolescent patients undergoing conservative nerve-sparing surgery based on the proposed resection classification for sacral giant cell tumor. *J Clin Neurosci*, 2020, 80: 23–29.
19. Lin JL, Wu YH, Shi YF, et al. Survival and prognosis in malignant giant cell tumor of bone: a population-based analysis from 1984 to 2013. *J Bone Oncol*, 2019, 19: 100260.
20. Yin H, Yang X, Xu W, et al. Treatment and outcome of primary aggressive giant cell tumor in the spine. *Eur Spine J*, 2015, 24: 1747–1753.
21. Siddiqui MA, Seng C, Tan MH. Risk factors for recurrence of giant cell tumours of bone. *J Orthop Surg (Hong Kong)*, 2014, 22: 108–110.
22. Patel S, Chiu RG, Rosinski CL, et al. Incidence, management, and outcomes of spinal giant cell tumor of bone in adult patients: a National Cancer Database Analysis. *World Neurosurg*, 2020, 144: e296–e305.
23. Ouyang HQ, Jiang L, Liu XG, et al. Recurrence factors in giant cell tumors of the spine. *Chin Med J (Engl)*, 2017, 130: 1557–1563.
24. Klenke FM, Wenger DE, Inwards CY, Rose PS, Sim FH. Giant cell tumor of bone: risk factors for recurrence. *Clin Orthop Relat Res*, 2011, 469: 591–599.
25. Si MJ, Wang CG, Wang CS, et al. Giant cell tumours of the mobile spine: characteristic imaging features and differential diagnosis. *Radiol Med*, 2014, 119: 681–693.
26. Li D, Zhang J, Li Y, et al. Surgery methods and soft tissue extension are the potential risk factors of local recurrence in giant cell tumor of bone. *World J Surg Oncol*, 2016, 14: 114.
27. Shi LS, Li YQ, Wu WJ, Zhang ZK, Gao F, Latif M. Imaging appearance of giant cell tumour of the spine above the sacrum. *Br J Radiol*, 2015, 88: 20140566.
28. He Y, Zhou Y, Zhang J, et al. Tumor immunohistochemistry and preoperative magnetic resonance imaging features predict local recurrence of giant cell tumor of bone following intralesional curettage. *Oncol Lett*, 2019, 17: 1425–1434.
29. He Y, Wang J, Zhang J, Yuan F, Ding X. A prospective study on predicting local recurrence of giant cell tumour of bone by evaluating preoperative imaging features of the tumour around the knee joint. *Radiol Med*, 2017, 122: 546–555.
30. Hibberd CS, Quan GMY. Risk factors for pathological fracture and metastatic epidural spinal cord compression in patients with spinal metastases. *Orthopedics*, 2018, 41: E38–E45.
31. Jiang G, Sun LL, Ye YJ, et al. Giant cell tumors of the mobile spine with invasion of adjacent vertebrae: an unusual imaging finding. *BMC Musculoskelet Disord*, 2021, 22: 726.
32. Yuan B, Zhang LH, Yang SM, et al. Imaging features of aggressive giant cell tumors of the mobile spine: retrospective analysis of 101 patients from single center. *Global Spine J*, 2021. <https://doi.org/10.1177/2192568220982280>.
33. Jeys LM, Suneja R, Chami G, Grimer RJ, Carter SR, Tillman RM. Impending fractures in giant cell tumours of the distal femur: incidence and outcome. *Int Orthop*, 2006, 30: 135–138.
34. Montgomery C, Couch C, Emory CL, Nicholas R. Giant cell tumor of bone: review of current literature, evaluation, and treatment options. *J Knee Surg*, 2019, 32: 331–336.