

UCSF

UC San Francisco Previously Published Works

Title

Rapid sequential development and rupture of mycotic aneurysms within a period of days in a patient with graft-versus-host disease and angiotropic *Scedosporium apiospermum* infection

Permalink

<https://escholarship.org/uc/item/8jj521s0>

Authors

Budohoski, Karol P
Raygor, Kunal
Cook, Dan
et al.

Publication Date

2022

DOI

10.25259/sni_970_2021

Peer reviewed



Case Report

Rapid sequential development and rupture of mycotic aneurysms within a period of days in a patient with graft-versus-host disease and angiotropic *Scedosporium apiospermum* infection

Karol P. Budohoski¹, Kunal Raygor¹, Dan Cook², Timothy Henrich³, Adib A. Ablal¹

Departments of ¹Neurosurgery and ²Radiology, University of California San Francisco, ³Department of Medicine, Division of HIV, Infectious Diseases, and Global Medicine, University of California San Francisco, San Francisco, California, Unites States.

E-mail: *Karol P. Budohoski - karol.budohoski@gmail.com; Kunal Raygor - kunal.raygor@ucsf.edu; Dan Cook - daniel.cooke@ucsf.edu; Timothy Henrich - timothy.henrich@ucsf.edu; Adib A. Ablal - adib.abla@ucsf.edu



*Corresponding author:

Karol P. Budohoski,
Department of Neurosurgery,
University of California San
Francisco, San Francisco,
California, Unites States.

karol.budohoski@gmail.com

Received : 25 September 2021

Accepted : 18 May 2022

Published : 10 June 2022

DOI

10.25259/SNI_970_2021

Quick Response Code:



ABSTRACT

Background: Fungal origin mycotic aneurysms are rare and carry a high mortality rate. *Scedosporium apiospermum* is an ubiquitous fungus which has been described to cause devastating infections in immunocompromised hosts.

Case Description: We report a case of a 23-year-old patient with Burkitt's lymphoma and graft-versus-host disease admitted with intracerebral hemorrhage and sequential development of 12 anterior circulation aneurysms from disseminated *Scedosporium* infection. Despite aggressive surgical and antimicrobial treatment, the patient died 6 months later from multiorgan failure. The notable feature of this case is the rapid angioinvasiveness of the infection with new aneurysm formation within days of clear angiographic imaging despite the apparent lack of skull base osteomyelitis.

Conclusion: We highlight the difficulties in treating fungal mycotic aneurysms and the associated high mortality. While a less aggressive approach might have been appropriate given the known poor outcomes, the age of the patients as well as the family wishes dictated the treatment decisions.

Keywords: Mycotic aneurysm, *Scedosporium apiospermum*, Surgery

BACKGROUND

Fungal origin intracranial aneurysms are an extremely rare pathology, most commonly found in immunocompromised patients. They are typically caused by *Aspergillus* spp.^[8] and have been reported to carry a high mortality rate of around 80%.^[6] *Scedosporium apiospermum* is an ubiquitous filamentous fungus which affects immunocompromised hosts. To date, only ten cases of *S. apiospermum* mycotic aneurysm have been reported.^[1,3,4,7,9-12,14,16] Here, we present a case of rapid, sequential development, and rupture of new mycotic aneurysms in an immunocompromised patient with disseminated *Scedosporium* infection.

This is an open-access article distributed under the terms of the Creative Commons Attribution-Non Commercial-Share Alike 4.0 License, which allows others to remix, transform, and build upon the work non-commercially, as long as the author is credited and the new creations are licensed under the identical terms.

©2022 Published by Scientific Scholar on behalf of Surgical Neurology International

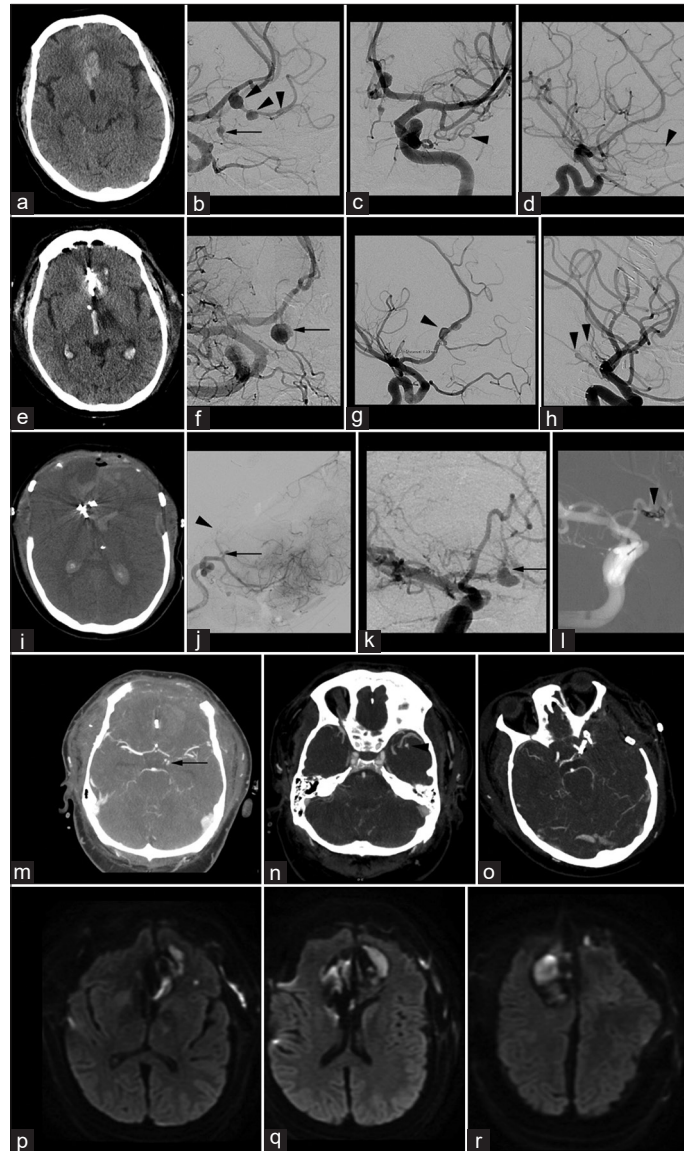


Figure 1: Depiction of the most relevant imaging findings from the patient's treatment. (a) Presentation CT head demonstrating left inferior frontal hemorrhage suspicious of vascular origin, (b-d) initial diagnostic DSA, (b) lateral view of the left ICA injection demonstrating $\times 1$ fusiform aneurysm on the orbitofrontal branch of the left ACA (arrow) and 3 fusiform aneurysms on the frontopolar branch of the left ACA (arrowheads), (c) AP view of the left ICA injection demonstrating fusiform aneurysm at the distal ATA of the left MCA (arrowhead), (d) lateral view of the right ICA injection demonstrating a fusiform aneurysm on the frontopolar branch of the right ACA (arrowhead), (e) CT scan obtained on postbleed day 4 and postoperative day 2 following parent vessel occlusion of the left frontopolar branch of the left ACA demonstrating new IVH and fresh blood in the inferior left frontal lobe suggesting re-bleed, (f-h) DSA obtained following re-bleeding on postbleed day 4, (f) oblique view of the left ICA injection demonstrating interval growth of the untreated left orbitofrontal branch fusiform aneurysm (arrow), (g) lateral view of the right ICA injection showing three new fusiform aneurysms on the A2 segment of the right ACA (arrowhead), (h) AP view of the left ICA injection showing new fusiform aneurysms of the distal AChA and PCOMA (arrowheads), (i and j) postbleed day 8 following further surgery with bilateral A2 occlusion and bifrontal decompression, (i) CT head demonstrating extensive bifrontal decompression and swelling following intraoperative sacrifice of bilateral A2s, (j) intraoperative DSA demonstrating no flow in the left ACA at the A2 segment (arrowhead) with new aneurysm formation at the ACOMA (arrow), (k-l) interval DSA on postbleed day 9, (k) AP injection of the right ICA demonstrating treating growth of the ACOMA aneurysm (arrow), (l) intraprocedural image on postbleed day 9 during parent vessel occlusion of the right A1 to treat the enlarging ACOMA aneurysm (arrowhead), (m) Interval imaging on postbleed day 10 demonstrating growth of the previously identified AChA and PCOMA aneurysms (arrow), (n) interval imaging on postbleed day 10 demonstrating stable ATA aneurysm, (o) postoperative CT head following pterional craniotomy and parent vessel occlusion of the growing AChA and PCOMA aneurysms and the stable ATA aneurysm, and (p-r) follow-up MRI 1 month following initial presentation demonstrating DWI lesions in both ACA territories, although not extensive and not encompassing the whole territories despite occlusion of both A2s and a DWI lesion in the left thalamus in keeping with hypodensities seen on presentation CT.

CASE PRESENTATION

A 23-year-old critically-ill male with history of Burkitt's lymphoma, with graft-versus-host disease (GVHD) requiring high-dose corticosteroids, was admitted to the Emergency Department following a 2 days history of somnolence and confusion with evolving respiratory distress requiring endotracheal intubation. On admission neurological examination, he would open eyes to painful stimuli and continued to follow commands.

Investigations

Initial CT head revealed a flame hemorrhage in the left gyrus rectus suspicious for vascular origin and a hypodensity in the left thalamus suspicious for an established infarction. An angiogram performed the next day demonstrated six fusiform aneurysms: three at the frontopolar branch and one at the orbitofrontal branch of the left anterior cerebral artery (ACA); 1 at the frontopolar branch of the right ACA; and one at the anterior temporal artery of the left middle cerebral artery (MCA); [Figure 1]. Body imaging revealed cavitory lung lesions. The patient was started on broad spectrum antibiotics, antifungals, and antiviral medications.

Treatment

The location of hemorrhage pointed to the left ACA branch aneurysms as the source. Surgery was chosen to allow for inspection of all lesions under direct vision for ruptured status as well as obtain tissue for microbiological purposes. A bicoronal craniotomy, parent vessel sacrifice, and excision of the three aneurysms arising from the left ACA were performed on postbleed day 2. Intraoperatively, the aneurysms were friable, thin walled, and prone to bleeding. The right ACA aneurysms were managed conservatively. Microbiology confirmed angioinvasive *S. apiospermum* infection. Vericonazole, amphotericin B, and caspofungin were started empirically and continued throughout the disease process.^[15]

CT scan obtained due to neurological deterioration on postbleed day 4 revealed new left frontal intracerebral hemorrhage and intraventricular hemorrhage (IVH). An emergency external ventricular drain was placed and a follow-up angiogram was obtained revealing interval growth of the left orbitofrontal artery aneurysm. Since microbiological diagnosis was available, endovascular parent vessel occlusion was recommended and preceded uneventfully. An interval angiogram on postbleed day 7 demonstrated three new fusiform aneurysms of the right ACA, a new aneurysm of the left anterior choroidal artery (AChA), and the left posterior communicating artery (PCOMA) and confirmed a stable appearing left anterior temporal artery aneurysm. Due to the rapid development of new aneurysms, as well as the hemorrhagic presentation, the treatment was recommended.

A3–A3 revascularization was attempted to avoid ACA sacrifice; however, due to the friable nature of the diseased vessels, this was unsuccessful and parent vessel sacrifice had to be performed. An intraoperative angiogram demonstrated a new anterior communicating artery (ACOMA) aneurysm, which was left untreated at the time of surgery. On further follow-up imaging, the ACOMA aneurysm continued to enlarge and, therefore, was treated with endovascular A1 occlusions on postbleed day 9. Finally, continued surveillance imaging demonstrated interval growth of the previously identified left AChA and PCOMA aneurysm, which were ultimately treated with parent vessel sacrifice.

Outcome and follow-up

Despite multiple parent vessel sacrifice, the patient recovered neurologically, continued to follow commands with upper extremities with expected, severe paraparesis in the lower extremities. His follow-up MRI confirmed a thalamic infarct which was already seen on admission imaging and new, incomplete ACA territory infarctions in keeping with the previous surgeries and parent vessel sacrifice of the bilateral ACAs. Due to the severe systemic and pulmonary disease, the patient remained intubated and ventilated and underwent a tracheostomy procedure. His subsequent course was complicated with septic shock from multidrug resistant pseudomonas superinfection of the cavitory lung lesions and the patient died 6 months after the hemorrhagic presentation.

DISCUSSION

This case report describes a critically ill, immunocompromised patient with GVHD secondary to Burkitt's lymphoma presenting with disseminated *Scedosporium* infection with cavitory lung lesions and rapid, and sequential development of hemorrhagic mycotic aneurysms. Despite aggressive antifungal therapy and treatment of the aneurysms, the patient died due to sepsis and multiorgan failure. The notable feature of this case is the rapid angioinvasiveness of the infection with new aneurysm formation within days of clear angiographic imaging despite the apparent lack of obvious skull base osteomyelitis.

Mycotic aneurysms are a rare entity and most commonly associated with bacterial endocarditis.^[2,5] Fungal origin is less common and known to convey a poor prognosis, with a very high-mortality rate.^[2,8] Infection of vessel wall can occur either through hematogenous spread or direct invasion from an intracranial source, for example, osteomyelitis or thrombophlebitis of dural sinuses. Fungal mycotic aneurysms often have a predisposition to the proximal arteries suggesting direct spread from the base of skull. The treatment of mycotic aneurysms remains controversial. A number of case reports describe either successes or failures of antimicrobial therapy

alone or in combination with surgery and endovascular treatment. The most important factor determining the treatment modality and outcome is the ruptured status of an aneurysm.^[13] To date, there have been only ten cases of *S. apiospermum* mycotic intracranial aneurysms reported, of which all have died either as a consequence of hemorrhage or disseminated infection, suggesting difficulty in treating this rare infection and its complications [Table 1].

Here, we present a case of a ruptured *Scedosporium* mycotic aneurysms in a patient with significant immunosuppression. The rationale for surgical treatment initially was the need to obtain microbiological diagnosis. Subsequent approaches were decided on a case-by-case basis, depending on location and nature of the aneurysm. Surgery was favored when diseased vessels were supplying eloquent brain and when endovascular access was deemed difficult. Furthermore, in cases, where mycotic aneurysm progression is seen despite aggressive systemic treatment further surgical debridement and tissue biopsy plays a role, which was rational for the final operation. In all cases, where it was possible, endovascular treatment was performed to minimize the patient's risk.

Such rapid development and rupture of fungal aneurysms have not been described previously. This patient developed in total 12 aneurysms over the course of 8 days. Furthermore, the aneurysms that were initially treated conservatively demonstrated rapid growth and rupture necessitating treatment. Due to the location of the aneurysms at the ACA, osteomyelitis of the anterior skull base was suspected as the cause; however, this was not confirmed on imaging. Furthermore, subsequent aneurysms were found to have occurred away from the skull base at the distal PCOMA and AChA. These findings suggest disseminated infection, possibly related to the patient's cavitary lung lesions. This case demonstrates the aggressive angioinvasiveness of the *Scedosporium* spp. as well as its resistance to treatment. The only other case reporting rapid development of an intracranial aneurysm within 20 days of clear vascular imaging also identified *Scedosporium* spp. as the causative organism.^[10]

This presented case highlights the challenges in treating mycotic aneurysms in the setting of disseminated infection with highly angioinvasive organisms. Without systemic and/

Table 1: Previously described cases of the *Scedosporium apiospermum* mycotic aneurysms.

Author	Year	n	Age/gender	Risk factors	Location of aneurysm	Treatment	Outcome
Baudrillard et al. ^[1]	1985	1	32/female	- None - Near drowning	SCA	- Amphotericin B - Surgical clipping	Death
Gosbell et al. ^[4]	1999	1	33/female	- AML	BA	- Amphotericin B - Itraconazole	Death
Watson et al. ^[16]	1999	1	41/female	- None	BA	- Fluconazole - Amphotericin B - Resection	Death
Messori et al. ^[9]	2002	1	3/female	- None - Near drowning	BA, PCA	- Itraconazole - Surgical debridement of skull base	Death
Smith et al. ^[14]	2002	1	36/female	- None - Head injury from horse	PICA	- None	Death
Husain et al. ^[7]	2003	1	Not stated	- Organ transplant	Not stated	- Voriconazole - Amphotericin B	Not specified
Gopinath et al. ^[3]	2010	1	51/female	- None - Near drowning	PCA	- Antibiotics	Death
Ortman et al. ^[12]	2010	1	53/female	- None - Near drowning	PCA	- Itraconazole	Death
Ong et al. ^[11]	2011	1	48/male	- DM	SCA	- Voriconazole - Surgical clipping	Death
Ogawa et al. ^[10]	2016	1	85/male	- None	ICA	- Voriconazole - Embolization	Death
Current	2021	1	23/male	- Allogenic SCT	ACA, ACOMA, PCOMA, AChA, ATA	- Voriconazole - Liposomal amphotericin B - Caspofungin	Death

AML: acute myeloid leukemia, ACA: anterior cerebral artery, AChA: anterior choroidal artery, ATA: anterior temporal artery, BA: basilar artery, DM: diabetes mellitus, ICA: internal carotid artery, SCA: superior cerebellar artery, SCT: stem cell transplant, PCA: posterior cerebral artery, ACOMA: anterior communicating artery, PCOMA: posterior communicating artery, PICA: posterior inferior cerebellar artery

or local disease control *de novo*, aneurysm formation and hemorrhage can be expected, leading to surgical difficulty. *Scedosporium* mycotic aneurysms are rare, the best treatment remains unknown, source control is often difficult, and results in the literature have been uniformly fatal. While imaging was not confirmatory, a bone biopsy of the anterior skull base might have yielded positive results and led to more aggressive source control with anterior skull base debridement. Finally, given the uniformly fatal nature of *Scedosporium* mycotic aneurysms described in the literature, it may have been reasonable to pursue more conservative treatment options in this case. Nevertheless, the age of the patients as well as his prior wishes dictated each therapeutic step.

CONCLUSION

We highlight the difficulties in treating fungal mycotic aneurysms and the associated high mortality. We also describe an unusually angioinvasive presentation with multiple aneurysms forming and rupturing during a single hospitalization. While a more conservative approach might have been appropriate the age of the patient and wishes of the family dictated the treatment strategy.

Declaration of patient consent

Patient's consent not required as patient's identity is not disclosed or compromised.

Financial support and sponsorship

Nil.

Conflicts of interest

There are no conflicts of interest.

REFERENCES

- Baudrillard JC, Rousseaux P, Lerais JM, Toubas O, Scherpereel B, Gari M, et al. Fungal mycotic aneurysms and multiple cerebral abscesses caused by *Scedosporium apiospermum*. Apropos of a case with review of the literature. J Radiol 1985;66:321-6.
- Ducruet AF, Hickman ZL, Zacharia BE, Narula R, Grobelny BT, Gorski J, et al. Intracranial infectious aneurysms: A comprehensive review. Neurosurg Rev 2010;33:37-46.
- Gopinath M, Cherian A, Baheti NN, Das A, Antony M, Sarada C. An elusive diagnosis: *Scedosporium apiospermum* infection after near-drowning. Ann Indian Acad Neurol 2010;13:213-5.
- Gosbell IB, Morris ML, Gallo JH, Weeks KA, Neville SA, Rogers AH, et al. Clinical, pathologic and epidemiologic features of infection with *Scedosporium prolificans*: Four cases and review. Clin Microbiol Infect 1999;5:672-86.
- Hart RG, Foster JW, Luther MF, Kanter MC. Stroke in infective endocarditis. Stroke 1990;21:695-700.
- Hot A, Mazighi M, Lecuit M, Poirée S, Viard JP, Loulergue P, et al. Fungal internal carotid artery aneurysms: Successful embolization of an *Aspergillus*-associated case and review. Clin Infect Dis 2007;45:e156-61.
- Husain S, Muñoz P, Forrest G, Alexander BD, Somani J, Brennan K, et al. Infections due to *Scedosporium apiospermum* and *Scedosporium prolificans* in transplant recipients: Clinical characteristics and impact of antifungal agent therapy on outcome. Clin Infect Dis 2005;40:89-99.
- Kannoth S, Iyer R, Thomas SV, Furtado SV, Rajesh BJ, Kesavadas C, et al. Intracranial infectious aneurysm: Presentation, management and outcome. J Neurol Sci 2007;256:3-9.
- Messori A, Lanza C, De Nicola M, Menichelli F, Capriotti T, Morabito L, et al. Mycotic aneurysms as lethal complication of brain pseudallescheriasis in a near-drowned child: A CT demonstration. AJNR Am J Neuroradiol 2002;23:1697-9.
- Ogawa Y, Sato M, Tashiro M, Miyazaki M, Nagata K, Takahashi N, et al. Rapid development of a mycotic aneurysm of the intracranial artery secondary to *Scedosporium apiospermum* sinusitis. Med Mycol Case Rep 2016;14:30-2.
- Ong A, Blyth CC, Bency R, Vicaretti M, Harun A, Meyer W, et al. Fatal mycotic aneurysms due to *Scedosporium* and *Pseudallescheria* infection. J Clin Microbiol 2011;49:2067-71.
- Ortmann C, Wüllenweber J, Brinkmann B, Fracasso T. Fatal mycotic aneurysm caused by *Pseudallescheria boydii* after near drowning. Int J Legal Med 2010;124:243-7.
- Peters PJ, Harrison T, Lennox JL. A dangerous dilemma: Management of infectious intracranial aneurysms complicating endocarditis. Lancet Infect Dis 2006;6:742-8.
- Smith D, Bannykh S, Sang UH, Ziegler E. A woman kicked in the head by a horse. Infect Dis Clin Pract 2002;11:28-9.
- Troke P, Aguirrebengoa K, Arteaga C, Ellis D, Heath CH, Lutsar I, et al. Treatment of scedosporiosis with voriconazole: Clinical experience with 107 patients. Antimicrob Agents Chemother 2008;52:1743-50.
- Watson JC, Myseros JS, Bullock MR. True fungal mycotic aneurysm of the basilar artery: A clinical and surgical dilemma. Cerebrovasc Dis 1999;9:50-3.

How to cite this article: Budohoski KP, Raygor K, Cook D, Henrich T, Abla AA. Rapid sequential development and rupture of mycotic aneurysms within a period of days in a patient with graft-versus-host disease and angiotropic *Scedosporium apiospermum* infection. Surg Neurol Int 2022;13:242.