

UCLA

UCLA Previously Published Works

Title

Patent foramen ovale: clinical manifestations and treatment.

Permalink

<https://escholarship.org/uc/item/8jp4t2jf>

Journal

Reviews in Cardiovascular Medicine, 9(3)

ISSN

1530-6550

Authors

Kedia, Gautam

Tobis, Jonathan

Lee, Michael S

Publication Date

2008

Copyright Information

This work is made available under the terms of a Creative Commons Attribution License, available at <https://creativecommons.org/licenses/by/4.0/>

Peer reviewed

Patent Foramen Ovale: Clinical Manifestations and Treatment

Gautam Kedia, MD,* Jonathan Tobis, MD,† Michael S. Lee, MD†

*Division of Medicine, Cedars-Sinai Medical Center, Los Angeles, CA; †Division of Cardiology, The David Geffen School of Medicine at UCLA, Los Angeles, CA

A persistent patent foramen ovale produces an intermittent intra-atrial right-to-left shunt and occurs in approximately 25% of the general population. Although the vast majority of people with patent foramen ovale are asymptomatic, a patent foramen ovale is believed to act as a pathway for chemicals or thrombus that can result in a variety of clinical manifestations, including stroke, migraine headache, decompression sickness, high-altitude pulmonary edema, and platypnea-orthodeoxia syndrome. The optimal management of patients with patent foramen ovale who experience cryptogenic stroke is unclear. Percutaneous closure appears to have a low risk profile and has been considered in high-risk patients who are not candidates for randomized clinical trials. Randomized clinical trials that are underway should help define the best management of patent foramen ovale, as well as the true safety and efficacy of percutaneous closure devices.

[Rev Cardiovasc Med. 2008;9(3):168-173]

© 2008 MedReviews, LLC



Key words: Patent foramen ovale • Migraine • Stroke • Echocardiogram • Transcranial Doppler

There is increasing interest among cardiologists and neurologists in the congenital cardiac defect known as *patent foramen ovale* (PFO). An incidence as high as 27% has been reported in an autopsy study of 965 normal hearts,¹ and PFO has been associated with a variety of clinical syndromes in adults. However, the mechanistic relationship between PFO and stroke is unclear, as much remains to be learned. This article discusses the clinical aspects of PFO, with a focus on its relationship to stroke, as well as percutaneous management.

Detailed embryology and pathophysiology of PFO are discussed elsewhere.² In brief, a PFO in all mammalian embryos allows oxygenated blood from the placenta to flow from the right atrium to the left atrium, and then to the cerebral circulation, thus bypassing the fetal pulmonary circulation, which serves no purpose in oxygen exchange. In the first year of life, the foramen ovale seals. However, in 25% to 30% of people, the foramen ovale does not seal with fibrosis, resulting in a PFO. A PFO can be revealed by transthoracic, transesophageal, and intracardiac echocardiography and transcranial Doppler.

Incidence and Course

In a study by Hagen and colleagues,¹ PFO size increased from a mean of 3.4 mm up to age 10 to 5.8 mm after age 90. In another study of patients 45 years and older who were being evaluated for potential risk factors for stroke, the prevalence of PFO was 26%.³ However, in studies of patients experiencing cryptogenic stroke, the incidence was as high as 39% to 46%,^{4,5} thus highlighting PFO as a not uncommon condition often persisting into adulthood.

Clinical Manifestations

Although often asymptomatic, a PFO is believed to act as a pathway for chemicals or thrombus, which can result in a variety of clinical manifestations, including stroke, migraine headache, decompression sickness, high-altitude pulmonary edema, and platypnea-orthodeoxia syndrome.

There is an increased prevalence of PFO in patients with a cryptogenic stroke, which is thought to be related to the right-to-left passage of a thrombus originating in peripheral or abdominal veins. Shunting can occur at rest or transiently when straining or with coughing, because both cause a

sudden increase in right atrial pressure. In the prospective Stroke Prevention: Assessment of Risk in a Community (SPARC) study of 148 patients with a PFO, 57% had a right-to-left shunt at rest and 92% had a shunt with straining or coughing.³

However, data regarding the increased incidence of stroke in patients with an isolated PFO are inconsistent. Cabanes and colleagues⁶ studied 100 patients ages 15 to 55 with recent cryptogenic stroke in comparison with 50 control subjects. A PFO was found in 18% of the control population and 43% of the study population, and regression analysis demonstrated that PFO was significantly associated with increased risk of stroke. Similarly, Overell and coworkers⁷ showed via a meta-analysis

with recent cryptogenic ischemic stroke. Patients with an isolated PFO did not have a higher risk of recurrent cerebrovascular event as compared with patients without septal abnormalities. Another study evaluated a subgroup of 585 patients from the SPARC study, ages 45 years or older, 140 of whom had a PFO.⁹ Of these, 9% had a cerebrovascular ischemic event at 5-year follow-up. The authors found that isolated PFO was not an independent risk factor for future cerebrovascular events in the general population.

Less ambiguous is the association between an atrial septal aneurysm (ASA) and stroke. An ASA is a localized deformity of the interatrial septum that results in hypermobility of the septum. Atrial septal deviation of

An association between migraine with aura and patent foramen ovale has also been demonstrated.

that patients with a PFO were more likely to experience a stroke than control patients.

In contrast, several studies have demonstrated a lack of association between PFO and recurrent stroke. In the Patent Foramen Ovale in Cryptogenic Stroke Study (PICSS) of 630 stroke patients (265 cryptogenic), there was no significant difference in the incidence of recurrent ischemic stroke or death between patients with and without a PFO, both in the overall population and in the cryptogenic subset.⁵ However, in the subset of patients who were older than 65, the recurrent stroke or death rate was 3 times higher in patients who had a PFO. This increase suggests that as people get older, paradoxical embolism may actually play a greater role, perhaps due to the higher risk of venous thrombus (such as from varicose veins). Mas and colleagues⁸ enrolled 598 patients ages 18 to 55

at least 10 mm into either atrium is the accepted criterion of an ASA. An ASA is found in combination with a PFO in about 10% of symptomatic patients and has been discovered in up to 15% of patients with a possible embolic stroke.¹⁰ Retrospective studies in patients younger than 55 years with cryptogenic stroke have demonstrated that the presence of both a PFO and an ASA confers a higher risk of recurrent stroke^{6,8} compared with patients who have a PFO alone or neither abnormality.

An association between migraine with aura and PFO has also been demonstrated.^{4,11} Although the etiology is unclear, it has been proposed that chemical substances that usually are inactivated in the lungs gain access to the cerebral circulation in the presence of a right-to-left shunt and thereby trigger a migraine.¹² An alternative theory is that the migraine may be triggered by cerebral ischemia

resulting from a small paradoxical embolism, such as from a platelet aggregate. In a prospective study of men and women using data from the Physician's Health Study and the Women's Health Study, analysis suggested that migraine may increase the risk for major cardiovascular disease, including ischemic stroke and myocardial infarction.^{13,14} These results may indicate that migraine is associated with a predisposition to develop atherosclerosis, although in these observational studies, the risk from migraine was independent of the usual risks for atherosclerosis. Alternatively, these observations may be explained by paradoxical embolism through a PFO. Although there is no consensus on the prevention of stroke in patients with migraine, prophylaxis with aspirin may be a reasonable option.

Nitrogen gas embolisms in scuba divers may pass through a PFO and

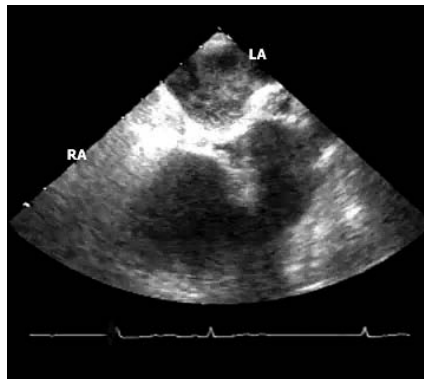


Figure 1. Patent foramen ovale discovered by transesophageal echocardiogram. LA, left atrium; RA, right atrium. www.medreviews.com

detected a PFO in 19 patients, whereas TTE with contrast injection detected a PFO in only 9 of these 19 (47%).¹⁶ The size and geometry of the PFO can also be determined by TEE.

Another diagnostic method is transcranial Doppler (TCD), a noninvasive tool. In the previously men-

In a patient with a cerebral ischemic event of uncertain etiology, a transthoracic echocardiogram is often attempted first, usually with agitated saline.

result in paradoxical embolism to the coronary and systemic circulation, leading to type II decompression sickness. A retrospective study of sport divers found that PFO increased the risk of decompression illness events 4.5-fold.¹⁵

Diagnostic Modalities

In a patient with a cerebral ischemic event of uncertain etiology, a transthoracic echocardiogram (TTE) is often attempted first, usually with agitated saline. If an interatrial defect is not found, and suspicion is still high, a transesophageal echocardiogram (TEE), which has higher sensitivity, may be performed (Figure 1). In a study of 49 patients with acute ischemic stroke or transient ischemic attack, TEE with contrast injection

tioned study, TCD missed a PFO in 6 of the patients diagnosed by TEE. In the patients who were missed, the PFO was 2 mm or smaller.¹⁶ However, another study demonstrated that TCD had equal sensitivity to contrast TEE in detecting cardiac right-to-left shunts.¹⁷ Other studies suggest that TCD may be more sensitive than TEE because the patient may have difficulty performing a Valsalva maneuver during a TEE.

Medical Management

The best medical management of patients with PFO who experience cryptogenic stroke is unclear. For example, at least 2 studies found no difference between aspirin and oral anticoagulation in secondary prevention of stroke in patients with PFO

and cryptogenic stroke.^{4,18} However, in patients in whom a PFO is found incidentally in the absence of clinical manifestations, further follow-up or repeat echocardiography is not needed, unless symptoms develop.

Percutaneous Closure

Percutaneous PFO closure appears to be safe and has a high rate of technical success.^{19,20} After entry, the PFO is located with a catheter and guide wire. An 8 French sheath is passed over the wire into the left atrium. The PFO occluding device is loaded into the sheath. The left-sided portion of the device is opened into the left atrium, and the device is pulled back until it lies flush against the septum. Then the right-sided part of the device is deployed into the right atrium. The procedure is usually completed with the use of contrast medium under fluoroscopic and intracardiac echocardiographic guidance. Transesophageal echocardiography is reserved for difficult cases. Post-procedure, the patient is treated with clopidogrel for 1 month and with aspirin for 6 months.

It should be emphasized that at the current time, there is no device approved by the US Food and Drug Administration (FDA) to close a PFO. Research studies are in progress to determine the risk/benefit ratio of PFO closure versus medical therapy in a variety of conditions. The 2 most common devices that are currently being used in the United States for percutaneous closure of PFO are the Amplatzer[®] device (AGA Medical Corporation, Golden Valley, MN) and the CardioSEAL[®] device (NMT Medical, Inc, Boston, MA [Figure 2]). Other options include the Premere[™] system (St. Jude Medical, Inc, Maple Grove, MN [Figure 3]) and the HELEX Septal Occluder (WL Gore & Associates, Inc, Flagstaff, AZ [Figure 4]).



Figure 2. The CardioSEAL closure device. Courtesy: NMT Medical, Inc. www.medreviews.com




Figure 3. The Premere closure device. Courtesy: St. Jude Medical, Inc. www.medreviews.com

Although percutaneous closure is generally technically successful, patients may not be free of recurrent neurological events. One review looked at 10 studies of percutaneous PFO closure and 6 studies of medical therapy including either antiplatelet or anticoagulant therapy.²¹ Percutaneous PFO closure was associated with a lower rate of recurrent neurological events (0% to 4.9%) as compared with medical therapy (3.8% to 12%). In another matched control study of 308 patients with a reported follow-up of 4 years, percutaneous closure was associated with fewer neurological events in the subset of patients who had more than 1 cerebrovascular event at baseline and in patients who had complete PFO clo-




Figure 4. The HELEX Septal Occluder device. Courtesy: WL Gore & Associates, Inc. www.medreviews.com

sure.²² However, no randomized trials to prove the superiority of PFO closure over medical therapy have yet been completed. The ongoing Randomized Evaluation of Recurrent Stroke Comparing PFO Closure to Established Current Standard of Care Treatment (RESPECT) trial compares medical therapy with percutaneous closure with the Amplatzer PFO occluder device in cryptogenic stroke patients ages 18 to 60. The Evaluation of the STARflex[®] Septal Closure System in Patients with a Stroke or Transient Ischemic Attack due to Pre-

cedure is of little consequence because over the next several weeks to months, scar tissue often overgrows the device. One study assessed the extent of thrombus formation on the CardioSEAL device and Amplatzer device 1 month after implantation by TEE.²³ Five of 23 (22%) patients with the CardioSEAL device had thrombus formation, whereas none of the 27 patients with the Amplatzer device had thrombus formation. However, no patients had a thromboembolic event. Furthermore, after anticoagulation with warfarin, the thrombus resolved in 3 of the 5 patients, but in 1 patient, the CardioSEAL device was surgically removed because of growth of the mobile thrombus despite anticoagulation.

Aside from residual shunt and thrombus formation, percutaneous closure may be associated with other uncommon complications that generate concern.²⁴ Embolization of the device may occur, but the device is usually retrievable by catheter. Additionally, the rim of the Amplatzer closure device may erode into the aorta or pericardium. There have

Although percutaneous closure is generally technically successful, patients may not be free of recurrent neurological events.

sumed Paradoxical Embolism through a PFO (CLOSURE 1) trial is evaluating a slightly different patient population that includes transient ischemic attack and compares the STARflex[®] septal closure system (NMT Medical, Inc) with medical therapy.

Mechanisms of recurrent neurological events after percutaneous closure include presence of a residual shunt,²⁰ the development of thrombus on the left atrial side of the closure device, and a stroke that was not due to paradoxical embolism. A residual shunt at the time of the proce-

been 5 reported cases of this occurrence out of about 25,000 implanted Amplatzer PFO devices. Infection is extremely rare. Nevertheless, antibiotic prophylaxis is recommended for the first year. Inflammation associated with healing of the devices can produce palpitations, atrial fibrillation, and migraine headaches. These complaints usually dissipate after the first 1 to 2 months.

The current American Heart Association/American Stroke Association guidelines indicate insufficient evidence for PFO closure in patients with a first stroke.²⁵ The only conditional

FDA approval through a controlled registry for PFO closure is in patients with recurrent cryptogenic stroke despite anticoagulation. The results of current randomized controlled studies will help us determine whether the best treatment option is to implant a PFO closure device after the first cryptogenic stroke or to wait for a recurrent stroke while continuing anticoagulation.

Patients at high risk for a recurrent neurological event may be considered for closure. High-risk features include an underlying hypercoagulable state, a large PFO, presence of ASA, and increased volume of right-to-left shunting.²⁶ But it should be emphasized that these procedures are performed off-label with devices that are not approved for PFO closure. Although it is essential to wait until the results of the randomized trials are available, there are some patient subsets that will never be tested in randomized trials.

Conclusion

Population-based studies indicate a high prevalence of PFO, especially in adults with cryptogenic stroke. However, data demonstrating a clear link between presence of a PFO and future neurological events are lacking. The most sensitive diagnostic modal-

ity seems to be TEE or TCD. Aside from anticoagulation, closure of the PFO is another consideration. Percutaneous closure appears to have a low-risk profile and can be considered in high-risk patients who are not candidates for the randomized clinical trials. Randomized clinical trials that are underway should help to define the best management of PFO, and the true safety and efficacy of percutaneous closure devices. All referring physicians should be encouraged to enroll their patients in the randomized clinical trials so that this critical information can be obtained. ■

Acknowledgment: Dr. Tobis is a consultant for the RESPECT and PREMIUM trials, sponsored by AGA Medical Corporation.

References

1. Hagen PT, Scholz DG, Edwards WD. Incidence and size of patent foramen ovale during the first 10 decades of life: an autopsy study of 965 normal hearts. *Mayo Clin Proc.* 1984;59:17-20.
2. Hara H, Virmani R, Ladich E, et al. Patent foramen ovale: current pathology, pathophysiology, and clinical status. *J Am Coll Cardiol.* 2005;46:1768-1776.
3. Meissner I, Whisnant JP, Khandheria BK. Prevalence of potential risk factors for stroke assessed by transesophageal echocardiography and carotid ultrasonography: the SPARC study. *Stroke Prevention: Assessment of Risk in a Community.* *Mayo Clin Proc.* 1999;74:862-869.
4. Lamy C, Giannesini C, Zuber M, et al. Clinical and imaging findings in cryptogenic stroke patients with and without patent foramen ovale:

the PFO-ASA Study. *Atrial Septal Aneurysm. Stroke.* 2002;33:706-711.

5. Homma S, Sacco RL, Di Tullio MR, et al. Effect of medical treatment in stroke patients with patent foramen ovale: Patent Foramen Ovale in Cryptogenic Stroke Study. *Circulation.* 2002;105:2625-2631.
6. Cabanes L, Mas JL, Cohen A, et al. Atrial septal aneurysm and patent foramen ovale as risk factors for cryptogenic stroke in patients less than 55 years of age. A study using transesophageal echocardiography. *Stroke.* 1993;24:1865-1873.
7. Overell JR, Bone I, Lees KR. Interatrial septal abnormalities and stroke: a meta-analysis of case-control studies. *Neurology.* 2000;55:1172-1179.
8. Mas JL, Arquizan C, Lamy C, et al. Recurrent cerebrovascular events associated with patent foramen ovale, atrial septal aneurysm, or both. *N Engl J Med.* 2001;345:1740-1746.
9. Meissner I, Khandheria BK, Heit JA, et al. Patent foramen ovale: innocent or guilty? Evidence from a prospective population-based study. *J Am Coll Cardiol.* 2006;47:440-445.
10. Pearson AC, Nagelhout D, Castello R, et al. Atrial septal aneurysm and stroke: a transesophageal echocardiographic study. *J Am Coll Cardiol.* 1991;18:1223-1229.
11. Anzola GP, Magoni M, Guindani M, et al. Potential source of cerebral embolism in migraine with aura: a transcranial Doppler study. *Neurology.* 1999;52:1622-1625.
12. Meier B, Lock JE. Contemporary management of patent foramen ovale. *Circulation.* 2003;107:5-9.
13. Kurth T, Gaziano JM, Cook NR, et al. Migraine and risk of cardiovascular disease in men. *Arch Intern Med.* 2007;167:795-801.
14. Kurth T, Gaziano JM, Cook NR, et al. Migraine and risk of cardiovascular disease in women. *JAMA.* 2006;296:283-291.
15. Schwerzmann M, Seiler C, Lipp E, et al. Relation between directly detected patent foramen ovale and ischemic brain lesions in sport divers. *Ann Intern Med.* 2001;134:21-24.
16. Di Tullio M, Sacco RL, Venketasubramanian N, et al. Comparison of diagnostic techniques for the detection of a patent foramen ovale in stroke patients. *Stroke.* 1993;24:1020-1024.
17. Blesch WK, Draganski BM, Holmer SR, et al. Transcranial duplex sonography in the detection

Main Points

- A patent foramen ovale (PFO) in mammalian embryos allows oxygenated blood from the placenta to flow from the right atrium to the left atrium, and then to the peripheral circulation. The PFO fails to seal in 25% to 30% of people.
- A PFO is believed to act as a pathway for chemicals or thrombus, which can result in a variety of clinical manifestations, including stroke, migraine headache, decompression sickness, high-altitude pulmonary edema, and platypnea-orthodoxia syndrome.
- In a patient with a cerebral ischemic event of uncertain etiology, a transthoracic echocardiogram is often attempted first. If an interatrial defect is not found, and suspicion is still high, a transesophageal echocardiogram, which has higher sensitivity, may be performed. Transcranial Doppler is another useful diagnostic tool.
- In patients in whom a PFO is found incidentally in the absence of clinical manifestations, further follow-up or repeat echocardiography is not needed, unless symptoms develop.
- Percutaneous PFO closure appears to be safe and has a high rate of technical success.

- of patent foramen ovale. *Radiology*. 2002;225:693-699.
18. Bogousslavsky J, Garazi S, Jeanrenaud X, et al. Stroke recurrence in patients with patent foramen ovale: the Lausanne Study. Lausanne Stroke with Paradoxal Embolism Study Group. *Neurology*. 1996;46:1301-1305.
 19. Martin F, Sanchez PL, Doherty E, et al. Percutaneous transcatheter closure of patent foramen ovale in patients with paradoxical embolism. *Circulation*. 2002;106:1121-1126.
 20. Windecker S, Wahl A, Chatterjee T, et al. Percutaneous closure of patent foramen ovale in patients with paradoxical embolism: long-term risk of recurrent thromboembolic events. *Circulation*. 2000;101:893-898.
 21. Khairy P, O'Donnell CP, Landzberg MJ. Transcatheter closure versus medical therapy of patent foramen ovale and presumed paradoxical thromboemboli: a systematic review. *Ann Intern Med*. 2003;139:753-760.
 22. Windecker S, Wahl A, Nedeltchev K, et al. Comparison of medical treatment with percutaneous closure of patent foramen ovale in patients with cryptogenic stroke. *J Am Coll Cardiol*. 2004;44:750-758.
 23. Anzai H, Child J, Natterson B, et al. Incidence of thrombus formation on the CardioSEAL and the Amplatzer interatrial closure devices. *Am J Cardiol*. 2004;93:426-431.
 24. Meier B. Closure of patent foramen ovale: technique, pitfalls, complications, and follow up. *Heart*. 2005;91:444-448.
 25. Sacco RL, Adams R, Albers G, et al. Guidelines for prevention of stroke in patients with ischemic stroke or transient ischemic attack: a statement for healthcare professionals from the American Heart Association/American Stroke Association Council on Stroke: co-sponsored by the Council on Cardiovascular Radiology and Intervention. *Stroke*. 2006;37:577-617.
 26. Wu LA, Malouf JF, Dearani JA, et al. Patent foramen ovale in cryptogenic stroke: current understanding and management options. *Arch Intern Med*. 2004;164:950-956.