

UC San Diego

UC San Diego Previously Published Works

Title

SAFETY AND EFFICACY OF ORAL FLUORESCEIN ANGIOGRAPHY IN DETECTING MACULAR EDEMA IN COMPARISON WITH SPECTRAL-DOMAIN OPTICAL COHERENCE TOMOGRAPHY

Permalink

<https://escholarship.org/uc/item/8kb1h8c8>

Journal

Retina, 33(8)

ISSN

0275-004X

Authors

Barteselli, Giulio

Chhablani, Jay

Lee, Su Na

et al.

Publication Date

2013-09-01

DOI

10.1097/iae.0b013e318285cd84

Peer reviewed



Published in final edited form as:

Retina. 2013 September ; 33(8): 1574–1583. doi:10.1097/IAE.0b013e318285cd84.

Safety and efficacy of oral fluorescein angiography in detecting macular edema in comparison with spectral domain optical coherence tomography

Giulio Barteselli, MD^{1,2}, Jay Chhablani, MD¹, Su Na Lee, MD¹, Haiyan Wang, MD¹, Sharif El Emam, MD¹, Igor Kozak, MD¹, Lingyun Cheng, MD¹, Dirk-Uwe Bartsch, PhD¹, Stanley Azen, PhD³, and William R. Freeman, MD.¹

¹Department of Ophthalmology, Jacobs Retina Center at Shiley Eye Center, University of California San Diego, La Jolla CA

²U.O. Oculistica, Fondazione IRCCS Ca' Granda-Ospedale Maggiore Policlinico, Università degli Studi di Milano, Milan, Italy

³Department of Preventive Medicine, Keck School of Medicine, University of Southern California, Los Angeles, CA

Abstract

Purpose—To evaluate the safety of oral fluorescein angiography (FA) and to compare its efficacy in detection of macular edema (ME) with spectral-domain optical coherence tomography (SD-OCT).

Methods—Results of imaging studies for 1,928 eyes of 1,019 patients who had simultaneously undergone both oral FA and SD-OCT by a confocal laser ophthalmoscope (cSLO) were reviewed. Sensitivity in detecting ME, discrepancy rate, and “kappa” agreement were determined for both the techniques, and with eyes stratified by disease diagnosis.

Results—No allergic reactions occurred after oral FA. Mild gastric discomfort was noted in <1% of the patients. 1,840 eyes (95.4%) showed concordance between the two techniques and “kappa” agreement was 90.3%. For ME, oral FA showed an overall sensitivity of 0.97 and SD-OCT of 0.91. Equivalent sensitivity was found in cases of wet age-related macular degeneration (0.99). Oral FA was more sensitive than SD-OCT in cases of retinovascular diseases. SD-OCT showed higher sensitivity in cases of macular holes. Detection of ME by SD-OCT was significantly higher in cases of intense leakage on oral FA ($p < 0.001$).

Conclusions—Oral FA proved to be a safe and adequate technique to evaluate ME. It is more sensitive than SD-OCT in detection of ME in cases of retinovascular diseases, but can fail to detect ME in cases of macular holes. A non-invasive examination with simultaneous oral FA and SD-OCT may be considered to obtain a comprehensive evaluation of the presence of ME from different pathologies.

Keywords

oral fluorescein angiography; spectral-domain optical coherence tomography; macular edema

[§]Corresponding author: William R. Freeman, MD, University of California at San Diego, Shiley Eye Center, 0946, 9415 Campus Point Drive, La Jolla, CA 92037; freeman@eyecenter.ucsd.edu.

The authors have no proprietary, financial, or conflicts of interest to disclose.

Introduction

Intravenous (IV) fluorescein angiography (FA) was first described by Novotny and Alvis in 1961.¹ Since then, it has been routinely used in the clinical practice to analyze retinal and choroidal pathologies. In 1979, Kincaid reported the first angiography after oral administration of fluorescein dye using a conventional fundus camera, but with poor results in terms of image quality.² Twenty years later, Hara et al. were able to obtain adequate photographic results in 97% of oral FA imaging studies using a latest-generation fundus camera; however, in many cases of age-related macular degeneration (AMD) and choroidal neovascularization (CNV) the image quality was not acceptable.³ In 1999, our group first reported the use of oral FA using a confocal scanning laser ophthalmoscope (cSLO); we showed that the confocal aperture has enough sensitivity and contrast to allow good-quality FA images in most retinal pathologies, and that oral FA with a cSLO is superior to oral FA using a film-based fundus camera.⁴ We subsequently reported that oral FA using a cSLO was able to detect CNV in patients with AMD, allowing visualization of the extent and type of CNV in most eyes.⁵ In 2006, Azad et al. reported that oral FA using cSLO is superior to oral FA using a digital fundus camera and is comparable to IVFA using a digital fundus camera in terms of image quality, branch retinal vessel identification and margin delineation.⁶

In recent years, optical coherence tomography (OCT) has played an important role as a non-invasive diagnostic and monitoring tool in many retinal diseases that cause macular edema (ME). With increasing use of non-invasive OCT for the diagnosis of ME, there is a tendency toward less frequent use of IVFA, which is invasive and has possible complications. FA identifies the anatomical location and pattern of vascular leakage, and is a qualitative and functional study, whereas OCT allows a morphological and quantitative assessment of ME by producing two or three-dimensional images of the retinal tissue.^{7, 8} It has been reported that certain conditions may show fluid on time domain (TD)-OCT without leakage on FA^{9, 10}, or viceversa.¹¹ Spectral domain (SD)-OCT detects retinal abnormalities more frequently compared to TD-OCT, but it still does not identify all cases with fluorescein leakage from CNV.¹² Thus, replacement of IVFA with OCT is controversial.

The use of IV sodium fluorescein dye is an invasive technique that can lead to mild to severe systemic complications, diffusely reported in the medical literature in large studies.¹³⁻¹⁵ Associated life-threatening adverse reactions are significantly less with oral FA compared to IVFA: no life-threatening or severe reactions have been previously reported following oral FA¹⁶⁻¹⁸, and ingestion of the dye can be also safely used in children.^{19, 20} In a large study evaluating complications of oral FA³, minimal itching, discomfort, or nausea were reported in 1.7% of the cases after ingestion of a large amount of sodium fluorescein: 10 mL of dye was necessary to detect fluorescence using a fundus camera. However, in that study a hypodermic injection of dexamethasone sodium phosphate and metoclopramide hydrochloride was administered 15 minutes before the dye ingestion as prophylaxis. With the use of a cSLO, the amount of dye necessary to obtain good-quality images is much smaller than the dye required using a fundus camera because of greater contrast due to confocal optics.⁴ Therefore, the rate of complications may be lower than what reported using a fundus camera, and a prophylaxis may not be necessary.

The current study was conducted to assess the safety of low-dosage oral FA using a cSLO, and additionally, to assess the ability of both oral FA and SD-OCT to detect ME in different retinal pathologies, in cases in which ME has been confirmed by either modality. We also desired to determine the agreement between the two techniques and explain any discrepancy.

Methods

After approval from the Institutional Review Board of the University of California at San Diego for retrospective studies, we reviewed the records of all the patients who were simultaneously imaged with oral FA and SD-OCT for clinical purposes over a 42-month period (March 2008 to September 2011) at the Jacobs Retina Center at Shiley Eye Center, University of California San Diego (La Jolla, CA). All patients signed an informed consent for care covering standard ophthalmic examinations, including imaging. Pathologies included wet and dry AMD, diabetic retinopathy (DR), epiretinal membrane (ERM), macular holes (MH, including full-thickness macular holes, pseudoholes and lamellar macular holes), retinal vein occlusion (RVO), uveitis, post-surgical ME and other causes of ME. In case of unilateral disease, also the normal fellow eye was included in the study. Demographic data, best corrected visual acuity (BCVA) and adverse reactions were recorded by reviewing the charts of the patients.

cSLO procedure

A cSLO Spectralis HRA (Heidelberg Engineering, Carlsbad, CA) was used for both oral FA and SD-OCT, using the built-in TruTrack™ Active Eye Tracking software of the device. For the oral FA, a late-phase frame technique was used: two vials (4 mL) of 25% Fluorescein Lite (Hub Pharmaceuticals, LLC, Rancho Cucamonga, CA [250 mg/mL]) were mixed with 30 mL of orange juice. After ingestion, an additional 30 mL of pure orange juice without fluorescein was ingested to clear the taste. No hypodermic injection of dexamethasone sodium phosphate and metoclopramide hydrochloride was administered before the ingestion of the dye. After ingestion, an OCT evaluation of the macula of both eyes was performed using a standard scanning protocol, including horizontal and vertical single scans centered on the fovea, and a macular volume scan. The early-phase FA frame was taken as soon as the dye was seen in the retinal vessels, typically between 5 and 15 minutes; the late frames were taken at least 30 minutes after the early frames. Patients were observed for at least 2 hours from the ingestion of the dye and the onset of any side effects was reported in the chart.

cSLO imaging

One set of images for oral FA and SD-OCT for each patient within the 42-month period was selected by an unmasked trained physician at random among the performed examinations, as long as the SD-OCT image signal strength value was above 15 dB on a scale of 40 dB, and the FA images were well-centered on the fovea. The FA images included one early-phase 30 degrees frame and one late-phase 30 degrees frame. The OCT images included one horizontal and one vertical lines passing through the fovea, as well as a volume scan of at least 37 B-scans covering the central 3 mm of the macula. The unmasked physician excluded cases with extensive submacular scarring to minimize the confounding factor of the staining effect, as well as cases in which OCT scans were not sectioning the areas that were leaking on FA. Two masked retina specialists analyzed the oral FA images and the SD-OCT scans in separate occasions to avoid bias.

Oral FA analysis

For the oral FA, the presence of edema was evaluated by comparing early-phase and late-phase frames. The presence of early hyperfluorescence that was increasing in late-phase images in the fovea or the perifoveal area was defined as leakage. The unmasked specialist defined the area of interest in the late-phase FA frame by placing a 3 mm diameter circle centered on the fovea. The circle was further divided into four quadrants by placing two perpendicular lines through the fovea. The masked specialists used a novel method to grade the ME for each quadrant in terms of percentage and intensity of leakage. Using the

fluorescence of the perifoveal vessels as comparison, intensity of leakage was classified into 4 grades (Figure 1, A–B): grade 0 corresponded to absence of leakage; grade 1 to presence of low-intensity leakage (less fluorescent than vessels); grade 2 to presence of mid-intensity leakage (similar fluorescence to the vessels); grade 3 to presence of high-intensity leakage (more fluorescent than the vessels). The area of leakage in each quadrant was calculated as a percentage and categorized into 6 grades (0, 2, 4, 6, 8, and 10). Grade 0 corresponded to absence of ME (0%); grade 2 corresponded to 1–20% of ME; grade 4 to 21–40% of ME; grade 6 to 41–60% of ME; grade 8 to 61–80% of ME; grade 10 to 81–100% of ME (Figure 1, C–D). The grading results for intensity of leakage and percentage area of leakage for each quadrant were summed to obtain a total grading of leakage for the 3 mm circle.

In cases of DR, one masked specialist also graded visualization of the foveal avascular zone (FAZ) using a three-point grading system previously proposed by Squirrell et al²¹: grade 1, FAZ seen and intact; grade 2, FAZ seen but not intact; grade 3, not possible to judge FAZ on an angiogram.

SD-OCT analysis

For the SD-OCT, the masked physicians determined the presence or the absence of IRF and SRF for all the scans. When at least one of the scans showed IRF or SRF, the outcome was “presence of ME”. When neither intraretinal fluid (IRF) nor subretinal fluid (SRF) was observed in the scans, the outcome was “absence of ME”. The central foveal retinal thickness was also recorded.

Statistical analysis

The concordance correlation coefficient between the two masked physicians was obtained for the analysis of both oral FA images and SD-OCT scans. The differences of the ability to detect ME between oral FA and SD-OCT were calculated in percentages for comparison purposes. Since it is not feasible to perform IVFA and oral FA simultaneously, and it is not ethical to have patients return for a second angiogram in a few days, IVFA was not used as gold standard for the presence of ME. Therefore, we determined the sensitivity of oral FA and SD-OCT by using the presence of ME determined by either instrument as the gold standard for the presence of ME, while the absence of ME as determined by both instruments was considered a true-negative finding. We have used this statistical technique on a previously published report.⁹ The “kappa” agreement between the two techniques was calculated applying the formula for Cohen’s Kappa using SAS statistical software version 9.2 (SAS Inc, Cary, NC).

Results

The diagnoses of 1,928 studied eyes of 1,019 patients are seen in Table 1. 1,581 eyes showed a retinal pathology, while 347 eyes were normal. The mean age of the patients was 70 years (range 11–103 years); 447 were men, 572 were women. The mean BCVA was 0.29 ± 0.36 (logMAR \pm SD), equivalent to Snellen 20/40. The median BCVA was 0.20 ± 0.36 (logMAR \pm SD), equivalent to Snellen 20/32. The mean central foveal thickness was 271 ± 127 (microns \pm SD). The mean time for the early-phase frame of the oral FA was 10 ± 5 (minutes \pm SD) after the dye ingestion, for the late-phase frame was 39 ± 12 (minutes \pm SD). The median time was 9 minutes for the early-phase frame, and 37 minutes for the late-phase frame.

Safety

No allergic reactions were recorded during the 42-month study, and ingestion of 4 mL sodium fluorescein was well tolerated without preventive hypodermic injection of

dexamethasone sodium phosphate and metoclopramide hydrochloride. Mild transient gastric discomfort or minimal nausea were noted in 9 out of 1,019 patients (0.88%) a few minutes after the ingestion of the dye, and did not require any treatment. No nausea, itching, or vasovagal reaction occurred during the 2-hour observation period.

Agreement/Discrepancy

The inter-observer agreement for analysis of oral FA images and SD-OCT scans was 93% and 96%, respectively. Out of 1,928 eyes, 1,840 (95.44%) had confirmation of the presence or the absence of ME by both oral FA and SD-OCT. The results of the sensitivity of oral FA and SD-OCT in detecting ME as well as the results of the discrepancy rates and the “kappa” agreement between the two techniques using a single-kappa coefficient are shown in Table 1.

The overall sensitivity of oral FA for ME was 97.2% and that of SD-OCT for ME was 91.3%. Dividing into groups of pathologies (Table 1), the sensitivity of oral FA was equivalent to that of SD-OCT only in cases of wet AMD, and was higher in cases of DR, ERM, RVO, uveitis and post-surgical ME. On the contrary, SD-OCT showed a higher sensitivity than oral FA in cases of MH and the group of “other pathologies”. The overall discrepancy rate in detecting ME was 4.56%. In 67 eyes (3.47%), the oral FA showed dye leakage in the macular area and no IRF nor SRF on the SD-OCT scans (Figure 2). In 21 eyes (1.09%), SD-OCT showed IRF and/or SRF, which were missed by the oral FA (Figure 3). Most cases of discrepancy were found in DR, MH and uveitis. The overall “kappa” agreement between the two techniques was 90%. Dividing into groups of pathologies, the highest agreement was found in the group of wet AMD (95%), while the lowest one in the group of DR (52%). Neither “kappa” agreement nor sensitivity or discrepancy was calculated for normal eyes nor eyes with dry AMD, which are not causes of ME.

Analyzing the visualization of the FAZ in the 149 eyes with DR, we found that grade 1 FAZ (seen and intact) was present in 32.2% of the cases, grade 2 FAZ (seen but not intact) in 65.8% and grade 3 FAZ (not possible to judge) in 2.0%. Significantly higher FA grading and central foveal thickness was found in cases of grade 2 or 3 ($p < 0.001$, Student’s *t*-test).

Table 2 and Figure 4 show the difference between the mean central foveal thickness and the mean BCVA (logMAR) in cases of presence and absence of ME. Cases of presence of ME by either the techniques showed a significantly higher central foveal thickness ($p < 0.001$, Student’s *t*-test) and lower BCVA ($p < 0.001$, Student’s *t*-test). Detection of ME by SD-OCT was significantly higher in cases of more intense leakage on oral FA ($p < 0.001$, Student’s *t*-test). BCVA, central foveal thickness, and FA grading were highly correlated ($p < 0.01$, Pearson’s correlation).

Discussion

In the present study, we found that the most common reaction after ingestion of low-dosage sodium fluorescein dye was mild transient gastric discomfort, occurring in less than 1% of the cases and not requiring any prophylaxis or treatment. No cases of nausea or itching were noted, nor cases of serious adverse reactions to oral fluorescein; however, the sample size of our population is too small to perform a reliable comparison with the severe adverse events rate reported in previous studies that analyzed the IVFA. Nausea, vomiting, extravasation, sneezing and pruritis after IVFA are estimated to occur in 5% or less, and a severe reaction (e.g., cardiac, respiratory, or similar severe reactions) to occur in 1 in 1,900 IVFA with death occurring in 1 in 222,000 angiograms.¹⁴ Adverse reactions occur approximately 10 times more frequently in cases of a previous adverse reaction after IVFA.¹³ The medical literature does however show that adverse reaction rate and severity are milder with oral than with IV

administration of many drugs, such as in case of penicillin.²² Thus, it is therefore reasonable to assume that orally administered fluorescein is less dangerous than IV fluorescein in terms of allergic reactions. Moreover, oral administration of the fluorescein does not require the discomfort and the risks of venipuncture. In our anecdotal experience, patients who have had IVFA and oral FA in different examinations prefer oral FA for these reasons.

Oral angiography using a cSLO device was able to obtain good-quality early and late phase images in most of the patients; an example of normal oral FA frames is shown in Figure 5. The cSLO provides a greater fluorescence signal than a conventional camera, and high contrast due to confocal optics.⁴ To record good-quality images, we advise to perform the early-phase image at least 9 minutes after the dye ingestion, while the late-phase image after 37 minutes. Fasting does not have a clinically important effect on the timing of the appearance of fluorescein dye in the retinal vasculature.⁴ However, we note some disadvantages in using oral FA. Firstly, the duration of the procedure is longer than IVFA; the mean time for detecting the dye in the retinal vessels with the cSLO (early phase frame) was 10 minutes, much longer if compared to the 20–30 seconds of the IV administration. However, the time required to drink the dye is shorter than the time required to prepare injection tray and to find good venous access in the arm and to inject the dye. The mean time for the late phase frame in our study was 39 minutes: thus, between the early and the late phase it was possible to perform the early phase frame in at least other two patients. Another limitation of oral FA is the inability to visualize the progressive perfusion of retinal vessels; moreover, the assessment of the FAZ is often not as good as with IVFA.^{4, 5, 21}

In more than 95% of the cases oral FA and SD-OCT showed concordance in evaluating the presence or absence of ME. Leakage on FA was highly correlated with foveal thickness on SD-OCT (and therefore edema), and both were negatively correlated with BCVA. BCVA is clearly affected mostly by intense ME, that is able to create retinal structural changes and leads to modification and reduction of the visual processing. Despite the high concordance, in 4.56% of the cases we noticed discrepancy between oral FA and SD-OCT. In 67 cases (3.47%), oral FA showed ME but lacked any corresponding retinal changes on SD-OCT; in 21 cases (1.09%), SD-OCT showed fluid with nothing shown on oral FA. ME results from loss of functional integrity in the blood-retinal barriers or in the retinal pigment epithelium (RPE) pump, with subsequent accumulation of fluid leading to increased retinal thickness.²³ The presence of excess fluid is often suggested by the progressive leakage on FA, sometimes with accumulation in well-demarcated spaces. Although leakage can result in fluid accumulation, it may also occur without fluid accumulation if the fluid that leaks into the retina or subretinal space is pumped out by the RPE cells at the same or a greater rate than the leakage.²⁴ Indeed, we found that if we compare the FA grading and the central foveal thickness between cases of absence of ME on OCT and cases of presence of ME on OCT (Table 2), both the FA grading and the central foveal thickness showed a significantly lower result in cases without ME on SD-OCT ($p < 0.001$, Student's t-test). This suggests that SD-OCT has a lower sensitivity in cases of low-grade leakage. However, fluid accumulation may also occur without obvious hyperfluorescence if the source of leakage is very small, and the fluorescein molecules leak slowly and disperse quickly into the space.²⁴ In the present study, the overall “kappa” agreement between oral FA and SD-OCT was 0.90 (95% confidence interval [CI], 0.88–0.92); however, in the subgroups of pathologies, high variation of the agreement and high discrepancy rate were noted. Similarly, group analysis showed considerable difference in the sensitivity of oral FA and SD-OCT in various retinal pathologies; interestingly, in some diseases neither technique is as sensitive alone as the two combined.

Oral FA and SD-OCT showed excellent equivalent sensitivity to detect macular edema in cases of wet AMD (0.99). However, if performed alone, in a very small percentage of cases

they can miss ME (discrepancy rate was 0.95). Therefore, simultaneous evaluation using oral FA and SD-OCT should be considered to detect all cases of new, persistent, or recurrent ME. Moreover, particular attention should be paid in evaluating ME on TD-OCT, since it has already been shown that it frequently fails to detect abnormalities when fluorescein leakage from CNV is identified^{25, 26}, more often than SD-OCT.¹²

Oral FA is able to detect all cases of ME from retinovascular diseases, and is more sensitive than SD-OCT in eyes with DR, RVO, uveitis and post-surgical ME (1.00 vs. 0.79, 0.94, 0.79 and 0.85, respectively). In cases of discrepancy, the FA grading was significantly lower than in cases of agreement between the two techniques, suggesting that mild leakage from the retinal vessels may not be detected on SD-OCT because is not sufficient to create obvious patterns of IRF, or retinal structural changes, or to affect the foveal thickness on SD-OCT. However, early perifoveal leakage is a sign of breakout of the inner blood-retinal barrier in retinovascular diseases and thus predictor of a possible future development of ME. Therefore, patients with early perifoveal leakage must receive closer follow-up than the others. On the other hand, in 98 out of 149 eyes with DR (65.8%) the FAZ was visualized on oral FA but without a clear delineation, due to ME (Figure 6). Therefore, oral FA is useful for the diagnosis of retinovascular diseases, but is less reliable in detecting the FAZ in eyes with DR, as previously reported by Squirrel et al.²¹

SD-OCT showed a higher sensitivity to detect ME than oral FA (1.00 vs. 0.84) in the group of eyes with macular holes. In 11.27% of the cases we found discrepancy, but in none of the cases the SD-OCT failed to detect any cystic changes at the edges of the MH. Oral FA revealed no leakage from perifoveal capillaries in 8 out of 49 eyes (16.3%) that showed cystic changes on SD-OCT; these changes may be due to mechanical damage and not necessarily to fluid within the inner layers since no retinovascular damage is present. Indeed, fluorescein leakage is often minimal or absent in cases of tractional ME and mechanical retinal changes in cases of partial posterior vitreous detachment, which remains adherent to the foveola.¹⁰ Gaudric suggested that these cystic changes, which are not linked to fluorescein leakage, could be due either to an enlargement of the virtual retinal intercellular space, or to cellular death, or both.²⁷

Neither oral FA nor SD-OCT was able to detect all the cases of tractional edema in eyes with ERM: discrepancy rate was 9.82% and “kappa” agreement 0.78. However, the sensitivity of oral FA was higher than that of SD-OCT (0.97 vs. 0.89). The central retinal thickness and the FA grading were significantly lower in cases of absence of ME on SD-OCT: one possible explanation is that the SD-OCT may fail to detect low grades of edema on oral FA related to tangential traction, when this is not sufficient to create retinal folds, vascular stretching or foveal evagination. We suggest that both the techniques should be performed in patients with this pathology.

The weakness of this study includes its retrospective nature; however, the large sample size of the studied population, the use of simultaneous FA and SD-OCT examination and the image analysis performed by masked experienced graders are strengths.

In conclusion, our study suggests that oral FA using cSLO is a safe, non-invasive and well tolerated procedure with high sensitivity to detect ME. In an era where SD-OCT may often be the predominantly used instrument to guide treatment decisions for many retinal pathologies, we conclude that SD-OCT facilitates quantitative assessment and detection of microstructural changes; however, occasionally it misses subtle ME that can be detected on FA. Oral FA is more sensitive than SD-OCT in detecting ME related to retinovascular diseases, while SD-OCT has greater ability to detect mechanical changes in the inner retinal layers in cases of MH. To obtain a comprehensive evaluation in common retinal diseases

that cause ME and to reduce risks and discomfort of the IVFA, a non-invasive examination using simultaneous oral FA and SD-OCT may be considered for clinical purposes.

Acknowledgments

Funding/Support: This study was supported by NIH grants R01EY007366 and R01EY018589 (WRF), and R01EY020617 (LC), R01EY016323 (DUB), and “RPB incorporated and unrestricted funds from Jacobs Retina Center”. The funding organizations had no role in the design or conduct of this research.

References

- Novotny HR, Alvis DL. A method of photographing fluorescence in circulating blood in the human retina. *Circulation*. 1961; 24:82–6. [PubMed: 13729802]
- Kelley JS, Kincaid M. Retinal fluorography using oral fluorescein. *Arch Ophthalmol*. 1979; 97:2331–2. [PubMed: 518385]
- Hara T, Inami M. Efficacy and safety of fluorescein angiography with orally administered sodium fluorescein. *Am J Ophthalmol*. 1998; 126:560–4. [PubMed: 9780101]
- Garcia CR, Rivero ME, Bartsch DU, et al. Oral fluorescein angiography with the confocal scanning laser ophthalmoscope. *Ophthalmology*. 1999; 106:1114–8. [PubMed: 10366079]
- Bartsch DU, Elmusharaf A, El-Bradey M, Freeman WR. Oral fluorescein angiography in patients with choroidal neovascularization and macular degeneration. *Ophthalmic Surg Lasers Imaging*. 2003; 34:17–24. [PubMed: 12570000]
- Azad RV, Baishya B, Pal N, Sharma YR, Kumar A, Vohra R. Comparative evaluation of oral fluorescein angiography using the confocal scanning laser ophthalmoscope and digital fundus camera with intravenous fluorescein angiography using the digital fundus camera. *Clin Experiment Ophthalmol*. 2006; 34:425–9. [PubMed: 16872337]
- Brar M, Yuson R, Kozak I, et al. Correlation between morphologic features on spectral-domain optical coherence tomography and angiographic leakage patterns in macular edema. *Retina*. 2010; 30:383–9. [PubMed: 20216291]
- Kang SW, Park CY, Ham DI. The correlation between fluorescein angiographic and optical coherence tomographic features in clinically significant diabetic macular edema. *Am J Ophthalmol*. 2004; 137:313–22. [PubMed: 14962423]
- Kozak I, Morrison VL, Clark TM, et al. Discrepancy between fluorescein angiography and optical coherence tomography in detection of macular disease. *Retina*. 2008; 28:538–44. [PubMed: 18398354]
- Johnson MW. Tractional cystoid macular edema: a subtle variant of the vitreomacular traction syndrome. *Am J Ophthalmol*. 2005; 140:184–92. [PubMed: 16086944]
- Ozdek SC, Erdinc MA, Gurelik G, Aydin B, Bahceci U, Hasanreisoglu B. Optical coherence tomographic assessment of diabetic macular edema: comparison with fluorescein angiographic and clinical findings. *Ophthalmologica*. 2005; 219:86–92. [PubMed: 15802932]
- Khurana RN, Dupas B, Bressler NM. Agreement of time-domain and spectral-domain optical coherence tomography with fluorescein leakage from choroidal neovascularization. *Ophthalmology*. 2010; 117:1376–80. [PubMed: 20452027]
- Kwiterovich KA, Maguire MG, Murphy RP, et al. Frequency of adverse systemic reactions after fluorescein angiography. Results of a prospective study. *Ophthalmology*. 1991; 98:1139–42. [PubMed: 1891225]
- Yannuzzi LA, Rohrer KT, Tindel LJ, et al. Fluorescein angiography complication survey. *Ophthalmology*. 1986; 93:611–7. [PubMed: 3523356]
- Kwan AS, Barry C, McAllister IL, Constable I. Fluorescein angiography and adverse drug reactions revisited: the Lions Eye experience. *Clin Experiment Ophthalmol*. 2006; 34:33–8. [PubMed: 16451256]
- Menezo JL, Martinez-Costa R, Diaz Llopis M, Planells C, Ramirez I, Martinez H. Angiography by the oral route using enteric-coated capsules. *J Fr Ophtalmol*. 1988; 11:879–82. [PubMed: 3253318]

17. Kelley JS, Kincaid M, Hoover RE, McBeth C. Retinal fluorograms using oral fluorescein. *Ophthalmology*. 1980; 87:805–11. [PubMed: 7443213]
18. Azad R, Nayak BK, Tewari HK, Khosla PK. Oral fluorescein angiography. *Indian J Ophthalmol*. 1984; 32:415–7. [PubMed: 6545332]
19. Nayak BK, Ghose S. A method for fundus evaluation in children with oral fluorescein. *Br J Ophthalmol*. 1987; 71:907–9. [PubMed: 3426997]
20. Morgan KS, Franklin RM. Oral fluorescein angioscopy in aphakic children. *J Pediatr Ophthalmol Strabismus*. 1984; 21:33–6. [PubMed: 6707856]
21. Squirrel D, Dinakaran S, Dhingra S, Mody C, Brand C, Talbot J. Oral fluorescein angiography with the scanning laser ophthalmoscope in diabetic retinopathy: a case controlled comparison with intravenous fluorescein angiography. *Eye (Lond)*. 2005; 19:411–7. [PubMed: 15184968]
22. Middleton, E., Jr; Ellis, RC.; EF, et al., editors. *Allergy: Principles and Practice*. 4. St. Louis: Mosby; 1993.
23. Marmor MF. Mechanisms of fluid accumulation in retinal edema. *Doc Ophthalmol*. 1999; 97:239–49. [PubMed: 10896337]
24. Ouyang Y, Keane PA, Sadda SR, Walsh AC. Detection of cystoid macular edema with three-dimensional optical coherence tomography versus fluorescein angiography. *Invest Ophthalmol Vis Sci*. 2010; 51:5213–8. [PubMed: 20357195]
25. Eter N, Spaide RF. Comparison of fluorescein angiography and optical coherence tomography for patients with choroidal neovascularization after photodynamic therapy. *Retina*. 2005; 25:691–6. [PubMed: 16141855]
26. Do DV, Gower EW, Cassard SD, et al. Detection of new-onset choroidal neovascularization using optical coherence tomography: the AMD DOC Study. *Ophthalmology*. 2012; 119:771–8. [PubMed: 22297028]
27. Gaudric A. Macular cysts, holes and cavitations: 2006 Jules Gonin lecture of the Retina Research Foundation. *Graefes Arch Clin Exp Ophthalmol*. 2008; 246:1071–9. [PubMed: 18446358]

Summary statement

Oral fluorescein angiography is a safe, well tolerated, and adequate technique to evaluate macular edema. It is more sensitive than SD-OCT in cases of retinovascular diseases, but can fail to detect macular edema in cases of macular holes.

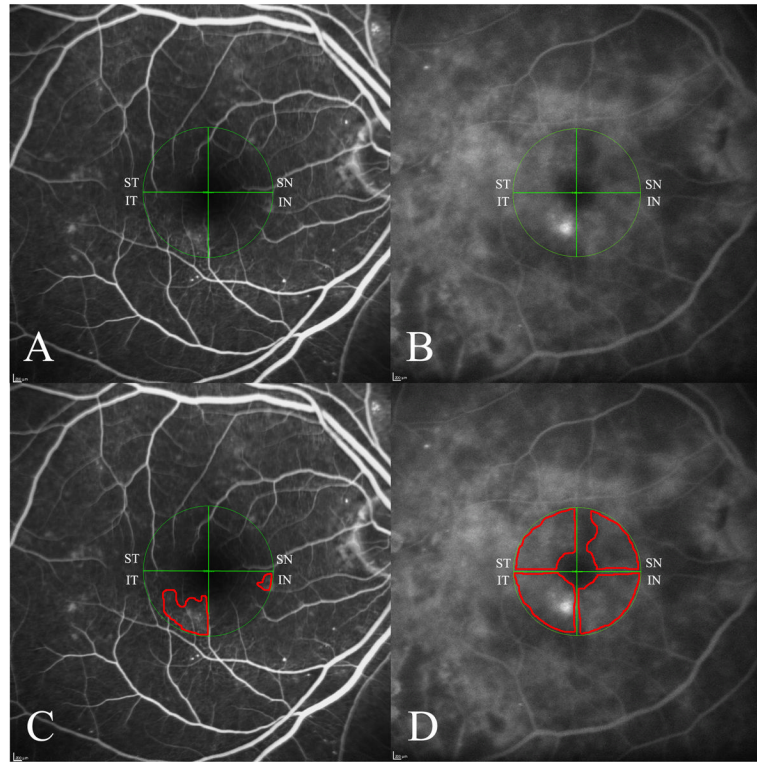


Figure 1.

A–B: Grading for leakage intensity on oral fluorescein angiography in the four macular quadrants (ST, supero-temporal; SN, supero-nasal; IN, infero-nasal; IT, infero-temporal) in two different eyes with diabetic retinopathy. The diameter of the circle centered on the fovea is 3 mm. **A:** Leakage is present in IT and IN quadrants, showing grade 1 intensity (less fluorescent than the perifoveal vessels). No leakage is seen in the other quadrants (grade 0). **B:** ST, SN and IN quadrants show grade 2 intensity of leakage (as fluorescent as the perifoveal vessels). IT quadrant shows grade 3 intensity of leakage (more fluorescent than the perifoveal vessels). **C–D:** Grading for leakage percentage on oral fluorescein angiography in the four macular quadrants in the same previous eyes. The diameter of the circle centered in the fovea is 3 mm. **C:** Grade 0 (no leakage) is seen in ST and SN quadrants. Grade 2 (between 1 and 20%) is present in IN quadrant. Grade 6 (between 41 and 60%) in IT quadrant. **D:** Grade 10 of leakage (between 80 and 100%) is present in ST, IN and IT quadrants. Grade 8 of leakage (between 61 and 80%) is seen in SN quadrant.

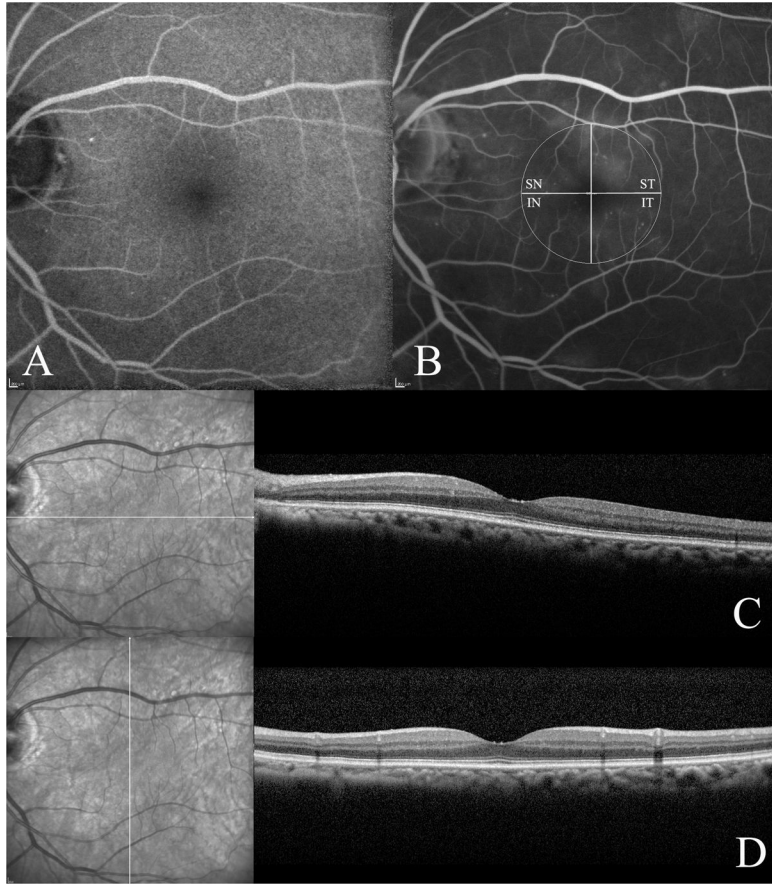


Figure 2. Example of discrepancy in detection of macular edema between oral fluorescein angiography (FA) and spectral-domain optical coherence tomography (SD-OCT) in an eye affected by diabetic macular edema. **A:** Early-frame image on oral FA (4 minutes after ingestion of the dye) showing small perifoveal microaneurysms. **B:** Late-frame image of the same eye (50 minutes after ingestion of the dye) showing leakage in all the macular quadrants except the infero-nasal (IN) quadrant. The total grading for the leakage on oral FA was 23, considering both percentage and intensity. **C:** SD-OCT horizontal scan, showing neither intraretinal fluid nor subretinal fluid. **D:** SD-OCT vertical scan, showing neither intraretinal fluid nor subretinal fluid.

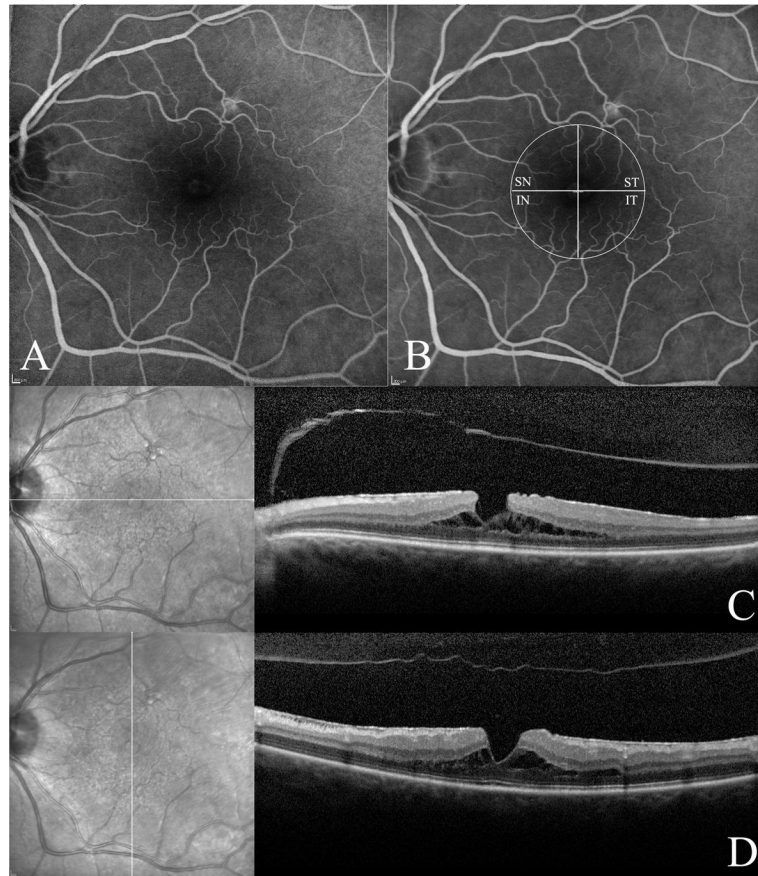


Figure 3. Example of discrepancy in detection of macular edema between oral fluorescein angiography (FA) and spectral-domain optical coherence tomography (SD-OCT) in an eye affected by lamellar macular hole (LMH). **A:** Early-frame image on oral FA (7 minutes after ingestion of the dye) showing subfoveal window effect. **B:** Late-frame image on oral FA (40 minutes after ingestion of the dye) showing no visible leakage in any of the macular quadrants. The total grading for the leakage on oral FA was 0, considering both percentage and intensity. **C:** SD-OCT horizontal scan, showing the LMH with intraretinal cystic fluid and incomplete vitreous detachment. **D:** SD-OCT vertical scan, showing the LMH with intraretinal cystic fluid and incomplete vitreous detachment.

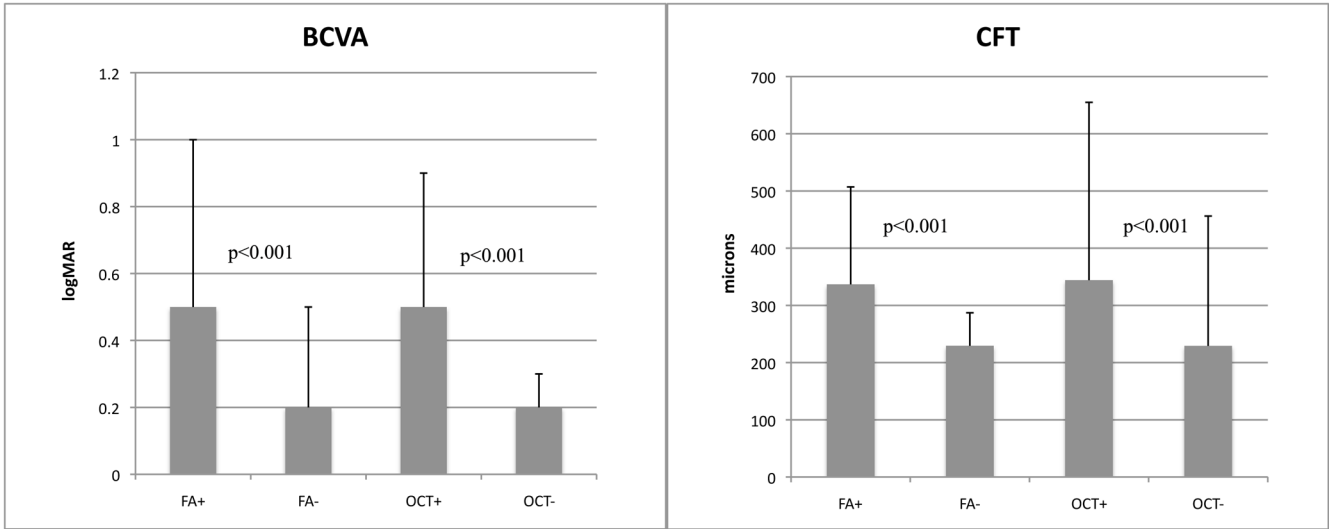


Figure 4.

Left: Association of mean best-corrected visual acuity (logMAR) and presence of macular edema on oral fluorescein angiography (FA) and spectral-domain optical coherence tomography (SD-OCT). (FA+: macular edema detected on FA; FA-: macular edema not detected on FA; OCT+: macular edema detected on OCT; OCT-: macular edema not detected on OCT). **Right:** Association of mean central foveal thickness (microns) and presence of macula edema on oral FA and SD-OCT. (FA+: macular edema detected on FA; FA-: macular edema not detected on FA; OCT+: macular edema detected on OCT; OCT-: macular edema not detected by OCT).

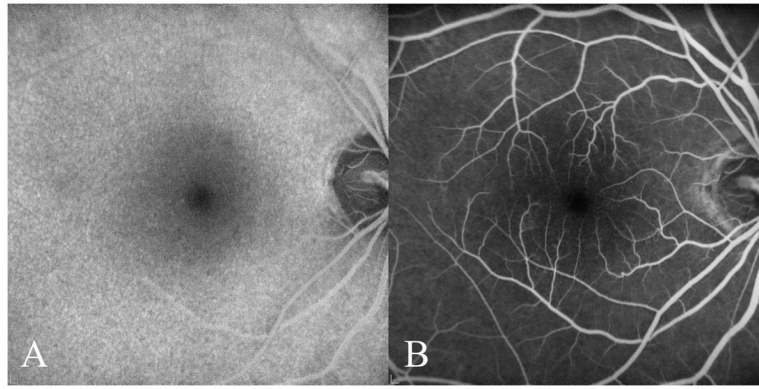


Figure 5.
A: Example of an early-frame image (7 minutes after ingestion of the dye) on oral fluorescein angiography (FA) in a normal eye. **B:** Late-frame image on oral FA (41 minutes after ingestion of the dye) in the same eye showing no leakage.

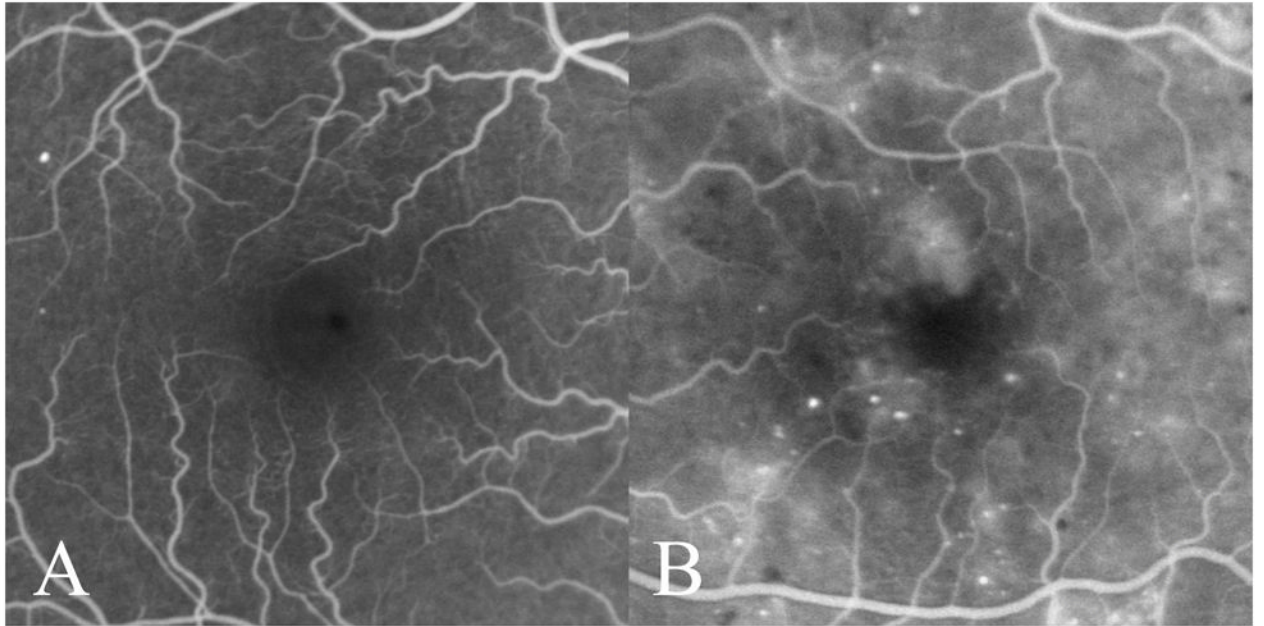


Figure 6.

A: Good visualization of the foveal avascular zone on oral fluorescein angiography in a patient with mild diabetic retinopathy. **B:** Poor visualization of foveal avascular zone borders due to macular edema on oral fluorescein angiography in a different patient with diabetic retinopathy.

TABLE 1
Sensitivity of Oral Fluorescein Angiography and Spectral Domain Optical Coherence Tomography, Discrepancy Rate and “Kappa” Agreement in Detection of Macular Edema in Various Pathologies

	Eyes (No.)	Sensitivity Oral FA (95% C.I.)	Sensitivity SD-OCT (95% C.I.)	Discrepancy (%)	“Kappa” Agreement (95% C.I.)
Total Eyes	1,928	0.97 (0.96–0.98)	0.91 (0.90–0.92)	4.56	0.90 (0.88–0.92)
Normal Eyes	347	-	-	-	-
Dry AMD	554	-	-	-	-
Wet AMD	240	0.99 (0.98–1.00)	0.99 (0.98–1.00)	0.83	0.95 (0.89–1.00)
DR	149	1.00	0.79 (0.72–0.86)	18.12	0.52 (0.38–0.67)
ERM	336	0.97 (0.95–0.99)	0.89 (0.86–0.92)	9.82	0.78 (0.71–0.85)
MH*	71	0.84 (0.75–0.93)	1.00	11.27	0.76 (0.61–0.91)
RVO	53	1.00	0.94 (0.88–1.00)	5.66	0.55 (0.10–0.99)
Uveitis	65	1.00	0.79 (0.69–0.89)	10.8	0.78 (0.64–0.93)
Post-surgical ME	23	1.00	0.85 (0.70–0.96)	8.7	0.82 (0.60–1.00)
Others [†]	90	0.94 (0.89–0.99)	1.00	2.2	0.95 (0.89–1.00)

* Includes full-thickness macular holes, pseudoholes and lamellar macular holes.

[†] Includes cases of degenerative myopia, foveoschisis, radiation retinopathy, retinal dystrophies, macroaneurysm, macular teleangiectasia, histoplasmosis, choroidal melanoma, Coat’s disease
FA, fluorescein angiography; SD-OCT, spectral domain optical coherence tomography; C.I., confidence interval; AMD, age-related macular degeneration; DR, diabetic retinopathy; ERM, epiretinal membrane; MH, macular hole; RVO, retinal vein occlusion; ME, macular edema

TABLE 2
 Central Foveal Thickness, Best Correct Visual Acuity, and Oral Fluorescein Angiography Grading related to Macular Edema

	FA+	FA-	p value	OCT+	OCT-	p value
CFT (microns)	336.7	229.4	<0.001	344	229.2	<0.001
BCVA (logMAR)	0.49	0.19	<0.001	0.51	0.19	<0.001
FA grading	-	-	-	26.33	1.02	<0.001

CFT, central foveal thickness; BCVA, best correct visual acuity; FA, fluorescein angiography; ME, macular edema; FA+, ME detected by FA; FA-, ME not detected by FA; OCT+, ME detected by OCT; OCT-, ME not detected by OCT