
How I Do It

A Novel Approach for Surgical Repair of Dehiscent High Jugular Bulb

Mohammad F. Shaikh, MD; Hossein Mahboubi, MD, MPH;
Michael German, MD; Hamid R. Djalilian, MD

Key Words: Dehiscent high jugular bulb, pulsatile tinnitus, aural fullness, conductive hearing loss.
Laryngoscope, 123:1803–1805, 2013

INTRODUCTION

The jugular bulb is found at the junction of the horizontal segment of the sigmoid sinus and the superior end of the internal jugular vein. A high jugular bulb (HJB) may extend into the middle ear cavity lateral to the cochlea. The superior threshold of HJB varies according to various authors. The limits include the inferior bony annulus, the lower border of the round window, and the upper limit of the basal turn of the cochlea.^{1–3} A dehiscent high jugular bulb (DHJB) occurs when a high jugular bulb lacks a bony covering within the middle ear. The incidence of HJB and DHJB has been reported as 3.5% to 22.6% and 0.5% to 1.7% percent, respectively.^{4,5} DHJB may initially manifest with profuse hemorrhage during myringotomy or middle ear surgery.⁵ When a DHJB impinges on tympanic structures, such as the tympanic membrane (TM), ossicles, or round window, patients may experience conductive hearing loss (CHL), aural fullness, or pulsatile tinnitus.⁶ Sensorineural hearing loss has also been described as a consequence of DHJB and is thought to occur from protrusion of the jugular bulb through the round window.⁷ In general, conservative management has been favored over surgical intervention.^{8,9} The pathophysiology of symptoms and operative complications of DHJB have been attributed to its close proximity with the TM. Where surgical intervention has been tried, the focus has been on control or manipulation of the jugular bulb.¹⁰ We describe a novel

technique whereby symptoms were relieved through lateralization of the inferior TM without repositioning of the jugular bulb.

MATERIALS AND METHODS

Case Report

An 18-year-old female presented with a history of mild to moderate right-sided conductive hearing loss with sensation of aural fullness and pulsatile tinnitus exacerbated with exercise. Otoscopy revealed a bluish hypotympanic mass abutting the inferior 25% of the TM surface (Fig. 1). High resolution temporal bone computed tomography confirmed a DHJB (Fig. 2). Observation and conservative management were recommended. Due to the severity of symptoms, the patient and her family strongly wished to proceed with surgery.

Surgical Procedure

After a postauricular approach, the tympanomeatal flap was raised and the TM was gently separated from the dehiscent jugular bulb using blunt instruments, including the duckbill elevator and drum elevator. We initially attempted to medialize the jugular bulb by compressing it with a cartilage graft, but were unable to safely separate the bulb medially from the surrounding bone. Rather than manipulating the jugular bulb itself, we lateralized the tympanomeatal flap to separate the TM from the jugular bulb. Ofloxacin-soaked Gelfoam (Pfizer, New York, NY) was moderately overpacked medial to the flap to maintain the separation between the jugular bulb and the TM. A small fascia graft was placed in an underlay fashion to bridge the gap between the tympanomeatal flap and the external auditory canal (Fig. 3). Several pieces of Gelfoam were placed along the tympanomeatal incision. No packing was placed lateral to the tympanomeatal flap to prevent medial compression of the TM. The wound was closed in the usual fashion (Fig. 4). At 3 months postoperatively, the patient was found to have normal hearing and resolution of aural fullness. These improvements have persisted at 3-year follow-up (Fig. 5).

DISCUSSION

Management of HDJB has been described in the literature by several authors. Buckwalter et al.¹¹ and

From the Division of Otolaryngology, Neurotology and Skull Base Surgery, Department of Otolaryngology–Head and Neck Surgery (M.F.S., H.M., M.G., H.R.D.), and the Department of Biomedical Engineering (H.R.D.), University of California, Irvine Medical Center, Orange, California, U.S.A.

Editor's Note: This Manuscript was accepted for publication October 24, 2012.

The authors have no funding, financial relationships, or conflicts of interest to disclose.

Send correspondence to Hamid R. Djalilian, MD, Department of Otolaryngology–Head and Neck Surgery, University of California, Irvine, 101 The City Drive South, Bldg. 56, Suite 500, Orange, CA 92868. E-mail: hdjalili@uci.edu

DOI: 10.1002/lary.23891

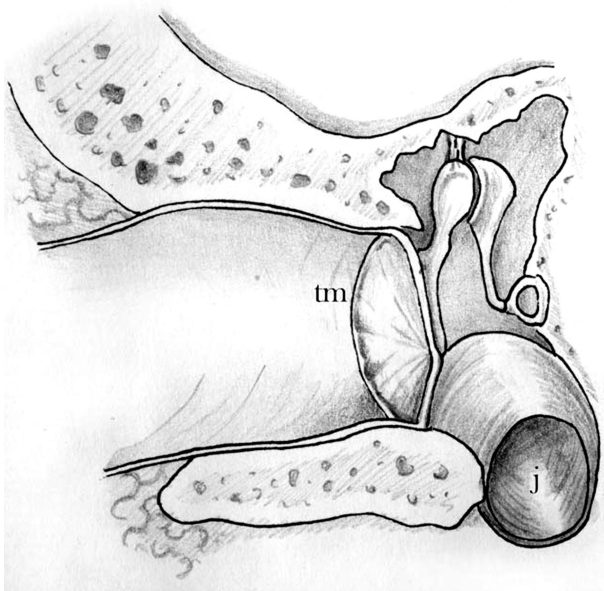


Fig. 1. Location of the dehiscence high jugular bulb (j) in relation to the tympanic membrane (tm) and middle ear cavity.

others¹² described ligation of the internal jugular vein in cases of debilitating pulsatile tinnitus. This invasive approach, although effective, involves significant risk to other vital neural and vascular structures in the neck. Endovascular embolization has also been used with success^{13,14} but carries the risk of venous thrombosis, infarct, and as with venous ligation, may lead to increased intracranial pressure (ICP).

In many cases, HDJB is encountered incidentally during middle ear surgery. In chronic middle ear disease, the TM may be opacified and landmarks may be obscured, concealing the classic otoscopic finding of bluish hue in the posteroinferior quadrant.⁵ Differential diagnosis for bluish discoloration of the tympanic membrane includes cholesterol granuloma, paraganglioma,

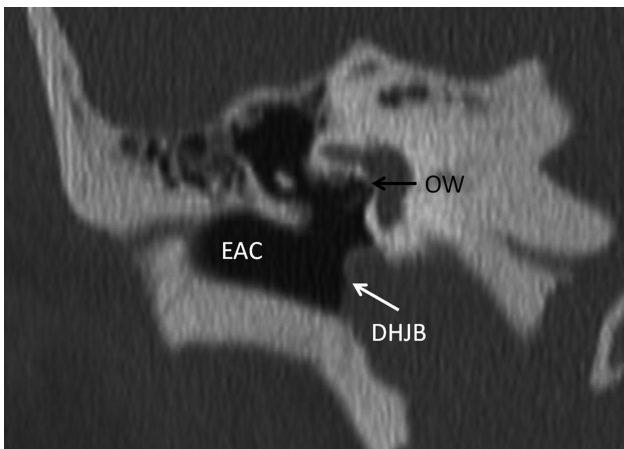


Fig. 2. Preoperative high-resolution computed tomography image of the temporal bone, coronal section. DHJB = dehiscence high jugular bulb; EAC = external auditory canal; OW = oval window.

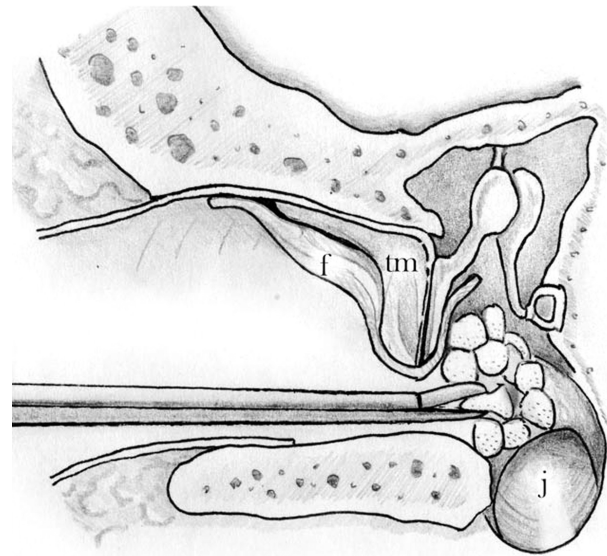


Fig. 3. Overpacking of Gelfoam and placement of the fascia graft. f = fascia graft; j = high jugular bulb; tm = tympanic membrane.

aberrant internal carotid artery, blue-domed mucosal cyst, rhabdomyosarcoma, aural polyp, varices of the TM, hemangioma, diverticulum of the internal carotid artery, extramedullary hematopoiesis, and jugular bulb phlebectasia.⁹ It is not uncommon for massive bleeding to occur on entry of the middle ear if the jugular bulb is entered. For a small tear, bleeding may remit with application of Gelfoam backed by pressure with a cottonoid or a cotton ball soaked in saline. Pressure should be maintained for 2 to 3 minutes. The Gelfoam should be left on the bulb and the cotton(oid) should be removed gently. For severe bleeding, the ear canal must be packed with petrolatum-impregnated gauze strips. Air embolus should be

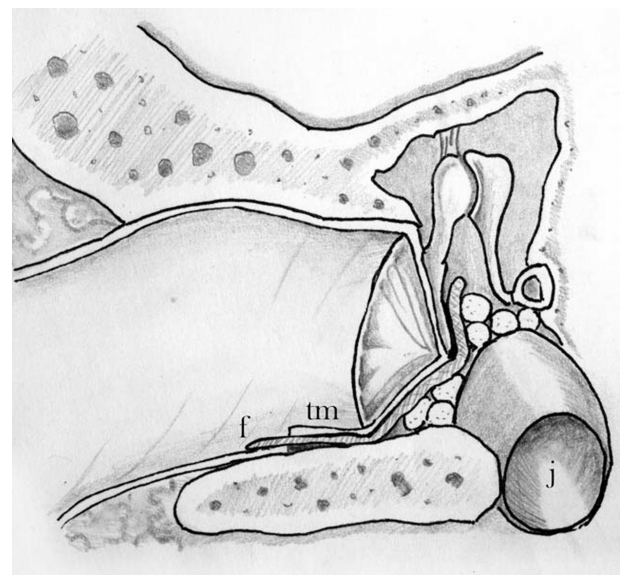


Fig. 4. Closure of the opening after the surgery. f = fascia graft; j = high jugular bulb; tm = tympanic membrane.

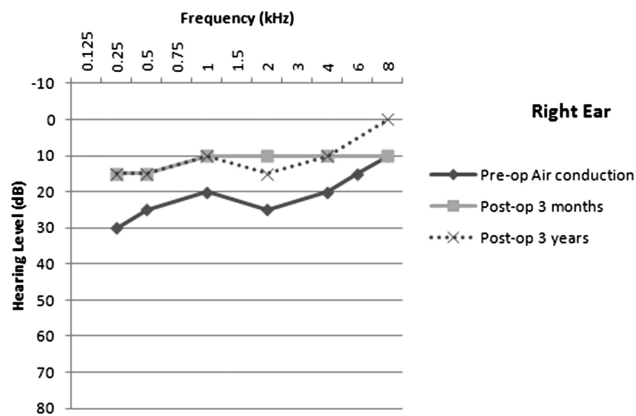


Fig. 5. Pure-tone audiometry before (Pre-op) and after (Post-op) the surgery for dehiscient high jugular bulb in the right ear.

prevented by lowering the head below the heart level.¹⁵ When discovered incidentally, the jugular bulb may need to be repositioned to complete the intended otologic surgery. Huang et al.⁵ reported using fascia, perichondrium, or autologous cartilage to cover and reinforce an HDJB encountered under such circumstances. Their series did not correlate symptom resolution with jugular bulb manipulation, as all patients were operated on for chronic or adhesive otitis media and not for HDJB.

More recently, El-Begermy et al.¹⁶ described a novel technique for treatment of tinnitus due to HDJB. They described a layered reconstruction of the bony hypotympanum using bone dust, perichondrium, and tragal cartilage with improvement of symptoms in five of seven patients and one complication of increased ICP. Postoperative audiograms were unchanged in six of seven cases; the seventh case had concomitant stapedectomy with decreased air-bone gap. In their series, it appeared that no subjects had CHL attributable to the HDJB. In our case, surgery was performed to relieve aural fullness and correct the CHL. Glasscock et al.¹⁷ surgically treated two patients with significant CHL due to a jugular bulb filling much of the tympanic cavity. They repositioned the jugular bulb to the hypotympanum with a mastoid cortex bone graft. In both cases the hearing did not return to normal and the authors did not subsequently recommend such surgery for a high jugular bulb, even if symptomatic.

It has been suggested that a progressive increase in the volume and height of HJBs has been observed in patients followed for several years.^{11,18-20} Our patient has remained symptom free for more than 3 years. Currently, the patient states that she feels a rub on her TM after aggressive aerobic exercises that lasts a few minutes after stopping exercising. If the jugular bulb continues to grow, it may again abut the TM and cause recurrence, although this would require extension over the bony annulus and into the external auditory canal. To our knowledge, there are no reports of lateral jugular bulb extension into the external auditory canal.

CONCLUSION

Much of the reported literature on surgical management of the DHJB places emphasis on altering, controlling, reinforcing, or otherwise manipulating the jugular bulb itself. In the technique presented here, lateral displacement of the tympanic membrane has achieved good long-term improvement in aural fullness and correction of CHL. Because of the rarity of symptomatic HDJB, it will be difficult to obtain a large series of patients. We surmise that this technique will only be useful in cases where the DHJB does not reach the umbo, and the inferior TM can be lateralized. If the DHJB reaches the umbo or the ossicular chain, then a combination of techniques may be used where cartilage is used to separate the DHJB from the ossicles, and the superior half of the TM and inferior TM is lateralized using the described technique. Other techniques, such as separating the TM from the umbo and amputating the inferior malleus, can be utilized as well.

BIBLIOGRAPHY

- Overton SB, Ritter FN. A high placed jugular bulb in the middle ear: a clinical and temporal bone study. *Laryngoscope* 1973;83:1986-1991.
- Wadin K, Wilbrand H. The topographic relations of the high jugular fossa to the inner ear. A radioanatomic investigation. *Acta Radiol Diagn (Stockh)* 1986;27:315-324.
- Atilla S, Akpek S, Uslu S, et al. Computed tomographic evaluation of surgically significant vascular variations related with the temporal bone. *Eur J Radiol* 1995;20:52-56.
- Chen B, Chen Z. The management of high jugular bulb and its active bleeding during middle ear surgery [in Chinese]. *Lin Chung Er Bi Yan Hou Tou Jing Wai Ke Za Zhi* 2007;21:157-159.
- Huang BR, Wang CH, Young YH. Dehiscient high jugular bulb: a pitfall in middle ear surgery. *Otol Neurotol* 2006;27:923-927.
- Weiss RL, Zahrtz G, Goldofsky E, et al. High jugular bulb and conductive hearing loss. *Laryngoscope* 1997;107:321-327.
- Tsunoda A. Sensorineural hearing loss caused by a high jugular bulb. *J Laryngol Otol* 2000;114:867-869.
- Moore PJ. The high jugular bulb in ear surgery: three case reports and a review of the literature. *J Laryngol Otol* 1994;108:772-775.
- West JM, Bandy BC, Jafek BW. Aberrant jugular bulb in the middle ear cavity. *Arch Otolaryngol* 1974;100:370-372.
- Ozturkcan S, Katilmis H, Ozkul Y, Erdofan N, Tayfun MA. Surgical treatment of the high jugular bulb by compressing sinus sigmoideus: two cases. *Eur Arch Otorhinolaryngol* 2007;265:987-991.
- Buckwalter JA, Sasaki CT, Virapongse C, et al. Pulsatile tinnitus arising from jugular megabulb deformity: a treatment rationale. *Laryngoscope* 1983;93:1534-1539.
- Golueke PJ, Panetta T, Sclafani S, Varughese G. Tinnitus originating from an abnormal jugular bulb: treatment by jugular vein ligation. *J Vasc Surg* 1987;6:248-251.
- Yoon BN, Lee TH, Kong SK, et al. Management of high jugular bulb with tinnitus: transvenous stent-assisted coil embolization. *Otolaryngol Head Neck Surg* 2008;139:740-741.
- Kondoh K, Kitahara T, Mishiroy Y, et al. Management of hemorrhagic high jugular bulb with adhesive otitis media in an only hearing ear: transcatheter endovascular embolization using detachable coils. *Ann Otol Rhinol Laryngol* 2004;113:975-979.
- Shao KN, Tatagiba M, Samii M. Surgical management of high jugular bulb in acoustic neuroma via retrosigmoid approach. *Neurosurgery* 1993;32:32-36; discussion 36-37.
- El-Begermy MA, Rabie AN. A novel surgical technique for management of tinnitus due to high dehiscient jugular bulb. *Otolaryngol Head Neck Surg* 2010;142:576-581.
- Glasscock ME, Dickins JR, Jackson CG, Weit RJ. Vascular anomalies of the middle ear. *Laryngoscope* 1980;90:77-88.
- Beyer RA, McCarty GE. High jugular and high carotid canal first observed as intracranial bruit. *Arch Neurol* 1983;40:387-388.
- Graham MD. The jugular bulb: its anatomic and clinical considerations in contemporary otology. *Laryngoscope* 1977;87:105-125.
- Jahrsdoerfer RA, Cail WS, Cantrell RW. Endolymphatic duct obstruction from a jugular bulb diverticulum. *Ann Otol Rhinol Laryngol* 90:619-623.