



Published in final edited form as:

*Lasers Surg Med.* 2008 November ; 40(9): 644–650. doi:10.1002/lsm.20673.

## Vascular Effects of Photodynamic and Pulsed Dye Laser Therapy Protocols

Jennifer Channual, BS<sup>1,2</sup>, Bernard Choi, PhD<sup>1,3</sup>, Kathryn Osann, PhD<sup>2</sup>, Daniel Pattanachinda, BS<sup>4</sup>, Justin Lotfi, BS<sup>1</sup>, and Kristen M. Kelly, MD<sup>1,5,\*</sup>

<sup>1</sup>Beckman Laser Institute, University of California, Irvine, California 92612

<sup>2</sup>School of Medicine, University of California, Irvine, California 92697

<sup>3</sup>Department of Biomedical Engineering, University of California, Irvine, California 92697

<sup>4</sup>School of Biological Sciences, University of California, Irvine, California 92697

<sup>5</sup>Department of Dermatology, University of California, Irvine, California 92697

### Abstract

**Background and Objective**—Pulsed dye laser (PDL) treatment of cutaneous vascular lesions is associated with variable and unpredictable efficacy. Thus, alternative treatment modalities are needed. Previous in vitro and in vivo studies have demonstrated enhanced selective vascular destruction with benzoporphyrin derivative (BPD) monoacid ring A photodynamic therapy (PDT) followed immediately by PDL irradiation (PDT+PDL). Here, we evaluate PDT alone, PDL alone, and PDT+PDL protocols using an optimized in vivo rodent dorsal window chamber model.

**Study Design/Materials and Methods**—A dorsal window chamber was surgically installed on male Golden Syrian hamsters. BPD solution was administered intravenously via a jugular venous catheter. Evaluated interventions included: (1) Control (no BPD, no light); (2) Control (BPD, no light); (3) PDT alone ( $\lambda=576$  nm; 25, 50, 75, or 96 J/cm<sup>2</sup> radiant exposure; 15 minutes post-BPD injection); (4) PDL alone at 7 J/cm<sup>2</sup> (585 nm, 1.5 milliseconds pulse duration, 7 mm spot); and (5) PDT (25 or 75 J/cm<sup>2</sup>)+PDL (7 J/cm<sup>2</sup>). Laser speckle imaging was used to monitor blood flow dynamics before, immediately after, and 1, 3, and 5 days post-intervention.

**Results**—Perfusion reduction on day 1 post-intervention was achieved with PDT >50 J/cm<sup>2</sup>, PDL alone, and PDT+PDL. However, by day 5 post-intervention, recovery of flow was observed with PDT alone at 50 J/cm<sup>2</sup> (-15.1%) and PDL alone (+215%). PDT (75 J/cm<sup>2</sup>)+PDL resulted in the greatest prolonged reduction in vascular perfusion (-99.8%).

**Conclusions**—Our in vivo data suggest that the PDT+PDL therapeutic protocol can result in enhanced and persistent vascular shutdown compared to PDT or PDL alone. The PDT+PDL approach has potential for considerable superficial vascular destruction and should be considered as a treatment modality for cutaneous vascular lesions. Monitoring of blood flow changes for as long as possible is crucial for accurate assessment of light-based vascular interventions.

### Keywords

benzoporphyrin derivative; laser speckle imaging; photodynamic therapy; port wine stains; visudyne

\*Correspondence to: Kristen M. Kelly, MD, 1002 Health Sciences Road East, Irvine, CA 92612. E-mail: kmkelly@uci.edu.

## INTRODUCTION

Port-wine stains (PWS) are benign congenital hyper-vascular lesions, most common on the face and neck and present in 0.3-0.5% of neonates [1]. The current standard of care for PWS is the pulsed dye laser (PDL) [2] with epidermal cooling [3]. Yellow light emitted by the PDL is strongly absorbed by intravascular hemoglobin constituents and can selectively damage vessels with diameters  $>20\ \mu\text{m}$  [4]. PDL treatment for PWS typically requires multiple treatments and complete blanching is not achieved for many patients [5,6]. Many factors contribute to suboptimal PWS blanching, including the presence of small ( $<20\ \mu\text{m}$  diameter) vessels resistant to photocoagulation due to poor thermal confinement [4], vascular density and depth, epidermal melanin that reduces light delivery to targeted PWS vessels [7], and post-treatment reperfusion and angiogenesis [3,8]. Due to the inconsistent efficacy of current PDL therapy, alternative treatment modalities should be evaluated.

In photodynamic therapy (PDT), a photosensitizer is administered and exposed to optical wavelengths specific to its absorption. The activated photosensitizer reacts with local oxygen to produce cytotoxic reactive oxygen species that can induce highly localized cellular damage [9-11]. With intravascular photosensitizer localization, endothelial cell damage can ensue, leading to platelet aggregation and photocoagulation. In contrast to PDL, which induces photothermal injury with short-pulsed and high-power laser irradiation, PDT results in photochemical damage with minimal heat generation. In a comparison of collateral damage after either PDT or PDL therapy, Barr et al. [12] demonstrated that the structural integrity of collagen is better maintained after PDT. Furthermore, PDT has been used successfully to treat various benign and malignant conditions, such as age-related macular degeneration [10,13], actinic keratosis [14], and non-melanoma skin cancers [15,16].

We have designed a protocol utilizing PDT in combination with PDL [17,18]. We selected benzoporphyrin derivative (BPD) monoacid ring A as the photosensitizer due to initial vascular predominance [19-22], proven safety and efficacy, and photosensitivity of relatively short duration [13,23]. Yellow light was selected due to high BPD absorption and limited depth of vascular injury. In preliminary studies, the combined PDT+PDL protocol has shown enhanced acute microvascular destruction compared to PDT or PDL alone. Studies involving the chick chorioallantoic membrane model [17] demonstrated a significant increase in persistent vascular shutdown with PDT+PDL as compared to other study groups: 127% more than PDT alone ( $P<0.01$ ) and 47% more than PDL alone ( $P<0.01$ ). Subsequent experiments on Sprague-Dawley rats bearing dorsal window chambers demonstrated safety and efficacy of the combined approach [18]. A reduction in perfusion was achieved for all intervention groups, with the PDT+PDL treatment protocol resulting in the greatest degree of vascular shutdown (56% reduction in mean blood flow) by 18 hours post-intervention.

In the present study, we sought to evaluate PDT, PDL, and combined PDT+PDL treatment protocols using a pre-clinical model that more closely mimics cutaneous vascular lesions in humans. The thinner skin ( $\sim 0.4\ \text{mm}$  thickness) [24] of Golden Syrian hamsters allowed for both epidermal irradiation and subdermal evaluation of vascular dynamics, serving as an improved model for cutaneous vascular lesions in which vessels contributing to erythema reside at a depth of 1 mm or less. Furthermore, preliminary data have suggested that the immediate (i.e., up to 24 hours post-intervention) microvascular response to light-based therapies does not persist upon subsequent evaluation [8]. Thus, we studied the vascular response to PDT, PDL, and PDT+PDL treatment protocols for up to 5 days post-intervention.

## MATERIALS AND METHODS

### Rodent Dorsal Window Chamber Model

A previously described rodent dorsal window chamber model [18], used in investigations of laser light effects on microcirculation [24,25-27], was applied to 26 male Golden Syrian hamsters (95-120 g; Harlan, Indianapolis, IN) in accordance with a protocol approved by the Institutional Animal Care and Use Committee of the University of California, Irvine. This preparation allowed for direct observation of the microvascular network from the subdermal aspect and intervention from the epidermal aspect. Two days after chamber implantation, jugular venous catheterization was performed to obtain intravenous access. This catheterization was performed on all animals, including those used in control experiments.

### Study Groups

Study groups are listed in Table 1. Three control animals underwent surgery and catheterization, but did not receive BPD or light irradiation. Two additional animals underwent surgery and catheterization, and received BPD alone in order to confirm that the medication alone did not impact vasculature. Twenty-one animals underwent evaluation after epidermal irradiation with one of the following protocols: PDT alone (25, 50, 75, or 96 J/cm<sup>2</sup> radiant exposure), PDL (7 J/cm<sup>2</sup>), and PDT (25 or 75 J/cm<sup>2</sup>)+PDL (7 J/cm<sup>2</sup>).

### Lasers

All irradiations were performed on the epidermal side. For PDT, a CW argon-pumped dye laser (Coherent, Santa Clara, CA) tuned to 576 nm was used. For PDL therapy, a flashlamp pumped PDL (ScleroPlus™, Candela Corp., Wayland, MA) was used at a wavelength of 585 nm, pulse duration of 1.5 milliseconds, and laser spot size of 7 mm diameter (flattop beam profile).

### Photodynamic Therapy

BPD (Verteporfin®, QLT, Vancouver, BC, Canada) liposomal powder was reconstituted in water at a concentration of 1 mg/ml. This working solution was protected from light and used within 1 hour of preparation. A 1.5 mg/kg aliquot of BPD solution was administered intravenously via the installed jugular venous catheter using a 1 ml syringe equipped with a 23-gauge needle. In humans, the dose of BPD for ophthalmologic indications is 6 mg/m<sup>2</sup> [13] although up to 14 mg/m<sup>2</sup> has been used in studies for treatment of non-melanoma skin cancers [28]. Dosage by surface area of 6 mg/m<sup>2</sup> was determined for hamsters using a proposed modified Meeh-Rubner equation [29], resulting in a dose of approximately 1.5 mg/kg. Post-BPD injection, animals were housed in dark isolation. Fifteen minutes after completion of BPD injection, 576-nm CW laser irradiation was applied at an irradiance of 100 mW/cm<sup>2</sup> for 4-16 minutes, yielding a total radiant exposure of 25, 50, 75, or 96 J/cm<sup>2</sup> ("PDT" entry in Table 1).

### PDL Irradiation

Epidermal PDL irradiation was performed at a radiant exposure of 7 J/cm<sup>2</sup> (Table 1). The laser spot was concentric with the clear aperture of the dorsal window chamber. Cryogen spray cooling was used with a 30 milliseconds spurt duration and a 20 milliseconds delay between the end of the spurt and onset of the laser pulse, to mimic a typical clinical treatment protocol.

### PDT+PDL

Animals in the PDT+PDL groups received PDT as described above followed immediately by PDL therapy.

**Laser Speckle Imaging**—Laser speckle imaging (LSI) was performed prior to, immediately after, and 1, 3, and 5 days post-intervention. LSI has been used previously to measure blood

flow dynamics in the rodent dorsal window chamber model with PDL therapy [8,18,27]. The image processing algorithm has been described previously in detail [30,31]. With this algorithm, raw speckle images were converted to speckle flow index (SFI) images. All animals were also examined for adverse cutaneous effects (blistering, scabbing, or ulceration) before imaging.

**Data and Statistical Analyses**—Mean percent changes from immediately post-intervention, and 1, 3, and 5 days post-intervention were calculated relative to pre-intervention and averaged. Mean percent change and standard errors from before treatment to immediately after, and 1, 3, and 5 days post-intervention were estimated for each study group. Changes over time were investigated for each experimental group using a repeated measures one-way analysis of variance model in Prism software (Version 4, GraphPad Software Inc., San Diego, CA). Differences between groups were investigated by inclusion of a grouping factor and testing significance of the group-time interaction. Due to variability and small numbers in the control groups, there was limited power to detect group differences. Thus, between-group comparisons were tested with significance level of  $P<0.05$  without adjustment for multiple comparisons.

## RESULTS

Mean time-resolved changes in SFI values for each intervention group are summarized in Figure 1 and Table 2. Figure 2 provides representative SFI images. Overall, we observed two general results in response to a therapeutic intervention: (1) absence of persistent vascular shutdown and (2) presence of persistent vascular shutdown.

### Controls

In the saline control group, SFI values were relatively stable until day 3 when an increase in flow was noted that was further augmented at day 5 (Figs. 1a and 2a). This increase in blood flow is likely secondary to an inflammatory response to the dorsal window surgery.

In the BPD control group, there was an increase in SFI values through day 3. However, by day 5, SFI values returned to near those observed immediately after BPD infusion (Fig. 1a, Table 2). SFI values did not change significantly across time for either control group ( $P=0.53$  and  $P=0.37$ , respectively).

### Absence of Persistent Vascular Shutdown

PDL alone resulted in an immediate decrease in flow (Fig. 1a). However, by day 3, restoration of blood flow was observed with dramatic reperfusion over baseline by day 5 (Fig. 2d; repeated measures ANOVA showed no significant changes over time,  $P=0.12$ ).

PDT at  $25 \text{ J/cm}^2$  resulted in an immediate increase in perfusion immediately post-intervention and then minimal change in SFI values over the 5-day observation period (repeated measures ANOVA  $P=0.97$  for change over time; Figs. 1a and 2b). The acute increase in perfusion during PDT has been observed previously by us [18] and other researchers [32], and is assumed to be due to the expected blood flow increase with enhanced oxygen consumption during the photochemical intervention.

PDT alone at  $50 \text{ J/cm}^2$  and PDT+PDL at  $25 \text{ J/cm}^2$  resulted in an initial increase in SFI values immediately post-intervention (Fig. 1a). Reduction of blood flow was noted on day 1 with reperfusion over subsequent days, although perfusion remained below pre-intervention values (Fig. 2e). SFI values were not significantly different as compared to saline control (repeated

measures ANOVA,  $P=0.25$  and  $0.40$  for change over time in PDT alone at  $50 \text{ J/cm}^2$  and PDT +PDL at  $25 \text{ J/cm}^2$ , respectively).

The mean blood flow reduction was greater with PDT+PDL at  $25 \text{ J/cm}^2$  as compared to PDT alone at  $25 \text{ J/cm}^2$  and PDL alone, although differences were not statistically significant (repeated measures ANOVA group $\times$ time interaction,  $P=0.06$  and  $0.14$ , respectively).

### Presence of Persistent Vascular Shutdown

PDT alone at  $75 \text{ J/cm}^2$  and  $96 \text{ J/cm}^2$ , and PDT+PDL at  $75 \text{ J/cm}^2$  resulted in prolonged flow diminution (Figs. 1b and 2c,f). With PDT alone at  $75 \text{ J/cm}^2$  and  $96 \text{ J/cm}^2$ , initial increases in SFI values were noted immediately post-intervention. On day 5, vascular flow was maintained at a reduced level. Repeated measures ANOVA demonstrates statistically significant differences over time for PDT at  $75 \text{ J/cm}^2$  and suggestive differences for PDT at  $96 \text{ J/cm}^2$  ( $P=0.10$ ).

PDT+PDL at  $75 \text{ J/cm}^2$  achieved the greatest prolonged reduction of flow (Fig. 2f). We documented an initial decrease in SFI immediately post-intervention, with further reduction by day 1. SFI remained reduced at day 3 and continued to decline at day 5. PDT+PDL at  $75 \text{ J/cm}^2$  achieved statistically greater vascular shutdown by day 5 compared to PDL alone (repeated measures ANOVA for change over time,  $P=0.003$ ). Mean blood flow reduction was significantly greater compared to PDL alone (group $\times$ time interaction,  $P=0.029$ ).

### Ulceration

Ulceration was observed to occur when flow remained below SFI values of  $\sim 6,000$  for more than 1 day without subsequent flow restoration towards baseline values, suggesting a potential minimum tissue blood flow required to maintain epidermal viability. Epidermal skin changes (erythema, blistering, scabbing, or ulceration) were not observed either in saline control, BPD control, or PDL alone experiments. Ulcerations were noted at a frequency of 0/3 at PDT  $25 \text{ J/cm}^2$ , 1/3 at PDT  $50 \text{ J/cm}^2$ , 1/3 at PDT  $75 \text{ J/cm}^2$ , 0/3 at PDT  $96 \text{ J/cm}^2$ , 0/3 at PDT  $25 \text{ J/cm}^2$ +PDL, and 1/3 at PDT  $75 \text{ J/cm}^2$  +PDL by day 5 post-intervention.

## DISCUSSION

The experimental data of this present study demonstrate the potential efficacy of the PDL+PDT treatment protocol for achieving persistent vascular shutdown. The greatest reduction in flow from immediately post-intervention to day 5 was observed with PDT  $75 \text{ J/cm}^2$ +PDL ( $7 \text{ J/cm}^2$ ), in agreement with our previous results from experiments involving the CAM model [17] and the in vivo rat dorsal window chamber model [18]. Vascular shutdown achieved by day 5 with PDT+PDL ( $7 \text{ J/cm}^2$ ) at  $75 \text{ J/cm}^2$  was statistically significant compared to PDL alone. This was the only statistically significant difference observed between study groups. Given the observed efficacy of the PDT+PDL protocol, this intervention may offer a powerful alternative for treatment of cutaneous vascular lesions in humans, including PWS.

Observation of flow through day 5 of the PDL alone group revealed an initial decrease in flow, but then a gradual restoration and subsequent hyperperfusion at a similar percent change to that observed in control experiments (Fig. 1a). We predict the recovery of flow post-PDL to occur by a combination of the following three biological response mechanisms: (1) restoration of vascular patency by the reperfusion of existing incompletely photocoagulated microvasculature, (2) angiogenesis or the development of sprouts from existing vasculature, and (3) neovasclogenesis or the development of blood vessels independent of existing vasculature [33-36]. Our findings of persistent perfusion are consistent with results from several published studies [3,18,33-35] and demonstrate the difficulty of achieving persistent

flow reduction with PDL therapy alone. Studies are currently underway to evaluate methods to modulate these biological response events and hence achieve enhanced persistent vascular shutdown.

The vascular shutdown achieved with PDT+PDL therapy was enhanced compared to that achieved with either PDT or PDL alone (Table 2). The degree of shutdown was maintained through day 5 post-intervention, in contrast with trends observed with either PDT or PDL alone in which recurrence of flow was frequently noted. We hypothesize the enhanced efficacy of the PDT+PDL protocol may be due to: (1) preliminary PDT-induced endothelial cell wall damage, resulting in enhanced PDL photocoagulation; and/or (2) enhanced photocoagulation of small vessels typically resistant to PDL therapy due to a decreased ratio of vessel surface area to cross-sectional area that occurs due to PDT-induced vasodilatation [37,38]. Future experiments are planned to further study the underlying mechanism.

A 5-day observation period was reported; however, we did monitor vascular changes and superficial cutaneous effects (blistering, scabbing, or ulceration) for up to 14 days. Fascial overgrowth within the majority of the windows limited the visibility of the vasculature after day 5 post-intervention and thus day 5 post-intervention was consistently the longest time point possible for LSI evaluation and data acquisition. Since the completion of this study, we have utilized a mouse model, which allows post-intervention evaluations for 14-28 days.

Ulceration was observed in some of the PDT and PDT+PDL experiments. We believe that ulceration is a limitation of the dorsal window chamber and does not indicate that ulceration will occur when these therapeutic interventions are introduced for treatment of vascular lesions in humans. In fact, clinical studies evaluating the PDT+PDL protocol for treatment of PWS are underway and no epidermal ulcerations or scarring have been observed to date at the same therapeutic doses used in this study (KMK, unpublished work). In vivo skin can remain viable despite substantial photocoagulation of the superficial vascular plexus due to perfusion from the deep vascular plexus. With the dorsal window chamber model, there is no residual deeper vascular plexus to maintain oxygen delivery. To confirm our hypothesis that the dorsal window chamber is more prone to ulceration than in vivo skin, four hamsters without the dorsal skin fold window chamber installed were depilated and subjected to PDT at 96 J/cm<sup>2</sup> using the same protocol, and followed for up to 14 days post-intervention for ulceration (KMK, unpublished work). No epidermal ulcerations or scarring were observed in any of the animals. In the present study, ulceration did not occur in the control or PDL alone groups because observed flow diminution was much less compared to that achieved with higher radiant exposure and combined PDT+PDL interventions. It is acknowledged that PDT can result in extensive and deep vascular shutdown, which can lead to skin infarction and epidermal ulceration [22]. Hence, further study is required to confirm selection of treatment parameters, which will prevent elimination of deep cutaneous vasculature and avoid skin infarction.

Another observation from this study is that long-term monitoring of microvascular dynamics is crucial in the evaluation of PDT and PDL outcomes and efficacy. In agreement with previously reported data [8], data from this study confirms that immediate (<24 hours) vascular responses may differ greatly from those observed several days post-intervention (Fig. 1). Specifically, PDT alone at 50 J/cm<sup>2</sup>, 75 J/cm<sup>2</sup>, and 96 J/cm<sup>2</sup> resulted in an immediate increase in perfusion followed by a reduction in perfusion by day 1. The initial immediate increase in flow was hypothesized to be related to PDT-induced hypoxia and/or inflammatory mechanisms [32]. Furthermore, as noted previously, continued observation of study groups demonstrated reperfusion by day 5 in many of the experiments in which PDT alone or PDL alone was implemented. Such return of vascular flow as a result of reperfusion or angiogenesis may be a critical factor limiting the efficacy of these treatments in current clinical practice and deserves further study.

## CONCLUSIONS

PDT+PDL demonstrated enhanced and persistent blood flow reduction compared to PDT or PDL alone. The PDT+PDL approach has potential for considerable superficial vascular destruction and as such, should be considered as a treatment modality for cutaneous vascular lesions. Evaluation of blood flow changes suggests that the immediate response may not persist and that monitoring over a longer period is crucial for accurate assessment of light-based vascular interventions.

## ACKNOWLEDGMENTS

This work was supported in part by grants obtained from the National Institutes of Health (AR51443 to KMK), Sturge Weber Foundation (KMK), American Cancer Society Institutional Research Grant (ACS-IRG 98-279-04 to BC), Arnold and Mabel Beckman Foundation, and the American Society for Laser Medicine and Surgery (JC). Institutional support was provided by the National Institutes of Health Laser Microbeam and Medical Program (LAMMP). BPD was provided by QLT (Vancouver, BC, Canada). We thank Laurie Newman for assistance with animal handling, Drs. Sol Kimel and Lars Svaasand for their advice and assistance, and researchers in the Choi lab for assistance with the in vivo imaging. We also thank Dr. Amy Tsai and Ms. Cynthia Walsler from the Department of Bioengineering at University of California, San Diego, for training on the jugular venous catheterization protocol and technical assistance.

Contract grant sponsor: American Cancer Society Institutional Research ACS-; Contract grant number: IRG 98-279-04; Contract grant sponsor: Arnold and Mabel Beckman Foundation; Contract grant sponsor: American Society for Laser Medicine and Surgery; Contract grant sponsor: National Institutes of Health; Contract grant number: AR051443; Contract grant sponsor: Laser Microbeam and Medical Program (LAMMP); Contract grant sponsor: NIH Biomedical Technology Resource, University of California, Irvine; Contract grant number: #P41-RR01192; Contract grant sponsor: Sturge-Weber Foundation.

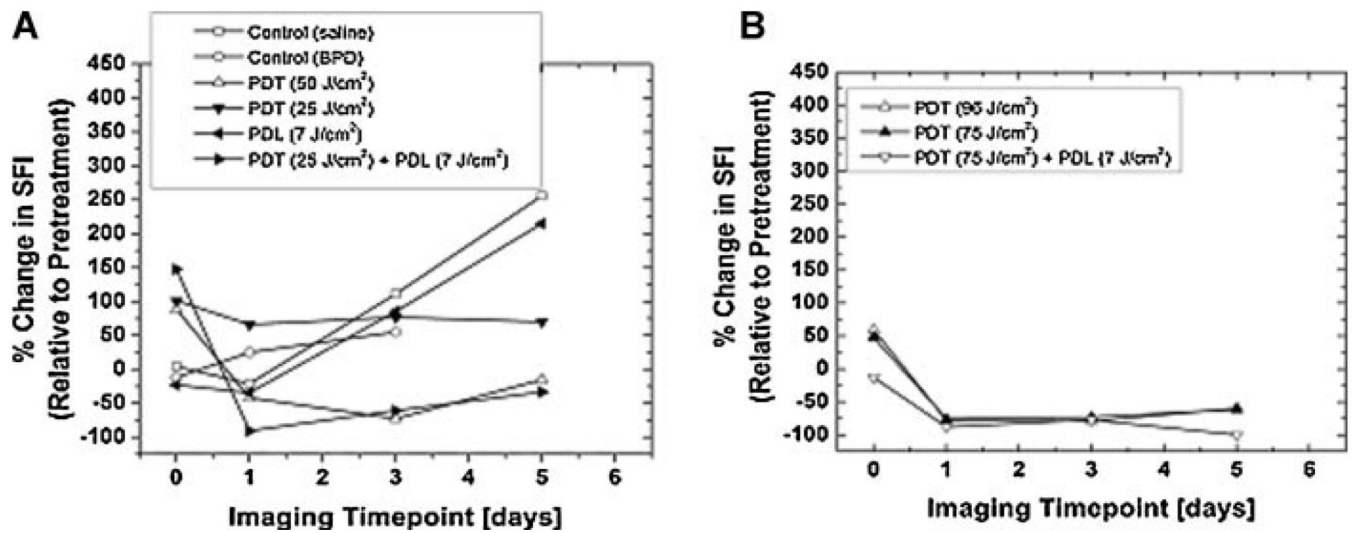
## REFERENCES

1. Jacobs AH, Walton RG. The incidence of birthmarks in the neonate. *Pediatrics* 1976;58:218–222. [PubMed: 951136]
2. Morelli JG, Huff JC, Weston WL. Treatment of congenital telangiectatic vascular malformations with the pulsed-dye laser (585 nm). *Pediatrics* 1993;92:603–606. [PubMed: 8414835]
3. Kelly KM, Choi B, McFarlane S, Motosue A, Jung B, Khan MH, Ramirez-San-Juan JC, Nelson JS. Description and analysis of treatments for port-wine stain birthmarks. *Arch Facial Plast Surg* 2005;7:287–294. [PubMed: 16172335]
4. Edstrom DW, Hedblad MA, Ros AM. Flashlamp pulsed dye laser and argon-pumped dye laser in the treatment of port wine stains: A clinical and histological comparison. *Br J Dermatol* 2002;146:285–289. [PubMed: 11903241]
5. Kelly KM, Nanda VS, Nelson JS. Treatment of port-wine stain birthmarks using the 1.5-msec pulsed dye laser in conjunction with cryogen spray cooling. *Dermatol Surg* 2002;4:309–313. [PubMed: 11966787]
6. Kauvar AN, Geronemus RG. Repetitive pulsed dye laser treatments improve persistent port-wine stains. *Dermatol Surg* 1995;6:515–521. [PubMed: 7773599]
7. Norvang LT, Fiskerstrand EJ, Nelson JS, Berns MW, Svaasand LO. Epidermal melanin absorption in human skin. *Proc SPIE* 1996;2624:143–154.
8. Choi B, Jia W, Channual J, Kelly KM, Lotfi J. The importance of long-term monitoring to evaluate the microvascular response to light-based therapies. *J Invest Dermatol* 2008;128(2):485–488. [PubMed: 17657245]
9. Nelson, JS.; McCullough, JL.; Berns, MW. Principles and applications of photodynamic therapy in dermatology. In: Arndt, KA.; Dover, JE.; Olbricht, SA., editors. *Lasers in cutaneous and aesthetic surgery*. Lippincott-Raven; Philadelphia, PA: 1997. p. 349-382.
10. Zuluaga MF, Mailhos C, Robinson G, Shima DT, Gurny R, Lange N. Synergies of VEGF inhibition and photodynamic therapy in the treatment of age-related macular degeneration. *Invest Ophthalmol Vis Sci* 2007;4:1767–1772. [PubMed: 17389510]

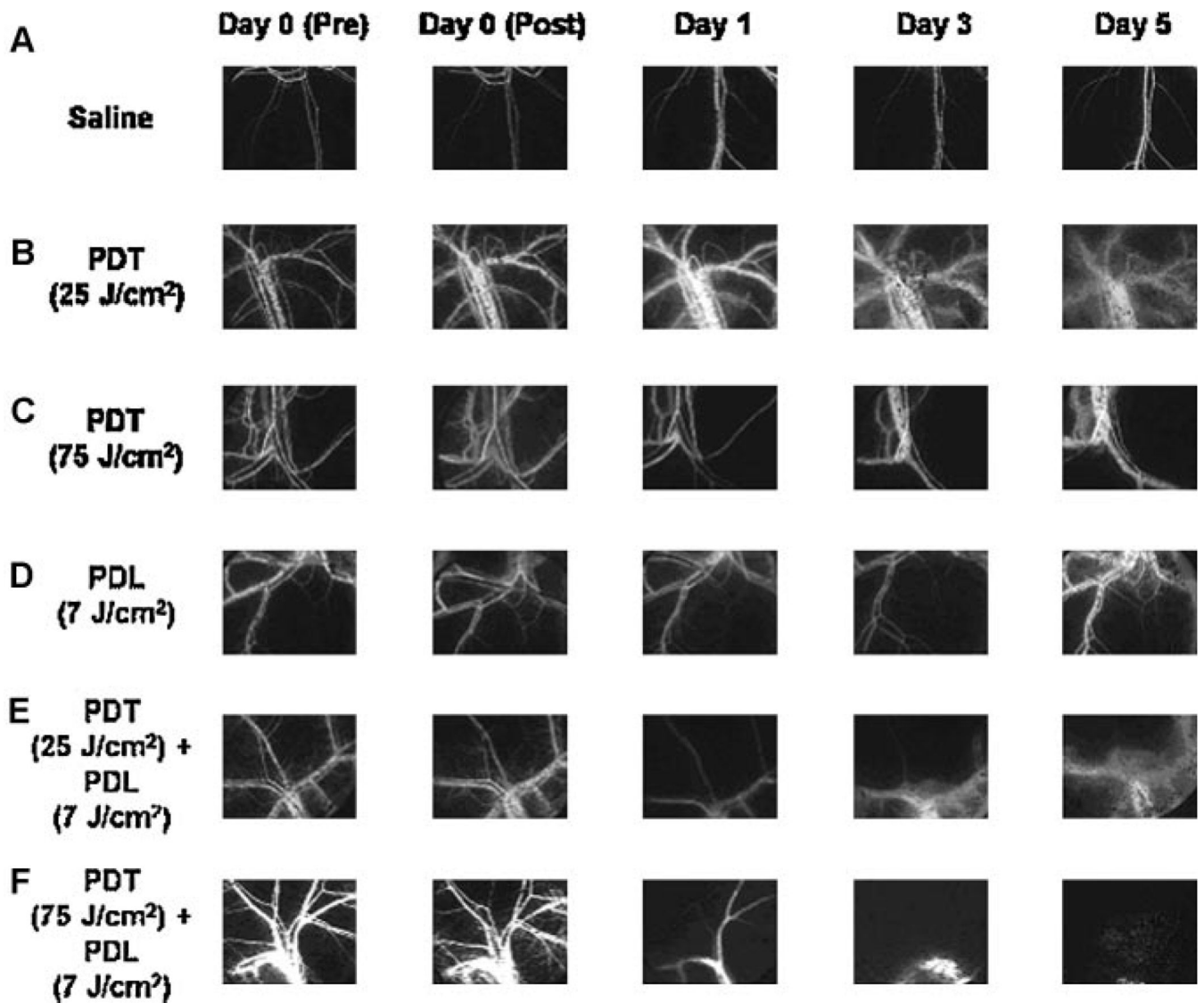
11. Nelson, JS.; McCullough, JL.; Berns, MW. Principles and applications of photodynamic therapy in dermatology. In: Arndt, KA.; Dover, JE.; Olbricht, SA., editors. *Lasers in cutaneous and aesthetic surgery*. Lippincott-Raven; Philadelphia, PA: 1997. p. 349-382.
12. Barr H, Traulau CJ, MacRobert AJ, Krasner N, Boulos PB, Clark CG, Bown SG. The contrasting mechanisms of colonic collagen damage between photodynamic therapy and thermal injury. *Photochem Photobiol* 1987;46:795–800. [PubMed: 3441502]
13. Sickenberg M, Schmidt-Erfurth U, Miller JW, Pournaras CJ, Zografos L, Piguet B, Donati G, Laque H, Barbazetto I, Gragoudas ES, Lane A-M, Birngruber R, van den Bergh H, Strong A, Manjuris U, Gray T, Fsadni M, Bressler NM. A preliminary study of photodynamic therapy using verteporfin for choroidal neovascularization in pathologic myopia, ocular histoplasmosis syndrome, angioid streaks, and idiopathic causes. *Arch Ophthalmol* 2003;118:327–339. [PubMed: 10721954]
14. Jeffes EW, McCullough JK, Weinstein GD, Fergin PE, Nelson JS, Shull TF, Simpson KR, Bukaty LM, Hoffman WL, Fong NL. Photodynamic therapy of actinic keratoses with topical 5-aminolevulinic acid (ALA): A pilot doseranging study. *Arch Dermatol* 1997;133:727–732. [PubMed: 9197826]
15. Taub AF. Photodynamic therapy: Other uses. *Dermatol Clin* 2007;1:101–109. [PubMed: 17126748]
16. Marcus, SL. Lasers in photodynamic therapy. In: Waynant, RW., editor. *Lasers in Medicine*. CRC Press; Boca Raton: 2002. p. 287-324.
17. Kelly KM, Kimel S, Smith T, Stacy A, Hammer-Wilson MJ, Svaasand LO, Nelson JS. Combined photodynamic and photothermal induced injury enhances damage to in vivo model blood vessels. *Lasers Surg Med* 2004;34:407–413. [PubMed: 15216534]
18. Smith TK, Choi B, Ramirez-San-Juan JC, Nelson JS, Osann K, Kelly KM. Microvascular blood flow dynamics associated with photodynamic therapy, pulsed dye laser irradiation and combined regimens. *Lasers Surg Med* 2006;5:532–539. [PubMed: 16615132]
19. Tsoukas MM, Lin GC, Lee MS, Anderson RR, Kollias N. Predictive dosimetry for threshold phototoxicity in photodynamic therapy on normal skin: Red wavelengths produce more extensive damage than blue at equal threshold doses. *J Invest Dermatol* 1997;108:501–505. [PubMed: 9077481]
20. Tsoukas MM, Gonzalez S, Flotte TJ, Anderson RR, Sherwood ME, Kollias N. Wavelength and fluence effect on vascular damage with photodynamic therapy on skin. *J Invest Dermatol* 2000;114:303–308. [PubMed: 10651990]
21. Fingar VH, Kik PK, Haydon PS, Cerrito PB, Tseng M, Abang E, Wieman TJ. Analysis of acute vascular damage after photodynamic therapy using benzoporphyrin derivative (BPD). *Br J Cancer* 1999;79:1702–1708. [PubMed: 10206280]
22. Lin GC, Tsoukas ML, Lee MS, Gonzalez S, Vibhagool C, Anderson RR, Kollias N. Skin necrosis due to photodynamic action of benzoporphyrin depends on circulating rather than tissue drug levels: Implications for control of photodynamic therapy. *Photochem Photobiol* 1998;68:575–583. [PubMed: 9796441]
23. Houle JM, Strong A. Duration of skin photosensitivity and incidence of photosensitivity reactions after administration of verteporfin. *Retina* 2002;22:691–697. [PubMed: 12476093]
24. Gourgouliatos ZF, Welch AJ, Diller KR. Measurements of argon laser light attenuation in the skin in vivo using a unique animal model. *Lasers Med Sci* 1992;7:63.
25. Barton JK, Vargas G, Pfefer TJ, Welch AJ. Laser fluence for permanent damage of cutaneous blood vessels. *Photochem Photobiol* 1999;70:916–920. [PubMed: 10628303]
26. Vargas G, Chan KF, Thomsen SL, Welch AJ. Use of osmotically active agents to alter optical properties of tissue: Effects on the detected fluorescence signal measured through skin. *Lasers Surg Med* 2001;29:213–220. [PubMed: 11573222]
27. Choi B, Kang NM, Nelson JS. Laser speckle imaging for monitoring blood flow dynamics in the in vivo rodent dorsal skin fold model. *Microvasc Res* 2004;68:143–146. [PubMed: 15313124]
28. Hobbs LH, Tope WD, Lee PK, Elmets C, Provost N, Chan A, Neyndorff H, Su XY, Jain H, Hamzavi I, McLean D, Bissonette R. Photodynamic therapy of multiple nonmelanoma skin cancers with verteporfin and red light-emitting diodes: Two-year results evaluating tumor response and cosmetic outcomes. *Arch Dermatol* 2004;149:26–32. [PubMed: 14732656]



29. Ohwada K. Body surface area of the golden Syrian hamster. Body surface area of the golden Syrian hamster. *Jikken Dobutsu* 1992;41(2):221–224. [PubMed: 1577083]
30. Dunn AK, Bolay H, Moskoqitz MA, Boas DA. Dynamic imaging of cerebral flow using laser speckle. *J Cereb Blood Flow Metab* 2001;1:195–201. [PubMed: 11295873]
31. Briers JD. Laser Doppler, speckle and related techniques for blood perfusion mapping and imaging. *Physiol Meas* 2001;22:R35–R66. [PubMed: 11761081]
32. Yu GQ, Durduran T, Zhou C, Wang HW, Putt ME, Saunders HM, Sehgal CM, Glatstein E, Yodh AG, Busch TM. Noninvasive monitoring of mural tumor blood flow during and after photodynamic therapy provides early assessment of therapeutic efficacy. *Clin Cancer Res* 2005;11:3543–3552. [PubMed: 15867258]
33. Heger M, Beek JF, Moldovan NI, van der Horst CM, van Gemert MJ. Towards optimisation of selective photothermolysis: Prothrombotic pharmaceutical agents as potential adjuvants in laser treatment of port wine stains. A theoretical study. *Thromb Haemost* 2005;93(2):242–256. [PubMed: 15711739]
34. Tan OT, Whitaker D, Garden JM, Murphy G. Pulsed dye laser (577 nm) treatment of portwine stains: Ultrastructural evidence of neovascularization and mast cell degranulation in healed lesions. *J Invest Dermatol* 1988;90(3):395–398. [PubMed: 2450146]
35. Huikeshoven M, Koster P, de Borgie C, Beek J, van Gemert M, van der Horst C. Redarkening of port-wine stains 10 years after pulsed-dye-laser treatment. *N Engl J Med* 2007;356:1235–1240. [PubMed: 17377161]
36. Mancuso MR, Davis R, Norberg SM, O'Brien S, Sennino B, Nakahara T, Yao VJ, Inai T, Brooks P, Freimark B, Shalinsky DR, Hu-Lowe DD, McDonald DM. Rapid vascular regrowth in tumors after reversal of VEGF inhibition. *J Clin Invest* 2006;116:2610–2621. [PubMed: 17016557]
37. Aguilar G, Svaasand LO, Nelson JS. Effects of hypobaric pressure on human skin: Feasibility study for port wine stain laser therapy (part I). *Lasers Surg Med* 2005;36:124–129. [PubMed: 15704161]
38. Aguilar G, Franco W, Liu J, Svaasand LO, Nelson JS. Effects of hypobaric pressure on human skin: Implications for cryogen spray cooling (part II). *Lasers Surg Med* 2005;36:130–135. [PubMed: 15704166]



**Fig. 1.** Mean blood flow change for eight experimental groups. Chronic LSI of the hamster dorsal window chamber micro-vascular network demonstrates two hemodynamic trends: **(A)** absence of persistent vascular shutdown and **(B)** presence of persistent vascular shutdown. Day 0 data points represent the percent change in SFI after intervention. A value of — 100% represents complete vascular shutdown. Based on application of repeated measures ANOVA to the experimental data, combination of PDT at 75 J/cm<sup>2</sup> with PDL therapy at 7 J/cm<sup>2</sup> [shown in **(B)**] resulted in a significant reduction in blood flow as compared to PDL therapy alone [shown in **(A)**] ( $P = 0.003$ ).



**Fig. 2.** Representative SFI images [ $5 \times 4 \text{mm}^2$  ( $640 \times 480$  pixels)] of the microvasculature following interventions: (A) Saline control, (B) PDT at  $25 \text{ J/cm}^2$ , (C) PDT at  $75 \text{ J/cm}^2$ , (D) PDL at  $7 \text{ J/cm}^2$ , (E) PDT ( $25 \text{ J/cm}^2$ )+PDL, and (F) PDT ( $75 \text{ J/cm}^2$ ) PDL from pre-intervention to day 5 post-intervention. Mean percent changes in SFI from immediately post-intervention, and 1, 3, and 5 days post-intervention were calculated relative to pre-intervention. Perfusion reduction on day 1 post-intervention was achieved with PDT at  $75 \text{ J/cm}^2$ , PDL alone, and PDT+PDL. However, by day 5 post-intervention, recovery of flow was observed with PDT alone and PDL alone. Combined PDT (at 25 or  $75 \text{ J/cm}^2$ )+ PDL resulted in greater flow reduction than PDT (at 25 or  $75 \text{ J/cm}^2$ ) or PDL alone. PDT ( $75 \text{ J/cm}^2$ )+PDL resulted in the greatest prolonged reduction in vascular perfusion ( $P = 0.003$ ).

**TABLE 1**

## Study Groups

Study group	No. of animals	BPD	PDT	PDL
Control (saline)	3	N/A	N/A	N/A
Control (BPD)	2	1.5 mg/kg	N/A	N/A
PDT 25 J/cm <sup>2</sup>	3	1.5 mg/kg	25 J/cm <sup>2</sup>	N/A
PDT 50 J/cm <sup>2</sup>	3	1.5 mg/kg	50 J/cm <sup>2</sup>	N/A
PDT 75 J/cm <sup>2</sup>	3	1.5 mg/kg	75 J/cm <sup>2</sup>	N/A
PDT 96 J/cm <sup>2</sup>	3	1.5 mg/kg	96 J/cm <sup>2</sup>	N/A
PDL 7 J/cm <sup>2</sup>	3	N/A	N/A	7 J/cm <sup>2</sup>
PDT 25 J/cm <sup>2</sup> + PDL 7 J/cm <sup>2</sup>	3	1.5 mg/kg	25 J/cm <sup>2</sup>	7 J/cm <sup>2</sup>
PDT 75 J/cm <sup>2</sup> + PDL 7 J/cm <sup>2</sup>	3	1.5 mg/kg	75 J/cm <sup>2</sup>	7 J/cm <sup>2</sup>

**TABLE 2**  
 Mean Percent Change in Speckle Flow Index (SFI) Calculated for Control and Experimental Groups Immediately After and Up To 5 Days Post-Intervention

Study group	Day 0 (post)		Day 1		Day 3		Day 5	
	Mean	SE	Mean	SE	Mean	SE	Mean	SE
Control (saline)	4.4	22	-21	30	111	164	256	298
Control (BPD)	-12	32	25	55	399	486	—	—
PDT 25 J/cm <sup>2</sup>	101	40	66	57	77	93	70	73
PDT 50 J/cm <sup>2</sup>	89	62	-42	37	-73	14	-15	63
PDT 75 J/cm <sup>2</sup>	48	13	-76	12	-73	19	-62	38
PDT 96 J/cm <sup>2</sup>	59	68	-78	14	-79	18	-60	19
PDL 7 J/cm <sup>2</sup>	-23	20	-34	14	85	109	215	81
PDT 25 J/cm <sup>2</sup> + PDL 7 J/cm <sup>2</sup>	148	177	-91	5	-61	39	-33	67
PDT 75 J/cm <sup>2</sup> + PDL 7 J/cm <sup>2</sup> <sup>a</sup>	-13	20	-88	4	-77	16	-100	0

—= No data available for day 5.

<sup>a</sup> Statistically greater vascular shutdown by day 5 compared to PDL alone (repeated measures ANOVA,  $P=0.003$ ).