

UC Davis

Dermatology Online Journal

Title

Morbilliform eruption related to eltrombopag: emerging data on the cutaneous toxicity of thrombopoietin receptor agonists

Permalink

<https://escholarship.org/uc/item/8pk3534w>

Journal

Dermatology Online Journal, 22(6)

Authors

Kazemi, Tiana
Martin, Sabrina
Worswick, Scott

Publication Date

2016

DOI

10.5070/D3226031325

Copyright Information

Copyright 2016 by the author(s). This work is made available under the terms of a Creative Commons Attribution-NonCommercial-NoDerivatives License, available at <https://creativecommons.org/licenses/by-nc-nd/4.0/>

Peer reviewed

Case presentation

Morbilliform eruption related to eltrombopag: emerging data on the cutaneous toxicity of thrombopoietin receptor agonists

Tiana Kazemi BA¹, Sabrina Martin MD², Scott Worswick MD²

Dermatology Online Journal 22 (6): 13

¹ David Geffen School of Medicine at UCLA

² Department of Medicine, David Geffen School of Medicine at UCLA

Correspondence:

Scott Worswick
200 Medical Plaza Suite 450
Los Angeles CA, 90095
Tel. (310) 917-3376
sworswick@mednet.ucla.edu

Abstract

Eltrombopag is a thrombopoietin mimetic used for the treatment of thrombocytopenia in patients with chronic immune thrombocytopenia, hepatitis C patients undergoing antiviral therapy, and thrombocytopenia secondary to aplastic anemia that is refractory to immunosuppressive therapy. We report a case of a 25-year-old man with a history of aplastic anemia who presented with fever and a monomorphic papular rash. Subsequent labs, biopsy, and clinical course favored drug-induced cutaneous toxicity, with eltrombopag as the likely culprit. Eltrombopag is generally well-tolerated; however, clinicians should be aware of the possibility of dose-independent drug-induced cutaneous toxicity with this medication. This report reviews the mechanism and use of eltrombopag along with a summary of associated adverse cutaneous reactions.

Keywords: eltrombopag, cutaneous drug rash, drug eruption, DRESS, erythroderma, ITP

Introduction

Eltrombopag is a thrombopoietin mimetic that binds to the c-mpl receptor and induces megakaryopoiesis and platelet production via JAK-STAT signaling pathway activation [1, 2]. It is indicated for patients with chronic immune thrombocytopenia, hepatitis C patients undergoing antiviral therapy, and refractory thrombocytopenia secondary to aplastic anemia [1, 3, 4].

Although eltrombopag has no indications of dose-limiting toxicity and is generally well-tolerated [2, 3, 5, 6, 7, 8], there have been some reported cases of drug-induced cutaneous toxicity associated with its use [2, 3, 9, 10]. We present a 25-year-old man with refractory aplastic anemia who developed a papular and petechial rash with fever following eltrombopag use. We also summarize the mechanism of eltrombopag and discuss reported adverse cutaneous reactions associated with this drug.

Case synopsis

A 25-year-old man was admitted for a non-pruritic rash and fever up to 103°F of two days duration accompanied by red eyes and oral sores. The eruption started on his shoulders and spread to his face, trunk, groin, and legs. He had recently undergone an NIH trial for refractory aplastic anemia six weeks prior to admission. This regimen began in late August and included IV horse antithymocyte globulin (hATG) infusion for four days, a prednisone taper over two weeks starting at 80mg PO daily, cyclosporine 250mg PO BID, and eltrombopag 150mg PO daily (with a plan to continue for three months). Concurrently, the patient was started on amlodipine, valacyclovir, pentamidine, and atovaquone for prophylaxis. Five weeks later, he presented to the emergency department with a rash and was treated empirically with levofloxacin, imipenem-cilastatin, and one dose of IVIG, given initial concern for a viral infection. His cyclosporine was stopped owing to this initial suspicion for infection.

Physical examination revealed 1-2 mm erythematous, discrete monomorphic papules and some petechiae symmetrically scattered on his face, chest, abdomen, back, bilateral arms, glans penis, and buttocks (Figure 1).

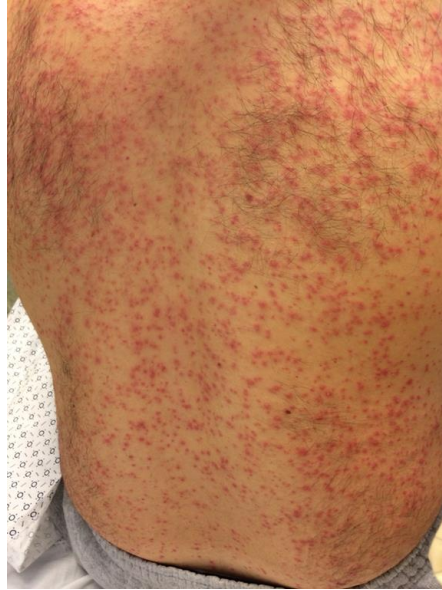

Figure 1. Monomorphic erythematous papules with petechiae

Round, shallow erosions with shaggy borders on the lower oral labial mucosa and a white-yellow plaque on the tongue were also noted. Labs revealed leukopenia, anemia, and thrombocytopenia but no eosinophilia. Renal and liver function tests were stable throughout hospitalization and all viral serologies were negative (including CMV, EBV, HHV6, HHV7, Parvovirus, Hepatitis panel, Rubella, Rubeola, and Coxsackie).

A punch biopsy obtained from the right shoulder demonstrated interface change along the dermal-epidermal junction with overlying hyperkeratosis and some spongiosis of the epidermis (Figure 2).

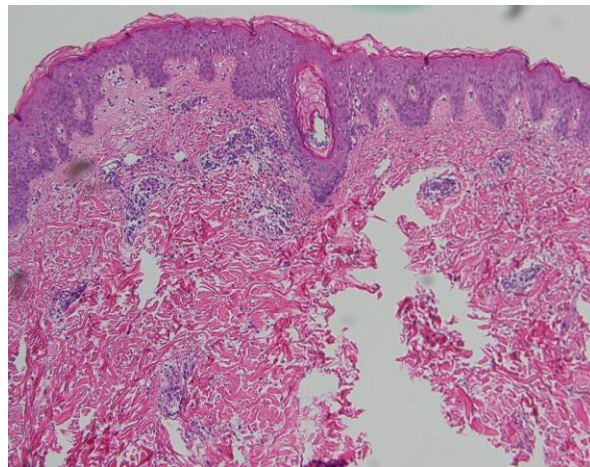


Figure 2. Interface changes and mild epidermal spongiosis

A superficial perivascular lymphohistiocytic inflammatory infiltrate with melanin incontinence was noted. Eosinophils were not prominent but were present. Given the interface change on biopsy and lack of any other symptoms clinically, a drug reaction was strongly favored over a viral exanthem.

Upon review of his most recent medications and their timing, eltrombopag was identified as a potential cause of the eruption and was stopped two days after admission, as were his other medications. The eruption coalesced into confluent, brightly erythematous patches with petechiae that then faded and healed with superficial desquamation in a cephalo-caudal direction. Complete resolution of the erythema with some residual desquamation was observed two weeks following discharge. The patient re-initiated the other medications that pre-dated the onset of rash (cyclosporine, valacyclovir, atovaquone, and amlodipine) and there was no recurrence at subsequent visits. Owing to the severity of the rash, the patient did not attempt re-initiation of eltrombopag.

Discussion

Eltrombopag is a highly selective non-peptide thrombopoietin mimetic that activates the transmembrane region of the hematopoietic growth factor receptor (c-mpl). Eltrombopag binds to c-mpl and activates the JAK-STAT (Janus kinase/signal transducers and activators of transcription) and MAPK (mitogen-activated protein kinase) signaling pathways, thereby inducing megakaryopoiesis and ultimately increasing platelet production in a dose-responsive manner [1, 2, 3, 5, 6, 10]. It is currently FDA approved for the treatment of thrombocytopenia in patients with chronic immune thrombocytopenia and in hepatitis C patients undergoing antiviral therapy [1]. Studies have also demonstrated the drug's efficacy in treating thrombocytopenia secondary to aplastic anemia that is refractory to immunosuppressive therapy [3, 4, 7]. Over 80% of ITP patients treated with eltrombopag demonstrate an increase in platelet count with minimal adverse effects [1]. In one phase II study, 40% of patients with thrombocytopenia secondary to aplastic anemia displayed a positive response with reports of sustained and durable hematopoiesis following drug discontinuation and no dose-limiting toxicity [7].

Eltrombopag is generally well tolerated [2, 3, 5, 6, 7, 8]. The most frequently cited side effects include dry mouth, headache, abdominal pain, nausea, and vomiting [5, 11]. In two different phase II and phase III studies, the incidence and severity of adverse effects were not significantly different between placebo and eltrombopag groups and there were no indications of dose-limiting toxicity [2, 8]. In addition, no worsening thrombocytopenia or serious bleeding was observed following drug discontinuation in the phase III study [8]. Some patients receiving eltrombopag in clinical trials developed mild and reversible transaminitis and elevated bilirubin levels but these were not associated with any clinically significant symptoms [6, 7].

There is limited data on adverse cutaneous reactions associated with eltrombopag use. Moulis et al. examined differences in adverse drug reaction patterns between eltrombopag and romiplostin (another thrombopoietin receptor agonist) and report four cases of rash with each drug although rash severity and characteristics are not provided [10]. Bussel et al. stated that three of eighty-eight patients in their phase II study developed a rash, however, rash severity and characteristics are also not reported [2]. In another phase II study by Olnes et al., two patients are reported as developing a rash, one of which is described as "severe." Further rash characteristics are not given in this series either [3].

Table 1. Summary of cutaneous reactions following eltrombopag use [10].

	Gender, Age (years)	Eltrombopag dose (mg/d)	Cutaneous Reaction (CR)	Time to CR	Management of CR
Our Patient	Male, 25	150	Exanthem Pruritus	5 weeks	Eltrombopag stopped Topical steroids
Meyer et al. Patient 1	Male, 81	25	Erythroderma Pruritus	9 weeks	Eltrombopag stopped Topical steroids Anti-histamines

Meyer et al. Patient 2	Male, 59	50	Exanthem Pruritus	3 months	Eltrombopag stopped Anti-histamines
Meyer et al. Patient 3	Female, 77	50	Exanthem Pruritus Oral erythema	2 days	Anti-histamines

Meyer et al. recently described adverse cutaneous reactions from eltrombopag in three immune thrombocytopenia patients, as described in Table 1. All patients initially discontinued eltrombopag, although one reinitiated treatment with addition of anti-histamines. The reaction is thought to be dose-independent, since lowering the dose to 25mg did not prevent an eruption. Two patients were switched to romiplostim and did not have recurrence of any cutaneous events [9]. Our patient was much younger and on a higher dose of eltrombopag, but his clinical examination was similar to previous cases. Despite the higher dosage, the time to adverse event of 5 weeks was similar to prior reports.

Drug-induced cutaneous toxicity can manifest in many forms. In the dermatologic literature, it seems to most often manifest as a pruritic morbilliform or papular rash. In more severe cases, total skin involvement with exfoliative dermatitis or erythroderma and mucosal involvement can be seen. These cutaneous changes can persist for weeks or months after removal of the offending agent without treatment. Eltrombopag-induced cutaneous toxicity is uncommon, but as evidenced by our case, can present with monomorphic papules, petechiae, and edema. Based on our case and prior reports, the rash is not dose-dependent and will resolve with cessation of the medication.

Conclusion

Here we describe the case of a young man with a monomorphic papular rash with fever, attributed to eltrombopag use. Upon stopping eltrombopag and initiating topical corticosteroid treatment, the rash showed gradual improvement in a cephalo-caudal manner with complete resolution occurring over two weeks. Although eltrombopag is generally well tolerated, clinicians should be aware of the risk for cutaneous toxicity with eltrombopag. We recommend stopping administration if an erythrodermic eruption develops; prior case reports suggest that the eruption is not dose-dependent. Although one study reports a cutaneous hypersensitivity reaction in both eltrombopag and romiplostim patients, there have been no other observations to suggest that it is unsafe to switch to another drug in the same class. Further studies are necessary determine if there is a risk of developing a systemic drug hypersensitivity reaction with eltrombopag and this type of cutaneous presentation.

References

1. Kuter DJ. Milestones in understanding platelet production: a historical overview. *Br J Haematol.* 2014;165(2):248-58. [PMID: 24528208] Kuter DJ. Milestones in understanding platelet production: a historical overview. *Br J Haematol.* 2014;165(2):248-58. [PMID: 24528208]
2. Bussel JB, Cheng G, Saleh MN, et al. Eltrombopag for the treatment of chronic idiopathic thrombocytopenic purpura. *N Engl J Med.* 2007;357(22):2237-47. [PMID: 18046028]
3. Olnes MJ, Scheinberg P, Calvo KR, et al. Eltrombopag and improved hematopoiesis in refractory aplastic anemia. *N Engl J Med.* 2012;367(1):11-9. [PMID: 22762314]
4. Willis L, Rexwinkle A, Bryan J, Kadia TM. Recent Developments in Drug Therapy for Aplastic Anemia. *Ann Pharmacother.* 2014;48(11):1469-1478. [PMID: 25184310]
5. Mihăilă RG, Cipăian RC. Eltrombopag in chronic hepatitis C. *World J Gastroenterol.* 2014;20(35):12517-21. [PMID: 25253952]
6. Garnock-jones KP. Eltrombopag: a review of its use in treatment-refractory chronic primary immune thrombocytopenia. *Drugs.* 2011;71(10):1333-53. [PMID: 21770480]
7. Desmond R, Townsley DM, Dumitriu B, et al. Eltrombopag restores trilineage hematopoiesis in refractory severe aplastic anemia that can be sustained on discontinuation of drug. *Blood.* 2014;123(12):1818-25. [PMID: 24345753]
8. Cheng G, Saleh MN, Marcher C, et al. Eltrombopag for management of chronic immune thrombocytopenia (RAISE): a 6-month, randomized, phase 3 study. *Lancet.* 2011;377(9763):393-402. [PMID: 20739054]
9. Meyer SC, Rovó A, Tsakiris DA, Scherer K, Tichelli A, Holbro A. Severe cutaneous toxicity related to Eltrombopag. *Br J Haematol.* 2013;160(3):412-4. [PMID: 23151239]
10. Moulis G, Bagheri H, Sailler L, et al. Are adverse drug reaction patterns different between romiplostim and eltrombopag? 2009-2013 French Pharmacovigilance assessment. *Eur J Intern Med.* 2014;25(8):777-80. [PIMD: 25242516]

11. McHutchison JG, Dusheiko G, Shiffman ML, et al. Eltrombopag for thrombocytopenia in patients with cirrhosis associated with hepatitis C. *N Engl J Med.* 2007;357(22):2227-36. [PMID: 18046027]