

UC Davis
Pediatrics

Title

Predictors of Cartilage Injury in Pediatric Patellar Instability Remain Unknown

Permalink

<https://escholarship.org/uc/item/8q1542nt>

Authors

Hamilton, Zachary T
Friel, Nicole A

Publication Date

2023

Data Availability

The data associated with this publication are not available for this reason: N/A

Predictors of Cartilage Injury in Pediatric Patellar Instability Remain Unknown

Introduction

- Pediatric patellofemoral instability, most commonly lateral patellar dislocation, can result in cartilage injury (chondral or osteochondral fracture) to the knee.
- Specific anatomical characteristics can predict the severity of patellar instability
- Can we identify anatomical predictors of cartilage injury in patients with patellar instability?

Design/Sample

- Study design: retrospective chart review
- Identified 71 patients with patellar instability, of which 34 had a loose body diagnosed by arthroscopy, and 37 did not have a loose body.
- Measured 5 anatomical characteristics on images:
 - Patellar height (Caton-Deschamps)
 - Translation of the tibial tubercle compared to the trochlear groove (TT-TG)
 - Trochlear Dysplasia (LTI, lateral trochlear inclination)
 - Patellar tilt
 - Lower extremity coronal plane alignment

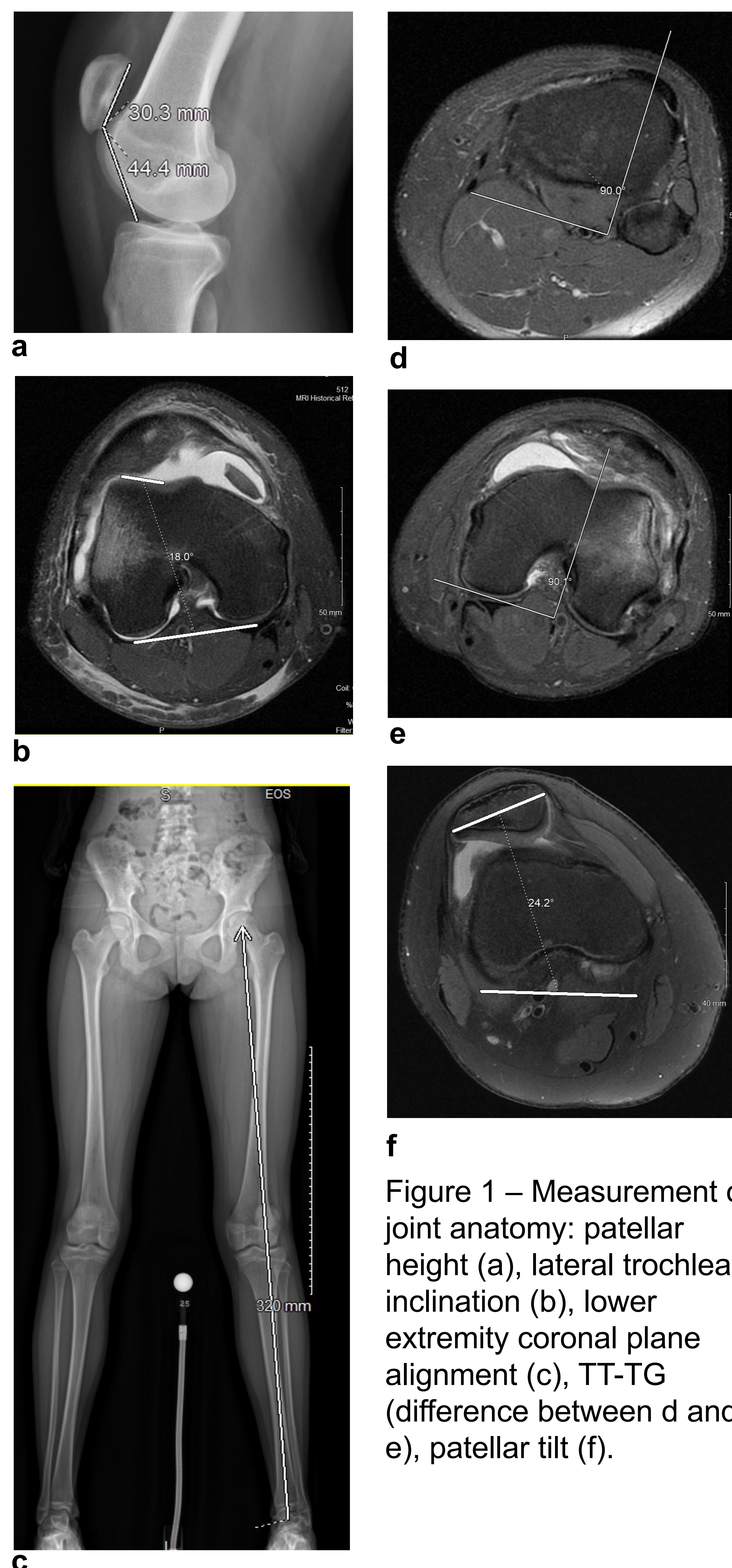


Figure 1 – Measurement of joint anatomy: patellar height (a), lateral trochlear inclination (b), lower extremity coronal plane alignment (c), TT-TG (difference between d and e), patellar tilt (f).

Results

Table 1
Patient demographic information

	Loose body	No loose body	All patients
Number of patients	34	37	71
Age, yrs	15.31 ± 2.10	15.11 ± 2.22	15.21 ± 2.15
Female, %	52.9	75.7	64.8
ICRS grade, %			
0	0	45	23.4
1	10.8	40	26
2	5.4	15	10.4
3	37.8	0	18.2
4	45.9	0	22.1
Bone involvement, %			
Yes	55.5	0	21.1
No	44.4	100	78.9

Table 2
Analysis of anatomical measurement association

	Loose body	No loose body	All patients	P value
Patellar height	1.25 ± 0.27	1.33 ± 0.21	1.29 ± 0.24	0.182
Patellar translation (TT-TG)	15.29 ± 5.14	15.76 ± 5.46	15.54 ± 5.28	0.716
Trochlear dysplasia (LTI)	15.05 ± 4.85	17.52 ± 6.31	16.36 ± 5.76	0.078
Patellar tilt, degrees	22.53 ± 9.96	26.53 ± 11.57	24.64 ± 10.95	0.133
LE coronal plane alignment	1.11 ± 0.70	1.03 ± 0.65	1.06 ± 0.67	0.65

Conclusions

- Measurements of patellar height, TT-TG, extent of trochlear dysplasia, patellar tilt, and lower extremity coronal plane alignment are not good predictors of chondral damage in skeletally immature individuals with patellar instability.
- There was no statistical difference in any of these measurements between the loose body and no loose body groups

Further Study

- Further investigation of joint measurement is required to determine the anatomical predictors of chondral damage in skeletally immature patients with patellar instability.

Acknowledgements

- Mentor: Nicole A. Friel, MD
- UC Davis School of Medicine
- Shriners Children's Northern California