

UC Davis

UC Davis Previously Published Works

Title

Surgical management of symptomatic Tarlov cysts: cyst fenestration and nerve root imbrication—a single institutional experience

Permalink

<https://escholarship.org/uc/item/8qd8t2zs>

Journal

Journal of Spine Surgery, 5(4)

ISSN

2414-469X

Authors

Medani, Khalid
Lawandy, Shokry
Schrot, Rudolph
[et al.](#)

Publication Date

2019-12-01

DOI

10.21037/jss.2019.11.11

Peer reviewed



Surgical management of symptomatic Tarlov cysts: cyst fenestration and nerve root imbrication – a single institutional experience

Khalid Medani¹, Shokry Lawandy¹, Rudolph Schrot^{2,3}, Jose N. Binongo⁴, Kee D. Kim¹, Ripul R. Panchal^{1,3}

¹Department of Neurological Surgery, University of California Davis, Sacramento, CA, USA; ²Department of Neurological Surgery, Sutter Medical Center Sacramento, Sacramento, CA, USA; ³Touro University College of Osteopathic Medicine, Vallejo, CA, USA; ⁴Department of Biostatistics & Bioinformatics, Rollins School of Public Health, Emory University, Atlanta, GA, USA

Contributions: (I) Conception and design: K Medani, S Lawandy, R Schrot; (II) Administrative support: RR Panchal, KD Kim; (III) Provision of study materials or patients: R Schrot; (IV) Collection and assembly of data: K Medani, S Lawandy; (V) Data analysis and interpretation: Jose Binongo (VI) Manuscript writing: All authors; (VII) Final approval of manuscript: All authors.

Correspondence to: Ripul R. Panchal, DO. Assistant Professor, Department of Neurological Surgery, University of California, Davis Medical Center, 4860 Y Street, Suite 3740, Sacramento, CA 95817, USA. Email: ripulpanchal@gmail.com.

Background: Tarlov cyst disease is a collection of cerebrospinal fluid between the endoneurium and perineurium of spinal, usually sacral, nerve roots. These cysts can become symptomatic in 20% of patients, causing lower back pain, radiculopathy, bladder and bowel dysfunction necessitating medical or surgical intervention. Different surgical and non-surgical modalities have been described for the treatment of symptomatic Tarlov cysts. However, there has been no published study that examined types of surgical techniques side by side. Our study presents a preliminary experience in the surgical management of symptomatic Tarlov cysts using two surgical techniques: cyst fenestration and nerve root imbrication.

Methods: Retrospective chart review and analysis was done for all patients who underwent surgical intervention for symptomatic Tarlov cyst(s) in the period 2007–2013. Operative reports, preoperative and postoperative clinic visit reports were reviewed. The surgical techniques of cyst fenestration and nerve root imbrication were each described in terms of intraoperative parameters, hospital course and outcome. Modified MacNab criteria were used for evaluation of the final clinical outcome.

Results: Thirty-six surgical patients were identified. Three had repeat surgery (total of 39 operations). The median age was 51 years (range, 26–84 years). Eighty-six percent were females. The presenting symptoms were low back pain (94%), sensory radiculopathy (69%), bladder and bowel dysfunction (61%), sexual dysfunction (17%) and motor dysfunction (8%). Cyst fenestration was performed in 12 patients (31%) and nerve root imbrication was done in 27 (69%). All patients in the fenestration group but only 67% in the imbrication group had fibrin glue injection into the cyst or around the reconstructed nerve root. The overall surgery-related complication rate was 28%. The complication rate was 5/12 (42%) in the fenestration group and 6/27 (22%) in the imbrication group. At the time of the last clinic visit, improved clinical outcome was noted in 9/11 (82%) and 20/25 (80%) in the fenestration and the imbrication group, respectively.

Conclusions: Cyst fenestration and nerve root imbrication are both surgical techniques to treat symptomatic Tarlov cyst(s), and both can result in clinical improvement.

Keywords: Tarlov cyst; meningeal cyst; surgical management; cyst fenestration; nerve root imbrication

Submitted Apr 09, 2019. Accepted for publication Sep 16, 2019.

doi: 10.21037/jss.2019.11.11

View this article at: <http://dx.doi.org/10.21037/jss.2019.11.11>

Introduction

Tarlov cysts (Nabors Type II spinal meningeal cysts) are collections of cerebrospinal fluid (CSF) between the endoneurium and perineurium of the nerve root sheath near the dorsal root ganglion of spinal (usually sacral) nerve roots (1). The prevalence of these lesions is estimated to be around 4.6% among the general population (1,2). Although the majority of these cysts are asymptomatic, up to 20% of the cases present with one or more of the following symptoms: back pain, radicular pain, paraesthesia, urinary and bowel dysfunction, dyspareunia or sexual dysfunction, and occasionally headache (1,3-7). Symptoms are often exacerbated by standing, sitting, walking, or coughing, due to increased CSF pressure (6). Different procedures were described in the medical literature for the treatment of symptomatic Tarlov cysts (1,3). Nonsurgical or minimally invasive techniques include lumbar CSF drainage (4,8) and CT-guided cyst aspiration with or without fibrin glue instillation (2,9,10). Neurosurgical techniques described in the literature and commonly performed include cyst fenestration, cyst shrinkage using bipolar cauterization, marsupialization, partial excision and oversewing of the cyst's wall with or without nerve root sleeve reconstruction, and complete excision of the cyst with the nerve root (1,5,7,11-16). Less commonly practiced neurosurgical interventions for symptomatic Tarlov cyst(s) include simple decompressive laminectomy, lumbo-peritoneal shunting, and cyst-to-subarachnoid shunt placement (1,3,7,8,17,18). In this study, we describe the demographics, operative details, and outcome for a series of patients who underwent either one of two types of surgical operations for symptomatic Tarlov cyst(s): simple cyst fenestration, or nerve root imbrication (nerve root repair). To our knowledge, this study is the largest consecutive surgical case series of symptomatic Tarlov cyst(s) patients. All operations were performed by the senior author (R Schrot) at University of California Davis (UC Davis) Medical Center. We present our preliminary experience with the surgical management of symptomatic Tarlov cyst disease.

In our study there was no specific criteria for which technique to be chosen. The senior author (R Schrot) was using the cyst fenestration technique earlier (2007–2009), then he adopted the imbrication technique afterward (2010–2013).

Methods

A retrospective chart review was conducted for all patients

operated on for Tarlov cyst in the period 2007–2013 at University of California, Davis Medical Center in Sacramento, CA, United States. The study was approved by the institutional review board (IRB) administration. A literature review was conducted using PubMed with search words: Tarlov cyst(s), extradural spinal meningeal cyst(s) and symptomatic perineural cyst(s). The search was confined to articles and abstracts published in English language. The list of patients was retrieved from the surgical operations scheduling department of the UC Davis Medical Center using the Current Procedural Terminology (CPT) coding system. All data were retrieved from the electronic medical records using the hospital system (Epic®). Operative reports were reviewed to ensure that the patients had undergone a neurosurgical procedure for symptomatic Tarlov cyst(s). Patient demographics and presenting symptoms were retrieved from the preoperative clinic visits and operative reports (*Table 1*). Details of the procedure, technique used, and estimated blood loss were extracted from the operative reports. Hospital stay and inpatient postoperative complications were obtained from the patients' electronic chart. Follow-up data were retrieved from clinic visit reports. All postoperative clinic visits were reviewed. Most of the patients conducted their initial postoperative visits within 2 to 4 weeks postoperatively, followed by a second visit within three months. Third and fourth visits were also conducted between 1 to 2 years depending on outcome and patient convenience. Data about long-term complications and clinical outcome were extracted from clinic postoperative visits reports. Patient clinical assessments were reviewed during each clinic visit and translated into the modified MacNab criteria (19). These criteria provided four categories of outcome:

- ❖ Excellent: no pain, no restriction of mobility, return to normal work and level of activity;
- ❖ Good: occasional non-radicular pain, relief of presenting symptoms, able to return to modified work;
- ❖ Fair: some improved functional capacity, still handicapped and/or unemployed;
- ❖ Poor: continued objective symptoms of root involvement, additional operative intervention needed at index level irrespective of length of postoperative follow-up.

The clinical outcome was then measured and classified according to the modified MacNab criteria from the reports obtained at the immediate post-operative visit (usually after 2–4 weeks following surgery), 3 months, 1 year, and 2 years

Table 1 Characteristics of patients operated on for Tarlov cysts during the period 2007–2013 at UC Davis (total =36 patients)

Characteristics	Value
Age (years), median [range]	51 [26–84]
Gender (No.) (female/male)	31/5
BMI (mean and standard deviation) (kg/m ²)	27.8 (\pm 7.7)
Preoperative symptoms, n [%]	
Lower back pain/sacrococcydynia	34 [94]
Sensory radiculopathy: numbness/tingling/pain in lower extremities, perineal area	25 [69]
Bladder or bowel dysfunction	22 [61]
Dyspareunia (% among females)	4 [13]
Erectile dysfunction (% among males)	2 [40]
Weakness/motor dysfunction	3 [8]

BMI, body mass index.

following surgery (if the visit was conducted); in addition to the last post-operative clinic visit. We then compared the clinical outcome per the last visit between the two types of surgical techniques. In an attempt to reduce observation bias, the operating surgeon did not participate in the clinical outcome classification, data review and analysis.

Continuous variables were summarized using the mean and standard deviation (or median and range, as appropriate); categorical variables were described using counts and percentages. The primary outcome was the clinical improvement as measured by the modified MacNab criteria. No attempt was made to assess the statistical significance of the between-group differences due to the small sample sizes.

Results

Thirty-six patients who underwent Tarlov cyst surgery were identified. The majority were female (n=31, 86%). Low back pain was the chief complaint in the majority of patients (n=34, 94%), followed by sensory dysfunction (n=25, 69%) and bladder and/or bowel dysfunction (n=22, 61%). The mean body mass index was 27.8 (\pm 7.7) kg/m² (Table 1).

A total of 39 operations were performed. Twelve surgeries (31%) involved partial sacral laminectomy and cyst fenestration, with injection of fibrin glue into the cyst lumen. The remainder of the operations (n=27, 69%) involved sacral laminoplasty, nerve root imbrication, and

wrapping with collagen matrix (DuraGen™), with or without fibrin glue reinforcement of the reconstructed nerve root (Table 2). The imbrication was performed using non-absorbable materials (usually Nylon 6-0). Figures 1,2 demonstrate lumbosacral MRI for symptomatic Tarlov's cyst before and after fenestration, respectively. Figures 3,4 demonstrate surgical operation for symptomatic Tarlov's cyst(s) with nerve root imbrication. All images were exclusively obtained from this patients' series operated on at our institution. The operative microscope was used in 33 (85%) cases. Intraoperative electromyographic (EMG) monitoring was used in 37 (95%) cases. Direct EMG unipolar stimulation was performed mainly from anal sphincter, gluteal muscles and gastrocnemius depending on the involved nerve roots.

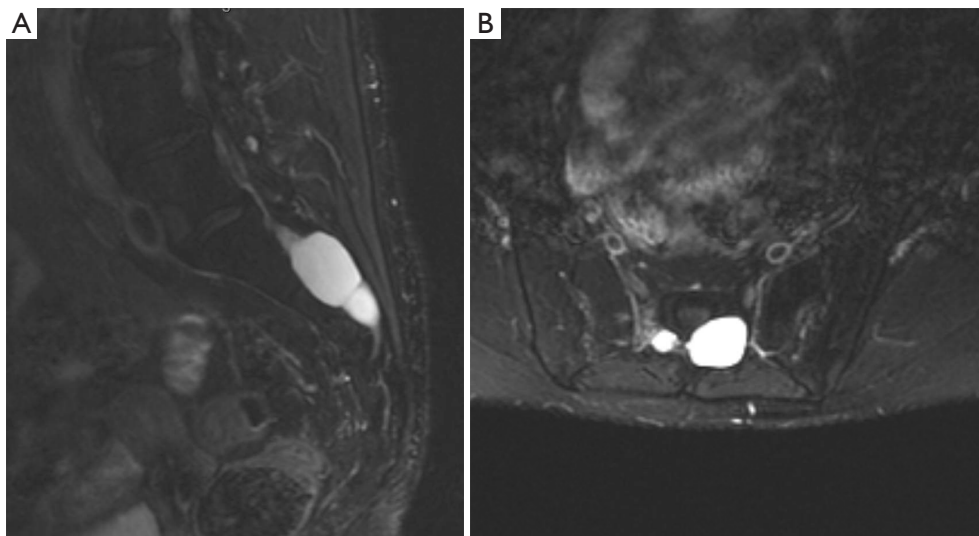
Half of the patients in the fenestration group had 1 cyst, compared to 56% in the imbrication group. Fibrin glue was applied in all of the patients who underwent cyst fenestration, and was used to reinforce the repair and in only 18 patients (67%) in the imbrication group. A lumbar drain was placed at the end of the procedure in 4 (33%) of the fenestration procedures, compared to 15 (56%) of the imbrication procedures. The total blood loss during each procedure was estimated to be 190 (SD: 160) mL on average in the fenestration procedures, compared to 190 (SD: 170) mL in the imbrication procedures. The median duration of hospital stay was 4 (range, 1–15) days in the fenestration group, compared to 4 (range, 1–10) days in the imbrication group.

Overall 3 of 36 patients (8%) (2 females and 1 male) required redo operation due to either no improvement or worsening of symptoms with radiological evidence of persistent or recurrent Tarlov cyst(s) (average time: 9 months; range, 7–11 months). One of the 3 patients who required reoperation for Tarlov cyst(s) underwent anterior retroperitoneal approach (via exploratory laparotomy) to treat anteriorly-located Tarlov cysts that were not accessible from the prior posterior approach. Immediate and short-term postoperative complications in the fenestration group and imbrication group, respectively, were: (I) contained CSF leak or "pseudomeningocele" in 4 (33%) and 4 (15%) patients, (II) wound infection in 1 (8%) and 0% patients, (III) wound dehiscence in 0% and 1 (4%) patients, and (IV) chemical meningitis in 0% and 1 (4%) patients, respectively. The total rate of surgery-related complication was 42% and 22% between fenestration and imbrication, respectively. Four patients (15%) in the imbrication group developed symptomatic cyst recurrence within 3 months to 2 years

Table 2 Operative characteristics retrieved from operative reports for the patients operated on for Tarlov Cysts during the period 2007–2013 at UC Davis, categorized by type of surgery (total =39 surgical procedures)

Operative characteristic	Fenestration (n=12)	Nerve root imbrication (n=27)
Redo surgery, n [%]	1 [8]	2 [7]
Microscope reportedly used, n [%]	8 [67]	25 [93]
EMG reportedly used, n [%]	12 [100]	25 [93]
Number of cysts fenestrated/nerve root imbrication per single procedure, n [%]		
1	6 [50]	15 [56]
2	2 [17]	4 [15]
3	1 [8]	4 [15]
4	2 [17]	3 [11]
>4	1 [8]	1 [4]
Fibrin glue used during procedure, n [%]	12 [100]	18 [67]
Lumbar drain placed, n [%]	4 [33]	15 [56]
Estimated blood loss (in mL) for surgery (mean \pm SD)	190 (\pm 160)	190 (\pm 170)
Post-operative duration of hospital stay (in days), median [range]	4 [1–15]	4 [1–10]

EMG, electromyographic; SD, standard deviation.

**Figure 1** Sagittal (A) and axial (B) T2-weighted MR images demonstrating preoperative sacral Tarlov cysts. MR, magnetic resonance.

(average 9.8 months). Three patients with symptomatic recurrence underwent intervention and the fourth was lost to follow-up. The first two patients underwent repeated nerve root imbrication while the third one underwent CT-guided aspiration with the instillation of fibrin glue. No one

from the fenestration group developed cyst recurrence (to the last date of follow up at our institution) (*Table 3*).

Table 4 describes the trend of clinical outcome per clinic visit in the 2-year postoperative follow-up. The average total duration of follow-up was 23.1 months (range,

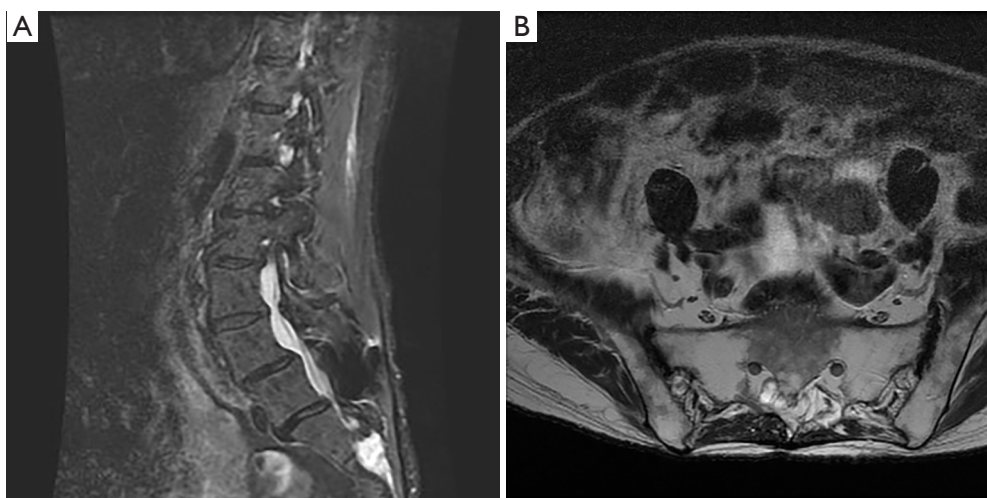


Figure 2 Sagittal (A) and axial (B) T2-weighted MR images performed nine years after undergoing cyst fenestration illustrating resolution of the Tarlov cysts. MR, magnetic resonance.

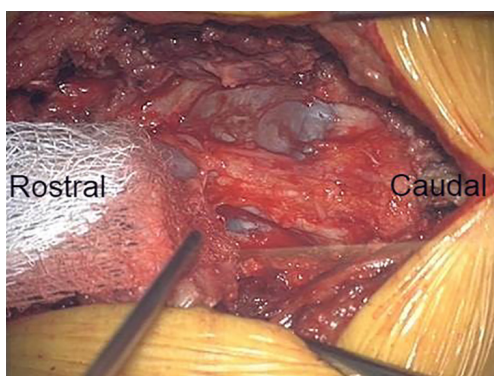


Figure 3 Intraoperative illustration of multiple sacral Tarlov cysts.

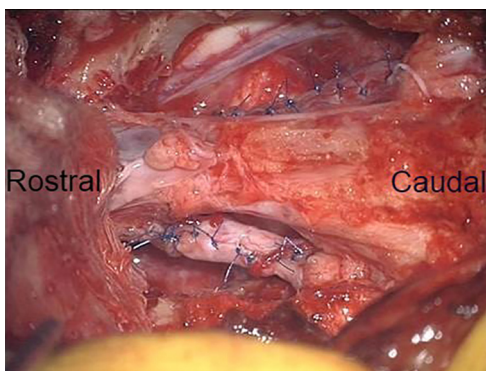


Figure 4 Intraoperative illustration of nerve root imbrication for multiple sacral Tarlov cysts.

2 weeks–7 years). At the time of the last follow-up visit, MacNab outcome scoring indicated the following in the fenestration group and imbrication group, respectively: poor in 18% and 20%, fair in 45% and 44%, good in 36% and 24%, and excellent in 0 and 12% (Table 5, Figure 5). Fair, good and excellent outcome groups were designated as “improved” while the Poor outcome group was designated as “no improvement.” Based on this analysis, 9/11 (82%) of the fenestration group and 20/25 (80%) of the nerve root imbrication group were “improved” after surgery (Table 6, Figure 6).

Discussion

Various neurosurgical techniques have been described to treat symptomatic Tarlov cyst(s). We report here a consecutive case series that reflects our initial experience and the evolution of our technique with the surgical management of symptomatic sacral Tarlov cysts. This series is the first one to our knowledge to provide data that compares two types of surgical procedures: cyst fenestration with the instillation of fibrin glue, and nerve root imbrication with or without reinforcement with Duragen™ and fibrin glue. Overall, there appears to be no apparent difference between the two surgical techniques in terms of outcome. There was not any apparent difference in the hospital stay, estimated blood loss, postoperative

Table 3 Postoperative complications and symptomatic recurrence classified by each type of surgery

Post-operative complication	Fenestration (n=12), n [%]	Nerve root imbrication (n=27), n [%]
Pseudomeningocele	4 [33]	4 [15]
Wound infection/cellulitis	1 [8]	0
Wound dehiscence	0	1 [4]
Chemical meningitis	0	1 [4]
Total complications	5 [42]	6 [22]
Symptomatic recurrence requiring intervention	0	4 [15]

Table 4 Number of patients in each MacNab score outcome by surgery type

Outcome	Fenestration				Nerve root imbrication				Total
	Poor	Fair	Good	Excellent	Poor	Fair	Good	Excellent	
Initial postoperative visit (2–4 weeks from surgery), n [%]	2 [18]	4 [36]	4 [36]	1 [9]	4 [16]	9 [36]	9 [36]	3 [12]	36
3-month follow-up, n [%]	3 [27]	6 [55]	2 [18]	0 [0]	5 [24]	9 [43]	5 [24]	2 [10]	32
12-month follow-up, n [%]	3 [27]	5 [46]	3 [27]	0 [0]	7 [41]	5 [29]	3 [18]	2 [12]	28
24-month follow-up, n [%]	2 [33]	2 [33]	2 [33]	0 [0]	5 [42]	4 [33]	0 [0]	3 [25]	18

Table 5 Number of patients in each MacNab score outcome by surgery type during the last clinic visit

Outcome	Fenestration (n=11)				Nerve root imbrication (n=25)			
	Poor	Fair	Good	Excellent	Poor	Fair	Good	Excellent
Number of patients [%]	2 [18]	5 [45]	4 [36]	0 [0]	5 [20]	11 [44]	6 [24]	3 [12]

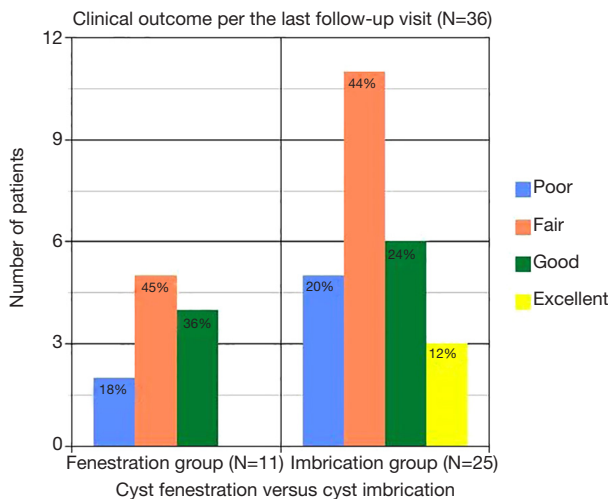


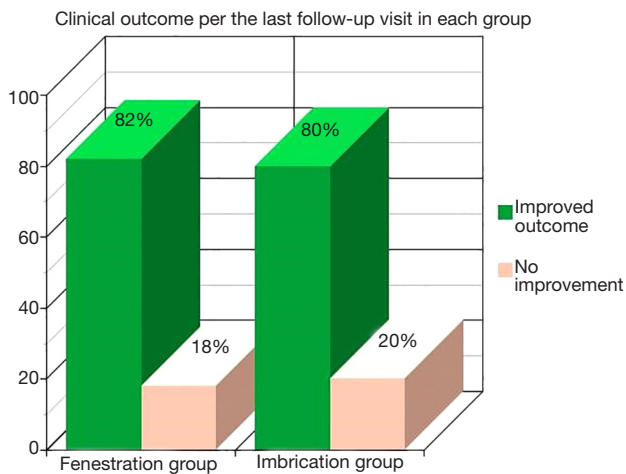
Figure 5 Clinical outcome during the last clinic visit between cyst fenestration and nerve root imbrication.

complications, or clinical outcome between the two groups. The vast majority of both fenestration and imbrication groups clinically improved, and although CSF leak and pseudomeningocele appeared as twice as common in the fenestration group compared to the imbrication group. This trend would be expected, since the cyst remains open with the fenestration, with increased potential for egress of CSF into the surrounding space. The preponderance of final MacNab outcomes of “Fair” and “Good” might result from patients with highly favorable outcomes not following up, or by their being discharged from the clinic. Some of the patients lived in locations remote from our institution, compromising follow-up.

In regards to the currently available literature that describes the surgical outcome for symptomatic Tarlov cysts, most of authors have described subjective clinical

Table 6 Improved and non-improved outcome in both types of surgery

Outcome	Fenestration (n=11)		Nerve root imbrication (n=25)	
	Improved	No improvement	Improved	No improvement
Number of patients [%]	9 [82]	2 [18]	20 [80]	5 [20]

**Figure 6** Rates of Improvement during the last clinic visit between cyst fenestration and nerve root imbrication.

improvement as a measure of the surgical outcome, i.e., disappearance or improvement of symptoms versus no improvement (4,20,21). A few authors have implemented the International Japanese Orthopedic Association (IJOA) scores and compared the results before and after surgery (16). Others, reported the visual analog scale (VAS) before surgery and compared results during follow-up (15). The majority of these series have reported improvement in the clinical outcome in 70–87% of patients following surgical/microsurgical intervention. However, none of them have described a comparative outcome of two or more types of surgical techniques (4,15,16,20,21).

A major limitation of this study is the retrospective chart review design of the protocol. Another limitation is that the modified MacNab criteria used for the analysis of the outcome might be somewhat subjective to the bias of the chart reviewer. This bias was mitigated in that the operating surgeon did not participate in the data review and analysis.

The sample size was too small to evaluate the statistical significance of the between-group differences. Assuming a 20% risk of complication in fenestration group, a sample size of 82 patients per group done would have been needed to detect with 80% power a minimum two-fold risk in the

nerve root imbrication group, using a 5% Type I error rate.

Overall, symptoms ascribed to Tarlov cysts were improved in the majority of patients who underwent surgical fenestration or repair of the cysts. This serves to support the diagnosis of symptomatic Tarlov cysts; they are not “incidental findings”, as if often stated in clinical practice. The optimal treatment, however, has not been established. The benefit of one technique over another was not resolved in the limited analysis presented here. A higher level of evidence would be provided by a prospective study with more robust outcome measures.

Conclusions

Cyst fenestration and nerve root imbrication are both surgical techniques to treat symptomatic Tarlov cyst(s), and both can result in clinical improvement. With the paucity of literature on management of Tarlov cysts, this provides early head to head comparison between two surgical techniques for treatment of symptomatic Tarlov cysts.

Acknowledgments

None.

Footnote

Conflicts of Interest: The authors have no conflicts of interest to declare.

Ethical Statement: The authors are accountable for all aspects of the work in ensuring that questions related to the accuracy or integrity of any part of the work are appropriately investigated and resolved. The study was approved by the institutional review board (IRB) administration (No. 864963-1).

References

- Mummaneni PV, Pitts LH, McCormack BM, et al. Microsurgical treatment of symptomatic sacral Tarlov

- cysts. *Neurosurgery* 2000;47:74-8; discussion 78-9.
2. Paulsen RD, Call GA, Murtagh FR. Prevalence and percutaneous drainage of cysts of the sacral nerve root sheath (Tarlov cysts). *AJNR Am J Neuroradiol* 1994;15:293-7; discussion 298-9.
 3. Acosta FL Jr, Quinones-Hinojosa A, Schmidt MH, et al. Diagnosis and management of sacral Tarlov cysts. Case report and review of the literature. *Neurosurg Focus* 2003;15:E15.
 4. Caspar W, Papavero L, Nabhan A, et al. Microsurgical excision of symptomatic sacral perineurial cysts: a study of 15 cases. *Surg Neurol* 2003;59:101-5; discussion 105-6.
 5. Nabors MW, Pait TG, Byrd EB, et al. Updated assessment and current classification of spinal meningeal cysts. *J Neurosurg* 1988;68:366-77.
 6. Marino D, Carluccio MA, Di Donato I, et al. Tarlov cysts: clinical evaluation of an Italian cohort of patients. *Neurol Sci* 2013;34:1679-82.
 7. Seo DH, Yoon KW, Lee SK, et al. Microsurgical excision of symptomatic sacral perineurial cyst with sacral recapping laminectomy: a case report in technical aspects. *J Korean Neurosurg Soc* 2014;55:110-3.
 8. Bartels RH, van Overbeeke JJ. Lumbar cerebrospinal fluid drainage for symptomatic sacral nerve root cysts: an adjuvant diagnostic procedure and/or alternative treatment? Technical case report. *Neurosurgery* 1997;40:861-4; discussion 864-5.
 9. Patel MR, Louie W, Rachlin J. Percutaneous fibrin glue therapy of meningeal cysts of the sacral spine. *AJR Am J Roentgenol* 1997;168:367-70.
 10. Murphy K, Oaklander AL, Elias G, et al. Treatment of 213 Patients with Symptomatic Tarlov Cysts by CT-Guided Percutaneous Injection of Fibrin Sealant. *AJNR Am J Neuroradiol* 2016;37:373-9.
 11. Siqueira EB, Schaffer L, Kranzler LI, et al. CT characteristics of sacral perineurial cysts. Report of two cases. *J Neurosurg* 1984;61:596-8.
 12. Nishiura I, Koyama T, Handa J. Intracanalicular perineurial cyst. *Surg Neurol* 1985;23:265-9.
 13. Tarlov IM. Cysts, perineurial, of the sacral roots; another cause, removable, of sciatic pain. *J Am Med Assoc* 1948;138:740-4.
 14. Tarlov IM. Cysts of the sacral nerve roots; clinical significance and pathogenesis. *AMA Arch Neurol Psychiatry* 1952;68:94-108.
 15. Voyadzis JM, Bhargava P, Henderson FC. Tarlov cysts: a study of 10 cases with review of the literature. *J Neurosurg* 2001;95:25-32.
 16. Sun JJ, Wang ZY, Teo M, et al. Comparative outcomes of the two types of sacral extradural spinal meningeal cysts using different operation methods: a prospective clinical study. *PLoS One* 2013;8:e83964.
 17. Xu J, Sun Y, Huang X, et al. Management of symptomatic sacral perineurial cysts. *PLoS One* 2012;7:e39958.
 18. Morio Y, Nanjo Y, Nagashima H, et al. Sacral cyst managed with cyst-subarachnoid shunt: a technical case report. *Spine (Phila Pa 1976)* 2001;26:451-3.
 19. MACNAB CRITERIA 2015. Available online: <http://www.scientificspine.com/spine-scores/macnab-criteria.html>
 20. Guo D, Shu K, Chen R, et al. Microsurgical treatment of symptomatic sacral perineurial cysts. *Neurosurgery* 2007;60:1059-65; discussion 1065-6.
 21. Tanaka M, Nakahara S, Ito Y, et al. Surgical results of sacral perineurial (Tarlov) cysts. *Acta Med Okayama* 2006;60:65-70.

Cite this article as: Medani K, Lawandy S, Schrot R, Binongo JN, Kim KD, Panchal RR. Surgical management of symptomatic Tarlov cysts: cyst fenestration and nerve root imbrication—a single institutional experience. *J Spine Surg* 2019;5(4):496-503. doi: 10.21037/jss.2019.11.11