

# UCSF

## UC San Francisco Previously Published Works

### Title

Maxillary Nerve-Mediated Postseptoplasty Nasal Allodynia: A Case Report

### Permalink

<https://escholarship.org/uc/item/8r06p6f8>

### Journal

A&A Practice, 14(13)

### ISSN

2575-3126

### Authors

Sharma, Shikha  
Ly, Wilson  
Yu, Xiaobing

### Publication Date

2020-11-01

### DOI

10.1213/xa.0000000000001356

Peer reviewed

# Maxillary Nerve-Mediated Postseptoplasty Nasal Allodynia: A Case Report

Shikha Sharma, MD, PhD,\* Wilson Ly, MD, PharmD,\* and Xiaobing Yu, MD\*†

Endoscopic nasal septoplasty is a commonly performed otolaryngology procedure, not known to cause persistent postsurgical pain or hypersensitivity. Here, we discuss a unique case of persistent nasal pain that developed after a primary endoscopic septoplasty, which then progressed to marked mechanical and thermal allodynia following a revision septoplasty. Pain symptoms were found to be mediated by the maxillary division of the trigeminal nerve and resolved after percutaneous radiofrequency ablation (RFA) of bilateral maxillary nerves. To the best of our knowledge, this is the first report of maxillary nerve-mediated nasal allodynia after septoplasty. (A&A Practice. 2020;14:e01356.)

## GLOSSARY

**CT** = computed tomography; **FR** = foramen rotundum; **HIPAA** = Health Insurance Portability and Accountability Act; **ION** = infraorbital nerve; **LPP** = lateral pterygoid plate; **MRI** = magnetic resonance imaging; **RFA** = radiofrequency ablation; **SPG** = sphenopalatine ganglion; **US** = ultrasound

Endoscopic nasal septoplasty is a common otolaryngology procedure with rare incidence of postsurgical complications. Minor complications include epistaxis, septal hematoma, septal perforation, cerebrospinal fluid leak, and persistent obstruction.<sup>1</sup> Numbness or hypoesthesia of the anterior palate, secondary to injury to the nasopalatine nerve, has been reported, but is usually rare and temporary, resolving over weeks to months.<sup>2</sup> Acute postoperative pain is also well managed in 90% of patients following any sinonasal surgery.<sup>3</sup> To the best of our knowledge, chronic postseptoplasty nasofacial pain and/or allodynia has not been reported. Here, we present a case of nasofacial pain that developed post an uncomplicated septoplasty, which then progressed to allodynia (to mechanical and thermal stimuli) following a revision septoplasty. The case review was approved by University of California San Francisco Institutional Review Board and written informed patient consent (Health Insurance Portability and Accountability Act [HIPAA] authorization) was obtained.

## CASE DESCRIPTION

This case report describes an otherwise healthy 21-year-old man who underwent an endoscopic submucosal

septoplasty for chronic nasal obstruction with resection of the cartilage inferiorly and posteriorly in 2010. Before this surgery, the patient only occasionally experienced mild headaches. However, his postoperative course was complicated by significant pain requiring high-dose opioids. After discharge, patient continued to have persistent deep, “aching” nasal pain which radiated toward bilateral forehead and incisors. Multimodal medications, including gabapentin, nortriptyline, topiramate, rizatriptan, prednisone, and opioids, were tried without significant benefits. Imaging studies, including computed tomography (CT) and magnetic resonance imaging (MRI), were unrevealing. Multiple outpatient evaluations performed by otolaryngology providers were notable for persistent septal deviation, possible contact point (between septum and left middle turbinate), and bilateral turbinate hypertrophy. Endoscopic revision septoplasty was subsequently performed in 2013 during which right posterior septal deviation was corrected and a posterior bony spur, thought to be a contact point, was resected. Bilateral submucosal inferior turbinate reduction was also performed. Unfortunately, postoperative course was again complicated by severe persistent nasofacial pain and he required readmission for a pain crisis. Although subsequent repeat outpatient rigid endoscopies showed widely patent nasal airway without any notable abnormalities, the quality of nasal pain changed. The patient developed intranasal hypersensitivity to gentle touch and temperature (pain evoked by breathing hot or cold air). Symptoms remained recalcitrant to topical and oral analgesics, as described above.

Nasal pain can be mediated by anterior ethmoid nerve (a branch of the ophthalmic division of the trigeminal nerve, V1; Figure A, B).<sup>4</sup> However, bilateral anterior ethmoid nerve bundle blocks, attempted by outside providers, failed to provide benefit. Sphenopalatine ganglion (SPG) blocks were also tried without much long-term success.

He then presented to our chronic pain clinic. Intraoperative sensory nerve injury was suspected to

From the \*Department of Anesthesia and Perioperative Care and †Division of Pain Medicine, University of California, San Francisco, California.

Accepted for publication October 16, 2020.

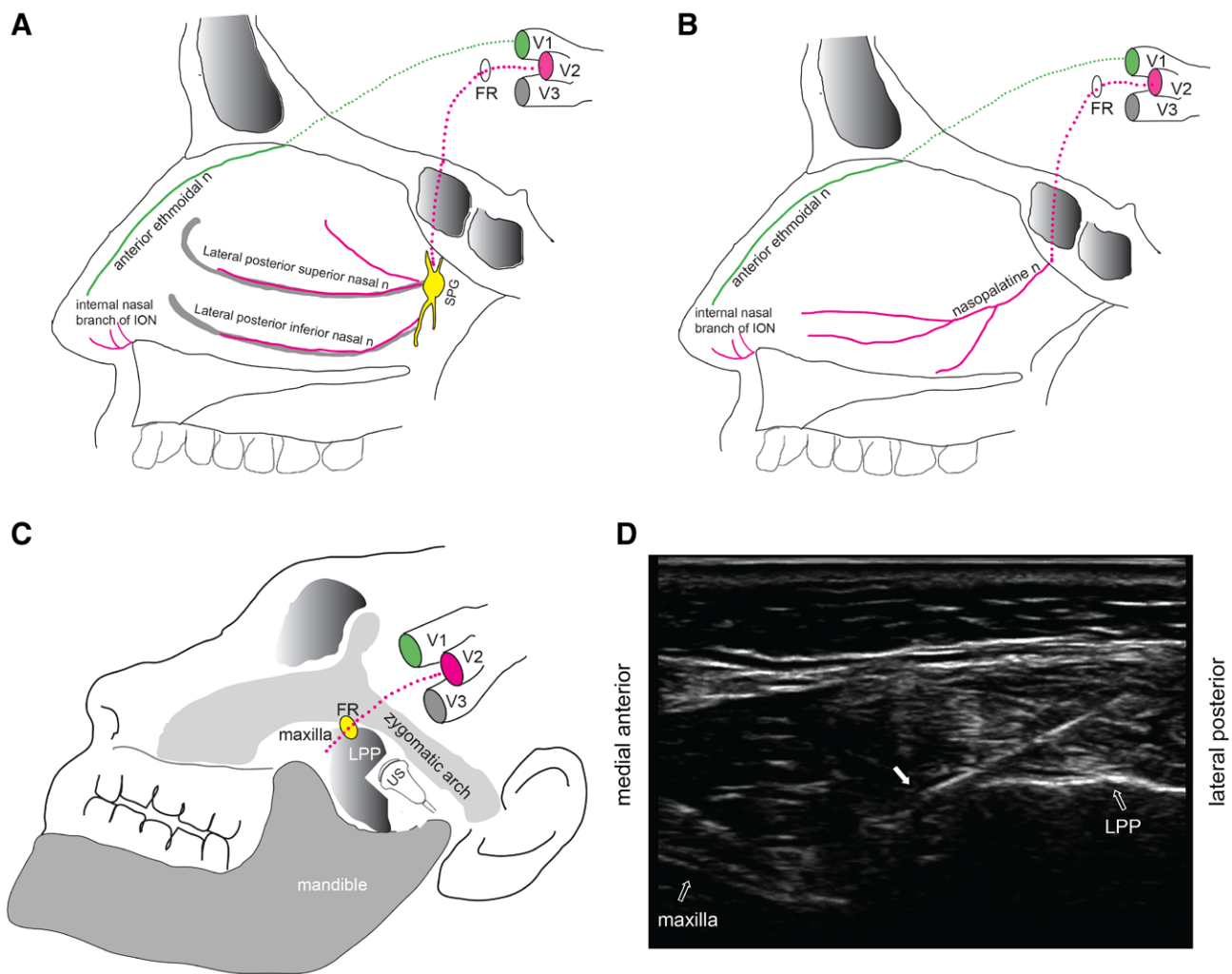
Funding: None.

The authors declare no conflicts of interest.

Address correspondence to Shikha Sharma, MD, PhD, Department of Anesthesia and Perioperative Care, University of California, 513 Parnassus Ave, S455E, San Francisco, CA 94143. Address e-mail to shikha.sharma2@ucsf.edu.

Copyright © 2020 The Author(s). Published by Wolters Kluwer Health, Inc. on behalf of the International Anesthesia Research Society. This is an open-access article distributed under the terms of the Creative Commons Attribution-Non Commercial-No Derivatives License 4.0 (CCBY-NC-ND), where it is permissible to download and share the work provided it is properly cited. The work cannot be changed in any way or used commercially without permission from the journal.

DOI: 10.1213/XAA.0000000000001356



**Figure.** Overview of the major sensory innervation of the nose derived from the maxillary and ophthalmic divisions of trigeminal nerve. A and B, Schematic diagram of the major sensory nerve supply to the lateral nasal wall (A) and nasal septum (B). C, Schematic of anatomic landmarks used for maxillary nerve RFA using infrazygomatic approach with the ultrasound probe placed in short axis. D, Representative ultrasound image of RFA needle targeting maxillary nerve in the pterygopalatine fossa. Solid arrow points to RF needle. FR indicates foramen rotundum; ION, infraorbital nerve; LPP, lateral pterygoid plate; RFA, radiofrequency ablation; SPG, sphenopalatine ganglion; US, ultrasound.

contribute to his symptoms. Notably, the mucosa of inferior and posterior nasal septum, as well as, bilateral inferior turbinates, which were targeted during his 2 prior septoplasties, are innervated by multiple branches of the maxillary (V2) division of the trigeminal nerve (Figure A, B).<sup>5</sup> To test our hypothesis, we first performed a trial of ultrasound-guided infrazygomatic bilateral maxillary nerve (V2) blocks<sup>6</sup> (Figure C, D) with 3.75 mL of 0.25% bupivacaine, 0.5 mL of 100 µg/mL clonidine, and 1 mL of 4mg/mL dexamethasone, which provided complete pain relief for over 4 weeks. With this confirmation, we proceeded with bilateral maxillary nerve radiofrequency ablation (RFA). During the ablation process, sensory stimulation reproduced patient's pain symptoms. Five rounds of RFA were performed without motor stimulation by a team led by fellowship-trained and board-certified pain physician/anesthesiologist at 42 °C and 45 V for a total of 10 minutes, on each side. After procedure, patient reported resolution of all prior pain symptoms. He also endorsed improvement in overall

well-being, as well as, improved sleep and breathing. The patient remained pain free for about 11 months. He returned to clinic for repeat RFA procedure a year later and has since remained pain free.

### DISCUSSION

Persistent postsurgical pain occurs in roughly 10%–15% of patient undergoing common surgical procedures.<sup>7</sup> Intraoperative nerve damage is a well-known clinical risk factor for chronic postsurgical pain.<sup>8</sup> In this case report, our patient developed postseptoplasty nasal hypersensitivity to both mechanical and thermal stimulation, a hallmark of neuropathic pain associated with nerve injury. To the best of our knowledge, chronic nasal allodynia following a septoplasty remains unreported.

The major sensory innervation to the nose is provided by V1 and V2 divisions of the trigeminal nerve (Figure A, B).<sup>5,9</sup> The nasociliary branch of the ophthalmic nerve (V1) gives off anterior and posterior ethmoidal nerves that together

innervate the anterolateral nasal wall and posterior-superior septum. Maxillary nerve (V2) enters the roof of the sphenopalatine fossa via the foramen rotundum, then sends off several sensory branches to the midface structures including the nasal cavity. Specifically, superior and middle meatus are innervated by lateral posterior superior nasal nerve; inferior meatus, anterior septum, and anterolateral wall by internal nasal branches of infraorbital nerve; posterior-inferior lateral wall by lateral posterior inferior nasal nerve; and posterior septum by nasopalatine nerve.

V1 involvement was first ruled out by unsuccessful anterior ethmoid nerve blocks. Rare sensory impairment of the anterior palate has been reported after nasal septoplasty, associated with nasopalatine nerve damage.<sup>2</sup> However, the distribution of our patient's sensory symptoms clearly went beyond the innervation of just the nasopalatine nerve. We hypothesized that several maxillary nerve terminal branches were likely injured during his septoplasties, resulting in symptoms that tracked along V2 distribution. We first confirmed this with successful blocks of bilateral maxillary nerves in the pterygopalatine fossa after exiting through the foramen rotundum (Figure C, D). Subsequently we proceeded with percutaneous RFA, whose efficacy and long-term outcome are well documented in treating trigeminal neuralgia and facet arthropathy.<sup>10,11</sup> Instead of using the conventional ablative RFA that delivers high energy (80 °C for 2 minutes) to produce coagulation of the target neural tissue adjacent to the electrode tip, we chose nonablative RFA with an aim to limit the extent of surrounding tissue injury and reduce undesirable facial motor or sensory deficits by applying low energy (42 °C for 10 minutes) preferably to the nociceptors.<sup>12</sup>

We cannot comment on the mechanism of primary neuropathic insult since we were unable to access the complete operative report of his first septoplasty. It is, however, plausible that a state of peripheral and central sensitization may have resulted, which worsened on a repeat surgical intervention.<sup>13</sup> We also cannot speak to the appropriateness of repeat septoplasty for indications such as contact points since this was at the discretion of surgical team. The debate regarding relevance of mucosal contact points for chronic rhinogenic headaches is ongoing and needs more robust evidence.<sup>14,15</sup>

In summary, development of persistent postsurgical nasal pain and allodynia after septoplasty is clinically unrecognized but can present a unique challenge to both anesthesia and surgical providers involved in acute or chronic pain

management. We present new evidence that nonoperative management through peripheral maxillary nerve blocks followed by RFA can have both diagnostic and therapeutic value for treating recalcitrant postsurgical nasofacial allodynia. ■■

#### DISCLOSURES

**Name:** Shikha Sharma, MD, PhD.

**Contribution:** This author helped draft, revise, and finalize the manuscript.

**Name:** Wilson Ly, MD, PharmD.

**Contribution:** This author helped draft, revise, and finalize the manuscript.

**Name:** Xiaobing Yu, MD.

**Contribution:** This author helped draft, revise, and finalize the manuscript.

**This manuscript was handled by:** Jennifer Banayan, MD.

#### REFERENCES

1. Sautter NB, Smith TL. Endoscopic septoplasty. *Otolaryngol Clin North Am.* 2009;42:253–260.
2. Chandra RK, Rohman GT, Walsh WE. Anterior palate sensory impairment after septal surgery. *Am J Rhinol.* 2008;22:86–88.
3. Locketz GD, Brant JD, Adappa ND, et al. Postoperative opioid use in sinonasal surgery. *Otolaryngol Head Neck Surg.* 2019;160:402–408.
4. Burnham HH. The anterior ethmoidal nerve syndrome; referred pain and headache from the lateral nasal wall. *Arch Otolaryngol.* 1949;50:640–666.
5. Shankland WE 2nd. The trigeminal nerve. Part III: the maxillary division. *Cranio.* 2001;19:78–83.
6. Nader A, Schitteck H, Kendall MC. Lateral pterygoid muscle and maxillary artery are key anatomical landmarks for ultrasound-guided trigeminal nerve block. *Anesthesiology.* 2013;118:957.
7. Kehlet H, Jensen TS, Woolf CJ. Persistent postsurgical pain: risk factors and prevention. *Lancet.* 2006;367:1618–1625.
8. Price TJ, Basbaum AI, Bresnahan J, et al. Transition to chronic pain: opportunities for novel therapeutics. *Nat Rev Neurosci.* 2018;19:383–384.
9. Shankland WE. The trigeminal nerve. Part II: the ophthalmic division. *Cranio.* 2001;19:8–12.
10. Cruccu G, Di Stefano G, Truini A. Trigeminal neuralgia. *N Engl J Med.* 2020;383:754–762.
11. Lord SM, Barnsley L, Wallis BJ, McDonald GJ, Bogduk N. Percutaneous radio-frequency neurotomy for chronic cervical zygapophyseal-joint pain. *N Engl J Med.* 1996;335:1721–1726.
12. Munglani R. The longer term effect of pulsed radiofrequency for neuropathic pain. *Pain.* 1999;80:437–439.
13. Basbaum AI, Bautista DM, Scherrer G, Julius D. Cellular and molecular mechanisms of pain. *Cell.* 2009;139:267–284.
14. Barinsky GL, Hanba C, Svider PF. Rhinogenic headache in children and adolescents. *Curr Pain Headache Rep.* 2020;24:7.
15. Wang J, Yin JS, Peng H. Investigation of diagnosis and surgical treatment of mucosal contact point headache. *Ear Nose Throat J.* 2016;95:E39–E44.