

UCLA

UCLA Previously Published Works

Title

Airway Management and Endoscopic Treatment of Subglottic and Tracheal Stenosis

Permalink

<https://escholarship.org/uc/item/8rt1b3b7>

Journal

Annals of Otology Rhinology & Laryngology, 123(4)

ISSN

0003-4894

Authors

Vorasubin, Nopawan
Vira, Darshni
Jamal, Nausheen
[et al.](#)

Publication Date

2014-04-01

DOI

10.1177/0003489414525340

Peer reviewed



Published in final edited form as:

Ann Otol Rhinol Laryngol. 2014 April ; 123(4): 293–298. doi:10.1177/0003489414525340.

Airway Management and Endoscopic Treatment of Subglottic and Tracheal Stenosis: The Laryngeal Mask Airway Technique

Nopawan Vorasubin, MD¹, Darshni Vira, MD¹, Nausheen Jamal, MD², and Dinesh K. Chhetri, MD¹

¹Department of Head and Neck Surgery, David Geffen School of Medicine, University of California, Los Angeles, Los Angeles, California, USA

²Department of Otolaryngology-Head & Neck Surgery, Temple University School of Medicine, Philadelphia, Pennsylvania, USA

Abstract

Objectives—The objective is to present clinical outcomes of subglottic and tracheal stenosis treated by flexible bronchoscopic delivery of carbon dioxide (CO₂) laser via laryngeal mask airway (LMA).

Methods—All consecutive, nontracheotomy dependent cases of subglottic and tracheal stenosis treated endoscopically over a 4-year period were retrospectively reviewed. The surgical approach consisted of radial incisions using a flexible fiber-based CO₂ laser, balloon dilation, and topical application of mitomycin C. Ventilation during the procedure occurred through the LMA, and the CO₂ laser fiber was delivered through the working channel of a flexible bronchoscope passed through the LMA. Number of dilations, period between dilations, and operative times were reviewed.

Results—Eleven patients who underwent airway intervention during the study period were identified. Average follow-up was 28 months. Etiologies of airway stenosis included intubation injury (6), idiopathic (4), or autoimmune disease (1), requiring an average of 1.3, 1.5, and 3 dilations, respectively. Average operative time was 67 minutes. Autoimmune etiology correlated with more frequent dilations.

Conclusion—LMA is an effective way to manage ventilation while simultaneously allowing unencumbered flexible bronchoscopic access for laser surgery, balloon dilation, and mitomycin C application for airway stenosis. Long-term success in treating stenosis is achievable using this technique.

© The Author(s) 2014

Reprints and permissions: sagepub.com/journalsPermissions.nav

Corresponding Author: Nopawan Vorasubin, MD, Department of Head and Neck Surgery, David Geffen School of Medicine, University of California, Los Angeles, 10833 Le Conte Ave, CHS 62-132, Los Angeles, CA 90095-1624, USA. nvorasubin@mednet.ucla.edu.

Declaration of Conflicting Interests

The author(s) declared no potential conflicts of interest with respect to the research, authorship, and/or publication of this article.

Keywords

subglottic stenosis; tracheal stenosis; airway management; laryngeal mask airway; CO₂ laser; balloon dilation

Subglottic and tracheal stenoses are chronic inflammatory processes that can occur as a result of several possible etiologies, most commonly as a complication of prolonged intubation. This pathology poses a management dilemma for otolaryngologists, especially with regard to which initial management, open versus endoscopic, to offer the patient. Traditionally, open procedures such as tracheotomy, tracheal resection, cricotracheal resection, or laryngotracheoplasty have been offered. Endoscopic management was popularized in the 1970s with the introduction of the carbon dioxide (CO₂) laser for medical applications.¹⁻⁴ In recent years, advancements in instrumentation and technology have improved success rates while minimizing morbidity with endoscopic techniques.⁵

Contemporary endoscopic management of subglottic and tracheal stenosis generally includes radial incisions of the stenotic airway segment, dilation, and adjunctive treatment with steroids or mitomycin C.⁶⁻¹⁰ Optimal airway access for both intraoperative ventilation and for the surgical procedure is one of the most important goals in surgical management of airway stenosis. To achieve this in our practice, we combine the laryngeal mask airway (LMA) ventilation technique with flexible bronchoscopic delivery of fiber-based CO₂ laser passed through the LMA to the stenotic site, followed by dilation using controlled radial expansion (CRE) balloon dilators. In this report, we describe a case series of tracheal and subglottic stenosis managed using the LMA for both ventilation and surgical access. To our knowledge, the outcomes of stenosis treatment using this technique have not been previously reported in the otolaryngology, thoracic surgery, or interventional pulmonology literature.

Methods

This is a retrospective chart review approved by the Institutional Review Board of the University of California, Los Angeles, and is Health Insurance Portability and Accountability Act compliant. All cases of incomplete, non-cartilaginous airway stenosis seen in our clinic between 2008 and 2011 were offered endoscopic treatment using this described protocol. Cases with concurrent glottic or supraglottic involvement were excluded, as were those patients with a tracheotomy in place. All operations were performed by the same surgeon (D.K.C.). Airway stenosis grade was evaluated with flexible bronchoscopy both in the clinic as well as in the operating room using the Cotton Meyer grading system.¹¹ Etiology of stenosis, number and frequency of dilations, and operative times were reviewed.

Surgical Technique

The procedure was performed under general anesthesia administered through an LMA (San Diego, California, USA), as previously described.¹² Once the LMA was positioned over the supraglottis by the anesthesiologist, the larynx and trachea were then visualized by passing a

flexible videobronchoscope through a bronchoscope adaptor on the LMA (Figure 1). To prevent laryngospasm on emergence, 5 to 10 ml of 4% lidocaine was sprayed via the working channel onto vocal folds prior to passing the bronchoscope through the glottic airway.

Care was taken to follow routine laser safety precautions prior to use of the laser, including draping the patient with moist towels and eye pads to minimize fires on the patient's external body.¹³ To minimize risk of fire in the airway, the fraction of inspired oxygen (FiO₂) was reduced to 21%, and fresh gas flow was elevated to 10 liters per minute to expedite clearance of oxygen (O₂) in the airway.¹⁴ Confirmation was obtained from the anesthesiologist that inspiratory and expiratory FiO₂ were below 30% before onset of laser use. These measures have been shown to be sufficient for ensuring FiO₂ levels in the airway have dropped below the safety threshold for laser use.¹⁴ Should the patient have reduced lung reserve requiring intermittent reoxygenation with 100% FiO₂, use of the laser was halted, and the anesthesiologist ventilated the patient with an appropriate level of FiO₂. When the patient was adequately oxygenated, the above steps were repeated before laser use resumed.

Under direct visualization on the video monitor, radial incisions of the stenosis were performed (Figure 2) using a flexible CO₂ laser fiber (OmniGuide Intelliguide FELS-ARC, 2010, Cambridge, Massachusetts, USA) passed through the working channel of the bronchoscope (Model P-180, Olympus America Inc, Center Valley, Pennsylvania, USA) at a setting of 6 to 10 watts, continuous mode. This laser system allows for a maximum of 20 watts power delivery. The fiber was carefully manipulated to minimize contact with blood or tissue. Only 1 fiber was needed for each patient. For circumferential stenosis, at least 5 radial incisions were made within the soft tissue of the stenosis, as has been described for traditional rigid bronchoscopic techniques.³

After radial incisions were made, a CRE balloon dilator (Boston Scientific Corporation, Natick, Massachusetts, USA), with a balloon length of 5.5 cm, was passed through the working channel of a flexible bronchoscope (Model 1T180, Olympus America Inc). This was used to dilate the airway. Dilatation was typically performed 1 or 2 times for 15 to 30 seconds each, to a radial diameter of 15 to 18 mm. These steps were repeated as necessary until the stenotic airway segment was flush with the planes of the distal and proximal normal airway. Hemostasis was achieved with oxymetazoline-soaked cottonoid pledgets applied to the bleeding surface. This was followed by application of pledgets soaked in 0.4 mg/mL mitomycin C for 4 minutes. It should be noted that there are no studies to date that have directly investigated the optimal dose or duration of mitomycin C application for airway stenosis, and the dose we have chosen at our institution is the one typically used by many other investigators.^{9,10,15,16} Pledgets were applied using a flexible biopsy forceps loaded through the bronchoscope working channel. The forceps grasped the pledget and delivered it to the stenotic site by advancing the bronchoscope tip through the LMA. Alternatively, the LMA can also be removed for this portion of the operation and the mitomycin pledget applied directly under direct suspension laryngoscopy. Patients were awakened from general anesthesia and discharged on the day of the operation. They then followed up as outpatients 2 to 4 weeks after surgery and approximately every 3 months thereafter (Figure 3).

Two factors were used to determine the need for further treatment: office-based tracheobronchoscopic appearance of the airway, and the patient's subjective airway symptoms. All postoperative endoscopic examinations were recorded and compared with the preoperative airway appearance at each follow-up visit (Figure 3).

Results

Twenty-one patients with noncartilaginous, incomplete airway stenosis were treated with this LMA protocol between 2008 and 2011. Ten cases had a tracheotomy in place, leaving 11 cases qualifying for inclusion in the study (Table 1). These included 9 women and 2 men with an average age of 49 years (range, 24–75 years). The average follow-up period was 28 months. The etiologies of airway stenosis were intubation injury (55%), idiopathic (36%), and autoimmune disease (Wegener's granulomatosis, 9%).

Airway stenosis ranged from grade 1 to 3, with grade 2 identified most frequently (45%), followed by grade 3 (36%) and grade 1 (18%). The stenotic segment involved the subglottis alone (55%), the trachea alone (18%), or both sites (27%). The length of the stenotic segment was 1 cm in 2 patients (18%) and >1 cm in the remaining 9 patients (82%). The average operative time was 67 minutes (range, 46–110 minutes). The LMA technique was successfully utilized in all patients without needing to convert to rigid endoscopy for the lasering or dilation, and no patients required rigid endoscopy on subsequent procedures. All patients had resolution of their airway symptoms after each treatment from both a subjective and an endoscopic standpoint.

For the entire group, the mean number of procedures was 1.5 (range, 1–3) over an average follow-up period of 28 months (Table 1). The mean number of dilations for the subgroups of intubation injury, idiopathic, and autoimmune etiologies were 1.3, 1.5, and 3, respectively. Repeat dilations, when needed, were performed approximately 8 months apart (range, 2.5 weeks to 2 years). Of note, 1 patient was treated 2.5 weeks after initial surgery for repeat mitomycin c application following the recommendation of Smith and Elstad, although this particular patient experienced complete resolution of symptoms following the initial surgery.⁹ For the autoimmune subgroup, the mean frequency of dilations was 6 months apart.

Discussion

Airway access for ventilation and endoluminal procedures requires a delicate balance. This study demonstrates successful management of subglottic and tracheal stenosis using the LMA with flexible bronchoscopic technique. The majority of patients treated with this technique required only 1 or 2 treatments during the study period. Our outcomes, with regard to the average number of procedures and symptom control, are similar to previous reports using straight laser and bronchoscopic dilations with rigid endoscopy.^{10,16,17}

In our experience, the LMA technique is particularly useful in patients with stenotic airways who are not tracheotomy-dependent because the airway caliber in this patient population can oftentimes be too narrow to allow passage of the smallest endotracheal (ET) tube. Another population for whom this technique is useful is patients whose anatomy is unfavorable for

exposure of the subglottis and trachea on direct laryngoscopy—such as those with cervical spinal fusion. This technique also allows for improved airway control and the ability to provide ventilation and simultaneous close-up visualization of the stenosis.

This constant airway access, even during the endoluminal procedure, is in contrast to ET tubes, which would obstruct endoscopic access, requiring repeated intubation and extubation. ET tubes also carry the risk of disrupting any laryngeal or subglottic lesions during intubation, which can lead to potential bleeding. Furthermore, the physical presence of the ET tube in the airway can serve as a substrate for airway fire ignition and fuel for fire propagation down the respiratory tract.⁹ While these advantages are also obtained with jet ventilation, the LMA technique offers the added benefit of establishing a completely closed and secured airway and avoids some of the risks associated with jet ventilation, such as a pneumothorax. The LMA is an ideal airway for this procedure because ventilating through this device increases airway security without introducing increased risk compared to jet ventilation. The LMA has been shown to be resistant to ignition under laser fire especially when compared to ET tubes.^{18,19} Alternatively, the LMA balloon can be filled with saline similar to laser safe ET tubes so that if the cuff of the LMA is penetrated by the laser, the resultant spill would help neutralize any potential fire. However, the laser should never be fired while the fiber tip is still within the bore of the LMA. In addition, operative duration may be reduced by forgoing repeated intubation and extubation or jet ventilation; however, other reports do not specify their operative times, so no conclusions can be ascertained at this time. In this series, there were no airway fires, deaths, or other complications, supporting the efficacy of this technique without compromising patient safety.

There are a number of CO₂ fiber systems available to the airway surgeon, including the Lumenis FiberLase and the PRI Clinicon SurgiGuide. Some even include aiming beams, such as the Lumenis UltraPulse SurgiTouch, the AccuPulse 40ST, and the KLS Martin MCO 20plus. The flexible laser available at the senior author's institution is the OmniGuide system (OmniGuide Intelliguide FELS-ARC). Of course, there is a cost associated with each use of the flexible laser system, in addition to use of this particular LMA technique. In this series, the average cost of each CRE balloon was \$200, each LMA was \$9, and the OmniGuide ENT-L laser fiber was \$1300. All products were designed to be single-use items. Further reports should compare operative times with the cost of the new technologies to determine if this technique is cost effective compared to other approaches to airway surgery.

The method of measuring postoperative outcome is highly subjective and nonstandardized. The use of comparing voice analysis and peak expiratory to inspiratory flow ratio between the pre- and postoperative states has been proposed as a reproducible and objective means of evaluating airway response to intervention; however, these pulmonary measures have not been proven to correlate with degree of stenosis.²⁰ Using endoscopic views of the airway to judge changes in stenosis can be unreliable, given the impact of lens distortion and tilt.²¹ Methods to eliminate these confounders using mathematical algorithms has been described in an effort to establish a method for quantitative airway sizing. This method is limited to direct laryngoscopic views, whereas our series relies on views obtained using a flexible bronchoscope. In this series, patients' subjective symptoms typically correlated nicely with

objective endoscopic findings of recurrent stenosis when reoperation was offered. Future studies are needed to develop an objective and reproducible method by which airway caliber can be assessed to better standardize outcome measurements and allow comparisons between case series for different airway stenosis treatment methods.

Autoimmune-related stenosis poses a specific therapeutic challenge. In the current series, this subgroup required more dilations on average than any other subgroup. Though our sample size is small, our experience with this subgroup is similar to other reports.^{22–25} Given the underlying inflammatory mechanism of these patients' stenoses, medical management in combination with potential surgical treatment is paramount. Therefore, a multidisciplinary approach must occur with coordination of care by the otolaryngologist and rheumatologist for effective management of these patients.

Conclusion

Subglottic and tracheal stenosis can be managed endoscopically using the LMA for ventilation as well as bronchoscopic delivery of the flexible fiber-based CO₂ laser for radial incisions, balloon dilation, and adjunctive treatment with mitomycin C. The main advantage of this technique is improved management of the airway for surgical access. This series demonstrates that long-term success with minimal morbidity can be achieved with this technique.

Acknowledgments

Funding

The author(s) disclosed receipt of the following financial support for the research, authorship, and/or publication of this article: This study was supported in part by grant RO1 DC011300 from the National Institutes of Health.

References

1. Couraud L, Brichon PY, Velly JF. The surgical treatment of inflammatory and fibrous laryngotracheal stenosis. *Eur J Cardiothorac Surg.* 1988; 2:410–415. [PubMed: 3272247]
2. Grillo HC, Donahue DM, Mathisen DJ, Wain JC, Wright CD. Post intubation tracheal stenosis: treatment and results. *J Thorac Cardiovasc Surg.* 1995; 109:486–492. [PubMed: 7877309]
3. Shapshay SM, Beams JF, Hybels RL, Bohigian RK. Endoscopic treatment of subglottic and tracheal stenosis by radial laser incision and dilation. *Ann Otol Rhinol Laryngol.* 1987; 96:661–664. [PubMed: 3688753]
4. Strong MS, Jako GJ. Laser surgery in the larynx. Early clinical experience with continuous CO₂ laser. *Ann Otol Rhinol Laryngol.* 1972; 81:791–798. [PubMed: 4636137]
5. Houlton J, de Alarcon A, Johnson K, et al. Voice outcomes following adult cricotracheal resection. *Laryngoscope.* 2011; 121(9):1910–1914. [PubMed: 22024843]
6. Koufman JA, Little FB, Weeks DB. Proximal large-bore jet ventilation for laryngeal laser surgery. *Arch Otol Head Neck Surg.* 1987; 113:314–320.
7. Koufman JA, Thompson JN, Kohut RI. Endoscopic management of subglottic stenosis with the CO₂ surgical laser. *Otolaryngol Head Neck Surg.* 1981; 89(2):215–220. [PubMed: 6787516]
8. Simpson GT, Strong MS, Healy GB, Shapshay SM, Vaughan CW. Predictive factors of success or failure in the endoscopic management of laryngeal and tracheal stenosis. *Ann Otol Rhinol Laryngol.* 1982; 91(4 pt 1):384–388. [PubMed: 7114718]
9. Smith ME, Elstad M. Mitomycin C and the endoscopic treatment of laryngotracheal stenosis: are two applications better than one? *Laryngoscope.* 2009; 119(2):272–283. [PubMed: 19160408]

10. Roediger FC, Orloff LA, Courey MS. Adult subglottic stenosis: management with laser incisions and mitomycin-C. *Laryngoscope*. 2008; 118(9):1542–1546. [PubMed: 18677286]
11. Myer CM, O'Connor DM, Cotton RT. Proposed grading system for subglottic stenosis based on endotracheal tube sizes. *Ann Otol Rhinol Laryngol*. 1994; 103(4):319–323. [PubMed: 8154776]
12. Chhetri DK, Long JL. Airway management and CO2 laser treatment of subglottic and tracheal stenosis using flexible bronchoscope and laryngeal mask anesthesia. *Op Techs Otolaryngol*. 2011; 22:131–134.
13. Ahmed F, Kinshuck AJ, Harrison M, et al. Laser safety in head and neck cancer surgery. *Eur Arch Otorhinolaryngol*. 2010; 267(11):1779–1784. [PubMed: 20652294]
14. Remz M, Luria I, Gravenstein M, et al. Prevention of airway fires: do not overlook the expired oxygen concentration. *Anesth Analg*. 2013; 117(suppl 1):1–77.
15. Simpson CB, James JC. The efficacy of mitomycin-C in the treatment of laryngotracheal stenosis. *Laryngoscope*. 2006; 116(10):1923–1925. [PubMed: 17003706]
16. Rahbar R, Shapshay SM, Healy GB. Mitomycin: effects on laryngeal and tracheal stenosis, benefits, and complications. *Ann Otol Rhinol Laryngol*. 2001; 110(1):1–6. [PubMed: 11201800]
17. Valdez TA, Shapshay SM. Idiopathic subglottic stenosis revisited. *Ann Otol Rhinol Laryngol*. 2002; 111(8):690–695. [PubMed: 12184589]
18. Keller C, Brimacombe J, Coorey A, Wood V, Keller K. Liability of laryngeal mask airway devices to thermal damage from KTP and Nd:YAG lasers. *Br J Anaesth*. 1999; 82(2):291–294. [PubMed: 10365014]
19. Brimacombe J. The incendiary characteristics of the laryngeal and reinforced laryngeal mask airway to CO2 laser strike— a comparison with two polyvinyl chloride tracheal tubes. *Anaesth Intensive Care*. 1994; 22(6):694–697. [PubMed: 7892974]
20. Plouin Gaudon I, Lawson G, Jamart J, et al. Subtotal carbon dioxide laser arytenoidectomy for the treatment of bilateral vocal fold immobility: long-term results. *Ann Otol Rhinol Laryngol*. 2005; 114(2):115–121. [PubMed: 15757190]
21. Nouraei SA, McPartlin DW, Nouraei SM, et al. Objective sizing of upper airway stenosis: a quantitative endoscopic approach. *Laryngoscope*. 2006; 116(1):12–17. [PubMed: 16481801]
22. Lebovics RS, Hoffman GS, Leavitt RY, et al. The management of subglottic stenosis in patients with Wegener's granulomatosis. *Laryngoscope*. 1992; 102(12 pt 1):1341–1345. [PubMed: 1453838]
23. Hoffman GS, Thomas-Golbanov CK, Chan J, et al. Treatment of subglottic stenosis, due to Wegener's granulomatosis, with intralesional corticosteroids and dilation. *J Rheumatol*. 2003; 30(5):1017–1021. [PubMed: 12734898]
24. Shvero J, Shitrit D, Koren R, et al. Endoscopic laser surgery for subglottic stenosis in Wegener's granulomatosis. *Yonsei Med J*. 2007; 48(5):748–753. [PubMed: 17963330]
25. Alaani A, Hogg RP, Lee ABD. Wegener's granulomatosis and subglottic stenosis: management of the airway. *J Laryngol Otol*. 2004; 118(10):786–790. [PubMed: 15550185]

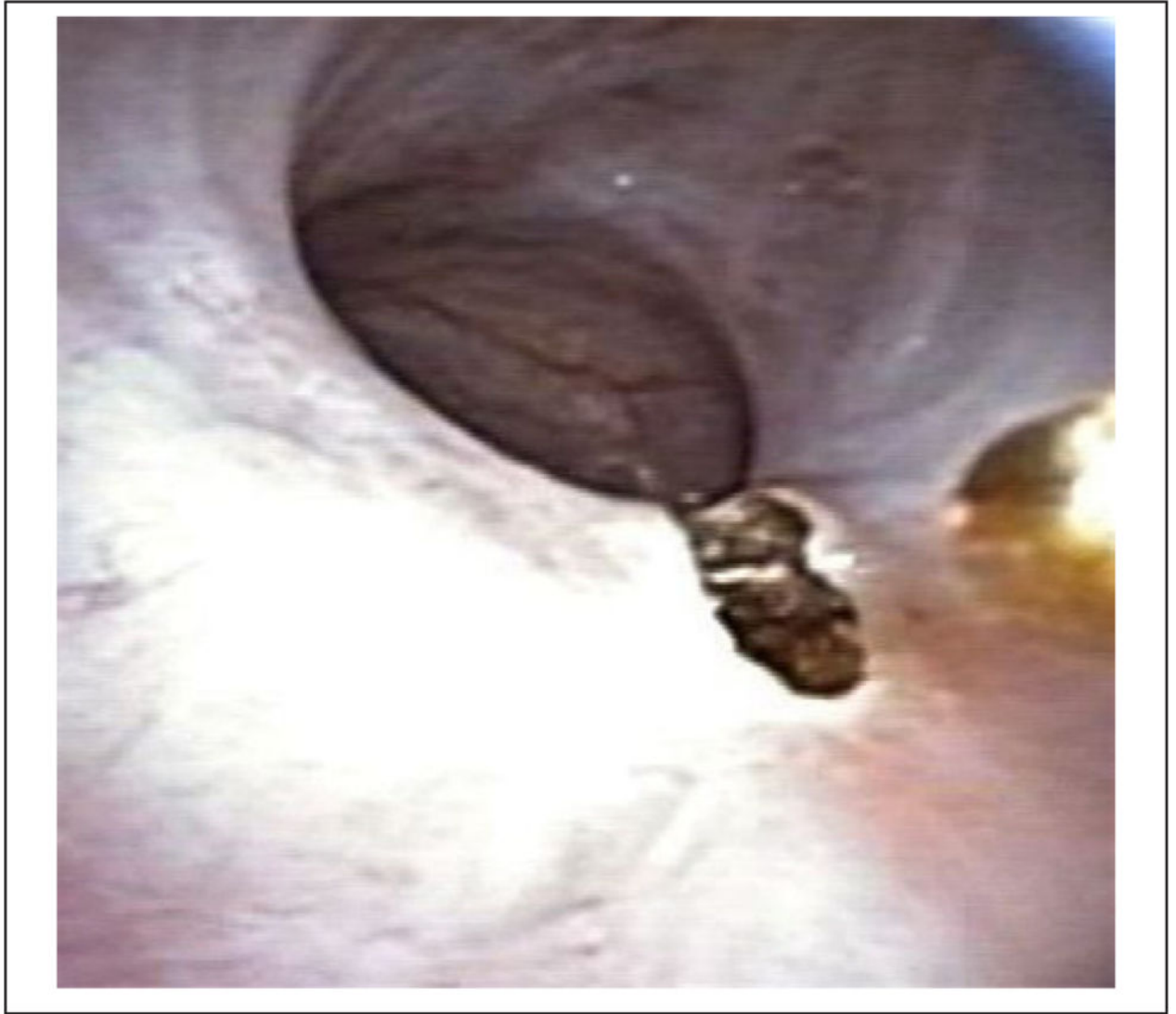


Figure 1. Idiopathic subglottic stenosis viewed with a videobronchoscope passed through the laryngeal mask airway (LMA) at the onset of CO₂ laser radial incisions. The first radial incision is shown at the lower right corner. Continuous general anesthesia is provided during the procedure using the LMA.

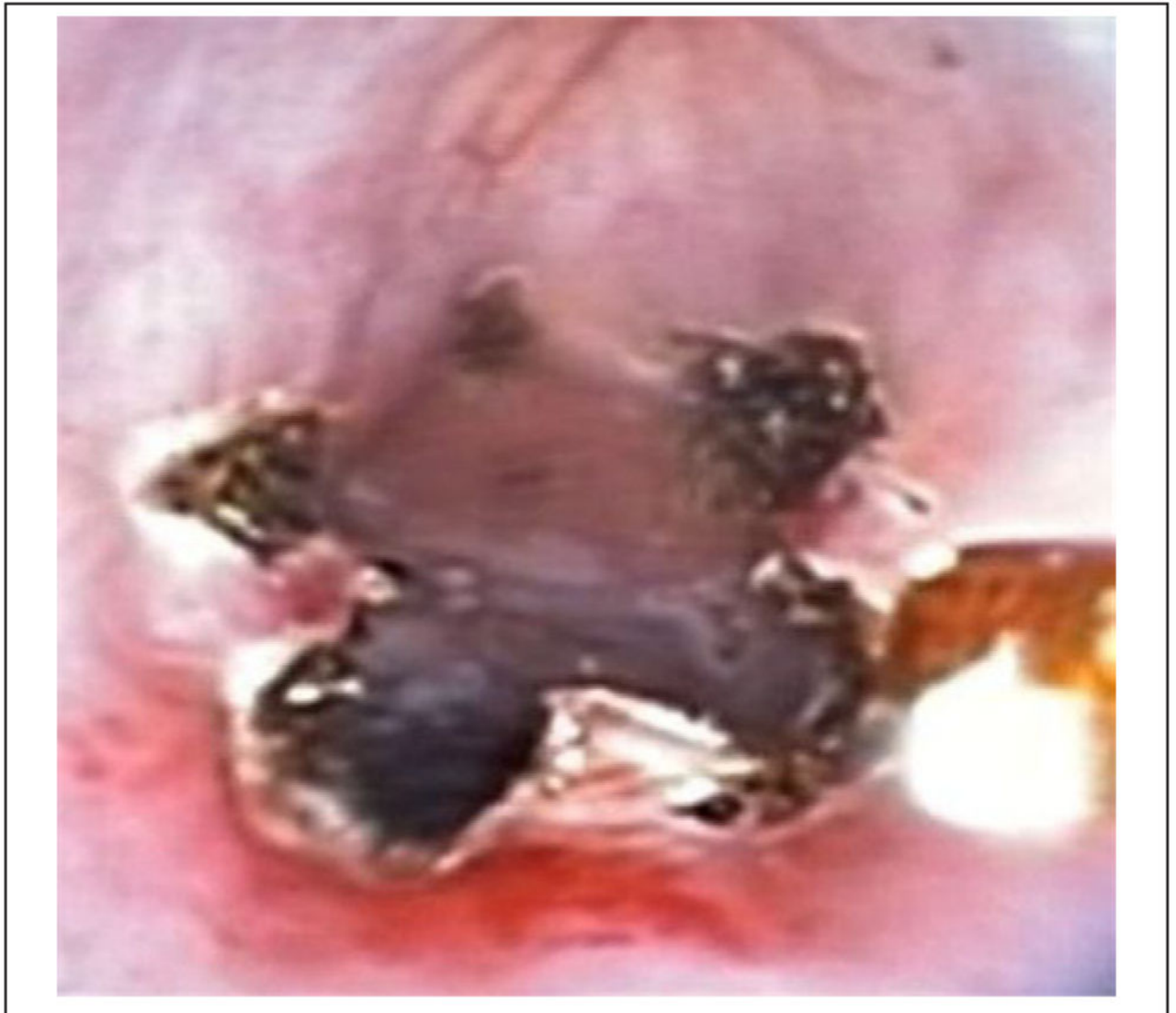

Figure 2. Idiopathic subglottic stenosis viewed with the videobronchoscope passed through the laryngeal mask airway (LMA) at the completion of CO₂ laser radial incisions.

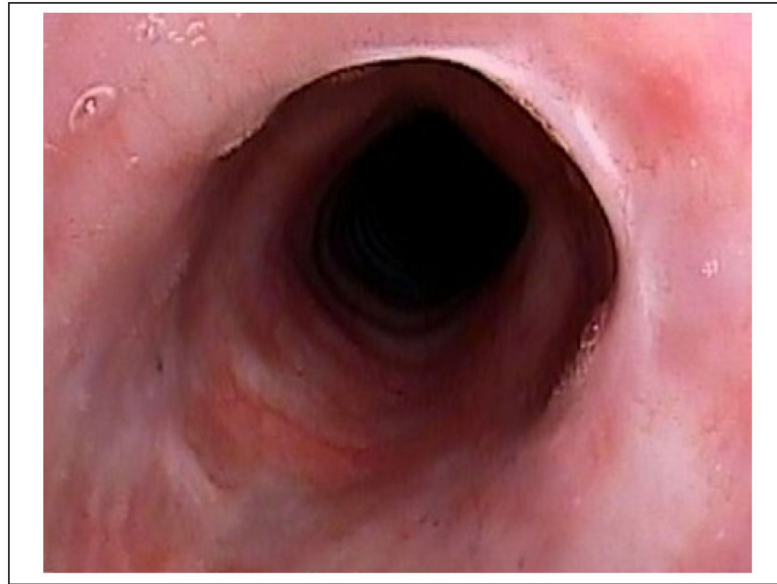


Figure 3.
In-office videoendoscopic view of idiopathic subglottic stenosis 18 months after endoscopic treatment.

Table 1

Patient Data.

Pt	Age, y	Sex	Dx	Grade	Length of stenosis, cm	Site	Treatments, no.	Avg INT, wks	Avg operative time, min	FU, mo
1	24	M	Intubation	3	1	SG	1	n/a	88	20
2	69	F	Intubation	2	1.5	SG	2	8	67	26
3	32	F	Intubation	1	1.5	SG	1	n/a	110	23
4	36	F	Intubation	3	0.5	Trachea	2	2.5	48	24
5	75	M	Intubation	2	3	Trachea	1	n/a	46	6
6	66	F	Intubation	1	2	SG	1	n/a	55	20
7	46	F	Idiopathic	3	1.5	SG	1	n/a	97	22
8	39	F	Idiopathic	3	2	SG, Trachea	2	35	65	12
9	60	F	Idiopathic	2	2	SG, Trachea	2	112	52	35
10	34	F	Idiopathic	2	2	SG, Trachea	1	n/a	65	5
11	55	F	WG	2	1.5	SG	3	26	48	24

Abbreviations: Avg INT, average interval between procedures; Dx, diagnosis; FU, total follow-up; Pt, patient; SG, subglottis; WG, Wegener's granulomatosis.