

# UC Davis

## UC Davis Previously Published Works

### Title

Proximal femoral reconstruction for failed internal fixation of a bisphosphonate-related femur fracture

### Permalink

<https://escholarship.org/uc/item/8sv2w54g>

### Journal

Arthroplasty Today, 2(4)

### ISSN

2352-3441

### Authors

Jethanandani, Rishabh G  
Nwankwo, Chima  
Wolinsky, Philip R  
et al.


### Publication Date

2016-12-01

### DOI

10.1016/j.artd.2016.04.001

Peer reviewed



## Case report

## Proximal femoral reconstruction for failed internal fixation of a bisphosphonate-related femur fracture

Rishabh G. Jethanandani, BSE <sup>a</sup>, Chima Nwankwo, MD <sup>b</sup>, Philip R. Wolinsky, MD <sup>c</sup>,  
Mauro Giordani, MD <sup>c</sup>, Derek F. Amanatullah, MD, PhD <sup>a,\*</sup>

<sup>a</sup> Department of Orthopaedic Surgery, Stanford University, Redwood City, CA, USA

<sup>b</sup> Department of Orthopaedic Surgery, St. Mary's Medical Center, San Francisco, CA, USA

<sup>c</sup> Department of Orthopaedic Surgery, University of California, Davis, Sacramento, CA, USA

## ARTICLE INFO

## Article history:

Received 24 January 2016

Received in revised form

16 April 2016

Accepted 19 April 2016

Available online 24 August 2016

## Keywords:

Total hip arthroplasty

Proximal femoral replacement

Bisphosphonate

Subtrochanteric

Atypical

Femur fracture

## ABSTRACT

We present a case of a bisphosphonate-related femur fracture in an elderly woman, who failed treatment with both cephalomedullary nail and proximal femoral locking plate, leading to successful treatment with total hip arthroplasty. Hardware failure should be included in the differential of patients with previous internal fixation of bisphosphonate-related femur fracture that present with hip or groin pain. Arthroplasty can be an acceptable salvage option in an active elderly patient with a bisphosphonate-related femur fracture.

© 2016 The Authors. Published by Elsevier Inc. on behalf of The American Association of Hip and Knee Surgeons. This is an open access article under the CC BY-NC-ND license (<http://creativecommons.org/licenses/by-nc-nd/4.0/>).

## Introduction

Bisphosphonates reduce the overall risk of fractures in patients with osteoporosis, even after cessation of use [1]. Numerous studies suggest a link between prolonged bisphosphonate therapy and atypical fractures of the femur [2,3]. The consensus is that bisphosphonate-related femur fractures (BRFFs) are rare [2,3].

There are no standardized practices for the surgical management of BRFFs. The use of total hip arthroplasty (THA) in the management of a bisphosphonate-related subtrochanteric femur

fracture has not been reported in the surgical literature. We describe such a case in an active elderly woman who failed fixation with a cephalomedullary nail (CMN) and proximal femoral locking plate (PFLP) necessitating treatment with proximal femoral replacement (PFR). The patient was informed that information concerning her case would be submitted for publication.

## Case history

A 69-year-old woman treated with a CMN a month prior at an outside hospital for a left atypical subtrochanteric femur fracture presented to our emergency department with a complaint of left hip pain. She was on bisphosphonate therapy for the past 10 years. She was physically active before her initial fracture. She reported a one-day history of pain that began suddenly while attempting to get off the toilet. The pain was localized to her left groin and was steady, continuous, nonradiating, exacerbated by movement, and inhibited ambulation. Physical examination revealed a healed operative wound at her lateral left hip. Her left leg was held preferentially in external rotation. Subsequent radiographs revealed an angulated left subtrochanteric fracture with a transverse fracture line through the lateral cortex, a short medial spike, and failure of the CMN (Fig. 1).

One or more of the authors of this paper have disclosed potential or pertinent conflicts of interest, which may include receipt of payment, either direct or indirect, institutional support, or association with an entity in the biomedical field which may be perceived to have potential conflict of interest with this work. For full disclosure statements refer to <http://dx.doi.org/10.1016/j.artd.2016.04.001>.

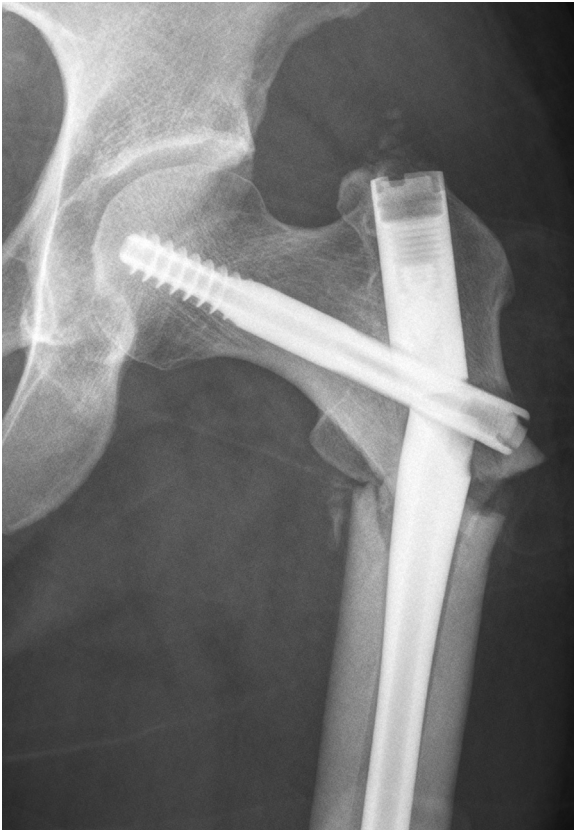There is no institutional review board approval required at our institution for case reports. However, the authors have obtained the patient's informed verbal consent for print and electronic publication of the case report.

\* Corresponding author. 450 Broadway Street, Pavilion C, 4th Floor, Redwood City, CA 94063-6342, USA. Tel.: +1 650 721 7638.

E-mail address: [dfa@stanford.edu](mailto:dfa@stanford.edu)

<http://dx.doi.org/10.1016/j.artd.2016.04.001>

2352-3441/© 2016 The Authors. Published by Elsevier Inc. on behalf of The American Association of Hip and Knee Surgeons. This is an open access article under the CC BY-NC-ND license (<http://creativecommons.org/licenses/by-nc-nd/4.0/>).



**Figure 1.** Anteroposterior (AP) radiograph of the left hip showing a bisphosphonate-related femur fracture treated with a cephalomedullary nail that went on to implant failure.

The next morning, she underwent surgery for removal of hardware and open reduction and internal fixation of her left proximal femur. After the CMN was removed, impaction bone grafting of the femoral head, femoral neck, and greater trochanter was performed using allograft bone chips and demineralized bone matrix. A laterally based PFLP was applied after compression of the fracture (Fig. 2a and b). She was discharged 4 days later to a skilled nursing facility with toe-touch weight-bearing precautions

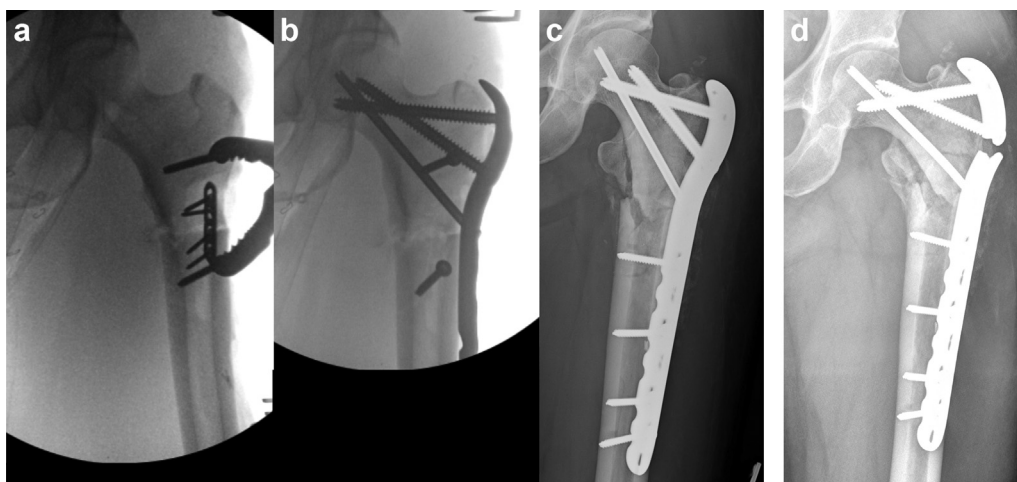
with calcium carbonate and vitamin D supplementation. Her bisphosphonate therapy was discontinued.

At 2 weeks, her left hip pain was steadily decreasing, her wound was healed, and she had no postoperative neurovascular deficits. Radiographic images revealed a stable construct and showed no evidence of hardware failure (Fig. 2c).

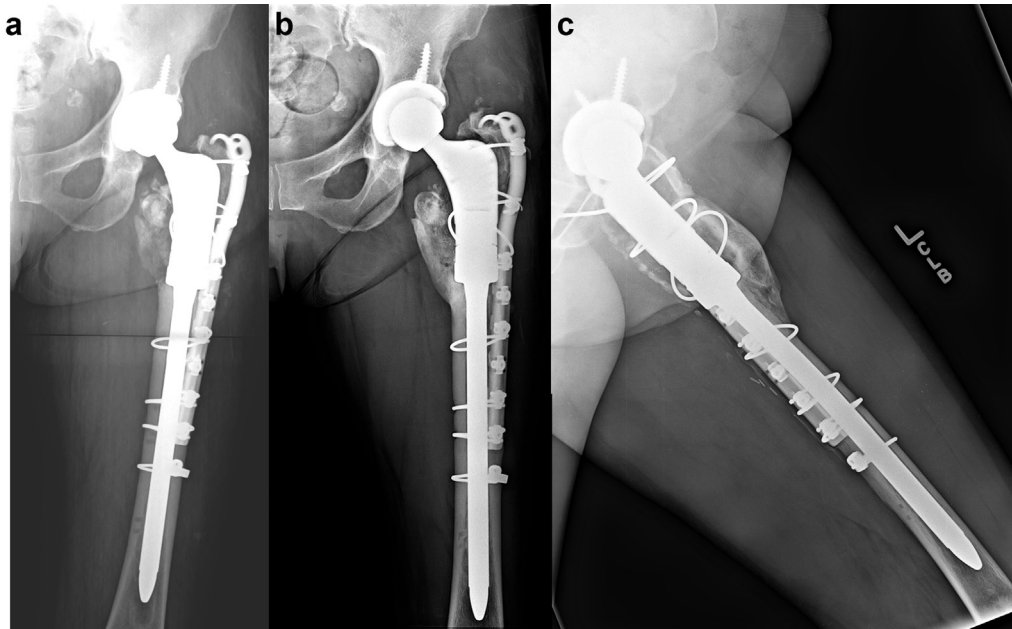
At 2 months, the patient complained of increasing left hip pain and inability to ambulate. She did not report any recent falls or other traumatic events. A physical examination was notable for pain with range of motion of her hip. Review of her radiographs demonstrated an atrophic nonunion at the site of the displaced subtrochanteric femur fracture and failure of the laterally based PFLP just proximal to the fracture site (Fig. 2d). Erythrocyte sedimentation and C-reactive protein levels were normal, so 2 surgical options were reviewed with the patient—(1) placement of a fixed angle blade plate with compression at the fracture site, possible addition of autologous bone graft or other biologic agent, and initiation of teriparatide therapy or (2) THA with a distally fixed implant. The risks and benefits of each intervention were outlined, including the off label use of teriparatide to act as an anabolic agent and make bone as well as the theoretical risk of osteosarcoma. The patient, in concert with her family and surgeon, selected THA.

The next morning, she underwent removal of hardware and reconstruction of the left hip via a posterior approach. A large amount of the proximal femur necessitated resection as it was deemed intraoperatively to be nonviable. Once the nonunion was resected back to healthy bone, a PFR was required for reconstruction of the left hip (Fig. 3a). Intraoperative range of motion at the hip joint was observed to be stable. The remainder of the patient's hospitalization was uneventful. She was able to ambulate with physical therapy on postoperative day 1 and was subsequently discharged to a skilled nursing facility for further rehabilitation with left-sided posterior hip precautions and touch down weight-bearing restrictions.

At 6 weeks, she reported good pain control on occasional oral narcotic pain medication. Her incision was healed. She was routinely ambulating over 300 feet with a front-wheel walker. She was advanced to weight bearing at tolerated and instructed to begin weaning her assistive device. At 3 months, she reported good pain control off oral narcotic pain medication and was ambulating over 300 feet with a cane. At 2 years, she reported no pain, however, still required a cane (Fig. 3b). Her Harris hip score had improved dramatically from 20 preoperatively to 80 at final follow-up.



**Figure 2.** (a) Fluoroscopic view of compression being applied via a Farabeuf clamp. (b) Fluoroscopic view after application of the proximal femoral locking plate. (c) AP radiograph of the left hip after treatment of the bisphosphonate-related femur fracture with compression and a proximal femoral locking plate. (d) AP radiograph of a bisphosphonate-related femur fracture treated with a proximal femoral locking plate that went on to implant failure.



**Figure 3.** (a) Postoperative anteroposterior radiograph of the bisphosphonate-related femur fracture treated with proximal femoral replacement and hook plate. (b) Anteroposterior radiograph of the left hip 2 years postoperatively demonstrating no subsidence, no pedestal, and lack of greater trochanteric migration all suggestive of stable a stable implant as well as union of the greater trochanter. (c) Frog leg lateral radiograph of the left hip 2 years postoperatively demonstrating distal spot welding, streaming trabeculae, and fracture union all suggestive of stable osseointegration.

## Discussion

Biphosphonates are used in the treatment of a variety of conditions including primary and metastatic tumors, heritable pediatric skeletal disorders, and metabolic diseases of bone. The implications of long-term bisphosphonate use are an area of ongoing research.

Biphosphonates accumulate at the site of bone resorption and are preferentially taken up by osteoclasts, inhibiting their ability to effectively resorb bone by dismantling the ruffled border and inducing apoptosis [4]. Bisphosphonates reduce bone turnover, increase overall mineralization, and affect the organic matrix by altering collagen maturity, crosslinking, and heterogeneity [2,5]. Bisphosphonates decrease cortical bone toughness [2,6].

Bone resorption by osteoclasts and bone formation by osteoblasts are closely linked at bone remodeling sites. Normally occurring microcracks are repaired through remodeling. Excessive bone remodeling results in bone loss and increased susceptibility to fragility fractures. The suppression of osteoclast activity by bisphosphonates significantly reduces the loss of bone that occurs through remodeling. However, this is also associated with increased microdamage accumulation because microcracks are not removed efficiently [7]. It is believed that microcracks accumulated and are propagated as stress fractures resulting in an atypical fracture.

BRFFs are observed in the subtrochanteric and diaphyseal regions as a result of minimal or no trauma. There can be prodromal thigh or groin pain. The fracture may be complete, seen as a transverse, or slightly oblique fracture extending across the entire femoral shaft, or incomplete, manifested by a radiolucent line in the lateral cortex and an oblique fracture line medially. They initially appear as thickening of the lateral cortex that subsequently develops into a fracture. Our patient has several of the major and minor features of BRFFs as defined by the American Society for Bone and Mineral Research and noted in numerous case reports [2].

Stress fractures heal via a different mechanism than acute fractures. Acute fractures heal via endochondral ossification, marked by cartilaginous callus formation after an initial inflammatory response. Bisphosphonates do not affect the initial development of

proliferative callus; however, bisphosphonates slow the remodeling of calcified callus into mature bone [8]. On the other hand, stress fractures heal via osteoclast-dependent bone remodeling which, as previously discussed, is reduced by bisphosphonate treatment. Intramedullary nailing allows for endochondral repair at the fracture site, whereas compression plating precludes this. Consequently, intramedullary nailing is recognized as the preferred method of treatment for BRFFs, even in the absence of controlled studies evaluating surgical treatment strategies [2].

BRFFs are difficult to manage surgically and hard to heal biologically [2,9–11]. In a retrospective review of 20 patients with subtrochanteric femur fractures, 3 of 12 (25%) patients treated with alendronate therapy had a nonunion fracture, versus only 1 of 8 (12.5%) in patients in the control group [9]. Two of the 3 nonunions were initially plated but required revision surgery to an intramedullary nail. The third nonunion was initially treated with a CMN. Based on this experience, treating BRFFs with an intramedullary implant, cessation of the bisphosphonate, and consideration of treatment with teraparotide postoperatively are recommended. Another retrospective review of 25 patients with BRFFs demonstrated postoperative failure of plating in 3 of 10 (30%) plated femurs, compared to 0 in of 15 (0%) patients treated with a nail [11]. Furthermore, none of the 20 control patients with similar, but non-bisphosphonate-related fractures, had postoperative failure. In addition, the time to union in the bisphosphonate cohort was 26 weeks as opposed to 19 weeks in the control cohort [11]. A case report describes 2 BRFFs initially treated with intramedullary nails that went on to develop atrophic nonunions. These patients were successfully treated with removal of the nail and definitive plating to achieve compression across the fracture [10]. Another retrospective review of 15 patients with BRFFs showed a revision rate of 46% after nailing, with one patient receiving a blade plate [12]. These reports collectively support the notion that BRFFs may have a higher propensity for delayed healing and hardware failure, especially when plate fixation is used initially.

There is emerging data that bisphosphonate use during THA may half the risk of all-cause revision and aseptic loosening

supporting the utilization of cementless fixation in osteoporotic patients on a bisphosphonate [13]. However, these data do not specifically address the optimal type of fixation for femoral of acetabular implants, especially in the setting of a BRFF. Cementation given the osteoporotic bone is also a reasonable means of fixation in osteoporotic bone.

### Summary

The standard treatment for BRFF is internal fixation. However, when fixation failure occurs in a patient with osteoporotic bone a salvage procedure with a PFR is a surgical option. THA is a possible alternative to internal fixation and hemiarthroplasty for an elderly patient with higher functional demands and a long-life expectancy [14,15]. THA is an acceptable treatment solution for failed internal fixation of intertrochanteric or subtrochanteric femur fractures in the elderly [16]. In this case report, arthroplasty offered advantages to repeat open reduction and compression with an angled blade plate after careful consideration of patient comorbidities, functional demands, and risk for revision. The degree of osteoporosis suggested that PFR might offer a better outcome than internal fixation through bone that was significantly nonviable in the proximal femoral region. In addition, THA offers the advantage of early weight bearing and mobilization, making it a potentially less morbid option in the elderly. Moreover, the likelihood of a future operation for a nonunion, malunion, or hardware failure is mitigated. This is especially important given the propensity for delayed healing in BRFFs.

### References

- Black DM, Schwartz AV, Ensrud KE, et al. Effects of continuing or stopping alendronate after 5 years of treatment: the Fracture Intervention Trial Long-term Extension (FLEX): a randomized trial. *JAMA* 2006;296(24):2927.
- Shane E, Burr D, Ebeling PR, et al. Atypical subtrochanteric and diaphyseal femoral fractures: report of a task force of the American Society for Bone and Mineral Research. *J Bone Miner Res* 2010;25(11):2267.
- Schilcher J, Michaelsson K, Aspenberg P. Bisphosphonate use and atypical fractures of the femoral shaft. *N Engl J Med* 2011;364(18):1728.
- Azuma Y, Sato H, Oue Y, et al. Alendronate distributed on bone surfaces inhibits osteoclastic bone resorption in vitro and in experimental hypercalcemia models. *Bone* 1995;16(2):235.
- Odvina CV, Zerwekh JE, Rao DS, et al. Severely suppressed bone turnover: a potential complication of alendronate therapy. *J Clin Endocrinol Metab* 2005;90(3):1294.
- Allen MR, Reinwald S, Burr DB. Alendronate reduces bone toughness of ribs without significantly increasing microdamage accumulation in dogs following 3 years of daily treatment. *Calcif Tissue Int* 2008;82(5):354.
- Allen MR, Burr DB. Bisphosphonate effects on bone turnover, microdamage, and mechanical properties: what we think we know and what we know that we don't know. *Bone* 2011;49(1):56.
- McDonald MM, Schindeler A, Little DG. Bisphosphonate treatment and fracture repair. *IBMS BoneKEy-Osteovision* 2007;4(9):236.
- Das De S, Setiobudi T, Shen L. A rational approach to management of alendronate-related subtrochanteric fractures. *J Bone Joint Surg Br* 2010;92(5):679.
- Grady MK, Watson JT, Cannada LK. Treatment of femoral fracture nonunion after long-term bisphosphonate use. *Orthopedics* 2012;35(6):e991.
- Prasarn ML, Ahn J, Helfet DL, Lane JM, Lorch DG. Bisphosphonate-associated femur fractures have high complication rates with operative fixation. *Clin Orthop Relat Res* 2012;470(8):2295.
- Weil Yoram A, Rivkin Gurion, Safran Ori, Libergall MM. The outcome of surgically treated femur fractures associated with long-term bisphosphonate use. *J Trauma Acute Care Surg* 2011;71(1):186.
- Khatod M, Inacio MC, Dell RM, et al. Association of bisphosphonate use and risk of revision after THA: outcomes from a US Total Joint Replacement Registry. *Clin Orthop Relat Res* 2015;473(11):3412.
- Hedbeck CJ, Enocson A, Lapidus G, et al. Comparison of bipolar hemiarthroplasty with total hip arthroplasty for displaced femoral neck fractures: a concise four-year follow-up of a randomized trial. *J Bone Joint Surg Am* 2011;93(5):445.
- Ravikumar KJ, Marsh G. Internal fixation versus hemiarthroplasty versus total hip arthroplasty for displaced subcapital fractures of femur—13 year results of a prospective randomised study. *Injury* 2000;31(10):793.
- Haentjens P, Casteleyn PP, Opdecam P. Hip arthroplasty for failed internal fixation of intertrochanteric and subtrochanteric fractures in the elderly patient. *Arch Orthop Trauma Surg* 1994;113(4):222.