

UC Irvine

UC Irvine Previously Published Works

Title

Successful treatment of angioinvasive aspergillosis during prolonged neutropenia with liposomal amphotericin, voriconazole, and caspofungin

Permalink

<https://escholarship.org/uc/item/8ts5f2sj>

Journal

Infectious Diseases in Clinical Practice, 11(6)

ISSN

1056-9103

Authors

Huang, SS
Chan, IT
Stone, RM
[et al.](#)

Publication Date

2002-08-01

DOI

10.1097/01.idc.0000078754.71576.ce

License

<https://creativecommons.org/licenses/by/4.0/> 4.0

Peer reviewed

Successful Treatment of Angioinvasive Aspergillosis During Prolonged Neutropenia with Liposomal Amphotericin, Voriconazole, and Caspofungin

Susan S. Huang,
Iris T. Chan,
Richard M. Stone, and
Lindsey R. Baden

Case Report. Treatment of invasive aspergillosis is changing because of new antifungal agents. Voriconazole and caspofungin have been studied for treatment of invasive aspergillosis refractory to treatment with amphotericin. However, optimal therapeutic combinations and durations are unknown. We report the successful treatment of angioinvasive aspergillosis in an immunocompromised host with a triple antifungal regimen of amphotericin, voriconazole, and caspofungin.

A 69-year-old man with fevers and chills presented to a local hospital in November 2000 following 6 weeks of progressive fatigue, dyspnea, and weight loss. Of note, he had been constructing a new home. He was neutropenic (absolute neutrophil count of 10 cells/ μ l), and the proportion of blasts on a peripheral blood smear was 2%. Chest computed tomography (CT) revealed left-upper-lobe and bilateral lower-lobe consolidative opacities. He was transferred to our hospital, where a bone marrow biopsy revealed FAB subtype M1 acute myelogenous leukemia.

Treatment with levofloxacin and ceftazidime was initiated for pneumonia and febrile neutropenia, and

he underwent urgent induction chemotherapy on CALGB protocol 9720 [1] with daunorubicin, etoposide, and high-dose ara-C. Amphotericin B (1 mg/kg per day) was added because of persistent fevers. On day +8 relative to chemotherapy initiation, a sputum culture yielded *Aspergillus niger*. He was switched to treatment with high-dose liposomal amphotericin (7.5 mg/kg per day) because of therapy-associated renal insufficiency.

A second chest CT demonstrated bilobar pneumonia with complete opacification of the left lower lobe

(Fig. 1A), left apical focal necrosis, and a segmental pulmonary artery filling defect, suspicious for angioinvasion. Additional sputum cultures and bronchoscopy did not demonstrate a pathogen.

His fevers diminished with resolution of neutropenia, and he underwent a diagnostic thoracoscopic biopsy on day +31. Examination of a frozen section of his lung revealed extensive involvement with *Aspergillus* species, but cultures were negative.

Given severe disease and progression on polyene therapy, com-

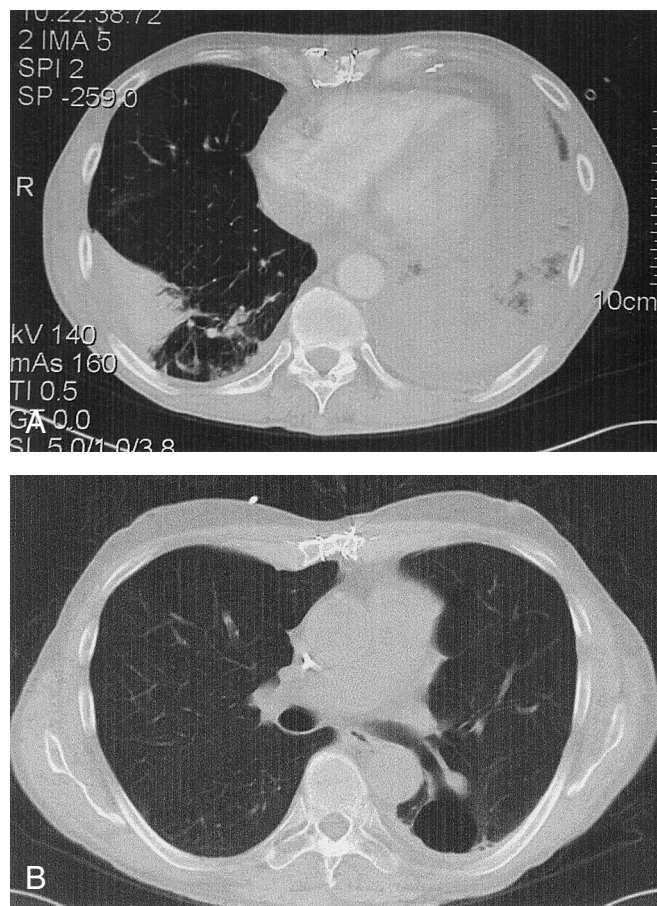


FIGURE 1. A, Chest CT following induction chemotherapy for AML, showing extensive left-lower-lobe consolidation and infarct and a right-lower-lobe wedge-shaped infarct with an adjacent loculated effusion due to biopsy-proven aspergillus infection. B, Chest CT 8 months later showing evolution of the left-lower-lobe infarct into a 3.5 \times 3.5 cm² cavitary structure in communication with the left-lower-lobe bronchus. No active pulmonary disease is seen.

passionate-use voriconazole (200 mg orally twice daily, subsequently increased to 300 mg twice daily) was given in addition to liposomal amphotericin (7.5 mg/kg per day). He was also treated surgically with left-lung decortication and debulking of a subpleural fungal abscess.

On day +64, he received consolidation chemotherapy and developed neutropenic fever. Chest CT showed increasing right middle and lower lobe opacities and persistent left-sided consolidation. These opacities stabilized with recovery of his neutrophil count to $>1,000$ cells/mm³. G-CSF was not administered.

On day +96 hemoptysis developed (100 ml), prompting the addition of caspofungin (70-mg IV loading dose, then 50 mg/day) to the treatment regimen for possible progressive angioinvasive aspergillosis. Chest CT findings remained stable, but further hemoptysis (250 ml) on day +116 required emergent intubation and rigid bronchoscopy. Bronchial blocker placement and emergent left-bronchial-artery embolization were required for stabilization.

On day +151 the caspofungin dosage was increased to 70 mg/day because of persistent right-sided infiltrates. By day +156, the liposomal amphotericin dosage was decreased to 7.5 mg/kg three times a week in anticipation of home infusion. A bone marrow biopsy showed continued remission, and subsequent chest CT showed significant diminishment of infiltrates bilaterally. On day +164 he was discharged to home.

Subsequently, in the infectious diseases clinic, it was noted that he had developed a tan despite limited sun exposure. Iron and cortisol levels were normal. Initially, he was pancytopenic, requiring blood transfusions twice. Workup for secondary causes of anemia were negative, and these were believed to be po-

tential side effects of the antifungal regimen. His outpatient medications included only nutritional supplements, metoprolol, and the triple-antifungal regimen.

Striking macrocytosis (MCV = 103.5) developed despite normal B12 and folate levels. Hepatitis serologies were negative, and transaminase levels remained normal. The alkaline phosphatase level became persistently elevated (to 150 mg/dl).

His performance status improved rapidly. He had no constitutional symptoms or further hemoptysis. He regained 23 pounds, 11 pounds short of his baseline weight (before induction therapy). A chest CT showed evolution of the pulmonary infarcts into large cavitory structures, including a left-lower-lobe (3.5×3.5 cm²) cavity in communication with the left-lower-lobe bronchus (Fig. 1B).

On day +252 (3 months after his last symptom or sign of infection), liposomal amphotericin was withdrawn because the creatinine concentration rose from 1.1 to 2.0 mg/dl. On day +287, caspofungin was withdrawn. In total, he received 94.47 g of liposomal amphotericin (244 days) and 12.41 g of caspofungin (192 days). He continued to receive voriconazole, 300 mg twice a day, until day +380, when it was withdrawn after 7 months of stable CT findings consistent with scarring and cavity formation.

One month later, a bone marrow biopsy was performed to investigate a newly declining platelet count. It revealed early relapse of AML. Voriconazole administration was restarted preemptively, and the patient underwent a nonmyeloablative peripheral stem cell transplantation from a fully matched related donor on April 12, 2002. Serial chest CTs showed no active pulmonary disease, and a bone marrow

biopsy performed 104 days after transplantation revealed remission.

Discussion. Multilobar aspergillus pneumonia during prolonged neutropenia is associated with a nearly 100% fatality rate, even with amphotericin treatment. During the course of this man's illness, caspofungin was FDA-approved, and voriconazole became available by compassionate release (now FDA approved [May 2002]). This report shows promise for combination antifungal therapy with these agents.

Voriconazole is a novel triazole that inhibits ergosterol incorporation into fungal cell membranes. Its in vitro activity against *Aspergillus* species is comparable to that of amphotericin. It has a bioavailability of 90%, volume of distribution of 2 l/kg, and half-life of 6 hours, and it is 58% protein-bound [2]. Like other azoles, voriconazole is metabolized by the hepatic cytochrome CYP3A4, 2C9, and 2C19 systems and interacts with drugs such as erythromycin, omeprazole, warfarin, and calcineurin inhibitors.

In vitro antagonism between polyenes (amphotericin) and azoles has been demonstrated in vitro [3]. Theoretically, inhibition of ergosterol synthesis by azoles reduces available binding sites for amphotericin. In fact, in vitro antagonism is most strongly manifested when azoles are given prior to amphotericin [4]. Nevertheless, antagonism in humans has not been established, and success with combination therapy has been reported [5].

We believed that the theoretical risk for antagonism did not outweigh the potential benefits of combined therapy [6], given the established use of polyenes and the preliminary success of voriconazole in the treatment of invasive aspergillosis at the time this case was managed. Subsequent to the

management of this case, a multicenter clinical trial showed that amphotericin was superior to voriconazole (by the composite endpoint) for empiric treatment of febrile neutropenia. However, significantly fewer breakthrough fungal infections occurred in the voriconazole group, and two additional large studies have demonstrated the efficacy and safety of voriconazole in the management of invasive aspergillosis [8,9]. In the study by Herbrecht et al. [9], voriconazole was found to be equivalent or superior to amphotericin B in single-agent therapy. The role of combination therapy has not yet been evaluated in a clinical trial.

Caspofungin is an echinocandin, a new class of agents that irreversibly inhibit 1,3- β -D-glucan synthase, leading to depletion of glucan in fungal cell walls and subsequent osmotic instability. This is a distinct mechanism of action in comparison with azoles and polyenes. Caspofungin has a half-life of 9–10 hours, is 80%–96% protein-bound, and is not eliminated by the p450 system [10]. However, drug interactions with calcineurin inhibitors, rifamycins, efavirenz, phenytoin, and nelfinavir have been noted. It was FDA-approved in January 2001 for the treatment of invasive aspergillosis refractory to treatment with amphotericin [11].

Several key points are worth highlighting in this case. First, unlike *A. fumigatus* or *A. flavus*, *A. niger* is ubiquitous in the environment and can often represent colonization. In an immunocompromised host, it is critical to obtain tissue to exclude other pathogens and demonstrate invasive disease. Our patient's active role in constructing a new home likely exposed him to large fungal loads of this species, which rapidly proliferated during neutropenia. Thus, we

pursued lung biopsy for a definitive diagnosis despite a negative bronchoscopy. In this case, bronchoscopy and culture of the lung tissue were negative despite substantial fungal disease on pathology specimens.

Second, reduction of fungal burden is essential in the management of invasive mold infections and mandates strong consideration of surgical debulking. In this case, lung decortication and drainage of the subpleural abscesses were instrumental in disease containment. Lobectomy was thought to be impossible because of the extent of friable tissue, leading to the high risk of stump dehiscence.

Third, neutropenia presents a critical period in which progression of invasive aspergillosis is likely—even expected—despite optimal antifungal therapy. Following induction chemotherapy, significant radiographic progression was noted during liposomal amphotericin monotherapy. During 4 weeks of neutropenia that occurred during consolidation chemotherapy, there was only slight radiographic progression of the multiple pulmonary infiltrates with the liposomal amphotericin and voriconazole therapy. In this case, combination antifungal therapy substantially decreased the rate of progression and enabled disease containment during an extremely high risk period.

Several weeks later, caspofungin was added to the treatment regimen following massive hemoptysis because of concern about progressive angioinvasion. Nevertheless, given the patient's prior clinical improvement, it was not clear whether this hemoptysis represented angioinvasion or mechanical erosion of a vessel within abnormal tissues.

We have reported on the successful treatment of biopsy-proven, pan-lobar, angioinvasive aspergillo-

sis through prolonged neutropenia with surgical debulking and combination antifungal therapy with amphotericin, voriconazole, and caspofungin. Our patient tolerated all three drugs over the course of several months with minimal side effects, including macrocytosis, mild cholestasis, and moderate photosensitivity. The latter two have been reported to occur in over 1% of patients who have received voriconazole. He did not experience any visual disturbances such as enhanced brightness or blurry vision, which have been reported to occur in up to 44% of patients [9].

Although it is difficult to draw firm conclusions from an individual case, the high morbidity and mortality associated with mold infections in immunocompromised hosts emphasize the urgent need for more effective therapeutic strategies. Our observation that antifungal therapy with three distinct classes of agents was efficacious and safe in this patient suggests the role for combination therapy in high-risk situations. Although clinical trials are needed, we believe treatment of invasive mold infections in severely immunocompromised patients requires early combination therapy with antifungal agents, followed by prolonged maintenance therapy.

Infectious Diseases in Clinical Practice,
2002;11:355–358 0796/02/0
10.1097/01.idc.0000078754.71576.ce
Copyright © 2002 by Lippincott Williams &
Wilkins, Inc.

From the Brigham and Women's Hospital,
Division of Infectious Diseases (SSH, ITC, RMS,
LRB), and the Dana Farber Cancer Institute (ITC,
RMS), Boston, Massachusetts

Dr. Lindsey Baden receives research support from
Merck and Pfizer.

Address for correspondence: Susan S. Huang,
M.D., M.P.H., Brigham and Women's Hospital,
Division of Infectious Diseases, 15 Francis
Street, PBBA-4, Boston, MA 02115 (E-mail:
sshuang@partners.org).

-
1. Lee EJ, George SL, Caligiuri M, et al. Parallel phase I studies of daunorubicin given with cy-

- tarabine and etoposide with or without the multidrug resistance modulator PSC-833 in previously untreated patients 60 years of age or older with acute myeloid leukemia: results of cancer and leukemia group B study 9420. *J Clin Oncol.* 1999;17:2831–9.
2. Ernst EJ. Investigational antifungal agents. *Pharmacotherapy.* 2001;21(8S):165s–174s.
 3. Kontoyiannis DP, Lewis RE, Sagar N, et al. Itraconazole-amphotericin G antagonisms in *Aspergillus fumigatus*: an E-test based strategy. *Antimicrob Agents Chemother.* 2000;44:2915–2918.
 4. Schaffner A, Bohler A. Amphotericin B refractory aspergillosis after itraconazole: evidence for significant antagonism. *Mycoses.* 1993;36:421–424.
 5. Caillot D, Casasnovas O, Bernard A, et al. Improved management of invasive pulmonary aspergillosis in neutropenic patients using early thoracic computed tomographic scan and surgery. *J Clin Oncol.* 1997;15:139–147.
 6. Lewis RE, Kontoyiannis DP. Rationale for combination antifungal therapy. *Pharmacotherapy.* 2001;21(8s):149s–164s.
 7. Walsh TJ, Pappas P, Winston DJ, et al. Voriconazole compared to liposomal amphotericin B for empirical antifungal therapy in patients with neutropenia and persistent fever. *N Engl J Med.* 2002;346:225–234.
 8. Denning DW, Ribaud P, Milpied N, et al. Efficacy and safety of voriconazole in the treatment of acute invasive aspergillosis. *Clin Infect Dis.* 2002;34:563–571.
 9. Herbrecht R, Denning DW, Patterson TF, et al. Voriconazole versus amphotericin B for primary therapy of invasive aspergillosis. *N Engl J Med.* 2002;347:408–415.
 10. Hoang A. Caspofungin acetate: an antifungal agent. *Am J Health Syst Pharm.* 2001;58:1206–1214.
 11. Maertens J, Raad I, Sable CA, et al. Multicenter, noncomparative study to evaluate safety and efficacy of caspofungin (CAS) in adults with invasive aspergillosis (IA) refractory (R) or intolerant (I) to amphotericin B (AMB), AMB lipid formulations (lipid AMB), or azoles [abstract 1103]. In: *Program and Abstracts of the 40th Interscience Conference on Antimicrobial Agents and Chemotherapy.* Washington, DC: American Society for Microbiology, 2000.