

UC Davis

UC Davis Previously Published Works

Title

Direct site endovascular repair as salvage procedure after anastomotic breakdown of primary repair following trauma.

Permalink

<https://escholarship.org/uc/item/8tv7s1z6>

Journal

Journal of Vascular Surgery Cases and Innovative Techniques, 5(4)

ISSN

2468-4287

Authors

Madurska, Marta
Moran, Benjamin
Morrison, Jonathan
et al.

Publication Date

2019-12-01

DOI

10.1016/j.jvscit.2019.04.002

Peer reviewed

Direct site endovascular repair as salvage procedure after anastomotic breakdown of primary repair following trauma

Anders J. Davidson, MD, MAS,^{a,b} Marta J. Madurska, MD,^c Benjamin Moran, MD,^c Jonathan J. Morrison, MD,^c Joseph J. DuBose, MD,^c and Thomas M. Scalea, MD,^c *Sacramento and Travis Air Force Base, Calif, and Baltimore, Md*

ABSTRACT

A 16-year-old boy presented to a level I trauma center after multiple gun shot wounds and a motorcycle crash. He was in profound hemorrhagic shock and had multiple traumatic injuries, including a right common iliac arterial injury. The vessel was shunted for damage control and subsequently repaired primarily. On hospital day 18, he experienced dehiscence of the anastomosis requiring urgent surgery. The artery was ultimately repaired with an expandable polytetrafluoroethylene stent graft deployed in an open fashion through the site of injury. We discuss the use of stent grafts as an interesting alternative to suture repair after anastomotic disruption. (*J Vasc Surg Cases and Innovative Techniques* 2019;5:597-601.)

Keywords: Direct site endovascular repair; DSER; Stent graft; Vascular trauma

The management of vascular injury can be one of the most challenging aspects of trauma care, particularly in the multiply injured trauma patient with gross contamination of the injury bed. Damage control via temporary vascular shunts has emerged as a temporizing technique to rapidly restore inline flow and to provide time for resuscitation before definitive vascular repair. This time period is traditionally relatively short (<24 hours), and there is a subset of patients who may continue to be physiologically depleted and at high risk of a complication from traditional interposition or extra-anatomic bypass.^{1,2} We describe one case where an endovascular stent graft was deployed under open visualization in an

unstable patient as salvage therapy after breakdown of primary repair. We also discuss the use of stent grafts as an interesting alternative to suture repair after anastomotic disruption.

DESCRIPTION OF CASE

A 16-year-old boy was transported to a level I trauma center in profound hemorrhagic shock and cardiac arrest after multiple gunshot wounds. Upon arrival, an aortic occlusion balloon was placed (resuscitative endovascular balloon occlusion of the aorta), resulting in return of circulation and an organized cardiac rhythm. Focused assessment with sonography in trauma was grossly positive and the patient was taken to the operating room for an emergent laparotomy. Identified injuries included a right common iliac artery (CIA) injury, and multiple bowel injuries. The CIA was temporarily shunted (Argyle, Cardinal Health, Dublin, Ohio). Gross bowel contamination required multiple resections and a right lower extremity fasciotomy was performed. The patient was profoundly acidotic (pH, 6.81; base deficit, -26) and received 47 units of blood products. He returned to the operating room the next day for definitive repair of the CIA. The injury was located approximately 2.5 cm distal to the aortic bifurcation. The internal iliac artery was divided, which provided enough mobility to repair the CIA primarily in a tension-free fashion. The anastomosis was wrapped in peritoneum (Fig 1). He underwent multiple subsequent surgical procedures.

On hospital day 17, he was noted to be unresponsive and in cardiac arrest. He had a tense abdomen with a grossly positive focused assessment with sonography in trauma. A resuscitative endovascular balloon occlusion of the aorta was placed and he was noted to have an

From the Department of Surgery, UC Davis Medical Center, Sacramento^a; the Department of General Surgery, David Grant Medical Center, Travis Air Force Base^b; and the R Adams Cowley Shock Trauma Center, University of Maryland Medical Center, Baltimore.^c

Author conflict of interest: There was no funding from the National Institutes of Health (NIH), Wellcome Trust, or the Howard Hughes Medical Institute (HHMI) for this work. No conflicts of interest were declared by any of the authors. The Clinical Investigation Facility, David Grant USAF Medical Center, Travis Air Force Base, California provided funding for this study.

Disclaimer: The views expressed in this material are those of the authors, and do not reflect the official policy or position of the U.S. Government, the Department of Defense, the Department of the Air Force, the University of Maryland, or the University of California Davis.

Correspondence: Joseph J. DuBose, MD, Department of Surgery, R Adams Cowley Shock Trauma Center, 22 S Greene St, Baltimore, MD 21201 (e-mail: joseph.dubose@umm.edu).

The editors and reviewers of this article have no relevant financial relationships to disclose per the Journal policy that requires reviewers to decline review of any manuscript for which they may have a conflict of interest.

2468-4287

Published by Elsevier Inc. on behalf of Society for Vascular Surgery. This is an open access article under the CC BY-NC-ND license (<http://creativecommons.org/licenses/by-nc-nd/4.0/>).

<https://doi.org/10.1016/j.jvscit.2019.04.002>

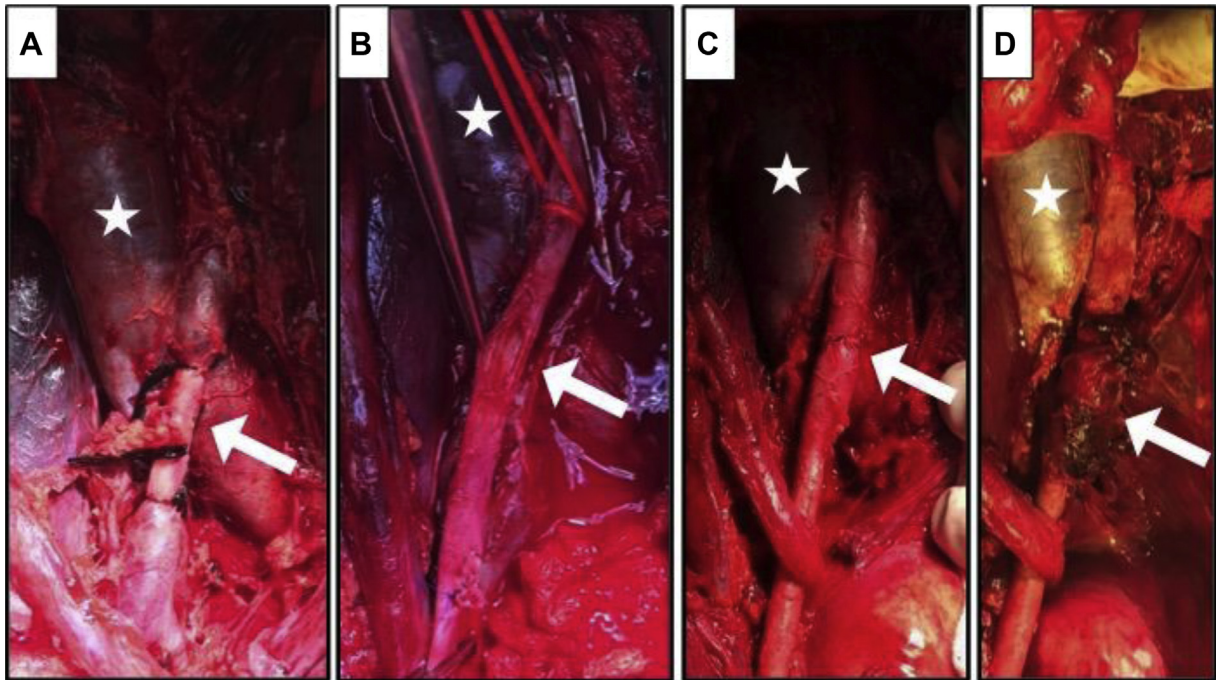


Fig 1. Right iliac artery at the time of the initial operation. **A**, Iliac artery with shunt in place. **B**, Iliac artery injury before repair. **C**, Iliac artery after initial primary repair. **D**, Final image of peritoneal patch overlying right iliac artery repair. *Star* marks the inferior vena cava. *Arrow* marks area of interest on right iliac artery.

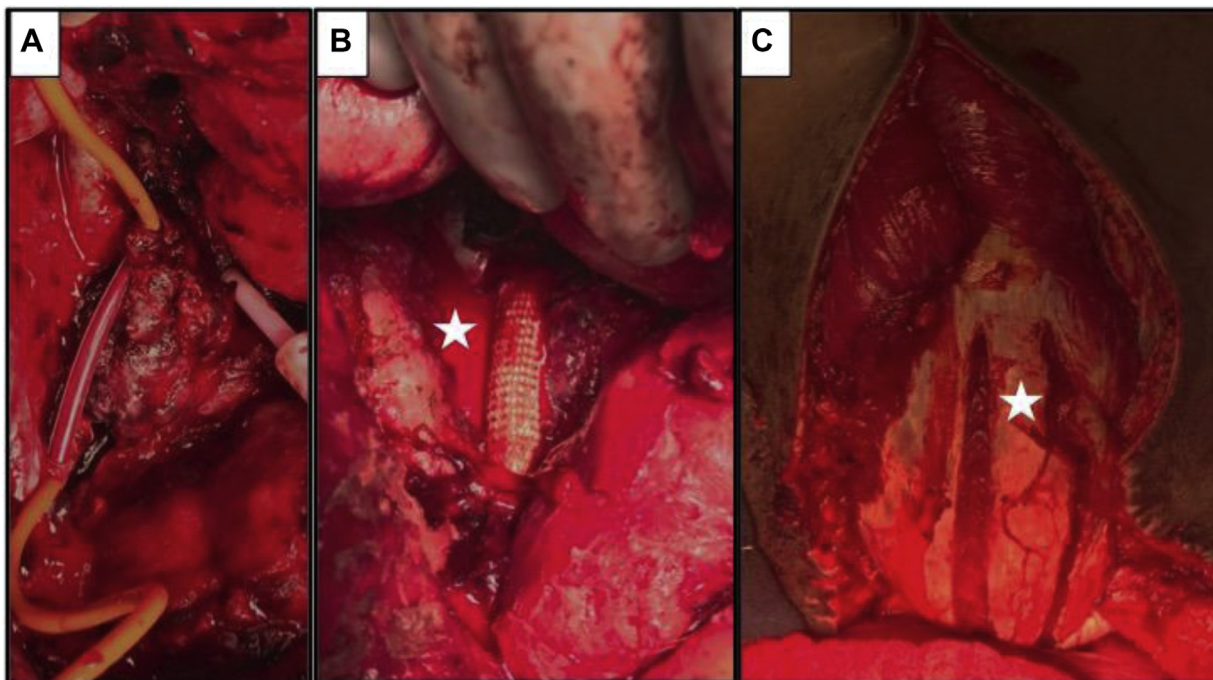


Fig 2. **A**, Temporary shunt in place before stent graft repair. **B**, Stent in place after direct site endovascular repair (DSER) repair. **C**, Rectus coverage of DSER repair.

anastomotic dehiscence of the CIA in the operating room. A temporary shunt was placed for damage control. After careful consideration of options after delayed failure of his primary anastomosis in the setting of bowel

contamination, he underwent repair of the CIA with an endovascular stent graft (Figs 2 and 3). An 11-mm \times 10-cm stent (Viabahn, W. L. Gore & Associates, Newark, Del) was deployed through a right groin 8F sheath under

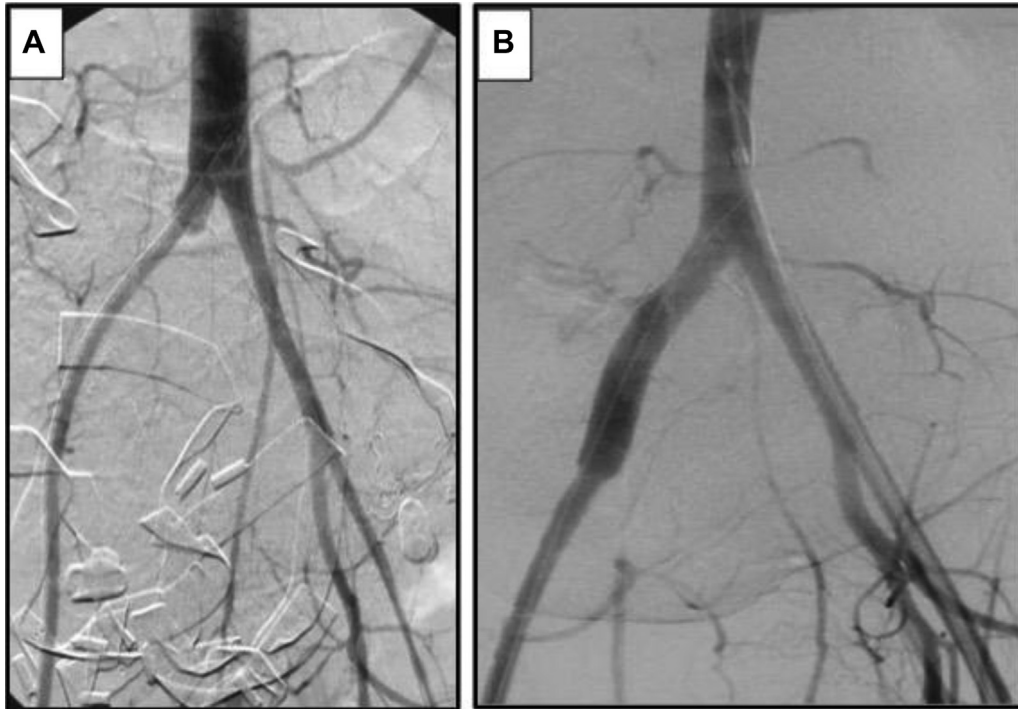


Fig 3. Angiography during second repair. **A,** Angiography through temporary shunt. **B,** Angiography through stent graft after direct site endovascular repair (DSER).

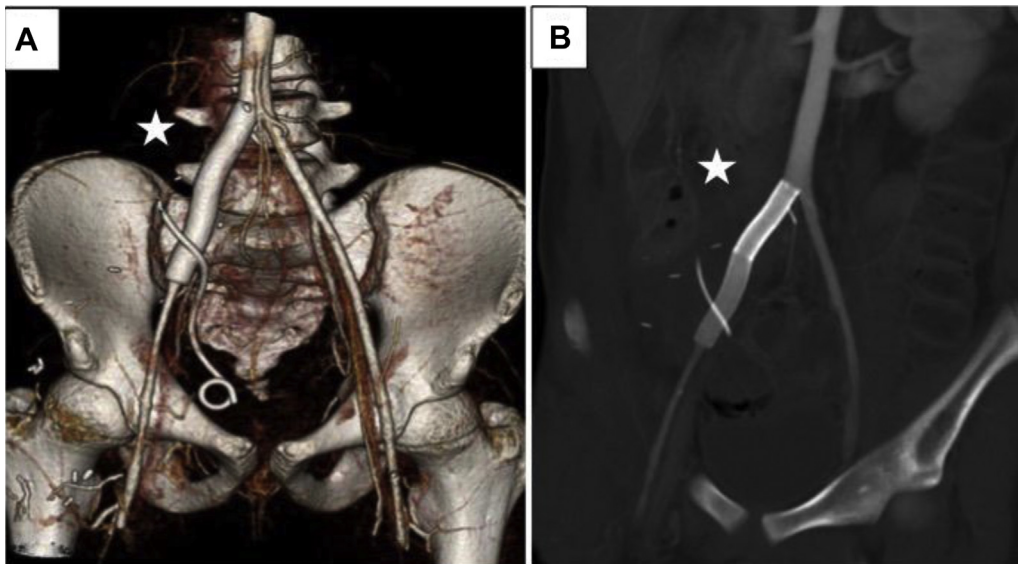


Fig 4. Computed tomography (CT) angiography 2.5 months after repair. **A,** Three-dimensional reconstruction demonstrating patent stent graft. **B,** CT angiography with patent stent graft. *Star* marks the stent graft.

direct vision after guiding a wire across the transection. Intraoperative cultures grew *Candida albicans* sensitive to fluconazole (Diflucan). He received 1 week of broad-spectrum antibiotics after anastomosis breakdown and 8 weeks of fluconazole. He improved and subsequently underwent a rectus femoris rotational flap to provide coverage of the stent graft. He was eventually

discharged from the hospital on day 57. During that time, he demonstrated no clinical or laboratory evidence of infection.

He was discharged on aspirin 81 mg/d. This was started as soon as he could take oral medication. There was no regional or therapeutic systemic anticoagulation ever used. He received follow up computed tomography

angiography 2.5 months after injury, which showed a patent stent (Fig 4). He was seen 8 months after injury with a normal vascular examination. The patient consented to the publication of this case.

DISCUSSION

This patient suffered a massive traumatic injury, including CIA disruption with associated hollow viscous injury. Temporary vascular shunting was used as a damage control adjunct with subsequent definitive repair within 24 hours using a tension-free primary anastomosis with peritoneal tissue coverage. Sixteen days later, he had anastomotic disruption causing massive hemorrhage and cardiovascular collapse. This case highlights several difficult clinical questions: What vascular repairs are available to a trauma surgeon in a contaminated field for the unstable patient? What options are available for salvage repair after anastomotic disruption of a suture repair in a contaminated field?

Regardless of the type of vascular repair performed or the conduits used, the required suture line represents a known risk for anastomotic failure.^{3,4} This risk is almost certainly higher with gastrointestinal contamination of the operative field. Impaired healing, postinjury immunosuppression, combined with contamination may result in anastomotic disruption as illustrated in the described case.⁵

Self-expanding stent grafts are commonly used for endovascular applications to exclude vascular pathology from normal arterial flow patterns. When used to exclude areas of pathology, these devices provide a durable exclusionary bridge between normal arterial segments across defects of various etiologies. To accomplish this bridge, the stent grafts rely on outward radial force over a landing zone of healthy vessel on either side of the spanned arterial segment. The successful use of stent graft arterial repair in trauma has been previously documented for pseudoaneurysms in locations that are normally difficult to access with conventional open approach.⁶⁻⁸ Similar open hybrid approaches have also been previously used in mesenteric arteries as surgical treatment of acute and chronic mesenteric ischemia.^{9,10}

There is potential for the use of expandable covered stent grafts as conduits in hybrid approaches as therapy for arterial repair after trauma. Combining initial open vessel control followed by endovascular stent graft repair introduces a viable sutureless repair option to the treating surgeon. Direct site endovascular repair (DSER) as described represents just such a sutureless repair option. These grafts are readily available with currently available lengths ranging from 2.5 to 25.0 cm and diameters of 5 to 13 mm; and can treat vessels ranging in diameter from 4.0 to 12 mm. Nonautologous interposition bypass options traditionally used for trauma have previously demonstrated their usefulness in contaminated settings

with acceptable performance.^{11,12} DSER represents a similar synthetic alternative, with the additional benefit that the use of this technique does not require the introduction of a high-risk suture line into the contaminated field. Moreover, DSER allows a timely restoration of blood flow in comparison with techniques that involve hand-sewn anastomoses.

DSER in this setting was initially considered a damage control adjunct.¹³ Vascular shunts are a well-established tool of damage control surgery in trauma, commonly used to rapidly restore perfusion across a damaged artery in severely depleted trauma patients who require further resuscitation before definitive repair.¹⁴ Although shunts provide an expeditious alternative for repair, the time required for definitive repair is relatively short compared with the time spent recovering from the initial traumatic injury.¹⁵ The use of DSER at damage control surgery may provide an interesting alternative to the traditional use of prosthetic shunts. Stent grafts can approximate native vessel diameter and provide more physiologic in-line flow when compared with temporary plastic shunts.¹⁶ Therefore, the use of DSER devices may represent a less thrombogenic option compared with plastic shunts, mitigating the risk for early thrombosis after use. The advantage is that DSER may be used as a prolonged shunt, which can be left in place days or weeks beyond that of a temporary shunt.¹³ This has the potential to allow for ongoing resuscitation, resolution of compartment syndrome, transfer to a higher level of care, and a definitive multidisciplinary approach to reconstruction to include orthopedic surgery, neurosurgery, and plastic surgery. DSER in this case was intended to give additional time for the individual's physiology to recover before definitive repair; beyond the capabilities of the traditional shunt. Used in this fashion, definitive vascular repair options, such as interposition bypass outside the infected field, could proceed under more optimal conditions, with fewer competing physiologic considerations, with appropriate graft material (ie, cryopreserved vessel ordered and available), and with available expertise.

In addition, DSER also has potential as a salvage technique after disruption of traditional definitive repair, as illustrated in the described case. Traditional dogma would suggest that reconstruction after disruption in a field with ongoing contamination should consist of cryopreserved allograft or arterial bypass around the area of issue with suture closure of the disrupted artery, still leaving an anastomosis or an arterial stump.¹⁷⁻¹⁹ This approach still leaves a suture line in an infected field with the potential for blowout.²⁰ It also requires the availability of a more experienced trauma or vascular surgeon with the technical skill and expertise to complete what amounts to a more complex repair.²¹ These complex repair options also divert the arterial stream unnaturally via more circuitous routes and are associated with lower

long-term patency than in-line interposition repairs.²² Repair immediately after arterial disruption would occur in a patient that is even more physiologically depleted and at higher risk for subsequent complications after complex arterial repair. The use of DSER as a salvage therapy in this setting was intended to restore inline flow quickly with something that could be left in longer than a shunt while monitoring the patient closely clinically. Our initial plan was to definitely repair the artery with one of the aforementioned options in a controlled setting, in a more stable patient, with a multidisciplinary team and availability of cryopreserved conduit if autograft was not available. However, because he never developed a graft infection, definitive therapy was not attempted (although these repair options remain available to this patient if he develops a problem with the graft in the future).

DSER represents a novel, suture-less repair option that can be used across a variety of challenging trauma situations. DSER has potential as salvage therapy after arterial suture line failure. In high contamination fields, it can function as a prolonged shunt as a bridge to definitive repair, and in low contamination injuries could be considered destination therapy under close clinical observation. Although additional research is needed, this approach provides surgeons with a potentially viable option to consider when challenged with similar difficult situations.

The authors thank the patient as well as all the numerous staff of Shock Trauma Hospital that provided excellent care to the patient described in this report. Their dedication and commitment to providing excellent care was instrumental in his recovery.

REFERENCES

1. Corriere MA, Guzman RJ. True and false aneurysms of the femoral artery. *Semin Vasc Surg* 2005;18:216-23.
2. Stoney RJ, Albo RJ, Wylie EJ. False aneurysms occurring after arterial grafting operations. *Am J Surg* 1965;110:153-61.
3. Mishwani AH, Ghaffar A, Janjua S. Combat related vascular trauma. *J Coll Physicians Surg Pak* 2012;22:213-7.
4. Branco B, DuBose J. Endovascular solutions for the management of penetrating trauma: an update on REBOA and axillo-subclavian injuries. *Eur J Trauma Emerg Surg* 2016;1-8.
5. Bilos L, Pirouzram A, Toivola A, Vidlund M, Cha SO, Hörer T. EndoVascular and Hybrid Trauma Management (EVTM) for blunt innominate artery injury with ongoing extravasation. *Cardiovasc Intervent Radiol* 2017;40:130-4.
6. Faulconer ER, Russo RM, Davidson AJ, Simon MA, DeSoucy ES, Loja MN, et al. Endovascular solutions for iliac and lower extremity junctional injuries. *J Endovasc Resusc Trauma Manage* 2017;1:22-7.
7. Blauw JT, Meerwaldt R, Brusse-Keizer M, Kolkman JJ, Gerrits D, Geelkerken RH. Retrograde open mesenteric stenting for acute mesenteric ischemia. *J Vasc Surg* 2014;60:726-34.
8. Oderich GS, Macedo R, Stone DH, Woo EY, Panneton JM, Resch T, et al. Multicenter study of retrograde open mesenteric artery stenting through laparotomy for treatment of acute and chronic mesenteric ischemia. *J Vasc Surg* 2018;68:470-80.e1.
9. Martin T, Mattox K, Feliciano D. Prosthetic grafts in vascular trauma: a controversy. *Compr Ther* 1985;11:41-5.
10. Vertrees A, Fox CJ, Quan RW, Cox MW, Adams ED, Gillespie DL. The use of prosthetic grafts in complex military vascular trauma: a limb salvage strategy for patients with severely limited autologous conduit. *J Trauma Acute Care Surg* 2009;66:980-3.
11. Davidson AJ, Neff LP, DuBose JJ, Sampson JB, Abbot CM, Williams TK. Direct-site endovascular repair (DSER): a novel approach to vascular trauma. *J Trauma Acute Care Surg* 2016;81(Suppl):S138-43.
12. Inaba K, Aksoy H, Seamon MJ, Marks JA, Duchesne J, Schroll R, et al. Multicenter evaluation of temporary intra-vascular shunt use in vascular trauma. *J Trauma Acute Care Surg* 2016;80:359-65.
13. Rasmussen TE, Clouse WD, Jenkins DH, Peck MA, Eliason JL, Smith DL. The use of temporary vascular shunts as a damage control adjunct in the management of wartime vascular injury. *J Trauma Acute Care Surg* 2006;61:8-15.
14. Oliver J, Gill H, Nicol A, Edu S, Navsaria PJ. Temporary vascular shunting in vascular trauma: a 10-year review from a civilian trauma centre. *S Afr J Surg* 2013;51:6-10.
15. Davidson AJ, Neff LP, Grayson JK, Clement NF, DeSoucy ES, Logan MAS, et al. Comparison of direct site endovascular repair utilizing expandable polytetrafluoroethylene stent grafts versus standard vascular shunts in a porcine (*Sus scrofa*) model. *J Trauma Acute Care Surg* 2017;83:457-63.
16. Mathew S, Smith BP, Cannon JW, Reilly PM, Schwab CW, Seamon MJ. Temporary arterial shunts in damage control: experience and outcomes. *J Trauma Acute Care Surg* 2017;82:512-7.
17. Diener H, Hellwinkler O, Carpenter S, Larena-Avellaneda A, Debus E. Homografts and extra-anatomical reconstructions for infected vascular grafts. *J Cardiovasc Surg* 2014;55(2 Suppl 1):217-23.
18. Wilson SE. New alternatives in management of the infected vascular prosthesis. *Surg Infect (Larchmt)* 2001;2:171-7.
19. Seeger JM, Pretus HA, Welborn MB, Ozaki CK, Flynn TC, Huber TS. Long-term outcome after treatment of aortic graft infection with staged extra-anatomic bypass grafting and aortic graft removal. *J Vasc Surg* 2000;32:451-61.
20. Chiesa R, Astore D, Frigerio S, Garriboli L, Piccolo G, Castellano R, et al. Vascular prosthetic graft infection: epidemiology, bacteriology, pathogenesis and treatment. *Acta Chir Belg* 2002;102:238-47.
21. Eckert M, Cuadrado D, Steele S, Brown T, Beekley A, Martin M. The changing face of the general surgeon: national and local trends in resident operative experience. *Am J Surg* 2010;199:652-6.
22. O'Donnell JT, Kelly JJ, Callow AD, Lahey SJ, Millan VA. A comparison of the early noninvasive hemodynamic results after aortofemoral or axillofemoral bypass graft. *Circulation* 1980;62:17-10.