

# UC Irvine

## UC Irvine Previously Published Works

### Title

The Value of Localizing Subclinical Seizures

### Permalink

<https://escholarship.org/uc/item/8vx586zx>

### Journal

Epilepsy Currents, 20(3)

### ISSN

1535-7597

### Author

King-Stephens, David

### Publication Date

2020-05-01

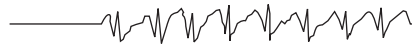### DOI

10.1177/1535759720917401

### Copyright Information

This work is made available under the terms of a Creative Commons Attribution License, available at <https://creativecommons.org/licenses/by/4.0/>

Peer reviewed



# The Value of Localizing Subclinical Seizures

Epilepsy Currents  
2020, Vol. 20(3) 147-148

© The Author(s) 2020

Article reuse guidelines:

sagepub.com/journals-permissions

DOI: 10.1177/1535759720917401

journals.sagepub.com/home/epi



## Localization Value of Subclinical Seizures on Scalp Video-EEG in Epilepsy Presurgical Evaluation

Wang Shan, Wang ZI, Tangy Y, et al. *Epilepsia*. 2019;60(1):2477-2485. doi:10.1111/epi.16383.

**Objective:** To evaluate the localization value and prognostic significance of subclinical seizures (SCSs) on scalp video electroencephalography monitoring (VEEG) in comparison to clinical seizures (CSs) in patients who had epilepsy surgery. **Methods:** We included 123 consecutive patients who had SCSs and CSs during scalp VEEG evaluation. All patients had subsequent epilepsy surgery and at least 1-year follow-up. Concordance between SCSs and CSs was summarized into 5 categories: complete, partial, overlapping, no concordance, or indeterminate. Using the same scheme, we analyzed the relationship between resection and SCS/CS localizations. The concordance measures, along with demographic, electroclinical, and other presurgical evaluation data, were evaluated for their associations with postoperative seizure outcome. **Results:** Sixty-nine (56.1%) patients had seizure-free outcome at 1-year follow-up. In 68 (55.3%) patients, the localizations of SCSs and CSs were completely concordant. Multivariate logistic analysis showed that complete SCS/CS concordance was independently associated with seizure-free outcome at 1 year ( $P = .020$ ) and 2-year follow-up ( $P = .040$ ). In the temporal lobe epilepsy (TLE) seizure-free group, SCS localization was completely contained within the resection in 44.4% and CS localization was completely contained within the resection in 41.7%; in the extratemporal lobe epilepsy (ETLE) seizure-free group, SCS localization was completely contained within the resection in 54.5% and CS localization was completely contained within the resection in 57.6%. **Significance:** Complete concordance between CS and SCS localization is a positive prognostic factor for 1-year and 2-year postoperative seizure-free outcome. Localization value of SCSs on scalp VEEG is similar to that of CSs for TLE and ETLE. Although SCSs cannot replace CSs, localization information from SCSs should not be ignored.

### Keywords

subclinical seizures, temporal lobe epilepsy, video/EEG, localization, surgical outcome

### Commentary

When assessing medically refractory epilepsy patients for possible surgical treatment or neuromodulation therapy, the aim of video/electroencephalography (EEG) monitoring is to capture clinical seizures (CSs) for the purpose of localization of the ictal focus (i). In some patients, electrographic or subclinical seizures (SCSs), defined as ictal activity without symptoms or clinical signs, are the only type of ictal activity that is captured during the average 1- to 2-week-long evaluation. Subclinical seizures seem to fall in the middle of the spectrum between interictal epileptiform discharges and CS in their accuracy for localizing the ictal focus (i)<sup>1</sup> and on their impact on cognitive function.<sup>2,3</sup> Using intracranial EEG in a group of patients with temporal lobe epilepsy (TLE), Babb et al<sup>4</sup> reported that the number of neurons firing at the start of a seizure correlates with the clinical symptoms, and because SCS do not activate

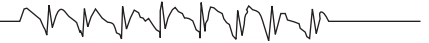a sufficient pool of neurons, they do not produce clinical or behavioral symptoms.

The prevalence of SCS is unknown. In a retrospective study of 327 pediatric and adult patients with TLE who were studied with scalp video/EEG, 8.3% demonstrated SCS, with most of these patients also demonstrating CS.<sup>5</sup> In contrast, studies using intracranial video/EEG report a higher incidence. In a study of 40 TLE patients, 57% had SCS and 25% had auras, with SCS arising from medial temporal structures and rarely spreading to the neocortex.<sup>6</sup> In a study of 111 patients mainly with TLE, 64% had SCS and only 2 patients had SCS captured without CS.<sup>7</sup>

Do SCS always arise from the same area as CS? At least for TLE, auras and SCS usually have identical EEG signatures and the same origin as complex partial seizures. Additionally, these usually remain restricted to the area in which they started and



Creative Commons Non Commercial No Derivs CC BY-NC-ND: This article is distributed under the terms of the Creative Commons Attribution-NonCommercial-NoDerivs 4.0 License (<https://creativecommons.org/licenses/by-nc-nd/4.0/>) which permits non-commercial use, reproduction and distribution of the work as published without adaptation or alteration, without further permission provided the original work is attributed as specified on the SAGE and Open Access pages (<https://us.sagepub.com/en-us/nam/open-access-at-sage>).



infrequently spread to other areas within or outside of the temporal lobe.<sup>6,7</sup> Assuming that this premise is correct, is it worthwhile to pursue a surgical treatment if SCS are the only ictal electrographic abnormality that is obtained during a presurgical evaluation? Similarly, is surgical outcome influenced by the co-localization of SCS and CS?

Review of the literature suggests that the answer to these 2 questions is a temperate yes. Data from retrospective studies using intracranial EEG in small groups of patients with single<sup>8</sup> or multiple foci<sup>7</sup> report a good surgical outcome when the area that is resected shows concordance between ES and CS. In the latter study,<sup>7</sup> 77.5% of patients who had concordance of SCS and CS and underwent resection became seizure-free at 1 year compared to 37.5% of patients with incomplete or no co-localization. Interestingly, 1 patient who had resection of the temporal lobe where over 1000 SCS began, compared to the contralateral lobe where only 1 CS was captured, achieved seizure freedom.


In a recent study by Wang et al,<sup>9</sup> data are presented on a group of 123 patients with mixed pathologies and epilepsy syndromes who had both SCS and CS captured with scalp video/EEG monitoring, underwent epilepsy surgery and had at least 1 year of follow-up. The lobar concordance between SCS and CS localization was classified into 5 categories, ranging from complete concordance when localizations were identical, to indeterminate when the ictal activity was non-localizable or generalized. Additionally, the relationship between resection site, at a lobar level, and localization of ictal activity was evaluated and classified.

Complete concordance between SCS and CS was present in 56.5% of TLE and 54.1% of extra-temporal lobe epilepsy (ETLE) patients. In terms of surgical outcome, the rate of complete concordance localizations was significantly higher in those seizure-free at 1 and 2 year post resection than in the non-seizure-free group, for both TLE and ETLE patients (65.2% vs 42.6%,  $P = .012$ ). Univariate analysis showed that the presence of a tumor and complete concordance between SCS and CS was significantly more frequent in patients with seizure-free outcomes. In terms of the localization value, there was no difference in the surgical outcome between the complete resection rates of SCS and CS.


The authors conclude that SCS have a clear clinical diagnostic value for both TLE and ETLE groups and that SCS and CS likely emanate from the same epileptogenic networks. They suggest that both should be used in conjunction for localization of the epileptogenic zone. Major contributions of the study are the large number of patients studied and the use of surgical outcome in all patients to validate the localizing value of SCS. Limitations of the study include the retrospective design and the lack of intracranial EEG data to validate the limited spatial resolution of surface EEG recordings. Additionally, it would

have been interesting to analyze the pattern of seizure evolution and presence or absence of propagation for their potential implications for surgical outcome.

The Wang et al study<sup>9</sup> provides important contributions to our understanding of the significance of SCS. Nevertheless, several important questions remain unanswered. For example, is the presence of SCS an independent predictor of surgical outcome? Do these results apply to patients who only have SCS captured during the presurgical evaluation and then undergo surgical treatment? Is there a difference in the significance of SCS that occur during sleep vs wakefulness? Additional work, including data obtained from chronic ambulatory intracranial EEG studies, is welcomed.

By David King-Stephens 

## ORCID iD

David King-Stephens  <https://orcid.org/0000-0003-0555-673X>

## References

1. Karoly PJ, Freestone D, Boston D, et al. Interictal spikes and epileptic seizures: their relationship and underlying rhythmicity. *Brain*. 2016;139(1):1066-1078.
2. Kleen JK, Scott RC, Holmes GL, Roberts DW, et al. Hippocampal interictal epileptiform activity disrupts cognition in humans. *Neurology*. 2013;81(2):18-24.
3. Bridgman PA, Malamut MA, Sperling MR, Sayking AJ, O'Connor MJ. Memory during subclinical hippocampal seizures. *Neurology*. 1989;39(2):853-856.
4. Babb TL, Wilson CL, Isokawa-Akesson M. Firing patterns of human limbic neurons during stereo-encephalography (SEEG) and clinical temporal lobe seizures. *Electroenceph Clin Neurophysiol*. 1987;66(2):467-482.
5. Wang S, Jin B, Yang L, Chenc C, et al. Clinical value and predictors of subclinical seizures in patients with temporal lobe epilepsy (TLE) undergoing scalp video-EEG monitoring. *J Clin Neurosci*. 2017;44(4):214-217.
6. Sperling MR, O'Connor MJ. Auras and subclinical seizures: characteristics and prognostic significance. *Ann Neurol*. 1990;28(1):320-328.
7. Zangaladaze A, Nei M, Liporace JD, Sperling MR. Characteristics and clinical significance of subclinical seizures. *Epilepsia*. 2008;49(5):2016-2021.
8. Farooque P, Duckrow R. Subclinical seizures during intracranial EEG recording: are they clinically significant? *Epilepsy Res*. 2014;108:1790-1796.
9. Wang S, Wang ZI, Tangy Y, et al. Localization value of subclinical seizures on scalp video-EEG in epilepsy presurgical evaluation. *Epilepsia*. 2019;60(1):2477-2485.