

UC Irvine

UC Irvine Previously Published Works

Title

Cardiophrenic lymph node metastasis in low-grade serous ovarian adenocarcinoma

Permalink

<https://escholarship.org/uc/item/8w33w44g>

Authors

Serna-Gallegos, Tasha

Gallegos, Nicolas

Bristow, Robert E


Publication Date

2017-02-01

DOI

10.1016/j.gore.2016.12.001

Peer reviewed



Case report

Cardiophrenic lymph node metastasis in low-grade serous ovarian adenocarcinoma



Tasha Serna-Gallegos^{a,*}, Nicolas Gallegos^b, Robert E. Bristow^a

^a Division of Gynecologic Oncology, Department of Obstetrics and Gynecology, University of California, Irvine-Medical Center, Orange, CA, USA

^b Department of Pathology, University of California, Irvine-Medical Center, Orange, CA, USA

ARTICLE INFO

Available online 14 December 2016

1. Introduction

The American Cancer Society has estimated 22,280 new cases of ovarian cancer and 14,240 deaths in 2016 (Siegel et al., 2016). Amongst the types of ovarian cancer, epithelial ovarian carcinoma represents greater than 90% of cases. The two-tier grading system of ovarian carcinoma by Malpica et al. has helped stratify two different subsets of disease (Malpica et al., 2004). Greater than eighty-percent of serous adenocarcinomas of the ovary are high-grade lesions with numerous mitotic figures and high-grade nuclei. Low-grade histology constitutes the remaining cases and is typically diagnosed at earlier stages. They exhibit fewer mitotic figures and low-grade nuclei histologically. Furthermore, they have an indolent disease course with a series of stepwise mutations from borderline tumors with low malignant potential progressing to a well-differentiated carcinoma (Vang et al., 2009). Surgical intervention is key given high rates of chemotherapy resistance. High-grade serous carcinomas, on the other hand, are genetically unstable leading to rapid progression and diagnosis at advanced stages. They are more responsive to platinum and taxane based chemotherapy.

Modalities of serous ovarian cancer metastases are direct tumor invasion into the peritoneal cavity followed by lymphatic and hematogenous spread. Malignant pleural effusions and intraparenchymal liver metastases are the most common sites that upstage the disease (Bonnefoi et al., 1999). Cardiophrenic lymph node (CPLN) metastases also upstage the disease to IV-B. This type of metastasis has only been reported in high-grade serous carcinoma. Mayadagli et al. references six total case reports describing mediastinal metastases from high-grade carcinoma (Mayadagli et al., 2012). There are currently no case reports that document CPLN metastases in low-grade serous carcinomas or borderline tumors.

When noted on computed tomography (CT) imaging, surgical planning can accommodate resection of cardiophrenic lymph nodes by

either gynecologic oncology or cardiothoracic surgery to help achieve complete cytoreduction. Currently, an abdominal CT and a chest x-ray are used to assess for thoracic and pleural metastases. A study done by Hynninen et al. found that preoperative ¹⁸F-fluorodeoxyglucose (FDG) positron emission tomography/computed tomography (PET/CT) diagnosed CPLN metastases in 67% of advanced stage epithelial ovarian cancer patients ($n = 30$), which was significantly higher than conventional imaging (33%) (Hynninen et al., 2012).

Whether resection of these cardiophrenic lymph nodes truly results in no residual disease is patient dependent. A study done in 2007 found that 65% of patients with advanced staged ovarian cancer and moderate to large pleural effusions had macroscopic intrathoracic lesions. They went on to propose using video-assessed thoracic surgery (VATS) prior to primary cytoreductive surgery to help stratify patients to neo-adjuvant chemotherapy versus a complete cytoreductive operation (Juretzka et al., 2007). This raises the importance of appropriate patient selection for cardiophrenic lymph node resection to ensure the benefits outweigh the risks.

The purpose of this report is to describe, to our knowledge, the first two cases of low-grade serous ovarian carcinoma with cardiophrenic lymph node metastasis. Furthermore, by presenting these cases, we strive to improve awareness of this rare disease pattern and optimize surgical cytoreduction in this chemotherapeutic resistant population.

1.1. Case 1

A 42 year-old woman presented to her gynecologist with a history of pelvic pressure, bloating, constipation, notable left lower quadrant mass and abnormal uterine bleeding. She had an unremarkable medical history. Transvaginal ultrasound (TVUS) revealed a uterus measuring $10.8 \times 6.8 \times 5.3$ cm with a complex right ovarian mass measuring $11.1 \times 7.4 \times 6.2$ cm. A cancer antigen 125 (CA-125) was 1070 U/ml. Computed tomographic (CT) imaging showed a complex cystic right adnexal mass measuring $10.9 \times 8.6 \times 8.5$ cm, a complex left ovary measuring $4.7 \times 4.2 \times 3.6$ cm, a solid appearing mass in the anterior pelvis measuring $5.4 \times 6.6 \times 7.5$ cm, trace ascites, and multiple calcified omental nodules. She underwent a robotically assisted-total laparoscopic hysterectomy, bilateral salpingo-oophorectomy, omentectomy, appendectomy, and peritoneal biopsies and washings at an outside hospital in August of 2014. There were small peritoneal implants scattered throughout the pelvis and diaphragm. Intra-operative frozen section

* Corresponding author at: 101 The City Drive Building 56, Orange, CA 92868, USA.
E-mail address: sermagat@uci.edu (T. Serna-Gallegos).

revealed a mucinous borderline tumor with no area of invasive disease however final pathology showed a mixed mucinous and Grade I serous papillary ovarian adenocarcinoma with involvement of the omentum, anterior pelvic peritoneum, right pelvic sidewall, and right posterior cul-de-sac. There was no lymphovascular space involvement and lymph nodes were not sampled.

Two months after her primary surgery, the patient complained of diffuse upper abdominal discomfort. Repeat CT imaging of her chest, abdomen, and pelvis showed shotty retroperitoneal lymphadenopathy and enlarged right cardiophrenic angle lymph nodes measuring up to 7 mm. She underwent a second cytoreductive surgery with complete debulking for Stage IIIC low-grade serous and mucinous ovarian carcinoma. This included a right diaphragm peritonectomy with resection of 100% of the right diaphragmatic surface area and full-thickness resection of the right diaphragm muscle (2×1 cm) with transdiaphragmatic resection of clinically enlarged four right cardiophrenic lymph nodes. She also had hyperthermic intraperitoneal chemotherapy with carboplatin at a dose of 800 mg/m^2 at 41 to 42°C for 60 min. Her final pathology was consistent with Stage IV-B low grade mixed mucinous and papillary serous histology with 4/4 positive cardiophrenic lymph nodes.

She underwent six cycles of intravenous carboplatin, paclitaxel, and bevacizumab with normalization of her CA-125. She continues on maintenance bevacizumab without evidence of recurrent disease radiologically or serologically 27 months after initial diagnosis.

1.2. Case 2

A 53 year-old woman presented to the Emergency Department with worsening abdominal pain for 6 months associated with nausea and vomiting. Her past history was remarkable for endometriosis and possible right ovarian oophorectomy. CA-125 at that time was 1093. CT imaging of her abdomen/pelvis revealed a large $12.7 \times 13 \times 13.3$ cm large lobulated heterogeneous partially calcified pelvic mass encasing the uterus and causing moderate right hydronephrosis, scattered omental, mesenteric, and serosal nodular implants with calcifications suspicious for diffuse carcinomatosis. A chest CT showed a 7.4 mm cardiophrenic lymph node possibly reactive in nature versus metastasis (Fig. 1). In April of 2016, she underwent an exploratory laparotomy, type 2 radical oophorectomy, right pelvic and paraaortic lymphadenectomy, total omentectomy, en block distal ileectomy, appendectomy, and resection of cecum and subtotal right colectomy, Morison's pouch peritonectomy, right diaphragm peritonectomy (100% surface area), transdiaphragmatic resection of right cardiophrenic lymph node with primary closure and transdiaphragmatic evacuation of pneumothorax, nonanatomic wedge resection of the liver segment 6 with associated tumor, resection of round ligament of liver and falciform

ligament, resection of anterior abdominal wall tumor and umbilectomy (5×2.5 cm segment of the anterior abdominal wall fascia and associated soft tissue), takedown of splenic flexure, stapled 33 mm circular end-to-end descending colon to rectum anastomosis, and stapled functional end-to-end ileo to ascending colon anastomosis (enterocolostomy)

Her post-operative course was complicated by a small pulmonary embolism, for which she was treated with Lovenox. Her final pathology was consistent with Stage IV-B low-grade serous adenocarcinoma of the ovary (Fig. 2). She completed six cycles of intravenous carboplatin and paclitaxel and is without evidence of disease 6 months after diagnosis.

2. Discussion

These two rare cases represent a small subset of the ovarian cancer population. They show low-grade serous histology with Stage IV-B disease by cardiophrenic lymph node metastasis. From a diagnostic standpoint, being able to recognize this pattern of spread where chemotherapeutic resistance is high, can dictate a more targeted surgical strategy. Identifying these cardiophrenic lymph node metastases gives the surgeon a much higher probability of performing a complete tumor debulking.

In 2004, Chi et al. found that incorporating these invasive upper abdominal and lower mediastinal procedures substantially increases the rate of successful cytoreduction (Chi et al., 2004). Their follow up study in 2010 showed that of the common postoperative complications seen (pleural effusion, pancreatic leak, intra-abdominal fluid collection), two-thirds of them were managed with percutaneous drainage of fluid collections. Overall, there was a 22% rate of major morbidity and 1.4% rate of mortality that seems acceptable (Chi et al., 2010). There is a paucity of data evaluating the prognostic impact of cardiophrenic lymph node metastasis in epithelial ovarian cancer.

Genetic and molecular profiling can also be a helpful tool in finding optimal chemotherapeutic agents in low-grade disease, as some evidence suggests a higher likelihood of resistance to standard platinum-taxane based therapy. Evidence suggests high resistance to platinum and taxane based chemotherapeutic agents though they do remain first line with close surveillance. In the setting of persistent disease, clinical trials are recommended. Given higher estrogen and progesterone receptor expression in low-grade disease, hormonal therapy is a reasonable option. Whether thoracic surgery influences the chemotherapeutic regimen is unknown.

In conclusion, cardiophrenic lymph node metastasis, defining Stage IV-B ovarian cancer, is extremely rare in low-grade serous ovarian carcinoma. We have presented two cases that bring to light the importance of pre-operative imaging and astute physician awareness to this unique disease pattern. Given high chemotherapy resistance, surgical cytoreduction for patients with low-grade serous carcinoma will remain

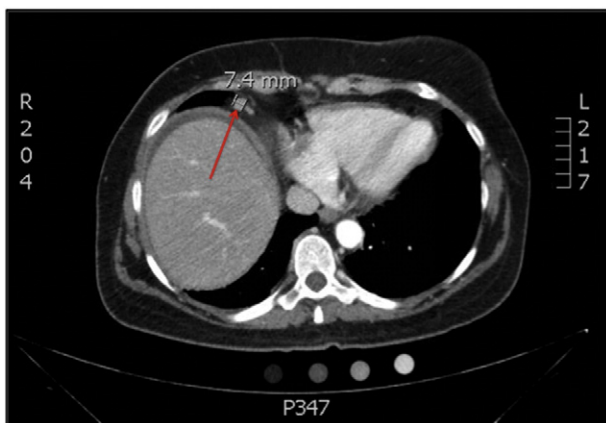

Fig. 1. Computed tomography imaging of the chest from Case #2 illustrating an enlarged 7.4-millimeter cardiophrenic lymph node indicative of metastatic disease.

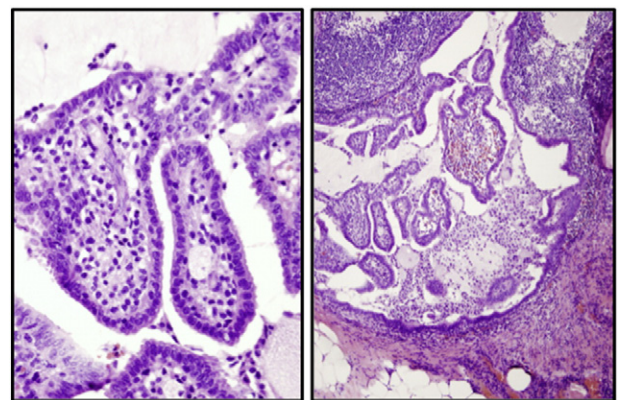


Fig. 2. Sections from the lymph node show a subcapsular cluster of papillae lined by relatively bland serous cells with monotonous nuclei and infrequent mitoses, morphologically identical to the tumor seen in the pelvis.

the mainstay of treatment. By improving awareness of this topic, gynecologic oncologists are better equipped to provide superior care to their ovarian cancer population.

Conflict of interest statement

The authors whose names are listed on this manuscript have NO affiliations with or involvement in any organization or entity with any financial interest (such as honoraria; educational grants; participation in speakers' bureaus; membership, employment, consultancies, stock ownership, or other equity interest; and expert testimony or patent-licensing arrangements), or non-financial interest (such as personal or professional relationships, affiliations, knowledge or beliefs) in the subject matter or materials discussed in this manuscript.

References

- Bonnefoi, H., A'Hern, R.P., Fisher, C., Macfarlane, V., Barton, D., Blake, P., et al., 1999. Natural history of stage IV epithelial ovarian cancer. *J. Clin. Oncol. Off. J. Am. Soc. Clin. Oncol.* 17 (3), 767–775.
- Chi, D.S., Franklin, C.C., Levine, D.A., Akselrod, F., Sabbatini, P., Jarnagin, W.R., et al., 2004. Improved optimal cytoreduction rates for stages IIIC and IV epithelial ovarian, fallopian tube, and primary peritoneal cancer: a change in surgical approach. *Gynecol. Oncol.* 94 (3), 650–654.
- Chi, D.S., Zivanovic, O., Levinson, K.L., Kolev, V., Huh, J., Dottino, J., et al., 2010. The incidence of major complications after the performance of extensive upper abdominal surgical procedures during primary cytoreduction of advanced ovarian, tubal, and peritoneal carcinomas. *Gynecol. Oncol.* 119 (1), 38–42.
- Hynninen, J., Auranen, A., Carpen, O., Dean, K., Seppanen, M., Kemppainen, J., et al., 2012. FDG PET/CT in staging of advanced epithelial ovarian cancer: frequency of supradiaphragmatic lymph node metastasis challenges the traditional pattern of disease spread. *Gynecol. Oncol.* 126 (1), 64–68.
- Juretzka, M.M., Abu-Rustum, N.R., Sonoda, Y., Downey, R.J., Flores, R.M., Park, B.J., et al., 2007. The impact of video-assisted thoracic surgery (VATS) in patients with suspected advanced ovarian malignancies and pleural effusions. *Gynecol. Oncol.* 104 (3), 670–674.
- Malpica, A., Deavers, M.T., Lu, K., Bodurka, D.C., Atkinson, E.N., Gershenson, D.M., et al., 2004. Grading ovarian serous carcinoma using a two-tier system. *Am. J. Surg. Pathol.* 28 (4), 496–504.
- Mayadagli, A., Ekici, K., Akcicek, M., Korkmaz, T., Eser, M., Kayipmaz, S.S., 2012. Metastasis to mediastinal lymph nodes from ovarian cancer: a case report. *Case Study Case Rep.* 2 (4), 129–136.
- Siegel, R.L., Miller, K.D., Jemal, A., 2016. Cancer statistics, 2016. *CA Cancer J. Clin.* 66 (1), 7–30.
- Vang, R., Shih Ie, M., Kurman, R.J., 2009. Ovarian low-grade and high-grade serous carcinoma: pathogenesis, clinicopathologic and molecular biologic features, and diagnostic problems. *Adv. Anat. Pathol.* 16 (5), 267–282.