

# UC Irvine

## UC Irvine Previously Published Works

### Title

Limbic-predominant age-related TDP-43 encephalopathy (LATE): consensus working group report

### Permalink

<https://escholarship.org/uc/item/8w45j4v0>

### Journal

Brain, 142(6)

### ISSN

0006-8950

### Authors

Nelson, Peter T  
Dickson, Dennis W  
Trojanowski, John Q  
et al.

### Publication Date



2019-06-01

### DOI

10.1093/brain/awz099

Peer reviewed

**REVIEW****Limbic-predominant age-related TDP-43 encephalopathy (LATE): consensus working group report**

Peter T. Nelson,<sup>1</sup>  Dennis W. Dickson,<sup>2</sup> John Q. Trojanowski,<sup>3</sup> Clifford R. Jack Jr.,<sup>4</sup> Patricia A. Boyle,<sup>5</sup> Konstantinos Arfanakis,<sup>5,6</sup> Rosa Rademakers,<sup>2</sup> Irina Alafuzoff,<sup>7</sup> Johannes Attems,<sup>8</sup> Carol Brayne,<sup>9</sup> Ian T.S. Coyle-Gilchrist,<sup>9</sup> Helena C. Chui,<sup>10</sup> David W. Fardo,<sup>1</sup> Margaret E. Flanagan,<sup>11</sup> Glenda Halliday,<sup>12</sup> Suvi R.K. Hokkanen,<sup>9</sup> Sally Hunter,<sup>9</sup> Gregory A. Jicha,<sup>1</sup> Yuriko Katsumata,<sup>1</sup> Claudia H. Kawas,<sup>13</sup> C. Dirk Keene,<sup>14</sup> Gabor G. Kovacs,<sup>15</sup> Walter A. Kukull,<sup>14</sup> Allan I. Levey,<sup>16</sup> Nazanin Makkinejad,<sup>6</sup> Thomas J. Montine,<sup>17</sup> Shigeo Murayama,<sup>18</sup> Melissa E. Murray,<sup>2</sup> Sukriti Nag,<sup>5</sup> Robert A. Rissman,<sup>19</sup>  William W. Seeley,<sup>20</sup> Reisa A. Sperling,<sup>21</sup> Charles L. White III,<sup>22</sup> Lei Yu<sup>5</sup> and Julie A. Schneider<sup>5</sup>

We describe a recently recognized disease entity, limbic-predominant age-related TDP-43 encephalopathy (LATE). LATE neuropathological change (LATE-NC) is defined by a stereotypical TDP-43 proteinopathy in older adults, with or without coexisting hippocampal sclerosis pathology. LATE-NC is a common TDP-43 proteinopathy, associated with an amnesic dementia syndrome that mimicked Alzheimer's-type dementia in retrospective autopsy studies. LATE is distinguished from frontotemporal lobar degeneration with TDP-43 pathology based on its epidemiology (LATE generally affects older subjects), and relatively restricted neuroanatomical distribution of TDP-43 proteinopathy. In community-based autopsy cohorts, ~25% of brains had sufficient burden of LATE-NC to be associated with discernible cognitive impairment. Many subjects with LATE-NC have comorbid brain pathologies, often including amyloid- $\beta$  plaques and tauopathy. Given that the 'oldest-old' are at greatest risk for LATE-NC, and subjects of advanced age constitute a rapidly growing demographic group in many countries, LATE has an expanding but under-recognized impact on public health. For these reasons, a working group was convened to develop diagnostic criteria for LATE, aiming both to stimulate research and to promote awareness of this pathway to dementia. We report consensus-based recommendations including guidelines for diagnosis and staging of LATE-NC. For routine autopsy workup of LATE-NC, an anatomically-based preliminary staging scheme is proposed with TDP-43 immunohistochemistry on tissue from three brain areas, reflecting a hierarchical pattern of brain involvement: amygdala, hippocampus, and middle frontal gyrus. LATE-NC appears to affect the medial temporal lobe structures preferentially, but other areas also are impacted. Neuroimaging studies demonstrated that subjects with LATE-NC also had atrophy in the medial temporal lobes, frontal cortex, and other brain regions. Genetic studies have thus far indicated five genes with risk alleles for LATE-NC: *GRN*, *TMEM106B*, *ABCC9*, *KCNMB2*, and *APOE*. The discovery of these genetic risk variants indicate that LATE shares pathogenetic mechanisms with both frontotemporal lobar degeneration and Alzheimer's disease, but also suggests disease-specific underlying mechanisms. Large gaps remain in our understanding of LATE. For advances in prevention, diagnosis, and treatment, there is an urgent need for research focused on LATE, including *in vitro* and animal models. An obstacle to clinical progress is lack of diagnostic tools, such as biofluid or neuroimaging biomarkers, for ante-mortem detection of LATE. Development of a disease biomarker would augment observational studies seeking to further define the risk factors, natural history, and clinical features of LATE, as well as eventual subject recruitment for targeted therapies in clinical trials.

Received January 7, 2019. Revised February 10, 2019. Accepted February 25, 2019. Advance Access publication April 30, 2019

© The Author(s) (2019). Published by Oxford University Press on behalf of the Guarantors of Brain.

This is an Open Access article distributed under the terms of the Creative Commons Attribution Non-Commercial License (<http://creativecommons.org/licenses/by-nc/4.0/>), which permits non-commercial re-use, distribution, and reproduction in any medium, provided the original work is properly cited. For commercial re-use, please contact [journals.permissions@oup.com](mailto:journals.permissions@oup.com)

- 1 University of Kentucky, Lexington, KY, USA
- 2 Mayo Clinic, Jacksonville, FL, USA
- 3 University of Pennsylvania, Philadelphia, PA, USA
- 4 Mayo Clinic, Rochester, MN, USA
- 5 Rush University Medical Center, Chicago, IL, USA
- 6 Illinois Institute of Technology, Chicago, IL, USA
- 7 Uppsala University, Uppsala, Sweden
- 8 Newcastle University, Newcastle upon Tyne, UK
- 9 University of Cambridge, Cambridge, UK
- 10 University of Southern California, Los Angeles, CA, USA
- 11 University of Minnesota, Minneapolis, MN, USA
- 12 The University of Sydney Brain and Mind Centre and Central Clinical School Faculty of Medicine and Health, Sydney, Australia
- 13 University of California, Irvine, CA, USA
- 14 University of Washington, Seattle, WA, USA
- 15 Institute of Neurology Medical University of Vienna, Vienna, Austria
- 16 Emory University, Atlanta, GA, USA
- 17 Stanford University, Stanford, CA, USA
- 18 Tokyo Metropolitan Geriatric Hospital and Institute of Gerontology, Tokyo, Japan
- 19 University of California, San Diego, CA, USA
- 20 University of California, San Francisco, CA, USA
- 21 Harvard University, Cambridge, MA, USA
- 22 University of Texas Southwestern Medical Center, Dallas, TX, USA

Correspondence to: Peter T. Nelson

311 Sanders-Brown Center on Aging, University of Kentucky, Lexington, KY, 40536, USA

E-mail: peter.nelson@uky.edu

**Keywords:** PET; MRI; FTLN; epidemiology; SNAP

**Abbreviations:** ADNC = Alzheimer's disease neuropathological changes; ALS = amyotrophic lateral sclerosis; FTD = frontotemporal dementia (clinical syndrome); FTLN-TDP = frontotemporal lobar degeneration with TDP-43 proteinopathy; GWAS = genome wide association study; LATE-NC = limbic-predominant age-related TDP-43 encephalopathy neuropathological changes; PPA = primary progressive aphasia; SNAP = suspected non-Alzheimer (non-amyloid- $\beta$ ) pathophysiology (by biomarkers)

## Introduction

Transactive response DNA binding protein of 43 kDa (TDP-43) proteinopathy in limbic brain structures is commonly observed in subjects past 80 years of age. This proteinopathy has been associated with substantial cognitive impairment that mimicked Alzheimer's disease clinical syndrome in retrospective studies. Despite evidence from many sources attesting to the public health impact of age-related TDP-43 proteinopathy, there is as yet no consensus-based nomenclature. To address this problem, we propose new terminology: limbic-predominant age-related TDP-43 encephalopathy (LATE). Guidelines are suggested for the autopsy evaluation and staging of LATE neuropathological change (LATE-NC). We review the medical literature pertaining to LATE, including cognitive manifestations, neuroimaging, public health impact, and genetics. The importance of LATE as a contributing factor in neurodegeneration is stressed, as are the needs for specific LATE biomarker development, TDP-43 focused drug discovery, and eventual clinical trials. We conclude by highlighting important knowledge gaps and potential future directions for research on LATE. Summary points are presented in Box 1.

## Background

There is growing awareness that Alzheimer's disease neuropathological change (ADNC) is only one of multiple neuropathological substrates associated with amnesic mild cognitive impairment and the Alzheimer's clinical syndrome in the aged population (Korczyn, 2002; Zekry *et al.*, 2002; Bennett *et al.*, 2006; Jellinger and Attems, 2007; Schneider *et al.*, 2007; Crary *et al.*, 2014; Murray *et al.*, 2014; Rahimi and Kovacs, 2014; James *et al.*, 2016). Recent studies have gathered rich clinical data from large groups of subjects across a spectrum of cognitive states, correlated these clinical findings with new pathological markers at autopsy, and then analysed the data using powerful statistical methods. These studies have indicated that the diseases of aged human brains are complex: multiple comorbid pathologies are the norm, and there is substantial interindividual variation in neuropathological phenotypes (Neuropathology Group. Medical Research Council Cognitive and Aging, 2001; Brayne *et al.*, 2009; Kovacs *et al.*, 2013; Murray *et al.*, 2014; Rahimi and Kovacs, 2014; White *et al.*, 2016; Abner *et al.*, 2017; Kapasi *et al.*, 2017; Suemoto *et al.*, 2017; Tanskanen *et al.*, 2017; Robinson *et al.*, 2018b, c). While there is a strong

### Box | LATE and LATE-NC summary points

- LATE-NC features
  - A sampling and staging system for routine autopsy diagnosis is proposed to characterize the anatomical distribution of TDP-43 proteinopathy
    - Stage 1: amygdala only
    - Stage 2: + hippocampus
    - Stage 3: + middle frontal gyrus
  - Hippocampal sclerosis pathology may be observed (and should be reported), but is neither necessary nor sufficient for diagnosis of LATE-NC
- LATE-NC is present in >20% (up to 50%) of individuals past age 80 years according to large community-based autopsy series
- LATE is associated with substantial disease-specific cognitive impairment, usually an amnesic dementia syndrome ('dementia of the Alzheimer's type')
- The overall public health impact of LATE is on the same order of magnitude as Alzheimer's disease neuropathological changes; the diseases are often comorbid, but which pathology is more severe varies greatly between individuals
- Genetic risk factors for LATE have some overlap with FTLD-TDP and with Alzheimer's disease
- There is no molecule-specific biomarker for LATE. This is an important area of need for use in clinical trials (including as a potential exclusion criterion for Alzheimer's disease clinical trials) and longitudinal studies of the clinical and pathological progression of LATE

association between severe ADNC and cognitive impairment in all age groups (Nelson *et al.*, 2009; Abner *et al.*, 2011), subjects who die after 80 years of age often have exhibited cognitive decline exceeding expectation given the severity of ADNC (Kawas and Corrada, 2006; Savva *et al.*, 2009; Nelson *et al.*, 2012). LATE-NC is an important contributor to this apparent clinicopathological mismatch (see below).

Historically, the first-recognized pathological manifestation of LATE was profound hippocampal neuron loss and gliosis, collectively termed hippocampal sclerosis. In a landmark study, Dickson *et al.* (1994) identified 13 elderly subjects with dementia and hippocampal sclerosis, yet who lacked substantial ADNC. Other larger autopsy series that included subjects with dementia and hippocampal sclerosis were later reported (Crystal *et al.*, 2000; Barker *et al.*, 2002; Leverenz *et al.*, 2002; White *et al.*, 2002; Zarow *et al.*, 2005; Attems and Jellinger, 2006; Brayne *et al.*, 2009). In 2006, phosphorylated TDP-43 was discovered as the disease protein in the ubiquitylated inclusions that are signatures of amyotrophic lateral sclerosis (ALS) and

most cases of frontotemporal lobar degeneration (FTLD), known as FTLD-TDP (Neumann *et al.*, 2006; Cairns *et al.*, 2007a). TDP-43 protein, encoded by the *TARDBP* gene (Ou *et al.*, 1995), is a protein that binds to RNA and DNA as well as to other proteins, and serves multiple functions in gene expression regulation at the levels of both transcription and translation (Cohen *et al.*, 2011; Guo and Shorter, 2017). Expressed in most human tissues and cell types, TDP-43 is predominantly non-phosphorylated and localized mostly within nuclei, while in disease states the protein is phosphorylated and often translocated to the cytoplasm (Neumann *et al.*, 2006).

Following the detection of TDP-43 proteinopathy in FTLD-TDP and in the large majority of ALS cases (Mackenzie *et al.*, 2007), TDP-43 proteinopathy was also discovered in the brains of subjects over age 80 years without FTLD or ALS, but often with comorbid hippocampal sclerosis and/or ADNC (Amador-Ortiz *et al.*, 2007a, b). In subjects with ADNC, LATE-NC represents a common comorbid lesion that lowers the threshold for developing dementia (Josephs *et al.*, 2014b, 2015). In retrospective studies, age-related TDP-43 proteinopathy has been associated with a progressive amnesic syndrome that mimicked the Alzheimer's clinical syndrome (Pao *et al.*, 2011; Brenowitz *et al.*, 2014). TDP-43 proteinopathy, hippocampal sclerosis pathology, and the associated amnesic dementia increases with advanced age, while the prevalence of severe ADNC decreases in extreme old age (Nelson *et al.*, 2011a, b, 2013; Brenowitz *et al.*, 2014). The presence of pathological TDP-43 in these cases suggests a novel disease mechanism in older adults. As there is currently no universally agreed upon terminology or staging system for common age-related TDP-43 proteinopathy, this condition is under-studied and not well recognized even among investigators in the field of dementia research. The promotion of research and increasing awareness of this disease are the primary motivations for developing the new term LATE, and for the recommendations that follow.

### LATE neuropathological changes

LATE-NC is a TDP-43 proteinopathy of advanced age, especially in subjects older than age 80. Following the convention proposed by a working group for the neuropathological criteria of Alzheimer's disease (Montine *et al.*, 2012), we use LATE to refer to the disease, and LATE-NC as the term to indicate LATE neuropathological changes. The term LATE is intended to encompass several previously used designations related to TDP-43 proteinopathy that may be associated with cognitive impairment, including hippocampal sclerosis, hippocampal sclerosis of ageing, hippocampal sclerosis dementia, cerebral age-related TDP-43 with sclerosis, and TDP-43 pathologies in the elderly (for reviews see Kuslansky *et al.*, 2004; Lippa and Dickson, 2004; Nelson *et al.*, 2013, 2016b; Dutra *et al.*, 2015).

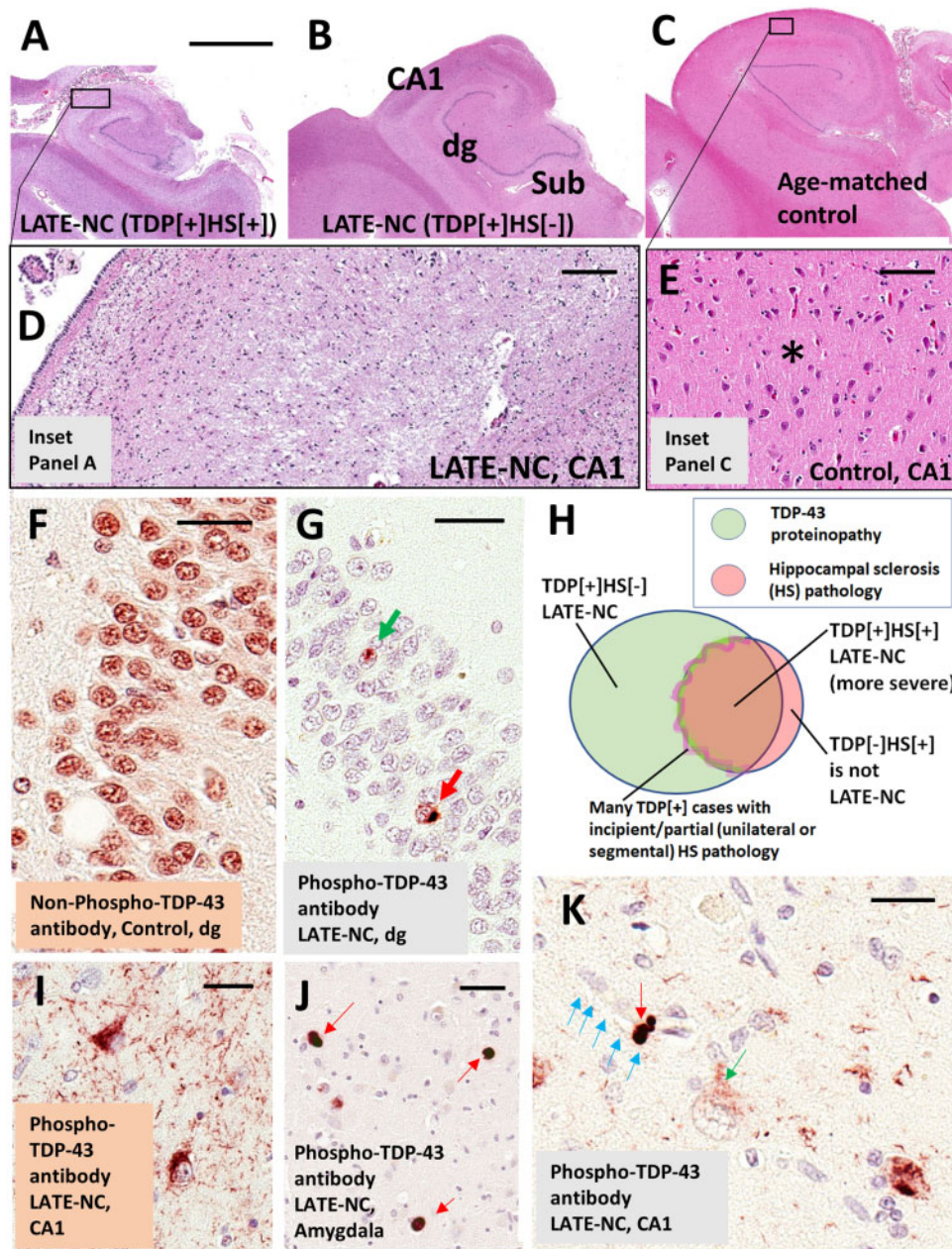
‘TDP-43 proteinopathy’ refers to loss of normal nuclear TDP-43 immunoreactivity, with TDP-43 protein ‘inclusion bodies’ in the neuronal cytoplasm, as well as abnormal TDP-43 accumulation (much of it phosphorylated) in nuclei and cell processes (neurites) of neurons and in oligodendroglia and astrocytes. For representative examples of TDP-43 proteinopathy, see Fig. 1. Mislocalized and phosphorylated TDP-43 is a necessary feature of LATE-NC and sometimes has characteristics similar to those seen in type A FTLD-TDP (Lin *et al.*, 2009; Mackenzie *et al.*, 2011; Murray *et al.*, 2014; Aoki *et al.*, 2015), but often the features do not fit cleanly into an established FTLD-TDP subtype. Indeed, a recent study described features of LATE-NC including both similarities and differences from type A FTLD-TDP (Josephs *et al.*, 2019). In addition to limbic structures, TDP-43 proteinopathy in LATE has also been described in the olfactory bulb, neocortex, basal ganglia, and less frequently in brainstem (Josephs *et al.*, 2008; Geser *et al.*, 2010; Josephs and Dickson, 2016; Nelson *et al.*, 2018). Immunoelectron microscopy showed that the TDP-43 inclusions have a fibrillary ultrastructure composed of bundled 10–20-nm diameter straight filaments (Lin and Dickson, 2008; Lin *et al.*, 2009), often accompanied by electron dense granules (Cairns *et al.*, 2007b; Robinson *et al.*, 2013).

In brains with LATE-NC, haematoxylin and eosin stains may reveal neuronal dropout and astrocytosis in the CA1 sector of the hippocampus, as well as in the subiculum, entorhinal cortex, and amygdala (Amador-Ortiz and Dickson, 2008). Atrophy can be marked in these areas (Fig. 1A–C). In severely affected hippocampi, the neuropil becomes rarefied and loss of neuronal components is accompanied by reactive astrocytosis (Amador-Ortiz *et al.*, 2007a). Pronounced leucocyte infiltrates or perivascular cuffing are not typically seen, but hypertrophic microglia can be numerous (Bachstetter *et al.*, 2015). The neuronal cell loss is segmental in some subjects, observed in some but not all sections from the same brain area (Ighodaro *et al.*, 2015). Hippocampal sclerosis pathology is unilateral in ~40–50% of cases in which both sides were evaluated (Nelson *et al.*, 2011b; Zarow *et al.*, 2012; Kero *et al.*, 2018), not unlike FTLD-TDP (Irwin *et al.*, 2018).

Hippocampal sclerosis is present in a subset of cases with severe LATE-NC, and was the first characteristic pathological feature that distinguished it from ADNC (Dickson *et al.*, 1994). Nevertheless, hippocampal sclerosis is neither specific to LATE-NC nor sufficient for the diagnosis of LATE. The neuropathological diagnosis of hippocampal sclerosis is fraught with difficulty. The most recent consensus guidelines for ADNC and related disorders stated that hippocampal sclerosis pathology is ‘defined by severe pyramidal cell loss and gliosis in CA1 and subiculum of the hippocampal formation that is out of proportion to AD neuropathologic change in the same structures’ (Montine

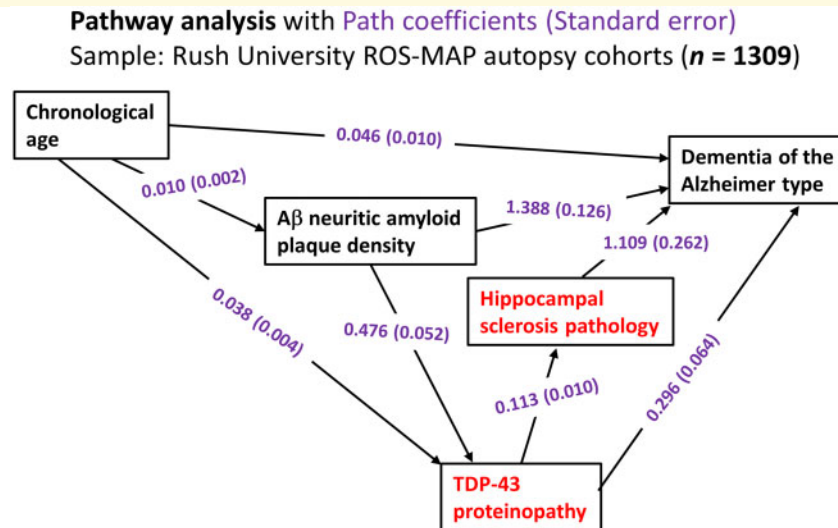
*et al.*, 2012). There is, however, significant topographic and phenotypic heterogeneity in hippocampal degeneration, creating difficulties in establishing strict criteria for widespread use. Moreover, hippocampal sclerosis is a pathological endpoint associated with various underlying disease processes, including epilepsy, hypoxia, hypoglycaemia, certain infections, and numerous neurodegenerative conditions (Josephs *et al.*, 2007; Thom *et al.*, 2009; Yokota *et al.*, 2010; Malek-Ahmadi *et al.*, 2013; Murray *et al.*, 2013; Ling *et al.*, 2017; Popkirov *et al.*, 2017; Sen *et al.*, 2018). Having originated in a 19th century study of epilepsy by Wilhelm Sommer (Sommer, 1880; Thom, 2009), the term hippocampal sclerosis is still used widely by radiologists and pathologists in the context of seizure disorders (Isnard and Bourdillon, 2015; Thom and Sisodiya, 2015). Detailed discussions of histopathological features and subtypes of hippocampal sclerosis can be found elsewhere (Probst *et al.*, 2007; Rauramaa *et al.*, 2013; Hatanpaa *et al.*, 2014; Dutra *et al.*, 2015; Thom and Sisodiya, 2015; Cykowski *et al.*, 2017). Brains with hippocampal sclerosis, but lacking TDP-43 pathology (TDP-43–/HS+), do not represent LATE-NC. For example, brains with hippocampal sclerosis caused by acute hypoxia or associated with epilepsy are negative for TDP-43 proteinopathy (Amador-Ortiz *et al.*, 2007b; Lee and Lee, 2008; Nelson *et al.*, 2011b) and do not fulfil criteria for LATE-NC (Fig. 1H). In summary, TDP-43 proteinopathy is a necessary feature of LATE-NC that may or may not be accompanied by hippocampal sclerosis.

As has been the case in other neurodegenerative diseases (Braak *et al.*, 1993, 2006; Thal *et al.*, 2000; Zaccai *et al.*, 2008; Alafuzoff *et al.*, 2009), careful assessments of autopsy data, from both longitudinal studies of clinic-based research subjects as in the NIA-funded Alzheimer’s Disease Centers, and from community-based studies, have expanded our understanding of LATE. While subjects with advanced age and hippocampal sclerosis often have TDP-43 proteinopathy (Amador-Ortiz *et al.*, 2007b; Nelson *et al.*, 2011b; Robinson *et al.*, 2014; Nag *et al.*, 2015, 2018), TDP-43 proteinopathy in limbic structures is more prevalent than hippocampal sclerosis (Kovacs *et al.*, 2013; Josephs *et al.*, 2014b; Keage *et al.*, 2014; Murray *et al.*, 2014; Rahimi and Kovacs, 2014; Aoki *et al.*, 2015; Nag *et al.*, 2015, 2017; Hokkanen *et al.*, 2018; Robinson *et al.*, 2018b). The TDP-43-positive (+) and hippocampal sclerosis-negative (HS–) cases are a subset of LATE-NC that represent 5–40% of research subjects in autopsy series. Prior researchers have used terms for brains with TDP-43 proteinopathy and with some degree of cell dropout and gliosis, but lacking frank hippocampal sclerosis, as a ‘precursor to HS’, ‘pre-HpScl’, or ‘pre-HS-Aging’ (Hatanpaa *et al.*, 2008; Aoki *et al.*, 2015; Hokkanen *et al.*, 2018). As suggested by the terminology, TDP-43+/HS– brains may represent an early or transitional phase on the same disease continuum as TDP-43+/HS+ cases. There are



**Figure 1 LATE neuropathological changes (LATE-NC).** (A–E) Coronally sectioned human hippocampi stained using haematoxylin and eosin (H&E). Note that the photomicrographs in A–C are presented at the same magnification. (A) LATE-NC with hippocampal sclerosis (HS). The hippocampus is atrophic and the neuropil rarefied. (D) Higher magnification in CA1 subfield, with lack of normal cellular architecture and with extensive gliosis. (C) Control age-matched hippocampus. (E) CA1 of the control hippocampus to demonstrate the normal cellular architecture and intact eosinophilic neuropil (asterisk). The hippocampus shown in B is less atrophic, with less obvious neuropil disruption, in comparison to the case in A at low magnification; however, an adjacent section revealed TDP-43 proteinopathy. Hippocampal fields are labelled in B: dg = dentate granule layer; Sub = subiculum. TDP-43 proteinopathy can be recognized using antibodies raised against either non-phosphorylated or phosphorylated TDP-43 epitopes. (F) Dentate granule cells in a case lacking TDP-43 pathology. Note that cell nuclei are normally immunopositive for non-phosphorylated TDP-43 protein. In a case with LATE-NC (G), by contrast, an antibody against phosphorylated TDP-43 protein recognizes only the pathological inclusions in the nucleus (green arrow) and cytoplasm (red arrow). Unlike the antibody against non-phosphorylated TDP-43, the antibody against phosphorylated TDP-43 is negative in non-affected cells. Most cells in G are visualized with the counterstain, haematoxylin, which stains cell nuclei blue. The Venn diagram in H illustrates schematically the imperfect overlap between cases with TDP-43 proteinopathy, hippocampal sclerosis, and LATE-NC. A subset of cases with TDP-43 pathology have comorbid hippocampal sclerosis pathology; the change zone between non-hippocampal sclerosis and hippocampal sclerosis cases is indistinct because many cases seem to be in transition with incipient hippocampal neuron loss and gliosis. Importantly, cases with hippocampal sclerosis pathology but no TDP-43 proteinopathy (e.g. hippocampal sclerosis pathology associated with anoxia or epilepsy) are not classified as LATE-NC. (I) Phospho-TDP-43 proteinopathy in two neurons in hippocampal CA1, along with phospho-TDP-43 immunoreactive dystrophic neurites. (J) Tangle-like

(continued)



**Figure 2** Statistical analyses on data related to LATE from the Rush University community-based autopsy cohort depicting the results of pathway analyses. Data were analysed from research volunteers (total  $n = 1309$ ) in two clinical-pathological studies of ageing from Rush University as described previously (Power *et al.*, 2018). In this sample, the mean age of death was 89.7 years [standard deviation (SD) 6.5 years, range 65–108 years]. These analyses incorporated age, density of amyloid- $\beta$  neuritic amyloid plaques (to factor in ADNC), TDP-43 proteinopathy, hippocampal sclerosis pathology, and the endpoint of Alzheimer's-type clinical dementia. The components of the pathway analyses most strongly associated with LATE-NC are shown in red. The numbers are path coefficients with standard error in parentheses (shown in purple). These numbers help to quantify the effects of individual pathways. For instance, the data are compatible with there being two pathways from TDP-43 proteinopathy to dementia, one direct pathway (TDP-43 proteinopathy  $\rightarrow$  dementia) and the other indirect pathway that includes hippocampal sclerosis pathology (TDP-43 proteinopathy  $\rightarrow$  hippocampal sclerosis  $\rightarrow$  dementia): in the statistical model, the TDP-43 proteinopathy is independently associated with both hippocampal sclerosis pathology and clinical dementia status. Further, the data indicate that a subset of TDP-43 proteinopathy is 'downstream' of ADNC-type neuritic amyloid plaque pathology. In a practical sense, this means that brains with more neuritic amyloid plaques are more likely to have TDP-43 proteinopathy, with all other known factors being the same. A $\beta$  = amyloid- $\beta$ .

other clues about LATE that were gathered from autopsy cohort studies. For example, even when hippocampal sclerosis was unilateral or segmental, the TDP-43 proteinopathy was almost always bilateral (Nelson *et al.*, 2011b; Ighodaro *et al.*, 2015). These observations have implications about how LATE evolves, which remains an important and open question.

Data gathered in large autopsy series have been analysed to test hypotheses about progression of LATE. Multivariable regression-based assessment can be used to generate models to test whether cross-sectional data align with proposed sequential pathways of neuropathological changes. Results of one such pathway analysis, from the Rush University community-based autopsy studies, are shown in Fig. 2. These analyses were performed as described previously (Power *et al.*, 2018) and the findings are compatible with at least three hypotheses: (i) a subset of

cases with TDP-43 proteinopathy develop hippocampal sclerosis caused or exacerbated by overlapping process(es) that promoted the TDP-43 proteinopathy, or directly by the TDP-43 proteinopathy itself; (ii) TDP-43 proteinopathy is associated independently with dementia, even in cases lacking hippocampal sclerosis; and (iii) pathogenetic mechanisms associated with ADNC (in Fig. 2, data are provided on neuritic amyloid- $\beta$  plaques) are also associated with increased TDP-43 proteinopathy. Current rodent models of TDP-43 proteinopathy with hippocampal sclerosis-like pathology are few (Ke *et al.*, 2015). TDP-43 proteinopathy was shown to be transmissible in mouse models similar to pathological tau and amyloid- $\beta$  from Alzheimer's disease brains (Porta *et al.*, 2018), but the published TDP-43 models are thought to be more directly relevant to FTL-DTP than LATE. For now, the lack of adequate longitudinal biomarker data and the limitations of current animal

#### Figure 1 Continued

phospho-TDP-43 immunoreactive cytoplasmic inclusions in amygdala (red arrows) with fewer phospho-TDP-43 immunoreactive neurites in the background. (K) An intraneuronal phospho-TDP-43 inclusion (red arrow) and a phospho-TDP-43 deposit (green arrow) surrounding a capillary (shown with blue arrows); these TDP-43 immunoreactive structures have been demonstrated to exist within astrocyte end-feet (Lin *et al.*, 2009). Note also the presence of a cell with cytoplasmic puncta (green arrow), perhaps in an early phase of phosphorylated TDP-43 proteinopathy. Scale bar in A = 4 mm for A–C; D = 200  $\mu$ m; E = 100  $\mu$ m; F = 30  $\mu$ m; G = 35  $\mu$ m; I = 30  $\mu$ m; and K = 25  $\mu$ m.

models hamper our study of disease mechanism(s) and further investigations are needed.

## LATE MRI studies

MRI studies have provided a complementary window into brain changes in LATE, highlighting brain atrophy both within and outside of the medial temporal lobes of brains with autopsy-verified LATE-NC. Prior studies featured research volunteers who underwent MRI with autopsy follow-up. Several of these studies focused on the subset of cases with hippocampal sclerosis (i.e. presumed severe LATE-NC), therefore, most of the published data were lacking information about less severely affected cases. With that caveat in mind, a common finding in MRI studies is that hippocampal atrophy is greater in cases with LATE-NC than in those with pure Alzheimer's disease (Jagust *et al.*, 2008; Josephs *et al.*, 2008, 2017a; Dawe *et al.*, 2011; Kaur *et al.*, 2014; Dallaire-Theroux *et al.*, 2017; Hanko *et al.*, 2019). Barkhof *et al.* (2007) found that many subjects with medial temporal atrophy lacked primary underlying ADNC. In this study cohort, the sensitivity and specificity of severe atrophy for ADNC was 63% and 69%, respectively, consistent with prior findings (Jack *et al.*, 2002). Josephs *et al.* (2008) reported that subjects with neuropathology consistent with LATE-NC tended to be older, with more cognitive impairment, and with more pronounced hippocampal atrophy than TDP-43– subjects. Zarow *et al.* (2011) also described atrophy and deformation of the hippocampus considerably greater in those with hippocampal sclerosis and LATE-NC than in those with only ADNC (Zarow *et al.*, 2011). In hippocampal sclerosis associated with LATE-NC, hippocampal atrophy was often asymmetric, and it tended to progress in a rostral-caudal gradient in the hippocampus. Using post-mortem MRI, Dawe *et al.* (2011) reported stronger correlations between hippocampal atrophy and LATE-NC (with hippocampal sclerosis pathology) than between hippocampal atrophy and ADNC, and subjects with both ADNC and LATE-NC had greater hippocampal atrophy than those with only ADNC. A recent study found that the volume and shape of the amygdala is associated with underlying LATE-NC and that these structural changes are indicative of cognitive decline beyond what can be explained with other pathological indices (Makkinejad *et al.*, 2019).

Post-mortem MRI research has also provided strong evidence that LATE-NC is associated with substantial brain atrophy outside the medial temporal lobes (Kotrotsou *et al.*, 2015). Figure 3A shows updated data from the Rush University autopsy cohort. After controlling for demographics, ADNC and other age-related pathologies, LATE-NC was related to not only the mesial temporal lobe atrophy, but also to atrophy in the inferior frontal, anterior temporal, and insular cortices. It is noteworthy that this regional atrophy pattern corresponds with the distribution of TDP-43 proteinopathy at autopsy (Josephs *et al.*, 2016; Nag *et al.*, 2018) (Fig. 3B). These data are

in agreement with pathological studies of LATE-NC, as well as neuroimaging in subjects with LATE-NC risk genotypes, showing widespread brain involvement (Neltner *et al.*, 2014; Cykowski *et al.*, 2016; Josephs *et al.*, 2016; Nelson *et al.*, 2016a; Nho *et al.*, 2016).

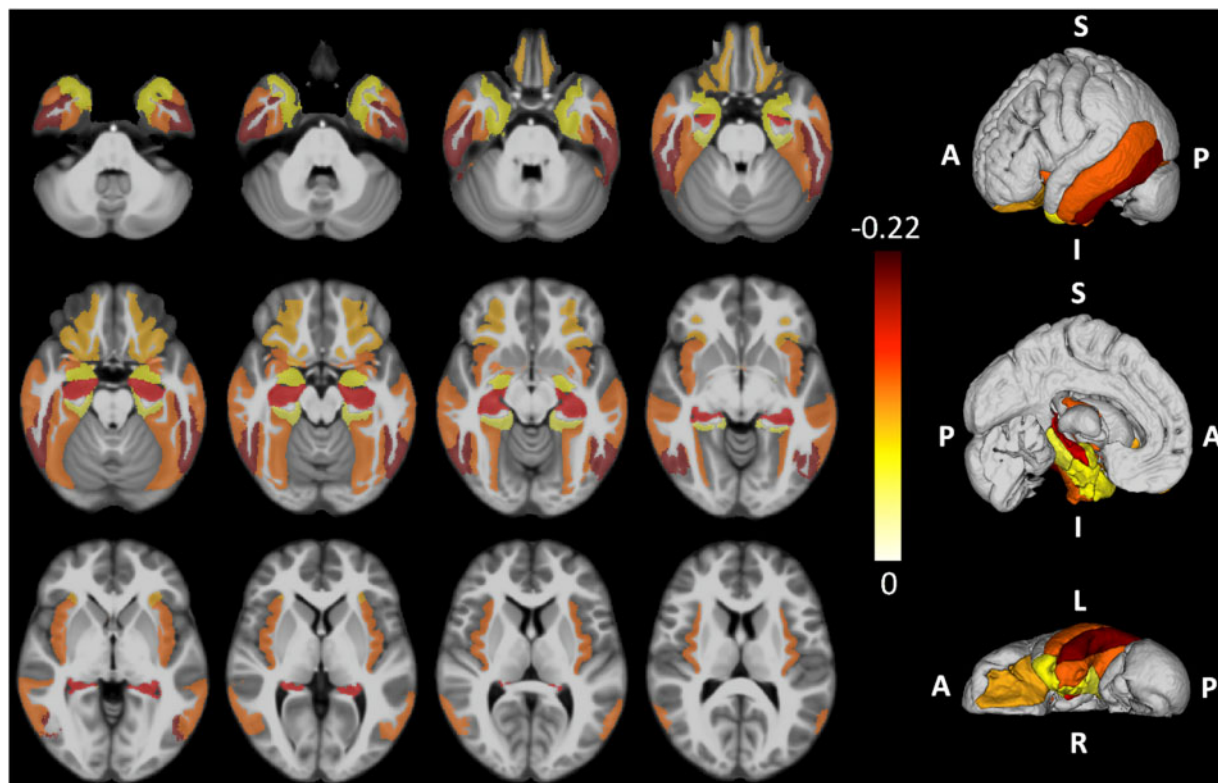
## Recommendations for routine autopsy evaluation and classification of LATE-NC

It is recommended that TDP-43 immunohistochemistry be performed as part of the neuropathological evaluation in all older subjects. At a minimum, immunohistochemical staining for TDP-43 is recommended in three brain areas: amygdala, mid-level hippocampus, and middle frontal gyrus. We recommend evaluating these regions as they are commonly obtained at autopsy of aged subjects and capture presumed progression of LATE-NC in the brain. This sampling includes the brain area affected early in the disease course (amygdala, Stage 1), an intermediate stage where the pathological change is robustly associated with cognitive impairment (hippocampus, Stage 2), and a region affected at more advanced stages (middle frontal gyrus, Stage 3) (Nag *et al.*, 2018). Any detected TDP-43 proteinopathy is sufficient to define an anatomical region-based stage: for example, a minute amount of detected TDP-43 proteinopathy in the hippocampus indicates at least Stage 2. We emphasize that the proposed sampling for LATE-NC autopsy screening is a minimal evaluation, whereas more detailed sampling and staging should be considered for specific research settings (Josephs *et al.*, 2014a, 2016; Uchino *et al.*, 2015; Nag *et al.*, 2017, 2018; Zhang *et al.*, 2019). Figure 3B depicts staging schemes for LATE-NC, including sampling recommended for neuropathological evaluation of brain of older adults. This does not address regions that would be assessed in separate TDP-43 pathological staging schemes developed for ALS or FTLTDP (Brettschneider *et al.*, 2013; Fatima *et al.*, 2015; Tan *et al.*, 2015; Verde *et al.*, 2017; Neumann and Mackenzie, 2019).

Practical questions arise in relation to diagnostic 'boundary zones' between LATE-NC, FTLTDP, and ADNC. While both LATE-NC and FTLTDP may affect neocortical areas and may be comorbid with hippocampal sclerosis, LATE-NC usually has a later age of onset, an amnesic dementia, and limbic predominance of pathological change (Nelson *et al.*, 2011b). On the other hand, recommendations for LATE-NC do not stipulate any age cut-offs, because the exact age ranges of disease susceptibility for FTLTDP or LATE-NC are not yet fully understood. For prior pathology-based comparisons between subtypes of TDP-43 proteinopathies (not related to age of onset), previous studies should be consulted (Amador-Ortiz *et al.*, 2007a; Tan *et al.*, 2015). More widespread and severe cortical atrophy is typically present in advanced FTLTDP than LATE-NC. There may indeed be features that could definitively distinguish LATE-NC cases



### A Brain atrophy associated with autopsy-confirmed LATE-NC: Data from Rush University ROS-MAP community-based autopsy cohorts



### B LATE-NC related stages based on anatomic distribution of TDP-43 pathology

Simplified staging of TDP-43 proteinopathy* for routine LATE-NC diagnosis (consensus recommendation)		Josephs TDP-43 proteinopathy staging (KA Josephs <i>et al.</i> , 2013)		Rush University TDP-43 proteinopathy staging (S Nag <i>et al.</i> , 2017)	
0	None	0	None	0	None
1	Amygdala	1	Amygdala	1	Amygdala
2	Hippocampus	2	Entorhinal cortex, subiculum	2	Entorhinal cortex, CA1
		3	Dentate, Occipitotemporal cortex	3	Anterior temporal cortex
		4	Insula, Inf temporal cortex	4	Midtemporal and orbitofrontal cortex
5	Inf olive, midbrain				
3	Middle frontal gyrus (MFG)	6	Basal ganglia, MFG	5	MFG

\*-Any TDP-43 proteinopathy is seen in that anatomic region

**Figure 3 Brain regions that are affected in LATE.** (A) Post-mortem MRI with autopsy confirmation allows discrimination of regions of brain atrophy associated with LATE-NC. These data indicate grey matter regions inside and outside of the medial temporal lobe with atrophy in cases with autopsy-confirmed LATE-NC from a community-based autopsy sample. The figure was prepared similarly to the methods used in Kotrotsou *et al.* (2015), with some modifications. Cerebral hemispheres from 539 participants of two cohort studies of ageing (Rush Memory and Aging Project and Religious Orders Study) were imaged with MRI *ex vivo* and also underwent detailed neuropathological characterization. The cortical and subcortical grey matter were segmented into 41 regions. Linear regression was used to investigate the association of regional volumes (normalized by height) with the score of LATE-NC at autopsy (scores: 0 = no TDP-43 inclusions, or inclusions in amygdala only; 1 = TDP-43 inclusions in amygdala as well as entorhinal cortex or hippocampus CA1, and neocortex; 2 = TDP-43 inclusions in amygdala, entorhinal cortex or hippocampus CA1, and neocortex, and hippocampal sclerosis pathology) controlling for amyloid plaques and neurofibrillary tangles, Lewy bodies, gross and microscopic infarcts, atherosclerosis, arteriolosclerosis, cerebral amyloid angiopathy, as well as age, sex, years of education, post-mortem interval to fixation and to imaging, and scanners. Unique colours have been assigned to different model estimates (units: mm<sup>2</sup>) for grey matter regions with significant negative correlation between their volumes and LATE pathology ( $P < 0.05$ , false discovery rate-corrected); darker colours indicate greater brain atrophy in that region. Results are overlaid on both hemispheres of the T<sub>1</sub>-weighted template of the IIT Human Brain Atlas (v.4.2). Lateral, medial and inferior to superior 3D views of the results are also shown. (B) Classification of LATE-NC according to anatomical region(s) affected by TDP-43 proteinopathy. The present working group recommended a simplified staging scheme for routine assessment of LATE-NC. This requires sampling and TDP-43 immunohistochemical staining of amygdala, hippocampus, and middle frontal gyrus. More detailed TDP-43 immunohistochemical staging schemes that are directly relevant to LATE-NC were previously published by Josephs *et al.* (2014a, 2016) and Nag *et al.* (2018). MFG = middle frontal gyrus.

(histopathologically or molecularly) from subtypes of FTLTDP (Arai *et al.*, 2010; Hasegawa *et al.*, 2011; Tsuji *et al.*, 2012; Laferriere *et al.*, 2019); however, more work is needed in this area. For now, definitive criteria to differentiate severe LATE-NC from FTLTDP await discovery of specific features that discriminate among various TDP-43 proteinopathies (Tan *et al.*, 2017a).

Although LATE-NC and ADNC are recognized by differing neuropathological hallmarks, they may share upstream risk factors and disease mechanisms. Genetic variants predisposing to one protein misfolding disorder may also cause or exacerbate others (see below), and there may be interactions between the misfolded proteins themselves (Trojanowski and Lee, 2000; Higashi *et al.*, 2007; Hu *et al.*, 2008; Uryu *et al.*, 2008; Kadokura *et al.*, 2009; Davis *et al.*, 2017; Spires-Jones *et al.*, 2017; Tan *et al.*, 2017b; Nelson *et al.*, 2018). Brains that harbour ADNC, including some subjects with early-onset familial Alzheimer's disease or Down syndrome, tend to also contain TDP-43 proteinopathy at rates higher than those lacking ADNC (Ala *et al.*, 2000; Jellinger, 2000; Lippa *et al.*, 2009; Davidson *et al.*, 2011; Zarow *et al.*, 2012). Individual neurons with both tau neurofibrillary tangle pathology and TDP-43 inclusions have been described, particularly in the amygdala, entorhinal cortex, and dentate gyrus of the hippocampus (Amador-Ortiz *et al.*, 2007b; Kadokura *et al.*, 2009; Smith *et al.*, 2017; Robinson *et al.*, 2018c; Josephs *et al.*, 2019). Several published accounts have evaluated the connections between primary age-related tauopathy (PART) and age-related TDP-43 proteinopathy (Josephs *et al.*, 2017b; Smith *et al.*, 2017; Zhang *et al.*, 2019), and TDP-43 proteinopathy has also been described in brains with coexisting argyrophilic grains or glial tauopathy (Fujishiro *et al.*, 2009; Yokota *et al.*, 2010; Arnold *et al.*, 2013; Kertesz *et al.*, 2015). The implications of comorbid amyloid- $\beta$  and various tau pathologies in the context of LATE-NC are still incompletely understood, so further studies are required. There is also evidence that Lewy body disease and TDP-43 proteinopathy may coexist (Nakashima-Yasuda *et al.*, 2007; McAleese *et al.*, 2017; Miki *et al.*, 2018; Trieu *et al.*, 2018). On the other hand, many cases with 'end-stage' ADNC or Lewy body disease lack TDP-43 proteinopathy, so we recommend reporting the presence or absence of LATE-NC as a separate diagnostic entity, even when there are comorbid amyloid- $\beta$ , tau and/or  $\alpha$ -synuclein proteinopathies.

Additional research is required to guide future consensus-based recommendations in this evolving field. In terms of immunohistochemical reagents used to detect TDP-43 proteinopathy, there is no current consensus that a specific antibody can be recommended. Many neuropathologists use sensitive phospho-TDP-43 antibodies (Hasegawa *et al.*, 2008; Alafuzoff *et al.*, 2015); small aggregates can be readily seen using these reagents. Others use antibodies against non-phosphorylated epitopes, especially for detecting early changes (pathological nuclear to cytoplasmic redistribution) that may precede inclusion body formation

(Vatsavayai *et al.*, 2016; Braak *et al.*, 2017; Braak and Del Tredici, 2018; Nana *et al.*, 2019). It is unclear whether the absence of nuclear TDP-43 is reversible, but animal studies using inducible pathogenetic systems would suggest so (Ke *et al.*, 2015). Further, there is some evidence that TDP-43 antigenicity can be vulnerable to fixation artefacts, and epitope retrieval methodology can influence results (Hatanpaa *et al.*, 2008). Additional practice guidelines for studying LATE-NC need formal blinded cross validation studies as has been done for amyloid- $\beta$ , tau and  $\alpha$ -synuclein pathological biomarkers. Future studies will be needed to validate and refine systems for staging LATE-NC, and grading local pathological severity, as they relate to clinical and neuroimaging outcomes, especially since at least three staging schemes have been proposed as summarized in Fig. 3B.

## Clinical and neurocognitive features of LATE

The clinical course of subjects with autopsy-proven LATE-NC has been characterized as an amnesic cognitive syndrome that can evolve to incorporate multiple cognitive domains and ultimately to impair activities of daily living, i.e. the dementia syndrome (Nelson *et al.*, 2010; Nag *et al.*, 2015; Robinson *et al.*, 2018a, b). The cognitive impairment is greater than can be accounted for by ADNC or other pathologies (Gold *et al.*, 2000; Kawas and Corrada, 2006; Imhof *et al.*, 2007; Giannakopoulos *et al.*, 2008; Nelson *et al.*, 2011b; Kravitz *et al.*, 2012; Boyle *et al.*, 2013; Erten-Lyons *et al.*, 2013). Initial reports on subjects with LATE-NC were focused on subjects with severe pathology (Dickson *et al.*, 1994; Snowden *et al.*, 1997; Crystal *et al.*, 2000; Vinters *et al.*, 2000; Leverenz *et al.*, 2002; Kuslansky *et al.*, 2004; Zarow *et al.*, 2005, 2008; Attems and Jellinger, 2006; Chui *et al.*, 2006; Leverenz and Lipton, 2008), which helped to show that LATE-NC can be associated with dementia. More recent autopsy series, with both large sample sizes and broad ranges of clinical and pathological findings, have enabled statistical approaches to model the likely relative impact of each disease type. With these methods, LATE-NC was associated with substantial cognitive impairment that was independent of other coexisting pathologies (Nelson *et al.*, 2010; Keage *et al.*, 2014; Murray *et al.*, 2014; Josephs *et al.*, 2015; Nag *et al.*, 2017). Table 1 shows primary data on the relationship between LATE-NC (stratified by the recommended three-stage system) and cognition. The neurological features associated with LATE-NC were different from the behavioural or aphasic clinical syndromes seen in FTLTDP cases (Nelson *et al.*, 2011b; Jung *et al.*, 2014; Wilson *et al.*, 2019). While TDP-43 proteinopathy has been documented in some cognitively unimpaired subjects (Arnold *et al.*, 2013; Keage *et al.*, 2014; Uchino *et al.*, 2015; Elobeid *et al.*, 2016; Nascimento *et al.*, 2016; Nag *et al.*, 2018; Nascimento *et al.*, 2018), it is likely that this represents

**Table 1** Selected parameters from a large community-based autopsy cohort, stratified by LATE-NC stages

Characteristics	Consensus proposed LATE-NC TDP-43 stages				P-value
	0	1	2	3	
<i>n</i>	666	263	258	189	-
Age at death (SD)	87.9 (6.8)	89.9 (6.2)	91.8 (5.6)	91.9 (5.4)	<0.001
% Female	65.3	67.7	74	72.5	0.040
<b>Clinical diagnosis</b>					<0.001
% Normal	41.8	33.5	18.9	7.6	
% MCI or dementia	58.2	66.5	81.1	92.4	
% with comorbid HS pathology	1.7	3.5	13.6	42.9	<0.001
<b>Cognitive function tests proximate to death, mean (SD)</b>					
MMSE score	22.8 (8.1)	21.2 (8.9)	18.2 (9.8)	14.0 (10.0)	<0.001
Episodic memory score	-0.60 (1.28)	-0.76 (1.31)	-1.36 (1.34)	-2.06 (1.23)	<0.001

Data were analysed from the Rush University ROS-MAP community-based autopsy cohort; *n* = 1376.

These data were analysed as described previously (Nag *et al.*, 2018) from the Rush University Religious Orders Study (ROS), showing clinical, pathological, and cognitive status features. The new consensus guidelines for LATE-NC staging were applied to highlight the associations between LATE-NC severity (operationalized with new recommended staging method) including hippocampal sclerosis (HS) pathology and cognitive function tests. Note that many of these subjects in all the LATE-NC stages have additional pathologies including ADNC as described previously (Schneider *et al.*, 2007; James *et al.*, 2016).

MCI = mild cognitive impairment; MMSE = Mini-Mental State Examination.

preclinical disease in subjects dying before onset of clinical symptoms; such clinical resilience to pathological changes has been described in many disorders (Perkins *et al.*, 2003; Shojania *et al.*, 2003; Roulson *et al.*, 2005; Latimer *et al.*, 2017; Robinson *et al.*, 2018b).

Although there is overlap in clinical features of autopsy-confirmed LATE-NC and ADNC (Pao *et al.*, 2011; Brenowitz *et al.*, 2014; Murray *et al.*, 2014; Nag *et al.*, 2017), careful analyses may identify distinctive neurocognitive features. Preliminary evidence suggests that subjects with relatively 'pure' LATE-NC (lacking severe comorbid pathologies) tend to have a more gradual clinical decline compared to those with 'pure' ADNC (Murray *et al.*, 2014; Boyle *et al.*, 2017). In contrast, those with comorbid ADNC and LATE-NC showed faster decline and more severe cognitive impairment than those with either ADNC or LATE-NC alone (Josephs *et al.*, 2014b, 2015; Nag *et al.*, 2017). In studies with both detailed longitudinal cognitive testing and comprehensive neuropathological evaluations, subjects with LATE-NC had prominent impairment in episodic memory (Table 1), but other cognitive domains and global cognitive status were also commonly affected especially in the later disease stages (Nag *et al.*, 2015, 2017, 2018; Wilson *et al.*, 2019). Correlative studies indicate that certain neurocognitive assessments, such as verbal fluency measures, are not independently associated with hippocampal volume, but are instead correlated with neocortical grey matter volumes (Ajilore *et al.*, 2015; Pelletier *et al.*, 2017). Correspondingly, subjects with relatively preserved verbal fluency (cortically-dependent), despite profound deficiency in word list delayed recall (hippocampal-dependent), have been shown to be at risk for LATE-NC (Nelson *et al.*, 2011b). This pattern of neurocognitive test scores in LATE differs from that seen in subjects with ADNC

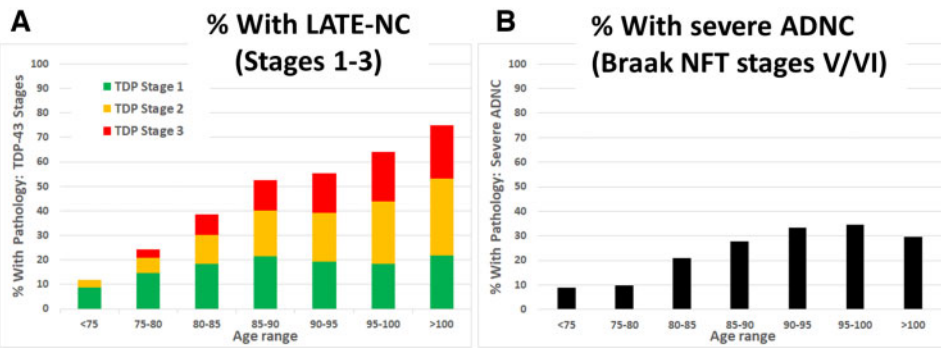
alone (Nelson *et al.*, 2011b) or FTLD-TDP (Brenowitz *et al.*, 2014).

Neuropsychiatric disturbances have been reported in some subjects with LATE-NC (Ighodaro *et al.*, 2015), and a retrospective, cross-sectional, multicentre study found evidence of increased risk of 'agitation/aggression' symptoms in subjects with ADNC and comorbid TDP-43 proteinopathy in comparison to subjects with ADNC lacking TDP-43 proteinopathy (Sennik *et al.*, 2017). However, not all prior studies found that LATE-NC was associated with non-amnesic manifestations (Velakoulis *et al.*, 2009; Nelson *et al.*, 2011b; Vatsavayi *et al.*, 2014; Sahoo *et al.*, 2018). Future investigations are warranted to test for specific neuropsychiatric, motor, or autonomic signs that distinguish LATE from other degenerative disorders.

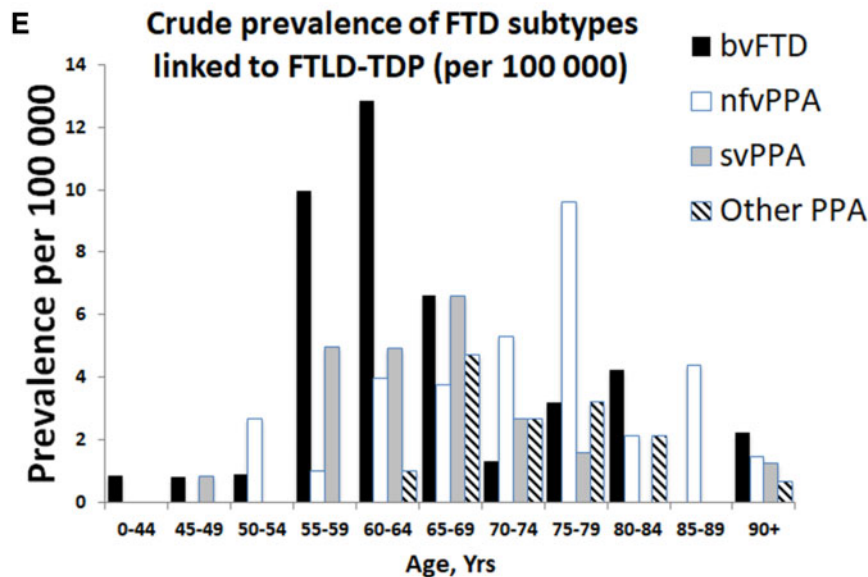
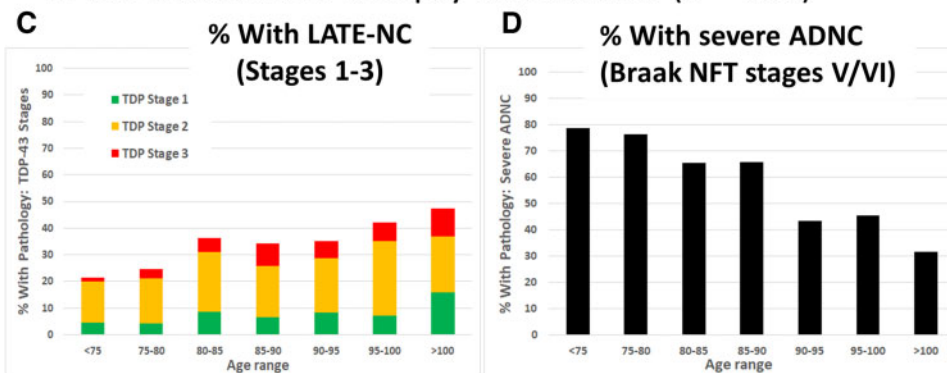
## Public health impact of LATE

The public health impact of LATE is likely to be quite significant. Two basic study design elements that influence recognition of LATE-NC in autopsy cohorts are the age range in the cohort, and the date of the study. Researchers were unaware of TDP-43 proteinopathy prior to 2006, so studies prior to this time could not assess the specific impact of LATE. LATE-NC is mostly seen in the oldest-old, whereas in early clinical-pathological correlation studies of dementia (Roth *et al.*, 1966; Blessed *et al.*, 1968), the research subjects had died in their early 70s. LATE-NC needs to be assessed in population studies that include all age ranges. More recent clinical studies have demonstrated biomarker evidence of 'suspected non-Alzheimer's disease pathophysiology' (SNAP) causing amnesic type cognitive impairment with substantial hippocampal atrophy but lacking detectable amyloid- $\beta$  amyloidosis (Caroli *et al.*, 2015;

Rush University community-based cohort data ( $n = 1376$ )



NACC multicentre autopsy cohort data ( $n = 806$ )



**Figure 4 Different neurodegenerative disease conditions stratified by age: LATE-NC, severe ADNC, and FTD.** FTD/FTLD cases were not present in data shown in **A–D**. Note that published studies to estimate disease prevalence for the various diseases have used importantly different study designs—thus, **E** is a clinical (no autopsy) study because population-based autopsy cohorts lack substantial numbers of FTD/FTLD cases. (**A** and **B**) Data from a community-based autopsy cohort—the Rush University ROS-MAP cohort (overall  $n = 1376$ ). The TDP-43 pathology is operationalized using standard methods as described previously (Nag *et al.*, 2018) and then the current paper’s suggested simplified staging system was applied; sample sizes for each age group (in years) are: <75 ( $n = 34$ ); 75–80 ( $n = 82$ ); 80–85 ( $n = 192$ ); 85–90 ( $n = 375$ ); 90–95 ( $n = 407$ ); 95–100 ( $n = 222$ ); and >100 ( $n = 64$ ). Note that in this community-based sample, the proportion of cases with advanced ADNC is <50% in all age groups. (**C** and **D**) Data from the National Alzheimer’s Coordinating Center (NACC), which derives from 27 different research centres, as described previously (Besser *et al.*, 2018; Katsumata *et al.*, 2018). Overall sample size is  $n = 806$ , stratified thus by age groups (in years): <75 ( $n = 155$ ); 75–80 ( $n = 118$ ); 80–85 ( $n = 165$ ); 85–90 ( $n = 170$ ); 90–95 ( $n = 122$ ); 95–100 ( $n = 57$ ); and >100 ( $n = 19$ ). The NACC research subjects were more likely to come to autopsy after being followed in dementia clinics, and the sample includes a higher percentage of subjects with severe ADNC. The percentage of subjects with LATE-NC is still >20% in each age group. Note that in both the community-based cohort (**A**

(continued)

Burnham *et al.*, 2016; Jack *et al.*, 2016, 2017; Abner *et al.*, 2017; Wisse *et al.*, 2018). For example, the evaluation of 1535 participants in the Mayo Clinic Study of Aging showed significantly greater prevalence of SNAP compared with preclinical Alzheimer's disease, and multimorbidity was increased in SNAP (odds ratio 2.16) (Vassilaki *et al.*, 2018). LATE is probably an important contributor in this group of subjects (see below).

Among subjects autopsied past 80 years of age, most studies indicate that >20% of brains had pathological features consistent with LATE-NC (Fig. 4). It is noteworthy that the majority of these cases had additional comorbid pathologies, so the measured clinical-pathological correlation (relative contribution of each pathology to cognitive impairment) depends on how the investigators defined diagnostic thresholds and cut-points. The frequency of LATE-NC in autopsy series have varied, ranging from 5% to 50% of brains that were evaluated using TDP-43 immunohistochemistry, approximately twice the frequencies that were detected in prior studies that could only assess hippocampal sclerosis pathology (Leverenz *et al.*, 2002; Lippa and Dickson, 2004; Arai *et al.*, 2009; Nelson *et al.*, 2011b; Rauramaa *et al.*, 2011; Tremblay *et al.*, 2011; Corrada *et al.*, 2012; Zarow *et al.*, 2012; Malek-Ahmadi *et al.*, 2013; Keage *et al.*, 2014; Jellinger and Attems, 2015; Uchino *et al.*, 2015; Takao *et al.*, 2016; Latimer *et al.*, 2017; McAleese *et al.*, 2017; Hokkanen *et al.*, 2018; Kero *et al.*, 2018; Robinson *et al.*, 2018a). Differences in study design, including the application of various criteria for defining pathological abnormalities, pathological methods, recruitment strategy, and cohort demographics, all contribute to the variability in the reported frequency of LATE-NC.

One approach that can be used to assess the public health impact of a disease is the evaluation of attributable risk (Porta, 2014). Although generally used to study the impact of risk factors on disease prevalence in a population (Bruzzi *et al.*, 1985), this statistical method can be applied to neuropathological studies to indicate the relative impact of different neuropathologies on clinical dementia. More specifically, the assessment of attributable risk can query how the frequency of LATE-NC, in relation to other common brain lesions detected at autopsy, is associated with the probability

of a dementia diagnosis (Boyle *et al.*, 2019). This analytical approach theoretically makes it possible to estimate the proportion of dementia that might be prevented if LATE-NC could be eliminated, and to compare that with other neuropathologies. The results of an analysis of attributable risk in the Rush University Religious Orders Study is shown in Table 2; methods have been described in detail previously (Boyle *et al.*, 2019). These data are compatible with the hypothesis that a significant (~15–20%) proportion of clinically diagnosed Alzheimer's disease dementia (i.e. the Alzheimer's clinical syndrome) in advanced age is attributable to LATE-NC; the impact is about half the magnitude of ADNC in this group of older subjects, and the impact is similar to the combined effects of vascular neuropathologies.

Also pertinent to the current and future public health impact of LATE is the age range of subjects with highest risk for the disease. The tendency for LATE-NC to occur among the oldest-old has been appreciated for decades, since the groundbreaking studies on age-related hippocampal sclerosis (Crystal *et al.*, 1993; Dickson *et al.*, 1994), a pathological manifestation later shown to be associated with LATE-NC. In multiple subsequent large autopsy samples, LATE-NC was observed with increasing frequency in each year of life after age 85 (Nelson *et al.*, 2013; Keage *et al.*, 2014; Uchino *et al.*, 2015; Hokkanen *et al.*, 2018) (Fig. 4). This is in contrast to amyloid- $\beta$  plaques, which are common (seen in >50% of subjects) in all elderly age groups, but are not universal and not more frequently seen at autopsy with every year of advanced old age (Braak *et al.*, 2011; Nelson *et al.*, 2011a, 2013; Brenowitz *et al.*, 2014; Neltner *et al.*, 2016). LATE appears to be ~100-fold more prevalent than FTD syndromes, which tend to affect younger subjects (Knopman and Roberts, 2011; Coyle-Gilchrist *et al.*, 2016) (Fig. 4E; note the y-axis scale). Females are generally more likely to survive to advanced old age than males (Neltner *et al.*, 2016), which places them at increased lifetime risk for LATE. Otherwise, there is no compelling evidence to date of strong sex-related or ethnoracial differences in susceptibility to LATE (Brenowitz *et al.*, 2014; Murray *et al.*, 2014; Latimer *et al.*, 2017; Oveisgharan *et al.*, 2018), but further studies in diverse populations are needed. Since most

#### Figure 4 Continued

and **B**) and clinic-based cohort (**C** and **D**), the proportion of subjects with severe ADNC decreased in advanced old age, while in the same cases the proportion of subjects with LATE-NC increased. (**E**) Epidemiological data on FTD syndromes for comparison to LATE. Data are provided about crude prevalence rates for FTD syndromes that have been associated with FTLD-TDP. Several of these clinical syndromes are likely to have considerable numbers of cases with FTLD-tau (bvFTD and nfvPPA) or ADNC (other PPA) rather than FTLD-TDP, so the actual prevalence of FTLD-TDP pathology is probably lower than these data suggest. Note that the clinical syndromes associated with FTLD-TDP have a prevalence that are several orders of magnitude lower than LATE-NC. These data, described in detail previously (Coyle-Gilchrist *et al.*, 2016), derive from multisource referral over 2 years, which identified all diagnosed or suspected cases of FTD subtypes in two UK counties comprising the PiPPIN (Pick's Disease and Progressive Supranuclear Palsy: Prevalence and Incidence) catchment area in the East of England. Two cities in the PiPPIN catchment area were Norfolk and Cambridge. Diagnostic confirmation used current consensus diagnostic criteria after interview and re-examination. Total sample size was  $n = 986\,483$  subjects. Shown are crude prevalence rates for the major FTLD-TDP associated syndromes by age and syndrome. bvFTD = behavioural variant frontotemporal dementia; nfvPPA = non-fluent agrammatic variant primary progressive aphasia; svPPA = semantic variant PPA. Note that subjects between ages 55 and 80 are at greatest risk for FTD, and, the FTLD-TDP associated FTD syndrome prevalence is <30 per 100 000 (**E**), in sharp contrast to the data shown in **A–D**.

**Table 2 A statistical analysis of attributable risk from research volunteers in two clinical-pathological studies of ageing from Rush University**

Neuropathological indices	Fraction attributable % (95% CI) <sup>a</sup>
Alzheimer's disease (ADNC)	39.4 (31.5–47.4)
Vascular disease pathology <sup>b</sup>	24.8 (17.3–32.1)
<b>LATE-NC</b>	<b>17.3 (13.1–22.0)</b>
$\alpha$ -Synucleinopathy/Lewy body pathology	11.9 (8.4–15.6)

Shown are fractions of dementia of the Alzheimer type cases that were attributable to individual neuropathological indices in advanced age. In this sample, the mean age of death was 89.7 years (SD 6.5 years, range 65–108 years). For these analyses, multi-variable logistic regression models examined associations of neuropathological indices with the outcome of Alzheimer's-type clinical dementia and quantified the percentage of cases attributable to each. Methods have been described in detail previously (Boyle *et al.*, 2019). These data give strong indication that the public health impact of LATE is large, on the same order of magnitude as ADNC, vascular pathologies, and Lewy body pathology.

<sup>a</sup>95% CIs were derived using bootstrapping.

<sup>b</sup>Vascular pathologies included: cerebral amyloid angiopathy, atherosclerosis, arterio-sclerosis and gross infarcts.

relevant current data were derived from autopsy cohorts, the prevalence of LATE-NC may be higher in younger subjects than currently recognized if there is a survival bias (those with LATE-NC live to older ages), underscoring the need for more longitudinal studies that incorporate clinical biomarkers. Since the demographic group made up of subjects past 85 years of age is predicted to greatly expand in the coming decades (Gardner *et al.*, 2013; Nelson *et al.*, 2013), LATE is likely to become a far greater public health burden in the future unless preventative or therapeutic strategies are developed.

## Genetics of LATE

Genetic studies provide insights into disease-related mechanisms and, potentially, future therapeutic targets. The following five genes (in the chronological order in which they were identified) have been reported to harbour risk alleles associated with pathological manifestations we refer to as LATE-NC: granulin (*GRN*) on chromosome 17q, transmembrane protein 106B (*TMEM106B*) on chromosome 7p, ATP-binding cassette sub-family member 9 (*ABCC9*) on chromosome 12p, potassium channel subfamily M regulatory beta subunit 2 (*KCNMB2*) on chromosome 3q, and apolipoprotein E (*APOE*) on chromosome 19q (Dickson *et al.*, 2010; Pao *et al.*, 2011; Beecham *et al.*, 2014; Murray *et al.*, 2014; Nelson *et al.*, 2014, 2015b; Aoki *et al.*, 2015; Katsumata *et al.*, 2017; Yang *et al.*, 2018). See Supplementary Table 1 for summary information on these genes and their associated phenotypes. For this discussion, we include the endophenotype that was used in the published research (usually hippocampal sclerosis) rather than LATE-NC.

Gene variants in *GRN* and *TMEM106B* were shown to be associated with hippocampal sclerosis and TDP-43

proteinopathy risk using allele tests, based on the known relationship of those two genes to FTLT-TDP (Baker *et al.*, 2006; Boeve *et al.*, 2006; Cruts *et al.*, 2006; Van Deerlin *et al.*, 2010). These gene variants have now been most consistently associated with risk of LATE-NC. For the association between the *GRN* and hippocampal sclerosis, Dickson *et al.* showed that hippocampal sclerosis in aged subjects was associated with the T-allele of the *GRN* single nucleotide polymorphism (SNP) rs5848 (Dickson *et al.*, 2010; Murray *et al.*, 2014). Aoki and colleagues reported that the frequency of the C-allele of *TMEM106B* rs1990622 in hippocampal sclerosis was lower than that in non-hippocampal sclerosis controls (Aoki *et al.*, 2015). Following the initial studies, the findings were replicated of increased risk for hippocampal sclerosis associated with each copy of the T-allele of *TMEM106B* rs1990622 (Nelson *et al.*, 2014, 2015b; Dickson *et al.*, 2015; Yu *et al.*, 2015).

Since *GRN* and *TMEM106B* were both implicated in FTLT-TDP, their strong association with LATE-NC provides compelling evidence for pathogenetic overlap between FTLT-TDP and LATE. From a mechanistic perspective, the cognate proteins for these genes have been shown to play important roles in endosomal/lysosomal biology, and there is experimental evidence for interaction of these gene products (Chen-Plotkin *et al.*, 2012; Nicholson and Rademakers, 2016; Klein *et al.*, 2017; Zhou *et al.*, 2017; Paushter *et al.*, 2018). The *TMEM106B* gene appears to be pleiotropic for multiple diseases (Gallagher *et al.*, 2014; Ou *et al.*, 2015; Hsiao *et al.*, 2017; Cherry *et al.*, 2018; Chornenkyy *et al.*, 2019), and the LATE-NC risk allele in *TMEM106B* may influence healthy brain ageing (Rhinn and Abeliovich, 2017; Ren *et al.*, 2018). Separate studies have found that *GRN* gene products (granulins) play roles in inflammation and wound repair (Ahmed *et al.*, 2007; Miller *et al.*, 2013). Notably, the *GRN* risk variant rs5848 has been associated with increased inflammatory mediators in CSF (e.g. AXL and CLU) (Fardo *et al.*, 2017). More work is required to enable better understanding of how molecular pathways relevant to FTLT-TDP are involved in LATE.

An important recent finding by several different groups is that the *APOE*  $\epsilon$ 4 allele, which is a risk factor for ADNC and Lewy body disease, is also associated with increased risk for TDP-43 proteinopathy in the elderly (Robinson *et al.*, 2018c; Wennberg *et al.*, 2018; Yang *et al.*, 2018). Other studies did not find an association between *APOE* genotypes and risk for hippocampal sclerosis (Troncoso *et al.*, 1996; Leverenz *et al.*, 2002; Nelson *et al.*, 2011b; Pao *et al.*, 2011; Brenowitz *et al.*, 2014; Hall *et al.*, 2019; but see Farfel *et al.*, 2016). Few subjects with the *APOE*  $\epsilon$ 4 allele survive into advanced old age without any amyloid- $\beta$  plaques (Saunders *et al.*, 1993; Schmechel *et al.*, 1993), and it remains to be seen exactly how the *APOE*  $\epsilon$ 4 protein influences TDP-43 proteinopathy. Nevertheless, recent studies from large research cohorts have provided additional insights into the presence of pathogenetic mechanisms that are shared between neurodegenerative diseases.

Since the presence or absence of risk alleles in *TMEM106B*, *GRN*, and *APOE* cannot by themselves or in combination confidently predict the risk for LATE-NC in a given subjects (Katsumata *et al.*, 2017; Nelson *et al.*, 2019), there must be other factors that influence the disease phenotype. The connections of the *ABCC9* and *KCNMB2* genes with risk of LATE-NC were discovered via genome-wide association studies (GWAS), which are neither helped nor biased by prior mechanistic hypotheses. The finding of the associations between *ABCC9* gene variants and LATE-NC (Nelson *et al.*, 2015*b*), and brain atrophy detected with MRI (Nho *et al.*, 2016), were reported in separate samples from the initial GWAS (Nelson *et al.*, 2014). Neither *ABCC9* nor *KCNMB2* gene variants were associated with LATE-NC in cohorts other than those described above. *ABCC9* and *KCNMB2* are genes coding for proteins that serve to regulate potassium channels (Zarei *et al.*, 2007; Nelson *et al.*, 2015*a*). The *ABCC9* risk genotype also implicates thyroid hormone dysregulation in LATE-NC; the locus was found to be associated with altered brain expression of genes induced by thyroid hormone (Nelson *et al.*, 2016*a*). Thyroid hormones have been found to be dysregulated in subjects with autopsy-confirmed LATE-NC in recent studies (Trieu *et al.*, 2018; Nelson *et al.*, 2019), and high thyrotropin was associated with reduced hippocampal volume in a population-based study (Ittermann *et al.*, 2018). A gene variant near *ABCC9*, which lies within both the *SLCO1A2* and *IAPP* genes, was also found in a GWAS study to be associated with neurodegeneration disproportional to amyloid- $\beta$  accumulation (Roostaei *et al.*, 2016), which may indicate LATE in those cases. The *KCNMB2* gene has been associated with suicidal ideation in US military veterans (Kimbrel *et al.*, 2018) and may be related to depression, which is common in the elderly. Further, when *KCNMB2* is over-expressed in the hippocampus of mice, it rescues memory deficits (Yu *et al.*, 2018). More work is required to enable better understanding and identification of the molecular pathways involved in LATE.

Prior genetic studies on TDP-43 proteinopathy and hippocampal sclerosis have varied in important ways, including patient inclusion/exclusion criteria, disease definitions, and age composition, which may explain their differing findings with regard to genotype/phenotype associations. The prospects for successful future genetic discoveries will be improved by the development of specific and standardized LATE-NC endophenotypes. FTL-D-TDP provides an example in which pathological subtyping of patients has been beneficial for genetic correlation studies: there are, for example, strong associations between *TMEM106B* and *GRN* gene variants with FTL-D-TDP type A pathology (Rademakers *et al.*, 2008; Aoki *et al.*, 2015). Preliminary studies suggest that distinguishing morphology of TDP-43 pathology in LATE-NC may also be relevant to genetic risk (Josephs *et al.*, 2019). We speculate that genetic profiling may eventually become a key consideration for recruitment to clinical trials, and possible future precision medicine

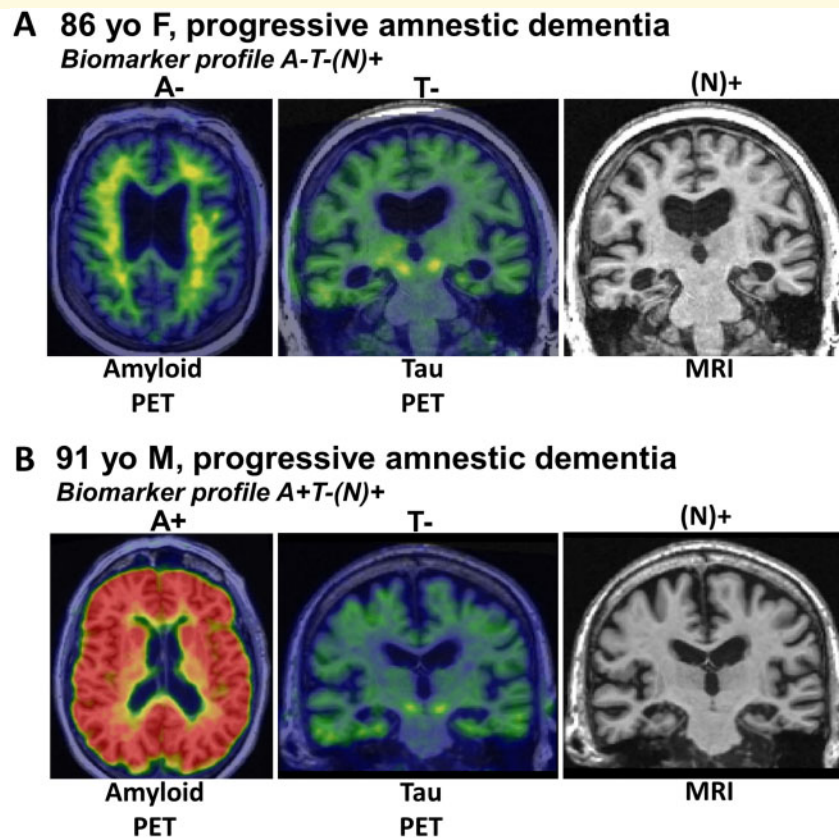
approaches, since some genotypes may be differentially responsive to specific interventions.

## LATE biomarkers

Optimal biomarkers for LATE, including biofluids or PET ligands, would be specific for the disease-defining feature, namely TDP-43 proteinopathy (Steinacker *et al.*, 2018). At this time, no biofluid or PET biomarker satisfies this essential criterion of molecular specificity. Nor do PET ligands for LATE seem to be on the near-term horizon. The problems of intracellular location and small pathological burden of TDP-43 proteinopathy are obstacles that limit signal-to-noise ratio for biomarkers.

The NIA-AA Research Framework group recommended a system for classifying subjects based on amyloid- $\beta$  amyloid (A), tau (T) and neurodegeneration/neuronal injury (N) biomarkers, which is termed AT(N) (Burnham *et al.*, 2016; Jack *et al.*, 2016). Each biomarker category can be binarized as positive (+) or negative (–) resulting in eight possible biomarker profiles. Certain AT(N) profiles indicate increased likelihood that LATE-NC might be present. The ‘N’ in AT(N) is in parentheses to indicate that it represents cumulative brain injury/neurodegeneration from all aetiologies and is not specific for any one aetiology. An assumption is that in Alzheimer’s disease, neurodegeneration is associated with tauopathy, and therefore in an A+T–(N)+ subject, the N+ is likely due to a comorbid non-Alzheimer’s disease pathophysiological process(es). If (N)+ is ascertained by an imaging measure that captures neurodegeneration as reflected medial temporal atrophy or hypometabolism, then this implicates LATE (often with hippocampal sclerosis) as a likely non-Alzheimer’s disease comorbidity. Similar logic applies to subjects with an A–T–(N)+ profile, the N+ is presumably due to a non-Alzheimer’s disease pathological process(es), and if the (N)+ measure is hippocampal atrophy, or medial temporal hypometabolism, then LATE is implicated (Fig. 5).

SNAP is a non-specific biomarker-defined category that affects ~15–30% of subjects in prior clinical series (Jack *et al.*, 2012; Vos *et al.*, 2013; Wisse *et al.*, 2015; Burnham *et al.*, 2016; Gordon *et al.*, 2016), and includes a variety of non-Alzheimer’s disease aetiologies, but prominent among these is LATE. Autopsy studies indicate that LATE-NC can exist without other brain pathologies, but commonly co-occurs with ADNC (Jellinger, 2000; Attems and Jellinger, 2006; Josephs *et al.*, 2014*b*, 2015, 2016); biomarker studies are consistent with those results. Botha *et al.* (2018) have shown that tau-PET-negative dementia can mimic Alzheimer’s disease clinically, suggesting that LATE is probably a common cause of tau-negative dementia. Further, a fluorodeoxyglucose (FDG) PET measure (the ratio of inferior to medial temporal metabolism) was elevated in autopsy proven LATE with hippocampal sclerosis compared to autopsy proven Alzheimer’s disease cases lacking LATE-NC (Botha *et al.*, 2018). LATE-NC was confirmed at autopsy in two subjects with tau-PET-negative



**Figure 5 Biomarkers are currently not specific to LATE-NC.** (A) Radiological scans from an 86-year-old female who suffered amnesic cognitive impairment compatible with ‘Probable Alzheimer’s disease’ diagnosis. However, the amyloid- $\beta$  PET scan was negative, tau PET scan was also negative, and the MRI showed appreciable atrophy of the medial temporal lobes bilaterally. This combination is considered ‘A–T–N+’ and was diagnosed during life as ‘suspected non-Alzheimer’s pathology’ (SNAP). Autopsy within a year of the brain scans confirmed the presence of TDP-43 pathology and hippocampal sclerosis, which now is diagnosable as LATE-NC. (B) Another common biomarker combination, in the brain of a 91-year-old male with dementia. In this subject, the amyloid PET scan was positive, yet the tau PET scan was negative. The MRI again showed atrophy of the medial temporal lobes. The combination of pathologies—in this case presumed early ADNC and comorbid LATE-NC—is common, especially in the brains of subjects in advanced age.

scans who both had elevated inferior to medial temporal FDG metabolism ratios. These data are compatible with the hypothesis that cognitively impaired tau-PET-negative subjects with marked medial temporal hypometabolism are likely to have LATE-NC. Other studies correlating autopsy findings with post-mortem magnetic resonance measures of regional tissue  $T_2$  relaxation times (Dawe *et al.*, 2014), hippocampal shape (Dawe *et al.*, 2011), and regional cortical volume measures (Kotrotsou *et al.*, 2015) indicate that neuroimaging signatures of ADNC and LATE-NC may differ (see above). The shape differences in the medial temporal lobes associated with LATE-NC versus ADNC provide potential imaging biomarkers of LATE (Dawe *et al.*, 2011; Makinejad *et al.*, 2019), whereas the evaluation of multiple brain regions is warranted as demonstrated in Fig. 3.

A non-specific biomarker of cumulative brain injury (N) may be useful in the context of LATE. If a biomarker for LATE is not forthcoming, then a quantitative *in vivo* indicator might remain the difference between the magnitude of

an observed (N) biomarker minus the predicted (N) value given the results of all other known biomarkers. A predictive (but not diagnostic) LATE measure could be envisioned as the ‘residual of the regression’ of expected on observed medial/basal temporal neurodegeneration, given all knowable information about other pathological processes. Recent studies indicate that neurofilament light chain (NfL) might be a preferred biofluid (N) biomarker (Zetterberg, 2016; Kortvelyessy *et al.*, 2018) but perturbation of NfL in LATE (plasma or CSF) remains to be tested. Moreover, elevated levels of NfL occur in many different causes of brain injury so NfL lacks disease specificity.

Although no specific LATE biomarker exists at present, the AT(N) system was designed explicitly to enable expansion to incorporate new biomarkers in categories beyond AT(N) (Jack *et al.*, 2018). If or when a biomarker of LATE is validated, AT(N) could be expanded to ATL(N), where ‘L’ stands for LATE. The ultimate objective would be comprehensive characterization of many relevant brain



pathologies *in vivo* using combinations of biomarkers. Future diagnostic biomarkers may be less centred on ADNC, and able to incorporate the common combinations of diseases that occur in ageing brain better. This concept is illustrated in Supplementary Table 2.

If a specific biomarker for LATE is developed, this may complement ongoing efforts to develop an optimal neuropathological assessment. LATE-NC may in the future be assessed along three dimensions: stage (i.e. anatomical distribution); subtype (i.e. differing histopathological patterns in a given region); and grade (i.e. severity or pathological load). While systems for subtyping or grading LATE-NC have yet to be validated, these may in the future be useful for early diagnosis, improved clinical prognosis, and development of new strategies to treat or prevent the disease.

## Implications for Alzheimer's disease and LATE clinical trials

Formalization of LATE diagnostic criteria and increased awareness of this disease should help guide the design and interpretation of Alzheimer's disease clinical trials. Comorbid ADNC and LATE-NC becomes increasingly more prevalent with advancing age, and the mechanisms underlying each of these common lesions have independent effects on cognitive performance (Nelson *et al.*, 2010). LATE-NC, when coexisting with ADNC, will have the potential to obscure the effects of a potential disease modifying agent on cognitive assessment results in living subjects. The primary outcome measures in disease-modifying Alzheimer's disease clinical trials will remain cognitive or functional scales for the foreseeable future (Cummings *et al.*, 2016; Register, 2018). Thus, the presence of LATE-NC will complicate interpretation of Alzheimer's disease-specific treatment effects that are inferred from observed cognitive outcomes. Until there are biomarkers for LATE, clinical trials should be powered to account for TDP-43 proteinopathy.

LATE is among the common age-related diseases that can mimic the amnesic presentation of Alzheimer's disease (Nelson *et al.*, 2013), and it is one of many reasons why biological rather than clinical disease definitions are important in the era of disease modifying clinical trials (Jack *et al.*, 2018). Biomarkers have roles for both inclusion and exclusion. It will be important, at recruitment of subjects into future disease-modifying Alzheimer's disease clinical trials, to stratify according to major known predictors, including clinical features, genetics, and known biomarkers. This stratification will enable enrichment for subjects on the ADNC continuum (Sevigny *et al.*, 2016) while excluding subjects likely to have high risk for LATE-NC (Botha *et al.*, 2018). Even with best efforts at baseline, the multiplicity of diseases that occur in brains of older subjects will still require analyses according to subgroups. This is another reason why clinical trials in dementing diseases of ageing will require large sample sizes.

Research into Alzheimer's disease has provided additional topical caveats (Gulisano *et al.*, 2018; Hunter *et al.*, 2018; Morris *et al.*, 2018). For example, there is a danger that we fundamentally misunderstand the nature and complexity of processes related to TDP-43 proteinopathy, and this could lead to significant biases in the ways that we approach clinical diagnosis and clinical trials of LATE. For now, as with Alzheimer's disease, the misfolded proteins provide a disease marker and a potential target for therapies.

Clinical trials directed at preventing or treating LATE, in isolation or in concert with other brain diseases, should be a major direction for future research. Performing such trials optimally will first require development of a specific LATE biomarker. For now, five alternative, but not mutually exclusive, approaches exist for developing disease-modifying therapies: (i) focus on pathways and gene products such as *APOE*  $\epsilon$ 4 that seem to be in common between Alzheimer's disease, Lewy body disease, and LATE; (ii) focus on pathways and gene products such as *TMEM106B* and *GRN* that are shared between FTLTDP and LATE; (iii) focus on pathways and gene products such as *ABCC9* and *KCNMB2* that have been implicated by GWAS; (iv) focus on potential research subjects with the A–T–(N+) biomarker profile, who are now excluded from many Alzheimer's disease-related clinical trials; and/or (v) focus on strategies to eliminate TDP-43 aggregates or to prevent the formation of these aggregates.

## Conclusions and future directions

A key goal of this working group effort was to catalyse future research on LATE, an under-recognized condition that affects many older subjects. It is important to promote awareness in multiple scientific areas and to focus on translational and interdisciplinary approaches.

Development of specific LATE biomarker(s) should be a high scientific priority. While a sensitive and specific biomarker using neuroimaging or biofluids would be ideal, other disease markers could capitalize on existing metrics such as the AT(N) research guidelines with or without imaging or biofluid risk profiling. Developing biomarkers or other criteria to identify subjects with LATE would augment observational studies that seek to unravel the natural history of LATE, and its coevolution with other ageing-related diseases. With sufficient longitudinal observations, cause and effect inferences may become possible, and clinical trials implemented.

Further pathology studies will also be necessary. The consensus pathological classification scheme that we propose should be considered preliminary because much remains to be learned about LATE. The application of pathological subtyping has been useful in the context of FTLTDP (Lee *et al.*, 2017; Mackenzie and Neumann,

2017; Pottier *et al.*, 2018), and pathological subtyping may help refine LATE-NC endophenotypes for diagnostic and genetic studies (Josephs *et al.*, 2019). At this point, there is no consensus about how or whether to apply such criteria for LATE-NC. A detailed characterization of the molecular pathology of TDP-43 is required for different cell types across brain regions in large population-representative samples. This should include characterization of various phosphorylation states, cleavage fragments, and other post-translational modifications of TDP-43. Further, each anti-TDP-43 antibody used should be assessed for potential cross-reactivity with other proteins or LATE-NC features *in situ*. It will also be important to determine the prevalence of all co-pathologies associated with LATE-NC, the impact of the molecular conformations and modifications of TDP-43, the cellular types involved, and the natural history of the disease. These advances will also assist in developing animal models.

Additional epidemiological, clinical, neuroimaging, and genetic studies will be important to better characterize the public health impact and clinical phenotypes for LATE. Further, LATE must be studied in more diverse populations and cohorts. Careful clinical assessments over time and into the oldest age groups is essential, along with detailed biological measures and autopsy, so that the complexity of ageing changes can be assessed (Brayne, 1993). *In vivo* and *ex vivo* imaging studies to determine the focal and more diffuse changes in the brains of subjects with LATE will also be important. Future studies may generate better insights into the clinical indices and cognitive features that are associated with increased probability of LATE-NC. Risk factors, protective influences, and other correlates could thus be identified to help prevent or predict LATE. For example, autoimmune disease may play a role in TDP-43 proteinopathy and LATE-NC in particular (Miller *et al.*, 2013; Trieu *et al.*, 2018). Optimally, future studies will complement traditional GWAS and gene-focused analyses with multi-omics studies to capture a greater appreciation of the complex mechanisms and diagnostic or therapeutic opportunities in the study of LATE.

Animal models and basic science research into LATE are imperative, with the caveat that the aged human brain is challenging to model accurately. Functional studies, including transmission animal models that use TDP-43 fibrils (Porta *et al.*, 2018) or extracts from brains with LATE-NC injected into animals or cell cultures (Laferriere *et al.*, 2019), can be combined with genetic studies to test hypotheses and to add statistical power for preclinical and hypothesis-testing experiments. Molecular studies that focus on TDP-43 and the upstream triggers and downstream molecular consequences are necessary to elucidate mechanisms of disease. Models that account for co-pathologies are rare at present, but have the potential to be highly informative. Ultimately, it is hoped that these collective research efforts will one day result in successful preventative and therapeutic strategies.

## Acknowledgements

We sincerely thank the research volunteers, clinicians, staff, and other colleagues for their hard work. The LATE working group meeting organizational committee consisted of Drs Peter Nelson, Nina Silverberg, Dennis Dickson, Julie Schneider, John Trojanowski, and Helena Chui. The working group in-person meeting (October 17–18 in Atlanta, GA, USA) included most of the co-authors, and Drs Nina Silverberg, Eliezer Masliah, Cerise Elliott, and Linda Van Eldik attended and contributed. Statistical analyses in Figs 2 and 3 were performed by co-author Dr Lei Yu. Thanks to Dr Hannah Keage at the University of South Australia for editorial help.

## Funding

Direct support for meeting logistics was provided via a NIA/NACC grant (supplemental to the parent NIH grant U01 AG016976 to W.A.K.). Support from the National Health and Medical Research Council of Australia (NHMRC) included NHMRC Senior Principal Research Fellowship (1079679) and other NHMRC grants (1132524, 1095127, 1037746) to G.H. Grant support from U.S. National Institutes of Health included grants P01 AG003949 (D.W.D.), R01 AG037491 (D.W.D.), P50 AG016574 (D.W.D.), R01 AG054449 (M.E.M.), P30 AG028303 (P.T.N. and G.A.J.), P30 AG012300 (C.L.W.), P30 AG049638 (T.J.M.), P30 AG010124 (J.Q.T.), P30 AG010161 (K.A., J.A.S., P.A.B.), P50 AG047366 (T.J.M.), P50 AG025688 (A.I.L.), P50 AG005131 (R.A.R.), R37 AG011378 (C.R.J.), R01 AG041851 (C.R.J.), R01 AG042210 (J.A.S.), R01 AG017917 (J.A.S.), R01 AG034374 (P.A.B.), UF1 AG053983 (T.J.M.), UF1 AG057707 (T.J.M.). UK grants included ARUK-PhD2014–19, and NIHR Senior Investigators award Ref: 534906 NF-SI-0616–10090 to co-author C.B. National Institute for Health Research, Senior Investigator Award, was awarded to C.B. for C.B. and S.H. The views expressed are those of the authors and not necessarily those of the NHS, the NIHR or the Department of Health and Social Care. S.H. is supported by the Addenbrooke's Charitable Trust, the Paul G. Allen Family Foundation and Alzheimer's Research, UK. S.R.K.H. is supported by Alzheimer's Research, UK. See Appendix 1 for additional acknowledgments.

## Competing interests

The authors report no competing interests.

## Supplementary material

Supplementary material is available at *Brain* online.

## Appendix I

### NACC data

We are extremely grateful to the many patients, clinicians, and other colleagues, who have worked so hard to provide and organize these data. The NACC database is funded by NIA/NIH Grant U01 AG016976. NACC data are contributed by the NIA-funded ADCs: P30 AG019610 (PI Eric Reiman, MD), P30 AG013846 (PI Neil Kowall, MD), P50 AG008702 (PI Scott Small, MD), P50 AG025688 (PI Allan Levey, MD, PhD), P50 AG047266 (PI Todd Golde, MD, PhD), P30 AG010133 (PI Andrew Saykin, PsyD), P50 AG005146 (PI Marilyn Albert, PhD), P50 AG005134 (PI Bradley Hyman, MD, PhD), P50 AG016574 (PI Ronald Petersen, MD, PhD), P50 AG005138 (PI Mary Sano, PhD), P30 AG008051 (PI Thomas Wisniewski, MD), P30 AG013854 (PI M. Marsel Mesulam, MD), P30 AG008017 (PI Jeffrey Kaye, MD), P30 AG010161 (PI David Bennett, MD), P50 AG047366 (PI Victor Henderson, MD, MS), P30 AG010129 (PI Charles DeCarli, MD), P50 AG016573 (PI Frank LaFerla, PhD), P50 AG005131 (PI James Brewer, MD, PhD), P50 AG023501 (PI Bruce Miller, MD), P30 AG035982 (PI Russell Swerdlow, MD), P30 AG028383 (PI Linda Van Eldik, PhD), P30 AG053760 (PI Henry Paulson, MD, PhD), P30 AG010124 (PI John Trojanowski, MD, PhD), P50 AG005133 (PI Oscar Lopez, MD), P50 AG005142 (PI Helena Chui, MD), P30 AG012300 (PI Roger Rosenberg, MD), P30 AG049638 (PI Suzanne Craft, PhD), P50 AG005136 (PI Thomas Grabowski, MD), P50 AG033514 (PI Sanjay Asthana, MD, FRCP), P50 AG005681 (PI John Morris, MD), P50 AG047270 (PI Stephen Strittmatter, MD, PhD).

## References

- Abner EL, Kryscio RJ, Schmitt FA, Fardo DW, Moga DC, Ighodaro ET, et al. Outcomes after diagnosis of mild cognitive impairment in a large autopsy series. *Ann Neurol* 2017; 81: 549–59.
- Abner EL, Kryscio RJ, Schmitt FA, Santacruz KS, Jicha GA, Lin Y, et al. “End-Stage” neurofibrillary tangle pathology in preclinical Alzheimer’s disease: fact or fiction? *J Alzheimers Dis* 2011; 25: 445–53.
- Ahmed Z, Mackenzie IR, Hutton ML, Dickson DW. Progranulin in frontotemporal lobar degeneration and neuroinflammation. *J Neuroinflammation* 2007; 4: 7–20.
- Ajilore O, Lamar M, Medina J, Watari K, Elderkin-Thompson V, Kumar A. Disassociation of verbal learning and hippocampal volume in type 2 diabetes and major depression. *Int J Geriatr Psychiatry* 2015; 30: 393–9.
- Ala TA, Beh GO, Frey WH 2nd. Pure hippocampal sclerosis: a rare cause of dementia mimicking Alzheimer’s disease. *Neurology* 2000; 54: 843–8.
- Alafuzoff I, Ince PG, Arzberger T, Al-Sarraj S, Bell J, Bodi I, et al. Staging/typing of Lewy body related alpha-synuclein pathology: a study of the BrainNet Europe Consortium. *Acta Neuropathol* 2009; 117: 635–52.
- Alafuzoff I, Pikkarainen M, Neumann M, Arzberger T, Al-Sarraj S, Bodi I, et al. Neuropathological assessments of the pathology in frontotemporal lobar degeneration with TDP43-positive inclusions: an inter-laboratory study by the BrainNet Europe consortium. *J Neural Transm (Vienna)* 2015; 122: 957–72.
- Amador-Ortiz C, Ahmed Z, Zehr C, Dickson DW. Hippocampal sclerosis dementia differs from hippocampal sclerosis in frontal lobe degeneration. *Acta Neuropathol (Berl)* 2007a; 113: 245–52.
- Amador-Ortiz C, Dickson DW. Neuropathology of hippocampal sclerosis. *Handb Clin Neurol* 2008; 89: 569–72.
- Amador-Ortiz C, Lin WL, Ahmed Z, Personett D, Davies P, Duara R, et al. TDP-43 immunoreactivity in hippocampal sclerosis and Alzheimer’s disease. *Ann Neurol* 2007b; 61: 435–45.
- Aoki N, Murray ME, Ogaki K, Fujioka S, Rutherford NJ, Rademakers R, et al. Hippocampal sclerosis in Lewy body disease is a TDP-43 proteinopathy similar to FTLD-TDP type A. *Acta Neuropathol* 2015; 129: 53–64.
- Arai T, Hasegawa M, Nonoka T, Kametani F, Yamashita M, Hosokawa M, et al. Phosphorylated and cleaved TDP-43 in ALS, FTLD and other neurodegenerative disorders and in cellular models of TDP-43 proteinopathy. *Neuropathology* 2010; 30: 170–81.
- Arai T, Mackenzie IR, Hasegawa M, Nonoka T, Niizato K, Tsuchiya K, et al. Phosphorylated TDP-43 in Alzheimer’s disease and dementia with Lewy bodies. *Acta Neuropathol* 2009; 117: 125–36.
- Arnold SJ, Dugger BN, Beach TG. TDP-43 deposition in prospectively followed, cognitively normal elderly individuals: correlation with argyrophilic grains but not other concomitant pathologies. *Acta Neuropathol* 2013; 126: 51–7.
- Attems J, Jellinger KA. Hippocampal sclerosis in Alzheimer disease and other dementias. *Neurology* 2006; 66: 775.
- Bachstetter AD, Van Eldik LJ, Schmitt FA, Neltner JH, Ighodaro ET, Webster SJ, et al. Disease-related microglia heterogeneity in the hippocampus of Alzheimer’s disease, dementia with Lewy bodies, and hippocampal sclerosis of aging. *Acta Neuropathol Commun* 2015; 3: 32.
- Baker M, Mackenzie IR, Pickering-Brown SM, Gass J, Rademakers R, Lindholm C, et al. Mutations in progranulin cause tau-negative frontotemporal dementia linked to chromosome 17. *Nature* 2006; 442: 916–9.
- Barker WW, Luis CA, Kashuba A, Luis M, Harwood DG, Loewenstein D, et al. Relative frequencies of Alzheimer disease, Lewy body, vascular and frontotemporal dementia, and hippocampal sclerosis in the State of Florida Brain Bank. *Alzheimer Dis Assoc Disord* 2002; 16: 203–12.
- Barkhof F, Polvikoski TM, van Straaten EC, Kalaria RN, Sulkava R, Aronen HJ, et al. The significance of medial temporal lobe atrophy: a postmortem MRI study in the very old. *Neurology* 2007; 69: 1521–7.
- Beecham GW, Hamilton K, Naj AC, Martin ER, Huentelman M, Myers AJ, et al. Genome-wide association meta-analysis of neuropathologic features of Alzheimer’s disease and related dementias. *PLoS Genet* 2014; 10: e1004606.
- Bennett DA, Schneider JA, Arvanitakis Z, Kelly JF, Aggarwal NT, Shah RC, et al. Neuropathology of older persons without cognitive impairment from two community-based studies. *Neurology* 2006; 66: 1837–44.
- Besser LM, Kukull WA, Teylan MA, Bigio EH, Cairns NJ, Kofler JK, et al. The revised national Alzheimer’s coordinating center’s neuropathology form-available data and new analyses. *J Neuropathol Exp Neurol* 2018; 77: 717–26.
- Blessed G, Tomlinson BE, Roth M. The association between quantitative measures of dementia and of senile change in the cerebral grey matter of elderly subjects. *Br J Psychiatry* 1968; 114: 797–811.
- Boeve BF, Baker M, Dickson DW, Parisi JE, Giannini C, Josephs KA, et al. Frontotemporal dementia and parkinsonism associated with the IVS1+1G->A mutation in progranulin: a clinicopathologic study. *Brain* 2006; 129: 3103–14.

- Botha H, Mantyh WG, Murray ME, Knopman DS, Przybelski SA, Wiste HJ, et al. FDG-PET in tau-negative amnesic dementia resembles that of autopsy-proven hippocampal sclerosis. *Brain* 2018; 141: 1201–17.
- Boyle PA, Wilson RS, Yu L, Barr AM, Honer WG, Schneider JA, et al. Much of late life cognitive decline is not due to common neurodegenerative pathologies. *Ann Neurol* 2013; 74: 478–89.
- Boyle PA, Yang J, Yu L, Leurgans SE, Capuano AW, Schneider JA, et al. Varied effects of age-related neuropathologies on the trajectory of late life cognitive decline. *Brain* 2017; 140: 804–12.
- Boyle PA, Yu L, Leurgans SE, Wilson RS, Brookmeyer R, Schneider JA, et al. Attributable risk of Alzheimer's dementia due to age-related neuropathologies. *Ann Neurol* 2019; 85: 114–24.
- Braak H, Braak E, Bohl J. Staging of Alzheimer-related cortical destruction. *Eur Neurol* 1993; 33: 403–8.
- Braak H, Del Tredici K. Anterior cingulate cortex TDP-43 pathology in sporadic amyotrophic lateral sclerosis. *J Neuropathol Exp Neurol* 2018; 77: 74–83.
- Braak H, Ludolph AC, Neumann M, Ravits J, Del Tredici K. Pathological TDP-43 changes in Betz cells differ from those in bulbar and spinal alpha-motoneurons in sporadic amyotrophic lateral sclerosis. *Acta Neuropathol* 2017; 133: 79–90.
- Braak H, Muller CM, Rub U, Ackermann H, Bratzke H, de Vos RA, et al. Pathology associated with sporadic Parkinson's disease—where does it end? *J Neural Transm Suppl* 2006: 89–97.
- Braak H, Thal DR, Ghebremedhin E, Del Tredici K. Stages of the pathologic process in Alzheimer disease: age categories from 1 to 100 years. *J Neuropathol Exp Neurol* 2011; 70: 960–9.
- Brayne C. Research and Alzheimer's disease: an epidemiological perspective. *Psychol Med* 1993; 23: 287–96.
- Brayne C, Richardson K, Matthews FE, Fleming J, Hunter S, Xuereb JH, et al. Neuropathological correlates of dementia in over-80-year-old brain donors from the population-based Cambridge city over-75s cohort (CC75C) study. *J Alzheimers Dis* 2009; 18: 645–58.
- Brenowitz WD, Monsell SE, Schmitt FA, Kukull WA, Nelson PT. Hippocampal sclerosis of aging is a key Alzheimer's disease mimic: clinical-pathologic correlations and comparisons with both Alzheimer's disease and non-tauopathic frontotemporal lobar degeneration. *J Alzheimers Dis* 2014; 39: 691–702.
- Brettschneider J, Del Tredici K, Toledo JB, Robinson JL, Irwin DJ, Grossman M, et al. Stages of pTDP-43 pathology in amyotrophic lateral sclerosis. *Ann Neurol* 2013; 74: 20–38.
- Bruzzi P, Green SB, Byar DP, Brinton LA, Schairer C. Estimating the population attributable risk for multiple risk factors using case-control data. *Am J Epidemiol* 1985; 122: 904–14.
- Burnham SC, Bourgeat P, Dore V, Savage G, Brown B, Laws S, et al. Clinical and cognitive trajectories in cognitively healthy elderly individuals with suspected non-Alzheimer's disease pathophysiology (SNAP) or Alzheimer's disease pathology: a longitudinal study. *Lancet Neurol* 2016; 15: 1044–53.
- Cairns NJ, Bigio EH, Mackenzie IR, Neumann M, Lee VM, Hatanpaa KJ, et al. Neuropathologic diagnostic and nosologic criteria for frontotemporal lobar degeneration: consensus of the Consortium for Frontotemporal Lobar Degeneration. *Acta Neuropathol (Berl)* 2007a; 114: 5–22.
- Cairns NJ, Neumann M, Bigio EH, Holm IE, Troost D, Hatanpaa KJ, et al. TDP-43 in familial and sporadic frontotemporal lobar degeneration with ubiquitin inclusions. *Am J Pathol* 2007b; 171: 227–40.
- Caroli A, Prestia A, Galluzzi S, Ferrari C, van der Flier WM, Ossenkoppele R, et al. Mild cognitive impairment with suspected nonamyloid pathology (SNAP): prediction of progression. *Neurology* 2015; 84: 508–15.
- Chen-Plotkin AS, Unger TL, Gallagher MD, Bill E, Kwong LK, Volpicelli-Daley L, et al. TMEM106B, the risk gene for frontotemporal dementia, is regulated by the microRNA-132/212 cluster and affects progranulin pathways. *J Neurosci* 2012; 32: 11213–27.
- Cherry JD, Mez J, Crary JF, Tripodis Y, Alvarez VE, Mahar I, et al. Variation in TMEM106B in chronic traumatic encephalopathy. *Acta Neuropathol Commun* 2018; 6: 115.
- Chornenkyy Y, Fardo DW, Nelson PT. Tau and TDP-43 proteinopathies: kindred pathologic cascades and genetic pleiotropy. *Lab Invest* 2019. doi: 10.1038/s41374-019-0196-y.
- Chui HC, Zarow C, Mack WJ, Ellis WG, Zheng L, Jagust WJ, et al. Cognitive impact of subcortical vascular and Alzheimer's disease pathology. *Ann Neurol* 2006; 60: 677–87.
- Cohen TJ, Lee VM, Trojanowski JQ. TDP-43 functions and pathogenic mechanisms implicated in TDP-43 proteinopathies. *Trends Mol Med* 2011; 17: 659–67.
- Corrada MM, Berlau DJ, Kawas CH. A population-based clinicopathological study in the oldest-old: the 90+ study. *Curr Alzheimer Res* 2012; 9: 709–17.
- Coyle-Gilchrist IT, Dick KM, Patterson K, Vazquez Rodriguez P, Wehmann E, Wilcox A, et al. Prevalence, characteristics, and survival of frontotemporal lobar degeneration syndromes. *Neurology* 2016; 86: 1736–43.
- Crary JF, Trojanowski JQ, Schneider JA, Abisambra JF, Abner EL, Alafuzoff I, et al. Primary age-related tauopathy (PART): a common pathology associated with human aging. *Acta Neuropathol* 2014; 128: 755–66.
- Cruts M, Gijssels I, van der Zee J, Engelborghs S, Wils H, Pirici D, et al. Null mutations in progranulin cause ubiquitin-positive frontotemporal dementia linked to chromosome 17q21. *Nature* 2006; 442: 920–4.
- Crystal HA, Dickson D, Davies P, Masur D, Grober E, Lipton RB. The relative frequency of “dementia of unknown etiology” increases with age and is nearly 50% in nonagenarians. *Arch Neurol* 2000; 57: 713–9.
- Crystal HA, Dickson DW, Sliwinski MJ, Lipton RB, Grober E, Marks-Nelson H, et al. Pathological markers associated with normal aging and dementia in the elderly. *Ann Neurol* 1993; 34: 566–73.
- Cummings J, Aisen PS, DuBois B, Frolich L, Jack CR Jr, Jones RW, et al. Drug development in Alzheimer's disease: the path to 2025. *Alzheimers Res Ther* 2016; 8: 39.
- Cykowski MD, Powell SZ, Schulz PE, Takei H, Rivera AL, Jackson RE, et al. Hippocampal sclerosis in older patients: practical examples and guidance with a focus on cerebral age-related TDP-43 with sclerosis. *Arch Pathol Lab Med* 2017; 141: 1113–26.
- Cykowski MD, Takei H, Van Eldik LJ, Schmitt FA, Jicha GA, Powell SZ, et al. Hippocampal sclerosis but not normal aging or Alzheimer disease is associated with TDP-43 pathology in the basal forebrain of aged persons. *J Neuropathol Exp Neurol* 2016; 75: 397–407.
- Dallaire-Theroux C, Callahan BL, Potvin O, Saikali S, Duchesne S. Radiological-pathological correlation in Alzheimer's disease: Systematic review of antemortem magnetic resonance imaging findings. *J Alzheimers Dis* 2017; 57: 575–601.
- Davidson YS, Raby S, Foulds PG, Robinson A, Thompson JC, Sikkink S, et al. TDP-43 pathological changes in early onset familial and sporadic Alzheimer's disease, late onset Alzheimer's disease and Down's syndrome: association with age, hippocampal sclerosis and clinical phenotype. *Acta Neuropathol* 2011; 122: 703–13.
- Davis SA, Gan KA, Dowell JA, Cairns NJ, Gitcho MA. TDP-43 expression influences amyloid-beta plaque deposition and tau aggregation. *Neurobiol Dis* 2017; 103: 154–62.
- Dawe RJ, Bennett DA, Schneider JA, Arfanakis K. Neuropathologic correlates of hippocampal atrophy in the elderly: a clinical, pathologic, postmortem MRI study. *PLoS ONE* 2011; 6: e26286.
- Dawe RJ, Bennett DA, Schneider JA, Leurgans SE, Kotrotsou A, Boyle PA, et al. Ex vivo T2 relaxation: associations with age-related neuropathology and cognition. *Neurobiol Aging* 2014; 35: 1549–61.
- Dickson DW, Baker M, Rademakers R. Common variant in GRN is a genetic risk factor for hippocampal sclerosis in the elderly. *Neurodegener Dis* 2010; 7: 170–4.

- Dickson DW, Davies P, Bevona C, Van Hoeven KH, Factor SM, Grober E, et al. Hippocampal sclerosis: a common pathological feature of dementia in very old (> or =80 years of age) humans. *Acta Neuropathol* 1994; 88: 212–21.
- Dickson DW, Rademakers R, Nicholson AM, Schneider JA, Yu L, Bennett DA. The TMEM106B locus and TDP-43 pathology in older persons without FTL. *Neurology* 2015; 85: 1354–5.
- Dutra JR, Cortes EP, Vonsattel JP. Update on hippocampal sclerosis. *Curr Neurol Neurosci Rep* 2015; 15: 67.
- Elobeid A, Libard S, Leino M, Popova SN, Alafuzoff I. Altered proteins in the aging brain. *J Neuropathol Exp Neurol* 2016; 75: 316–25.
- Erten-Lyons D, Dodge HH, Woltjer R, Silbert LC, Howieson DB, Kramer P, et al. Neuropathologic basis of age-associated brain atrophy. *JAMA neurology* 2013; 70: 616–22.
- Fardo DW, Katsumata Y, Kauwe JS, Deming Y, Harari O, Cruchaga C, et al. CSF protein changes associated with hippocampal sclerosis risk gene variants highlight impact of GRN/PGRN. *Exp Gerontol* 2017; 90: 83–9.
- Farfel JM, Yu L, Buchman AS, Schneider JA, De Jager PL, Bennett DA. Relation of genomic variants for Alzheimer disease dementia to common neuropathologies. *Neurology* 2016; 87: 489–96.
- Fatima M, Tan R, Halliday GM, Kril JJ. Spread of pathology in amyotrophic lateral sclerosis: assessment of phosphorylated TDP-43 along axonal pathways. *Acta Neuropathol Commun* 2015; 3: 47.
- Fujishiro H, Uchikado H, Arai T, Hasegawa M, Akiyama H, Yokota O, et al. Accumulation of phosphorylated TDP-43 in brains of patients with argyrophilic grain disease. *Acta Neuropathol* 2009; 117: 151–8.
- Gallagher MD, Suh E, Grossman M, Elman L, McCluskey L, Van Swieten JC, et al. TMEM106B is a genetic modifier of frontotemporal lobar degeneration with C9orf72 hexanucleotide repeat expansions. *Acta Neuropathol* 2014; 127: 407–18.
- Gardner RC, Valcour V, Yaffe K. Dementia in the oldest old: a multifactorial and growing public health issue. *Alzheimers Res Ther* 2013; 5: 27.
- Geser F, Robinson JL, Malunda JA, Xie SX, Clark CM, Kwong LK, et al. Pathological 43-kDa transactivation response DNA-binding protein in older adults with and without severe mental illness. *Arch Neurol* 2010; 67: 1238–50.
- Giannakopoulos P, Bouras C, Hof PR. Clinicopathologic correlates in the oldest-old: commentary on “No disease in the brain of a 115-year-old woman”. *Neurobiol Aging* 2008; 29: 1137–9.
- Gold G, Bouras C, Kovari E, Canuto A, Glaria BG, Malky A, et al. Clinical validity of Braak neuropathological staging in the oldest-old. *Acta Neuropathol (Berl)* 2000; 99: 579–82; discussion 83–4.
- Gordon BA, Blazey T, Su Y, Fagan AM, Holtzman DM, Morris JC, et al. Longitudinal beta-amyloid deposition and hippocampal volume in preclinical Alzheimer disease and suspected non-Alzheimer disease pathophysiology. *JAMA Neurol* 2016; 73: 1192–200.
- Gulisano W, Maugeri D, Baltrons MA, Fa M, Amato A, Palmeri A, et al. Role of amyloid-beta and tau proteins in Alzheimer’s disease: confuting the amyloid cascade. *J Alzheimers Dis* 2018; 64: S611–31.
- Guo L, Shorter J. Biology and pathobiology of TDP-43 and emergent therapeutic strategies. *Cold Spring Harb Perspect Med* 2017; 7. doi: 10.1101/cshperspect.a024554.
- Hall A, Pekkala T, Polvikoski T, van Gils M, Kivipelto M, Lotjonen J, et al. Prediction models for dementia and neuropathology in the oldest old: the Vantaa 85+ cohort study. *Alzheimers Res Ther* 2019; 11: 11.
- Hanko V, Apple AC, Alpert KI, Warren KN, Schneider JA, Arfanakis K, et al. In vivo hippocampal subfield shape related to TDP-43, amyloid beta, and tau pathologies. *Neurobiol Aging* 2019; 74: 171–81.
- Hasegawa M, Arai T, Nonaka T, Kametani F, Yoshida M, Hashizume Y, et al. Phosphorylated TDP-43 in frontotemporal lobar degeneration and amyotrophic lateral sclerosis. *Ann Neurol* 2008; 64: 60–70.
- Hasegawa M, Nonaka T, Tsuji H, Tamaoka A, Yamashita M, Kametani F, et al. Molecular dissection of TDP-43 proteinopathies. *J Mol Neurosci* 2011; 45: 480–5.
- Hatanpaa KJ, Bigio EH, Cairns NJ, Womack KB, Weintraub S, Morris JC, et al. TAR DNA-binding protein 43 immunohistochemistry reveals extensive neuritic pathology in FTLD-U: a midwest-southwest consortium for FTLD study. *J Neuropathol Exp Neurol* 2008; 67: 271–9.
- Hatanpaa KJ, Raisanen JM, Herndon E, Burns DK, Foong C, Habib AA, et al. Hippocampal sclerosis in dementia, epilepsy, and ischemic injury: differential vulnerability of hippocampal subfields. *J Neuropathol Exp Neurol* 2014; 73: 136–42.
- Higashi S, Iseki E, Yamamoto R, Minegishi M, Hino H, Fujisawa K, et al. Concurrence of TDP-43, tau and alpha-synuclein pathology in brains of Alzheimer’s disease and dementia with Lewy bodies. *Brain Res* 2007; 1184: 284–94.
- Hokkanen SRK, Hunter S, Polvikoski TM, Keage HAD, Minett T, Matthews FE, et al. Hippocampal sclerosis, hippocampal neuron loss patterns and TDP-43 in the aged population. *Brain Pathol* 2018; 28: 548–59.
- Hsiao SJ, Karajannis MA, Diolaiti D, Mansukhani MM, Bender JG, Kung AL, et al. A novel, potentially targetable TMEM106B-BRAF fusion in pleomorphic xanthoastrocytoma. *Cold Spring Harb Mol Case Stud* 2017; 3: a001396.
- Hu WT, Josephs KA, Knopman DS, Boeve BF, Dickson DW, Petersen RC, et al. Temporal lobar predominance of TDP-43 neuronal cytoplasmic inclusions in Alzheimer disease. *Acta Neuropathol* 2008; 116: 215–20.
- Hunter S, Smailagic N, Brayne C. Abeta and the dementia syndrome: simple versus complex perspectives. *Eur J Clin Invest* 2018; 48: e13025.
- Ighodaro ET, Jicha GA, Schmitt FA, Neltner JH, Abner EL, Kryscio RJ, et al. Hippocampal sclerosis of aging can be segmental: two cases and review of the literature. *J Neuropathol Exp Neurol* 2015; 74: 642–52.
- Imhof A, Kovari E, von Gunten A, Gold G, Rivara CB, Herrmann FR, et al. Morphological substrates of cognitive decline in nonagenarians and centenarians: a new paradigm? *J Neurol Sci* 2007; 257: 72–9.
- Irwin DJ, McMillan CT, Xie SX, Rascovsky K, Van Deerlin VM, Coslett HB, et al. Asymmetry of post-mortem neuropathology in behavioural-variant frontotemporal dementia. *Brain* 2018; 141: 288–301.
- Isnard J, Bourdillon P. Morphological imaging of the hippocampus in epilepsy. *Rev Neurol (Paris)* 2015; 171: 298–306.
- Ittermann T, Wittfeld K, Nauck M, Bulow R, Hosten N, Volzke H, et al. High thyrotropin is associated with reduced hippocampal volume in a population-based study from Germany. *Thyroid* 2018; 28: 1434–42.
- Jack CR Jr, Bennett DA, Blennow K, Carrillo MC, Dunn B, Haeberlein SB, et al. NIA-AA Research Framework: toward a biological definition of Alzheimer’s disease. *Alzheimers Dement* 2018; 14: 535–62.
- Jack CR Jr, Dickson DW, Parisi JE, Xu YC, Cha RH, O’Brien PC, et al. Antemortem MRI findings correlate with hippocampal neuropathology in typical aging and dementia. *Neurology* 2002; 58: 750–7.
- Jack CR Jr, Knopman DS, Chetelat G, Dickson D, Fagan AM, Frisoni GB, et al. Suspected non-Alzheimer disease pathophysiology—concept and controversy. *Nat Rev Neurol* 2016; 12: 117–24.
- Jack CR Jr, Knopman DS, Weigand SD, Wiste HJ, Vemuri P, Lowe V, et al. An operational approach to National Institute on Aging-Alzheimer’s Association criteria for preclinical Alzheimer disease. *Ann Neurol* 2012; 71: 765–75.
- Jack CR Jr, Wiste HJ, Weigand SD, Therneau TM, Knopman DS, Lowe V, et al. Age-specific and sex-specific prevalence of cerebral beta-amyloidosis, tauopathy, and neurodegeneration in cognitively

- unimpaired individuals aged 50–95 years: a cross-sectional study. *Lancet Neurol* 2017; 16: 435–44.
- Jagust WJ, Zheng L, Harvey DJ, Mack WJ, Vinters HV, Weiner MW, et al. Neuropathological basis of magnetic resonance images in aging and dementia. *Ann Neurol* 2008; 63: 72–80.
- James BD, Wilson RS, Boyle PA, Trojanowski JQ, Bennett DA, Schneider JA. TDP-43 stage, mixed pathologies, and clinical Alzheimer's-type dementia. *Brain* 2016; 139: 2983–93.
- Jellinger K. Pure hippocampal sclerosis: a rare cause of dementia mimicking Alzheimer's disease. *Neurology* 2000; 55: 739–40.
- Jellinger KA, Attems J. Neuropathological evaluation of mixed dementia. *J Neurol Sci* 2007; 257: 80–7.
- Jellinger KA, Attems J. Challenges of multimorbidity of the aging brain: a critical update. *J Neural Transm (Vienna)* 2015; 122: 505–21.
- Josephs KA, Ahmed Z, Katsuse O, Parisi JF, Boeve BF, Knopman DS, et al. Neuropathologic features of frontotemporal lobar degeneration with ubiquitin-positive inclusions with progranulin gene (PGRN) mutations. *J Neuropathol Exp Neurol* 2007; 66: 142–51.
- Josephs KA, Dickson DW. TDP-43 in the olfactory bulb in Alzheimer's disease. *Neuropathol Appl Neurobiol* 2016; 42: 390–3.
- Josephs KA, Dickson DW, Tosakulwong N, Weigand SD, Murray ME, Petrucelli L, et al. Rates of hippocampal atrophy and presence of post-mortem TDP-43 in patients with Alzheimer's disease: a longitudinal retrospective study. *Lancet Neurol* 2017a; 16: 917–24.
- Josephs KA, Murray ME, Tosakulwong N, Weigand SD, Serie AM, Perkerson RB, et al. Pathological, imaging and genetic characteristics support the existence of distinct TDP-43 types in non-FTLD brains. *Acta Neuropathol* 2019; 137: 227–38.
- Josephs KA, Murray ME, Tosakulwong N, Whitwell JL, Knopman DS, Machulda MM, et al. Tau aggregation influences cognition and hippocampal atrophy in the absence of beta-amyloid: a clinico-imaging-pathological study of primary age-related tauopathy (PART). *Acta Neuropathol* 2017b; 133: 705–15.
- Josephs KA, Murray ME, Whitwell JL, Parisi JE, Petrucelli L, Jack CR, et al. Staging TDP-43 pathology in Alzheimer's disease. *Acta Neuropathol* 2014a; 127: 441–50.
- Josephs KA, Murray ME, Whitwell JL, Tosakulwong N, Weigand SD, Petrucelli L, et al. Updated TDP-43 in Alzheimer's disease staging scheme. *Acta Neuropathol* 2016; 131: 571–85.
- Josephs KA, Whitwell JL, Knopman DS, Hu WT, Stroh DA, Baker M, et al. Abnormal TDP-43 immunoreactivity in AD modifies clinicopathologic and radiologic phenotype. *Neurology* 2008; 70: 1850–7.
- Josephs KA, Whitwell JL, Tosakulwong N, Weigand SD, Murray ME, Liesinger AM, et al. TAR DNA-binding protein 43 and pathological subtype of Alzheimer's disease impact clinical features. *Ann Neurol* 2015; 78: 697–709.
- Josephs KA, Whitwell JL, Weigand SD, Murray ME, Tosakulwong N, Liesinger AM, et al. TDP-43 is a key player in the clinical features associated with Alzheimer's disease. *Acta Neuropathol* 2014b; 127: 811–24.
- Jung Y, Dickson DW, Murray ME, Whitwell JL, Knopman DS, Boeve BF, et al. TDP-43 in Alzheimer's disease is not associated with clinical FTLD or Parkinsonism. *J Neurol* 2014; 261: 1344–8.
- Kadokura A, Yamazaki T, Lemere CA, Takatama M, Okamoto K. Regional distribution of TDP-43 inclusions in Alzheimer disease (AD) brains: their relation to AD common pathology. *Neuropathology* 2009; 29: 566–73.
- Kapasi A, DeCarli C, Schneider JA. Impact of multiple pathologies on the threshold for clinically overt dementia. *Acta Neuropathol* 2017; 134: 171–86.
- Katsumata Y, Fardo DW, Kukull WA, Nelson PT. Dichotomous scoring of TDP-43 proteinopathy from specific brain regions in 27 academic research centers: associations with Alzheimer's disease and cerebrovascular disease pathologies. *Acta Neuropathol Commun* 2018; 6: 142.
- Katsumata Y, Nelson PT, Ellingson SR, Fardo DW. Gene-based association study of genes linked to hippocampal sclerosis of aging neuropathology: GRN, TMEM106B, ABCC9, and KCNM2. *Neurobiol Aging* 2017; 53: 193.e17–193.e25.
- Kaur B, Himali JJ, Seshadri S, Beiser AS, Au R, McKee AC, et al. Association between neuropathology and brain volume in the Framingham Heart Study. *Alzheimer Dis Assoc Disord* 2014; 28: 219–25.
- Kawas CH, Corrada MM. Alzheimer's and dementia in the oldest-old: a century of challenges. *Curr Alzheimer Res* 2006; 3: 411–9.
- Ke YD, van Hummel A, Stevens CH, Gladbach A, Ippati S, Bi M, et al. Short-term suppression of A315T mutant human TDP-43 expression improves functional deficits in a novel inducible transgenic mouse model of FTLD-TDP and ALS. *Acta Neuropathol* 2015; 130: 661–78.
- Keage HA, Hunter S, Matthews FE, Ince PG, Hodges J, Hokkanen SR, et al. TDP-43 pathology in the population: prevalence and associations with dementia and age. *J Alzheimers Dis* 2014; 42: 641–50.
- Kero M, Raunio A, Polvikoski T, Tienari PJ, Paetau A, Myllykangas L. Hippocampal sclerosis in the oldest old: a Finnish population-based study. *J Alzheimers Dis* 2018; 63: 263–72.
- Kertesz A, Finger E, Murrell J, Chertkow H, Ang LC, Baker M, et al. Progressive supranuclear palsy in a family with TDP-43 pathology. *Neurocase* 2015; 21: 178–84.
- Kimbrel NA, Garrett ME, Dennis MF; Va Mid-Atlantic Mental Illness Research, Education, and Clinical Center Workgroup, Hauser MA, et al. A genome-wide association study of suicide attempts and suicidal ideation in U.S. military veterans. *Psychiatry Res* 2018; 269: 64–9.
- Klein ZA, Takahashi H, Ma M, Stagi M, Zhou M, Lam TT, et al. Loss of TMEM106B ameliorates lysosomal and frontotemporal dementia-related phenotypes in progranulin-deficient mice. *Neuron* 2017; 95: 281–96.e6.
- Knopman DS, Roberts RO. Estimating the number of persons with frontotemporal lobar degeneration in the US population. *J Mol Neurosci* 2011; 45: 330–5.
- Korczyn AD. Mixed dementia—the most common cause of dementia. *Ann N Y Acad Sci* 2002; 977: 129–34.
- Kortvelyessy P, Heinze HJ, Prudlo J, Bittner D. CSF biomarkers of neurodegeneration in progressive non-fluent aphasia and other forms of frontotemporal dementia: clues for pathomechanisms? *Front Neurol* 2018; 9: 504.
- Kotrotsou A, Schneider JA, Bennett DA, Leurgans SE, Dawe RJ, Boyle PA, et al. Neuropathologic correlates of regional brain volumes in a community cohort of older adults. *Neurobiol Aging* 2015; 36: 2798–805.
- Kovacs GG, Milenkovic I, Wohrer A, Hoftberger R, Gelpi E, Haberler C, et al. Non-Alzheimer neurodegenerative pathologies and their combinations are more frequent than commonly believed in the elderly brain: a community-based autopsy series. *Acta Neuropathol* 2013; 126: 365–84.
- Kravitz E, Schmeidler J, Beeri MS. Cognitive decline and dementia in the oldest-old. *Rambam Maimonides Med J* 2012; 3: e0026.
- Kuslansky G, Verghese J, Dickson D, Katz M, Busche H, Lipton RB. Hippocampal sclerosis: cognitive consequences and contribution to dementia. *Neurology* 2004; 62: A128–9.
- Laferriere F, Maniecka Z, Perez-Berlanga M, Hruska-Plochan M, Gilhespy L, Hock EM, et al. TDP-43 extracted from frontotemporal lobar degeneration subject brains displays distinct aggregate assemblies and neurotoxic effects reflecting disease progression rates. *Nat Neurosci* 2019; 22: 65–77.
- Latimer CS, Keene CD, Flanagan ME, Hemmy LS, Lim KO, White LR, et al. Resistance to Alzheimer disease neuropathologic changes and apparent cognitive resilience in the Nun and Honolulu-Asia aging studies. *J Neuropathol Exp Neurol* 2017; 76: 458–66.
- Lee EB, Lee VM, Trojanowski JQ, Neumann M. TDP-43 immunoreactivity in anoxic, ischemic and neoplastic lesions of the central nervous system. *Acta Neuropathol* 2008; 115: 305–11.
- Lee EB, Porta S, Michael Baer G, Xu Y, Suh E, Kwong LK, et al. Expansion of the classification of FTLD-TDP: distinct pathology

- associated with rapidly progressive frontotemporal degeneration. *Acta Neuropathol* 2017; 134: 65–78.
- Leverenz JB, Agustín CM, Tsuang D, Peskind ER, Edland SD, Nochlin D, et al. Clinical and neuropathological characteristics of hippocampal sclerosis: a community-based study. *Arch Neurol* 2002; 59: 1099–106.
- Leverenz JB, Lipton AM. Clinical aspects of hippocampal sclerosis. *Handb Clin Neurol* 2008; 89: 565–7.
- Lin WL, Castanedes-Casey M, Dickson DW. Transactivation response DNA-binding protein 43 microvasculopathy in frontotemporal degeneration and familial Lewy body disease. *J Neuropathol Exp Neurol* 2009; 68: 1167–76.
- Lin WL, Dickson DW. Ultrastructural localization of TDP-43 in filamentous neuronal inclusions in various neurodegenerative diseases. *Acta Neuropathol* 2008; 116: 205–13.
- Ling H, Morris HR, Neal JW, Lees AJ, Hardy J, Holton JL, et al. Mixed pathologies including chronic traumatic encephalopathy account for dementia in retired association football (soccer) players. *Acta Neuropathol* 2017; 133: 337–52.
- Lippa CF, Dickson DW. Hippocampal sclerosis dementia: expanding the phenotypes of frontotemporal dementias? *Neurology* 2004; 63: 414–5.
- Lippa CF, Rosso AL, Stutzbach LD, Neumann M, Lee VM, Trojanowski JQ. Transactive response DNA-binding protein 43 burden in familial Alzheimer disease and Down syndrome. *Arch Neurol* 2009; 66: 1483–8.
- Mackenzie IR, Bigio EH, Ince PG, Geser F, Neumann M, Cairns NJ, et al. Pathological TDP-43 distinguishes sporadic amyotrophic lateral sclerosis from amyotrophic lateral sclerosis with SOD1 mutations. *Ann Neurol* 2007; 61: 427–34.
- Mackenzie IR, Neumann M. Reappraisal of TDP-43 pathology in FTL-DU subtypes. *Acta Neuropathol* 2017; 134: 79–96.
- Mackenzie IR, Neumann M, Baborie A, Sampathu DM, Du Plessis D, Jaros E, et al. A harmonized classification system for FTL-DU pathology. *Acta Neuropathol* 2011; 122: 111–3.
- Makkinjad N, Schneider JA, Yu J, Leurgans SE, Kotrotsou A, Evia AM, et al. Associations of amygdala volume and shape with transactive response DNA-binding protein 43 (TDP-43) pathology in a community cohort of older adults. *Neurobiol Aging* 2019; 77: 104–11.
- Malek-Ahmadi M, Kahlon V, Adler CH, Obradov A, Thind K, Shill HA, et al. Prevalence of hippocampal sclerosis in a clinicopathologically characterized cohort. *Clin Exp Med Sci* 2013; 1: 317–27.
- McAleese KE, Walker L, Erskine D, Thomas AJ, McKeith IG, Attems J. TDP-43 pathology in Alzheimer's disease, dementia with Lewy bodies and ageing. *Brain Pathol* 2017; 27: 472–9.
- Miki Y, Mori F, Seino Y, Tanji K, Yoshizawa T, Kijima H, et al. Colocalization of Bunina bodies and TDP-43 inclusions in a case of sporadic amyotrophic lateral sclerosis with Lewy body-like hyaline inclusions. *Neuropathology* 2018; 38: 521–8.
- Miller ZA, Rankin KP, Graff-Radford NR, Takada LT, Sturm VE, Cleveland CM, et al. TDP-43 frontotemporal lobar degeneration and autoimmune disease. *J Neurol Neurosurg Psychiatry* 2013; 84: 956–62.
- Montine TJ, Phelps CH, Beach TG, Bigio EH, Cairns NJ, Dickson DW, et al. National Institute on Aging-Alzheimer's Association guidelines for the neuropathologic assessment of Alzheimer's disease: a practical approach. *Acta Neuropathol* 2012; 123: 1–11.
- Morris GP, Clark IA, Vissel B. Questions concerning the role of amyloid-beta in the definition, aetiology and diagnosis of Alzheimer's disease. *Acta Neuropathol* 2018; 136: 663–89.
- Murray ME, Bieniek KF, Banks Greenberg M, DeJesus-Hernandez M, Rutherford NJ, van Blitterswijk M, et al. Progressive amnesic dementia, hippocampal sclerosis, and mutation in C9ORF72. *Acta Neuropathol* 2013; 126: 545–54.
- Murray ME, Cannon A, Graff-Radford NR, Liesinger AM, Rutherford NJ, Ross OA, et al. Differential clinicopathologic and genetic features of late-onset amnesic dementias. *Acta Neuropathol* 2014; 128: 411–21.
- Nag S, Yu L, Boyle PA, Leurgans SE, Bennett DA, Schneider JA. TDP-43 pathology in anterior temporal pole cortex in aging and Alzheimer's disease. *Acta Neuropathol Commun* 2018; 6: 33.
- Nag S, Yu L, Capuano AW, Wilson RS, Leurgans SE, Bennett DA, et al. Hippocampal sclerosis and TDP-43 pathology in aging and Alzheimer disease. *Ann Neurol* 2015; 77: 942–52.
- Nag S, Yu L, Wilson RS, Chen EY, Bennett DA, Schneider JA. TDP-43 pathology and memory impairment in elders without pathologic diagnoses of AD or FTL-DU. *Neurology* 2017; 88: 653–60.
- Nakashima-Yasuda H, Uryu K, Robinson J, Xie SX, Hurtig H, Duda JE, et al. Co-morbidity of TDP-43 proteinopathy in Lewy body related diseases. *Acta Neuropathol* 2007; 114: 221–9.
- Nana AL, Sidhu M, Gaus SE, Hwang JL, Li L, Park Y, et al. Neurons selectively targeted in frontotemporal dementia reveal early stage TDP-43 pathobiology. *Acta Neuropathol* 2019; 137: 27–46.
- Nascimento C, Di Lorenzo Alho AT, Bazan Conceicao Amaral C, Leite REP, Nitri R, Jacob-Filho W, et al. Prevalence of transactive response DNA-binding protein 43 (TDP-43) proteinopathy in cognitively normal older adults: systematic review and meta-analysis. *Neuropathol Appl Neurobiol* 2018; 44: 286–97.
- Nascimento C, Suemoto CK, Rodriguez RD, Alho AT, Leite RP, Farfel JM, et al. Higher prevalence of TDP-43 proteinopathy in cognitively normal asians: a clinicopathological study on a multiethnic sample. *Brain Pathol* 2016; 26: 177–85.
- Nelson PT, Abner EL, Patel E, Anderson S, Wilcock DM, Kryscio RJ, et al. The amygdala as a locus of pathologic misfolding in neurodegenerative diseases. *J Neuropathol Exp Neurol* 2018; 77: 2–20.
- Nelson PT, Abner EL, Schmitt FA, Kryscio RJ, Jicha GA, Smith CD, et al. Modeling the association between 43 different clinical and pathological variables and the severity of cognitive impairment in a large autopsy cohort of elderly persons. *Brain Pathol* 2010; 20: 66–79.
- Nelson PT, Alafuzoff I, Bigio EH, Bouras C, Braak H, Cairns NJ, et al. Correlation of Alzheimer disease neuropathologic changes with cognitive status: a review of the literature. *J Neuropathol Exp Neurol* 2012; 71: 362–81.
- Nelson PT, Braak H, Markesbery WR. Neuropathology and cognitive impairment in Alzheimer disease: a complex but coherent relationship. *J Neuropathol Exp Neurol* 2009; 68: 1–14.
- Nelson PT, Estus S, Abner EL, Parikh I, Malik M, Neltner JH, et al. ABCC9 gene polymorphism is associated with hippocampal sclerosis of aging pathology. *Acta Neuropathol* 2014; 127: 825–43.
- Nelson PT, Gal Z, Wang WX, Niedowicz DM, Artiushin SC, Wycoff S, et al. TDP-43 proteinopathy in aging: associations with risk-associated gene variants and with brain parenchymal thyroid hormone levels. *Neurobiol Dis* 2019; 125: 67–76.
- Nelson PT, Head E, Schmitt FA, Davis PR, Neltner JH, Jicha GA, et al. Alzheimer's disease is not “brain aging”: neuropathological, genetic, and epidemiological human studies. *Acta Neuropathol* 2011a; 121: 571–87.
- Nelson PT, Jicha GA, Wang WX, Ighodaro E, Artiushin S, Nichols CG, et al. ABCC9/SUR2 in the brain: Implications for hippocampal sclerosis of aging and a potential therapeutic target. *Ageing Res Rev* 2015a; 24: 111–25.
- Nelson PT, Katsumata Y, Nho K, Artiushin SC, Jicha GA, Wang WX, et al. Genomics and CSF analyses implicate thyroid hormone in hippocampal sclerosis of aging. *Acta Neuropathol* 2016a; 132: 841–58.
- Nelson PT, Schmitt FA, Lin Y, Abner EL, Jicha GA, Patel E, et al. Hippocampal sclerosis in advanced age: clinical and pathological features. *Brain* 2011b; 134: 1506–18.
- Nelson PT, Smith CD, Abner EL, Wilfred BJ, Wang WX, Neltner JH, et al. Hippocampal sclerosis of aging, a prevalent and high-morbidity brain disease. *Acta Neuropathol* 2013; 126: 161–77.
- Nelson PT, Trojanowski JQ, Abner EL, Al-Janabi OM, Jicha GA, Schmitt FA, et al. “New Old Pathologies”: AD, PART, and

- Cerebral Age-Related TDP-43 with Sclerosis (CARTS). *J Neuropathol Exp Neurol* 2016b; 75: 482–98.
- Nelson PT, Wang WX, Partch AB, Monsell SE, Valladares O, Ellingson SR, et al. Reassessment of risk genotypes (GRN, TMEM106B, and ABCC9 variants) associated with hippocampal sclerosis of aging pathology. *J Neuropathol Exp Neurol* 2015b; 74: 75–84.
- Neltner JH, Abner EL, Baker S, Schmitt FA, Kryscio RJ, Jicha GA, et al. Arteriolosclerosis that affects multiple brain regions is linked to hippocampal sclerosis of ageing. *Brain* 2014; 137: 255–67.
- Neltner JH, Abner EL, Jicha GA, Schmitt FA, Patel E, Poon LW, et al. Brain pathologies in extreme old age. *Neurobiol Aging* 2016; 37: 1–11.
- Neumann M, Mackenzie IRA. Review: Neuropathology of non-tau frontotemporal lobar degeneration. *Neuropathol Appl Neurobiol* 2019; 45: 19–40.
- Neumann M, Sampathu DM, Kwong LK, Truax AC, Micsenyi MC, Chou TT, et al. Ubiquitinated TDP-43 in frontotemporal lobar degeneration and amyotrophic lateral sclerosis. *Science* 2006; 314: 130–3.
- Neuropathology Group. Medical Research Council Cognitive Function and Aging Study. Pathological correlates of late-onset dementia in a multicentre, community-based population in England and Wales. Neuropathology Group of the Medical Research Council Cognitive Function and Ageing Study (MRC CFAS). *Lancet* 2001; 357: 169–75.
- Nho K, Saykin AJ; Alzheimer's Disease Neuroimaging Initiative, Nelson PT. Hippocampal sclerosis of aging, a common Alzheimer's disease 'mimic': risk genotypes are associated with brain atrophy outside the temporal lobe. *J Alzheimers Dis* 2016; 52: 373–83.
- Nicholson AM, Rademakers R. What we know about TMEM106B in neurodegeneration. *Acta Neuropathol* 2016; 132: 639–51.
- Ou SH, Chalmers ZR, Azada MC, Ross JS, Stephens PJ, Ali SM, et al. Identification of a novel TMEM106B-ROS1 fusion variant in lung adenocarcinoma by comprehensive genomic profiling. *Lung Cancer* 2015; 88: 352–4.
- Ou SH, Wu F, Harrich D, Garcia-Martinez LF, Gaynor RB. Cloning and characterization of a novel cellular protein, TDP-43, that binds to human immunodeficiency virus type 1 TAR DNA sequence motifs. *J Virol* 1995; 69: 3584–96.
- Oveisgharan S, Arvanitakis Z, Yu L, Farfel J, Schneider JA, Bennett DA. Sex differences in Alzheimer's disease and common neuropathologies of aging. *Acta Neuropathol* 2018; 136: 887–900.
- Pao WC, Dickson DW, Crook JE, Finch NA, Rademakers R, Graff-Radford NR. Hippocampal sclerosis in the elderly: genetic and pathologic findings, some mimicking Alzheimer disease clinically. *Alzheimer Dis Assoc Disord* 2011; 25: 364–8.
- Paushter DH, Du H, Feng T, Hu F. The lysosomal function of progranulin, a guardian against neurodegeneration. *Acta Neuropathol* 2018; 136: 1–17.
- Pelletier A, Bernard C, Dilharreguy B, Helmer C, Le Goff M, Chanraud S, et al. Patterns of brain atrophy associated with episodic memory and semantic fluency decline in aging. *Aging (Albany NY)* 2017; 9: 741–52.
- Perkins GD, McAuley DF, Davies S, Gao F. Discrepancies between clinical and postmortem diagnoses in critically ill patients: an observational study. *Crit Care* 2003; 7: R129–32.
- Popkirov S, Ismail FS, Gronheit W, Kapauer M, Wellmer J, Bien CG. Progressive hippocampal sclerosis after viral encephalitis: potential role of NMDA receptor antibodies. *Seizure* 2017; 51: 6–8.
- Porta M. *Dictionary of Epidemiology*. 6th edn. New York: Oxford University Press; 2014.
- Porta S, Xu Y, Restrepo CR, Kwong LK, Zhang B, Brown HJ, et al. Patient-derived frontotemporal lobar degeneration brain extracts induce formation and spreading of TDP-43 pathology in vivo. *Nat Commun* 2018; 9: 4220.
- Pottier C, Zhou X, Perkerson RB 3rd, Baker M, Jenkins GD, Serie DJ, et al. Potential genetic modifiers of disease risk and age at onset in patients with frontotemporal lobar degeneration and GRN mutations: a genome-wide association study. *Lancet Neurol* 2018; 17: 548–58.
- Power MC, Mormino E, Soldan A, James BD, Yu L, Armstrong NM, et al. Combined neuropathological pathways account for age-related risk of dementia. *Ann Neurol* 2018; 84: 10–22.
- Probst A, Taylor KI, Tolnay M. Hippocampal sclerosis dementia: a reappraisal. *Acta Neuropathol* 2007; 114: 335–45.
- Rademakers R, Eriksen JL, Baker M, Robinson T, Ahmed Z, Lincoln SJ, et al. Common variation in the miR-659 binding-site of GRN is a major risk factor for TDP43-positive frontotemporal dementia. *Hum Mol Genet* 2008; 17: 3631–42.
- Rahimi J, Kovacs GG. Prevalence of mixed pathologies in the aging brain. *Alzheimers Res Ther* 2014; 6: 82.
- Rauramaa T, Pikkarainen M, Englund E, Ince PG, Jellinger K, Paetau A, et al. TAR-DNA binding protein-43 and alterations in the hippocampus. *J Neural Transm* 2011; 118: 683–9.
- Rauramaa T, Pikkarainen M, Englund E, Ince PG, Jellinger K, Paetau A, et al. Consensus recommendations on pathologic changes in the hippocampus: a postmortem multicenter inter-rater study. *J Neuropathol Exp Neurol* 2013; 72: 452–61.
- Register OotF. Early Alzheimer's Disease: Developing Drugs for Treatment; Draft Guidance for Industry. In: USDoHaH S, Administration FaD CC, (CBER) CfBEaR, editors. Silver Spring, MD: Office of the Federal Register, National Archives and Records Administration; 2018. p. 7060–1.
- Ren Y, van Blitterswijk M, Allen M, Carrasquillo MM, Reddy JS, Wang X, et al. TMEM106B haplotypes have distinct gene expression patterns in aged brain. *Mol Neurodegener* 2018; 13: 35.
- Rhinn H, Abeliovich A. Differential aging analysis in human cerebral cortex identifies variants in TMEM106B and GRN that regulate aging phenotypes. *Cell Syst* 2017; 4: 404–15.e5.
- Robinson AC, Davidson YS, Horan MA, Pendleton N, Mann DMA. Pathological correlates of cognitive impairment in The University of Manchester Longitudinal Study of Cognition in Normal Healthy Old Age. *J Alzheimers Dis* 2018a; 64: 483–96.
- Robinson JL, Corrada MM, Kovacs GG, Dominique M, Caswell C, Xie SX, et al. Non-Alzheimer's contributions to dementia and cognitive resilience in The 90+ Study. *Acta Neuropathol* 2018b; 136: 377–88.
- Robinson JL, Geser F, Stieber A, Umoh M, Kwong LK, Van Deerlin VM, et al. TDP-43 skeins show properties of amyloid in a subset of ALS cases. *Acta Neuropathol* 2013; 125: 121–31.
- Robinson JL, Lee EB, Xie SX, Rennert L, Suh E, Bredenberg C, et al. Neurodegenerative disease concomitant proteinopathies are prevalent, age-related and APOE4-associated. *Brain* 2018c; 141: 2181–93.
- Robinson JL, Molina-Porcel L, Corrada MM, Raible K, Lee EB, Lee VM, et al. Perforant path synaptic loss correlates with cognitive impairment and Alzheimer's disease in the oldest-old. *Brain* 2014; 137: 2578–87.
- Roostaei T, Nazeri A, Felsky D, De Jager PL, Schneider JA, Pollock BG, et al. Genome-wide interaction study of brain beta-amyloid burden and cognitive impairment in Alzheimer's disease. *Mol Psychiatry* 2016; 22: 287–95.
- Roth M, Tomlinson BE, Blessed G. Correlation between scores for dementia and counts of 'senile plaques' in cerebral grey matter of elderly subjects. *Nature* 1966; 209: 109–10.
- Roulson J, Benbow EW, Hasleton PS. Discrepancies between clinical and autopsy diagnosis and the value of post mortem histology; a meta-analysis and review. *Histopathology* 2005; 47: 551–9.
- Sahoo A, Bejanin A, Murray ME, Tosakulwong N, Weigand SD, Serie AM, et al. TDP-43 and Alzheimer's disease pathologic subtype in non-amnesic Alzheimer's disease dementia. *J Alzheimers Dis* 2018; 64: 1227–33.



- Saunders AM, Strittmatter WJ, Schmechel D, George-Hyslop PH, Pericak-Vance MA, Joo SH, et al. Association of apolipoprotein E allele epsilon 4 with late-onset familial and sporadic Alzheimer's disease. *Neurology* 1993; 43: 1467–72.
- Savva GM, Wharton SB, Ince PG, Forster G, Matthews FE, Brayne C. Age, neuropathology, and dementia. *N Engl J Med* 2009; 360: 2302–9.
- Schmechel DE, Saunders AM, Strittmatter WJ, Crain BJ, Hulette CM, Joo SH, et al. Increased amyloid beta-peptide deposition in cerebral cortex as a consequence of apolipoprotein E genotype in late-onset Alzheimer disease. *Proc Natl Acad Sci U S A* 1993; 90: 9649–53.
- Schneider JA, Arvanitakis Z, Bang W, Bennett DA. Mixed brain pathologies account for most dementia cases in community-dwelling older persons. *Neurology* 2007; 69: 2197–204.
- Sen A, Dugan P, Perucca P, Costello D, Choi H, Bazil C, et al. The phenotype of bilateral hippocampal sclerosis and its management in “real life” clinical settings. *Epilepsia* 2018; 59: 1410–20.
- Sennik S, Schweizer TA, Fischer CE, Munoz DG. Risk factors and pathological substrates associated with agitation/aggression in Alzheimer's disease: a preliminary study using NACC data. *J Alzheimers Dis* 2017; 55: 1519–28.
- Sevigny J, Chiao P, Bussiere T, Weinreb PH, Williams L, Maier M, et al. The antibody aducanumab reduces Abeta plaques in Alzheimer's disease. *Nature* 2016; 537: 50–6.
- Shojania KG, Burton EC, McDonald KM, Goldman L. Changes in rates of autopsy-detected diagnostic errors over time: a systematic review. *JAMA* 2003; 289: 2849–56.
- Smith VD, Bachstetter AD, Ighodaro E, Roberts K, Abner EL, Fardo DW, et al. Overlapping but distinct TDP-43 and tau pathologic patterns in aged hippocampi. *Brain Pathol* 2017; 28: 264–73.
- Snowdon DA, Greiner LH, Mortimer JA, Riley KP, Greiner PA, Markesbery WR. Brain infarction and the clinical expression of Alzheimer disease. *The Nun Study*. *JAMA* 1997; 277: 813–7.
- Sommer W. Erkrankung des Ammon's horn als aetiologis ches moment der epilepsien. *Arch Psychiatr Nurs* 1880; 10: 631–75.
- Spires-Jones TL, Attems J, Thal DR. Interactions of pathological proteins in neurodegenerative diseases. *Acta Neuropathol* 2017; 134: 187–205.
- Steinacker P, Barschke P, Otto M. Biomarkers for diseases with TDP-43 pathology. *Mol Cell Neurosci* 2018. pii: S1044-7431(18)30310-5.
- Suemoto CK, Ferretti-Rebustini RE, Rodriguez RD, Leite RE, Soterio L, Brucki SM, et al. Neuropathological diagnoses and clinical correlates in older adults in Brazil: a cross-sectional study. *PLoS Med* 2017; 14: e1002267.
- Takao M, Hirose N, Arai Y, Mihara B, Mimura M. Neuropathology of supercentenarians—four autopsy case studies. *Acta Neuropathol Commun* 2016; 4: 97.
- Tan RH, Ke YD, Ittner LM, Halliday GM. ALS/FTLD: experimental models and reality. *Acta Neuropathol* 2017a; 133: 177–96.
- Tan RH, Kril JJ, Fatima M, McGeachie A, McCann H, Shepherd C, et al. TDP-43 proteinopathies: pathological identification of brain regions differentiating clinical phenotypes. *Brain* 2015; 138: 3110–22.
- Tan RH, Yang Y, Halliday GM. Multiple neuronal pathologies are common in young patients with pathologically proven Frontotemporal lobar degeneration. *Neuropathol Appl Neurobiol* 2017b. doi: 10.1111/nan.12455.
- Tanskanen M, Makela M, Notkola IL, Myllykangas L, Rastas S, Oinas M, et al. Population-based analysis of pathological correlates of dementia in the oldest old. *Ann Clin Transl Neurol* 2017; 4: 154–65.
- Thal DR, Rub U, Schultz C, Sassin I, Ghebremedhin E, Del Tredici K, et al. Sequence of Abeta-protein deposition in the human medial temporal lobe. *J Neuropathol Exp Neurol* 2000; 59: 733–48.
- Thom M. Hippocampal sclerosis: progress since Sommer. *Brain Pathol* 2009; 19: 565–72.
- Thom M, Eriksson S, Martinian L, Caboclo LO, McEvoy AW, Duncan JS, et al. Temporal lobe sclerosis associated with hippocampal sclerosis in temporal lobe epilepsy: neuropathological features. *J Neuropathol Exp Neurol* 2009; 68: 928–38.
- Thom M, Sisodiya S. Epilepsy. In: Love S, Perry A, Ironside JW, Budka H, editors. *Greenfield's Neuropathology*. New York: CRC Press; 2015. p. 683–739.
- Tremblay C, St-Amour I, Schneider J, Bennett DA, Calon F. Accumulation of transactive response DNA binding protein 43 in mild cognitive impairment and Alzheimer disease. *J Neuropathol Exp Neurol* 2011; 70: 788–98.
- Trieu T, Sajjadi SA, Kawas CH, Nelson PT, Corrada MM. Risk factors of hippocampal sclerosis in the oldest old: the 90+ study. *Neurology* 2018; 91: e1788–98.
- Trojanowski JQ, Lee VM. “Fatal attractions” of proteins. A comprehensive hypothetical mechanism underlying Alzheimer's disease and other neurodegenerative disorders. *Ann N Y Acad Sci* 2000; 924: 62–7.
- Troncoso JC, Kawas CH, Chang CK, Folstein MF, Hedreen JC. Lack of association of the apoE4 allele with hippocampal sclerosis dementia. *Neurosci Lett* 1996; 204: 138–40.
- Tsuji H, Arai T, Kametani F, Nonaka T, Yamashita M, Suzukake M, et al. Molecular analysis and biochemical classification of TDP-43 proteinopathy. *Brain* 2012; 135: 3380–91.
- Uchino A, Takao M, Hatsuta H, Sumikura H, Nakano Y, Nogami A, et al. Incidence and extent of TDP-43 accumulation in aging human brain. *Acta Neuropathol Commun* 2015; 3: 35.
- Uryu K, Nakashima-Yasuda H, Forman MS, Kwong LK, Clark CM, Grossman M, et al. Concomitant TAR-DNA-binding protein 43 pathology is present in Alzheimer disease and corticobasal degeneration but not in other tauopathies. *J Neuropathol Exp Neurol* 2008; 67: 555–64.
- Van Deerlin VM, Sleiman PM, Martinez-Lage M, Chen-Plotkin A, Wang LS, Graff-Radford NR, et al. Common variants at 7p21 are associated with frontotemporal lobar degeneration with TDP-43 inclusions. *Nat Genet* 2010; 42: 234–9.
- Vassilaki M, Aakre JA, Kremers WK, Mielke MM, Geda YE, Alhurani RE, et al. The Association of Multimorbidity with Preclinical AD Stages and SNAP in Cognitively Unimpaired Persons. *J Gerontol A Biol Sci Med Sci* 2018. doi: 10.1093/geron/gly149.
- Vatsavayai SC, Yoon SJ, Gardner RC, Gendron TF, Vargas JN, Trujillo A, et al. Timing and significance of pathological features in C9orf72 expansion-associated frontotemporal dementia. *Brain* 2016; 139: 3202–16.
- Vatsavayi AV, Kofler J, Demichele-Sweet MA, Murray PS, Lopez OL, Sweet RA. TAR DNA-binding protein 43 pathology in Alzheimer's disease with psychosis. *Int Psychogeriatr* 2014; 26: 987–94.
- Velakoulis D, Walterfang M, Mocellin R, Pantelis C, Dean B, McLean C. Abnormal hippocampal distribution of TDP-43 in patients with late onset psychosis. *Aust N Z J Psychiatry* 2009; 43: 739–45.
- Verde F, Del Tredici K, Braak H, Ludolph A. The multisystem degeneration amyotrophic lateral sclerosis—neuropathological staging and clinical translation. *Arch Ital Biol* 2017; 155: 118–30.
- Vinters HV, Ellis WG, Zarow C, Zaias BW, Jagust WJ, Mack WJ, et al. Neuropathologic substrates of ischemic vascular dementia. *J Neuropathol Exp Neurol* 2000; 59: 931–45.
- Vos SJ, Xiong C, Visser PJ, Jasielec MS, Hassenstab J, Grant EA, et al. Preclinical Alzheimer's disease and its outcome: a longitudinal cohort study. *Lancet Neurol* 2013; 12: 957–65.
- Wennberg AM, Tosakulwong N, Lesnick TG, Murray ME, Whitwell JL, Liesinger AM, et al. Association of Apolipoprotein E epsilon4 with Transactive Response DNA-Binding Protein 43. *JAMA Neurol* 2018; 75: 1347–54.
- White L, Petrovitch H, Hardman J, Nelson J, Davis DG, Ross GW, et al. Cerebrovascular pathology and dementia in autopsied Honolulu-Asia Aging Study participants. *Ann N Y Acad Sci* 2002; 977: 9–23.

- White LR, Edland SD, Hemmy LS, Montine KS, Zarow C, Sonnen JA, et al. Neuropathologic comorbidity and cognitive impairment in the Nun and Honolulu-Asia Aging Studies. *Neurology* 2016; 86: 1000–8.
- Wilson RS, Yang J, Yu L, Leurgans SE, Capuano AW, Schneider JA, et al. Postmortem neurodegenerative markers and trajectories of decline in cognitive systems. *Neurology* 2019; 92: e831–e840.
- Wisse LE, Butala N, Das SR, Davatzikos C, Dickerson BC, Vaishnavi SN, et al. Suspected non-AD pathology in mild cognitive impairment. *Neurobiol Aging* 2015; 36: 3152–62.
- Wisse LEM, Das SR, Davatzikos C, Dickerson BC, Xie SX, Yushkevich PA, et al. Defining SNAP by cross-sectional and longitudinal definitions of neurodegeneration. *Neuroimage Clin* 2018; 18: 407–12.
- Yang HS, Yu L, White CC, Chibnik LB, Chhatwal JP, Sperling RA, et al. Evaluation of TDP-43 proteinopathy and hippocampal sclerosis in relation to APOE epsilon4 haplotype status: a community-based cohort study. *Lancet Neurol* 2018; 17: 773–81.
- Yokota O, Davidson Y, Bigio EH, Ishizu H, Terada S, Arai T, et al. Phosphorylated TDP-43 pathology and hippocampal sclerosis in progressive supranuclear palsy. *Acta Neuropathol* 2010; 120: 55–66.
- Yu L, De Jager PL, Yang J, Trojanowski JQ, Bennett DA, Schneider JA. The TMEM106B locus and TDP-43 pathology in older persons without FTL. *Neurology* 2015; 84: 927–34.
- Yu M, Guo L, Li N, Henzel KS, Gu H, Ran X, et al. Overexpression of Kcnmb2 in dorsal CA1 of offspring mice rescues hippocampal dysfunction caused by a methyl donor-rich paternal diet. *Front Cell Neurosci* 2018; 12: 360.
- Zaccai J, Brayne C, McKeith I, Matthews F, Ince PG. Patterns and stages of alpha-synucleinopathy: relevance in a population-based cohort. *Neurology* 2008; 70: 1042–8.
- Zarei MM, Song M, Wilson RJ, Cox N, Colom LV, Knaus HG, et al. Endocytic trafficking signals in KCNMB2 regulate surface expression of a large conductance voltage and Ca(2+)-activated K+ channel. *Neuroscience* 2007; 147: 80–9.
- Zarow C, Sitzer TE, Chui HC. Understanding hippocampal sclerosis in the elderly: epidemiology, characterization, and diagnostic issues. *Curr Neurol Neurosci Rep* 2008; 8: 363–70.
- Zarow C, Vinters HV, Ellis WG, Weiner MW, Mungas D, White L, et al. Correlates of hippocampal neuron number in Alzheimer's disease and ischemic vascular dementia. *Ann Neurol* 2005; 57: 896–903.
- Zarow C, Wang L, Chui HC, Weiner MW, Csernansky JG. MRI shows more severe hippocampal atrophy and shape deformation in hippocampal sclerosis than in Alzheimer's disease. *Int J Alzheimers Dis* 2011; 2011: 483972.
- Zarow C, Weiner MW, Ellis WG, Chui HC. Prevalence, laterality, and comorbidity of hippocampal sclerosis in an autopsy sample. *Brain Behav* 2012; 2: 435–42.
- Zekry D, Hauw JJ, Gold G. Mixed dementia: epidemiology, diagnosis, and treatment. *J Am Geriatr Soc* 2002; 50: 1431–8.
- Zetterberg H. Neurofilament light: a dynamic cross-disease fluid biomarker for neurodegeneration. *Neuron* 2016; 91: 1–3.
- Zhang X, Sun B, Wang X, Lu H, Shao F, Rozemuller AJM, et al. Phosphorylated TDP-43 staging of primary age-related tauopathy. *Neurosci Bull* 2019; 35: 183–92.
- Zhou X, Sun L, Brady OA, Murphy KA, Hu F. Elevated TMEM106B levels exaggerate lipofuscin accumulation and lysosomal dysfunction in aged mice with progranulin deficiency. *Acta Neuropathol Commun* 2017; 5: 9.