

UCSF

UC San Francisco Previously Published Works

Title

Early histochemical changes in irradiated salivary glands and lymph-nodes of the rat

Permalink

<https://escholarship.org/uc/item/8wm696mb>

Journal

The Journal of Pathology, 88(2)

ISSN

0022-3417

Authors

Greenspan, JS
Melamed, MR
Pearse, AGE

Publication Date

1964-10-01

DOI

10.1002/path.1700880207

Peer reviewed

EARLY HISTOCHEMICAL CHANGES IN IRRADIATED SALIVARY GLANDS AND LYMPH-NODES OF THE RAT

J. S. GREENSPAN*, M. R. MELAMED † AND A. G. E. PEARSE

Postgraduate Medical School of London, Ducane Road, London

PLATES CXX-CXXVI

THE mechanism by which radiation produces cell injury is unknown. It has been postulated that an initial event may be disruption of intracellular enzyme systems, and this hypothesis has received some support from biochemical work (Alexander and Bacq, 1961). Since cell damage from radiation is focal rather than uniform, histochemical techniques seem particularly suited for further exploring this possibility. In this study we have used these techniques to compare changes produced by radiation in a sensitive tissue with those occurring in relatively resistant tissues.

The major salivary glands and lymph-nodes in the neck of the rat were chosen because they represent relatively radioresistant and radiosensitive tissues in close proximity and because the entire complex is accessible to strictly local irradiation.

METHODS

In order to minimise damage to other structures a technique was devised for lateral irradiation of the salivary gland-lymph node complex. This was a modification of the method used by Thomlinson (1960, and personal communication) to irradiate tumours in the abdominal wall. A jig was constructed in which a rat could be placed on its side (fig. 1). A skin flap containing the salivary glands and lymph-nodes was pulled gently ventrally with a pair of modified artery forceps. Palpation and dissection of the tissues in this position proved that the salivary gland-lymph node complex was pulled with the subcutaneous tissues into the radiation field and away from the trachea, oesophagus and vertebral column. Radiographs also taken in this position confirmed the relation found by dissection (fig. 2). The jig with the rat in place was then fixed in the radiation chamber, which is described in full by Thomlinson. Basically this consisted of a Perspex hemisphere with a metal base to which the jig could be bolted. To this chamber air was delivered at 1 litre per min., and the temperature was maintained at 26–30° C.

Radiation factors

The radiation was delivered by a Marconi 250 KV, 15 m.Amp. machine with filters of copper (0.3 mm.) and aluminium (1 mm.). The Perspex top of the radiation chamber was 0.5 cm. thick. The half value layer was 1.2 mm. of copper. The X-rays passed through a 3 cm. hole in a lead shield 4 cm. thick, which collimated

* Present address: Royal Dental Hospital School of Dental Surgery, London, W.C. 2.

† On leave of absence from Memorial Hospital for Cancer and Allied Diseases, New York City, U.S.A.

them. The dose was indicated by a direct monitor; radiation times were 4 min. 56 sec. \pm 2 sec. for 2000 rads and 10 min. 15 sec. \pm 2 sec. for 4000 rads.

Procedure

Male white rats of an inbred strain maintained in the Medical Research Council Experimental Radio-pathology Research Unit for 5 yr, and known to be inbred for 50 generations, were used. They were *c.* 9 wk old and weighed 185–212 g. Diet was standard rat cake and water *ad libitum*.

One group of 10 rats received 2000 rads to the salivary gland-lymph node complex, and a second group of 11 received 4000 rads. Each rat was anaesthetised with 0.6–0.75 ml. of a 2.5 per cent. solution of sodium amytal intraperitoneally. The skin of the neck was shaved and the animal placed on the jig in the radiation chamber as described previously. Each rat was turned over after half the dose had been received, so that right and left sides received equal amounts of radiation.

Animals in the 2000 rads group were killed with coal gas at $\frac{1}{2}$, 1, 2, 4 and 8 hr, and 1, 2, 4, 7 and 14 days. The submandibular-sublingual complex and adjoining lymph-nodes were quickly removed, quenched in liquid air (-150° C.) and stored in sealed polythene bags at -80° C. The 4000 rads group were killed at $\frac{1}{2}$, 1 $\frac{1}{2}$, 4 and 8 hr, and 1, 2, 4, 8, 13, 17 and 22 days. The parotid, submandibular and sublingual glands and lymph-nodes were removed, quenched in liquid air and stored in the same manner. Time in storage did not exceed one month for any tissue block.

Control animals were of the same strain, sex, age and weight range as the experimental animals, and were housed and fed in the same manner. They were divided into 3 groups. In one group of 10, eight were anaesthetised in the same way as the experimental rats and killed at intervals up to four hours; 2 were not treated at all. Twelve other rats were killed at intervals with the radiated animals. Half of these were untreated, whilst half were anaesthetised, shaved and placed on the jig in the machine, but no radiation was delivered. In this way any changes that might have been due to the effects of barbiturate, handling, feeding, or normal growth and development would have come to light. In fact, as will be seen, none of these factors produced any changes demonstrable by the techniques used.

Histochemical techniques

Sections for all the techniques were cut at 8 μ in the cryostat at -18° C, picked up on coverslips, allowed to thaw and dried in air at room temperature and incubated unfixed unless otherwise stated.

For convenience the tissue blocks were handled in 3 groups, the barbiturate control series, the 2000 rads group with its series of controls and the 4000 rads group with its series of controls. All the blocks in each group were cut at the same time, within a period of 3–4 hours. The blocks in each group were selected at random for cutting.

Optimum incubation times were determined in a preliminary study of normal rat salivary glands.

Except where stated the methods were as given by Pearse (1960).

Enzymes

Dehydrogenases. The 3(4,5-dimethyl-thiazolyl-2)-2,5-diphenyl tetrazolium (MTT)-cobalt system of Pearse was used to identify NAD and NADP diaphorases (NAD-D and NADP-D), succinate dehydrogenase (S-DH), isocitrate dehydrogenase (IC-DH), malate dehydrogenase (M-DH), lactate dehydrogenase (L-DH), glucose-6-phosphate dehydrogenase (G6P-DH), β -hydroxybutyrate dehydrogenase (β OHB-DH), and alpha-glycerophosphate dehydrogenase (α GP-DH) (with menaphthone as intermediate H carrier). Incubation time varied from 15 to 60 min. at 37° C, depending on the level of enzymatic activity.

Ubiquinone (Ubq.) using MTT/Co (Tranzer and Pearse, 1963).

Alkaline phosphatase (AlkPase) using AS.MX phosphate and a stable diazo salt of 5-chloro-*o*-toluidine (fast red TR).

Acid phosphatase (AcPase) with AS.MX phosphate at pH 5.2 using a stable diazo salt of 4-(*p*'-nitro-2', 6-dichloro-phenylazo) 2-5-dimethoxy aniline (fast dark blue R).

Non-specific esterase (NSEase) by two methods; α -naphthyl acetate at pH 7.4 and fast blue B salt (a stable diazo salt of *o*-dianisidine) and using 4-chloro-5-bromo-*o*-acetyl indoxyl with ferri-ferro-cyanide.

Glucuronidase (β -Gase) by the post-coupling method of Seligman *et al.* (1949); 6-bromo-2-naphthyl- β -D-glucuronide and fast blue B were used on cryostat sections post-fixed for 15 min. in cold formol-calcium at 4° C.

Aminopeptidase (LAPase) by the method of Nachlas, Crawford and Seligman (1957), with 1-leucyl- β -naphthylamide at pH 6.5, fast blue B and copper sulphate.

Cytochrome oxidase (Cyt. ox.) by the method of Nachlas *et al.* (1958), with α -naphthol and 4-amino-N, N-dimethylnaphthylamine (ADN).

Monoamine oxidase (MAO) with tryptamine hydrochloride and tetranitro-BT (2,2', 5,5'-tetra-*p*-nitrophenyl-3,3'-(3,3'-dimethoxy-4,4'-biphenylene) ditetrazolium chloride) (after Glenner, Burtner and Brown, 1957).

Proteins, lipids, nucleic acids, carbohydrates

The DDD reaction of Barnett and Seligman for —SH groups.

The DNFB reaction (Tranzer and Pearse, 1964) for tyrosine, —SH and —NH₂ groups.

Lipids with sudan B in triethyl phosphate (after Casselman, 1959).

The periodic acid-Schiff (PAS) reaction for carbohydrates and the alcian blue (AB) reaction for acid mucopolysaccharides.

The methyl green-pyronin (MGP) procedure for nucleic acids, with ribonuclease control.

Cryostat sections were also stained with haematoxylin and eosin, and for reticulin (Gordon and Sweets, 1936).

RESULTS

Normal structures

The normal histochemistry of rat salivary glands and adjacent lymph-nodes in the animals studied is recorded in tables I–IV. There was no significant variation among the control animals. Detailed descriptions of the anatomy, histology and development of the salivary glands are available in reports by Greene (1935), Stormont (1932), Jacoby and Leeson (1959), English (1955) and Cherry and Glücksmann (1959).

For our purposes it is necessary only to emphasise that maturation of the submandibular gland is not complete in the 9-wk-old rat used for these experiments. The intralobular ducts are not yet fully differentiated into convoluted tubules and striated ducts. That part of the intralobular duct destined to become the convoluted tubule is characterised by vacuolation in some of its cells. Histochemical reactions in this developing convoluted tubule tended to be more variable and patchy than in the striated duct.

The description below is intended to summarise the findings presented and to amplify points that are not apparent from the tables.

Submandibular gland. Ducts showed the highest concentrations of dehydrogenases, generally progressively decreasing from interlobular ducts through striated ducts and convoluted tubules to intercalated ducts. An exception to this was the relatively high concentration of α GP-DH found in intercalated ducts. Acinar cells generally

TABLE I
Enzyme and staining reactions in the normal submandibular gland

Technique	Over-all Intensity	Interlobular ducts	Intralobular ducts		Intercalated ducts	Acini	Basket cells
			Striated	Convoluted			
NAD-D	moderate	++++	+++	++ p	+	±	CD
NADP-D	light	+++	++	+	+	±	+
S-DH	moderate	++++	++++	+++ p	+	+	CD
IC-DH	moderate	++	++	+	+	±	±
M-DH	v. light	++	++	+	±	±	±
L-DH	v. light	+	±	±	±	±	++ to ++++
G6P-DH	moderate	++++	+	±	±	+	CD
α GP-DH	moderate	+++	++ to +++ p	+ to ++ p	+++	+	CD
β OHB-DH	light	+++	++	+	++	±	++
Ubq.	strong	++ to +++	++	++	+ to ++	++	CD
AlkPase	moderate	-	-	-	++ to +++	±	++
AcPase	moderate	+++ to ++++	++	++	+	+ to ++	CD
NSEase	moderate	+++	++	+ to ++	+	+	CD
Indoxyl est.	moderate	+++	+++	++ p	+	+	CD
β -Gase	strong	+++	++ to +++	++ p	+	+	CD
Cyt. ox.	moderate	++++	+++ to ++++	+++ p	±	++	CD
MAO	light	++ to +++	++	+	±	±	CD
LAP	moderate	+	+	+	+++	±	CD
Sudan B	moderate	++	++	++ p	±	+	CD
AB	light	-	-	-	-	++	CD
PAS	light	+	+	+	+	++	CD
DNFB	moderate	++	++	++	++	+	CD
DDD	moderate	+++	++ to +++	++	++	+	CD

Abbreviations for techniques as in text.

Relative intensity of staining of different elements by each technique is indicated by ± to +++++. Comparisons between techniques may be judged by considering "over-all intensity" of staining.

Where serous cells or basket cells could not be distinguished as such the abbreviation CD is used.

The adscript "p" used in table I means patchy or variable staining.

showed lower dehydrogenase concentrations than ducts. Basket cells ("myo-epithelial" cells) could not always be distinguished. They were shown well by the alkaline phosphatase and lactic dehydrogenase techniques.

The ubiquinone reaction appeared as a coarse-grained green-blue deposit within ducts, and a fine-grained blue reaction in the acinar cells. It was mainly mitochondrial in distribution, but extramitochondrial deposits were also present in acinar cells.

TABLE II
Enzyme and staining reactions in the normal sublingual gland

Technique	Over-all intensity	Interlobular ducts	Intralobular ducts		Intercalated ducts	Mucous acini	Serous cells	Basket cells
			Large	Small				
NAD-D	moderate	++++	++++	++++	±	±	+	CD
NADP-D	moderate	++	+	+	±	± to +	+	CD
S-DH	moderate	++++	++++	++++	±	±	+	CD
IC-DH	light	++	+	+	+	+	+	+
M-DH	v. light	++	++	++	±	+	+	+
L-DH	v. light	+	+	+	±	±	+	+
G6P-DH	light	+++	±	±	±	±	+	CD
αGP-DH	moderate	++	+	+	++	+	+++	CD
βOHB-DH	light	++	+	±	+	±	±	+
Ubq.	strong	++	++	++	+ to ++	+ to ++	++ to ++	++
AlkPase	moderate	-	-	-	-	±	±	++ to +++
AcPase	moderate	+++ to ++++	++ to +++	++	+ to ++	+	+ to ++	CD
NSEase	moderate	+++	+++	+++	+	+	++	CD
Indoxyl est.	moderate	+++	+++	+++	±	±	+ to ++	CD
β-Gase	strong	+++ to ++++	+++ to ++++	+++ to ++++	±	±	++	CD
Cyt. ox.	moderate	+++	+++	+++	+	+	+	CD
MAO	light	++ to +++	++	++	+	±	+ to ++	CD
LAPase	light	+ to ++	+ to ++	+ to ++	+	±	++	CD
Sudan B	moderate	++	++	++	-	±	+	CD
AB	strong	-	-	-	-	+++	+	-
PAS	moderate	-	-	-	-	+++	CD	-
DNFB	moderate	++	++	++	++	±	+	CD
DDD	moderate	+++	+++	+++	+	±	++	CD

See footnote to table I.

Alkaline phosphatase was found in some capillaries, in adventitial spindle cells of arteries and veins, and in spindle and basket cells around ducts and acini. A slight reaction was seen in intercalated ducts and very faint deposits in the basal parts of acinar cells. Other ducts were completely negative.

Acid phosphatase was present as fine granules in progressively decreasing concentrations from interlobular to intercalated ducts, but some faint diffuse acinar staining could also be seen.

Interlobular ducts showed high levels of non-specific esterase activity, also decreasing in intralobular and intercalated ducts. The α-naphthyl acetate method best demonstrated patchy and globular staining of increased intensity on the lumen side of duct cells. Nerve

fibres and autonomic ganglion cells were particularly well demonstrated by the indoxyl acetate method.

The aminopeptidase (or peptidases) revealed by the method of Nachlas, Crawford and Seligman (1957) was especially strong in intercalated ducts, and even stronger in mast cells. A few fine LAPase positive granules were also seen in the other ducts and a very faint reaction in acini.

TABLE III
Enzyme and staining reactions in the normal parotid gland

Technique	Over-all intensity	Inter-lobular ducts	Intralobular ducts		Inter-calated ducts	Acini
			Large	Small		
NAD-D	moderate	+++	++	++	±	±
NADP-D	moderate	+++	+++	++	+	++
S-DH	moderate	+++ to ++++	+++	++ to +++	+	+
IC-DH	light	+	+	+	±	±
M-DH	v. light	+	±	±	±	±
L-DH	light	±	±	±	++	+
G6P-DH	light	+	+	+	+	+
αGP-DH	moderate	++ to +++	++	++	++	+
βOHB-DH	light	+	+	+	++	±
Ubq.	strong	++	++	++	+	++
AlkPase	moderate	-	-	-	+++	-
AcPase	moderate	++	++	+	++	+
NSEase	moderate	++	++	++++	+	++
Indoxyl est.	moderate	++ to +++	++	++	+	++
β-Gase	strong	+++	+++	+++	+	+
Cyt. ox.	moderate	++++	+++	++	+	+
MAO	light	++	++ to +++	+	+	+
LAPase	v. light	++	+	±	-	-
Sudan B	moderate	++	++	+	±	+
AB	light	-	-	-	-	+
PAS	light	++	++	++	++	+
DNFB	moderate	++	++	++	++	+
DDD	moderate	++ to +++	++	++	++ to +++	+

See footnote to table I.

Sudan black B staining was mainly mitochondrial, the basal striations of the striated ducts staining well. However, some non-mitochondrial staining was also present.

The DNFB reaction was most intense in collagen, but ducts and acini also stained well. Nuclei stained very faintly or not at all. With the DDD reaction for sulphhydryl groups nuclear staining was evident, but less than in the parotid. This finding was similarly reported by Kawakatsu *et al.* (1962).

Lumen contents were strongly AB and PAS positive.

Sublingual gland. Most of the substances studied showed distributions and concentrations analogous to those found in the submandibular gland. The products of reactions in the mucous acinar cells

HISTOCHEMICAL EFFECTS OF RADIATION

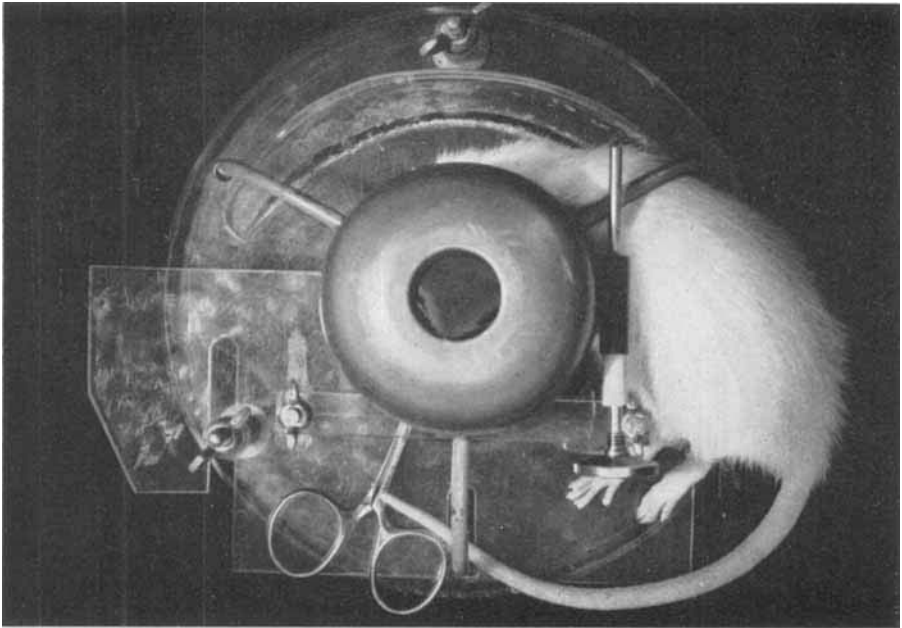


FIG. 1.—Position of rat in jig with skin flap pulled ventrally. The salivary gland-lymph node complex is drawn into the field of radiation with the skin and subcutaneous tissue. A lead shield protects the trachea, oesophagus and other neighbouring structures.

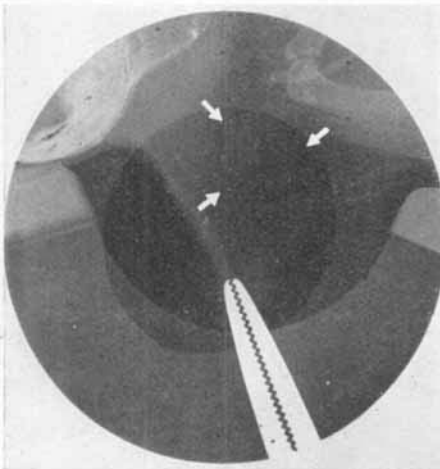


FIG. 2.—Radiograph of the rat in position (cf. fig. 1) shows the salivary gland-lymph node complex as a soft tissue shadow in the skin flap (arrows). It lies within the field outlined by the lead, which was removed during the course of this exposure and appears here as the semi-opaque outer grey ring.

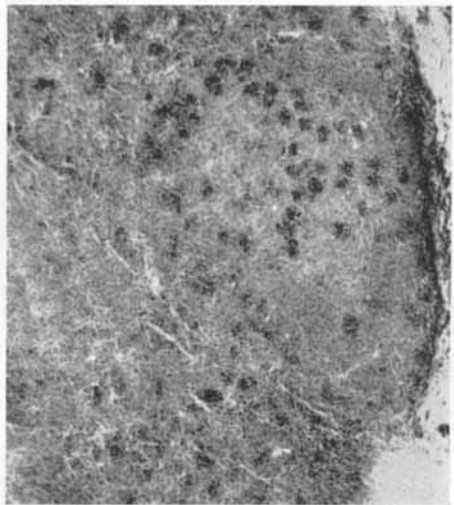


FIG. 3.—Lymph-node 4 hr after 4000 rads. Fragmented and deeper staining necrotic cells in follicle and in cortical pulp. Unfixed cryostat section. Haematoxylin and eosin. $\times 100$.

HISTOCHEMICAL EFFECTS OF RADIATION

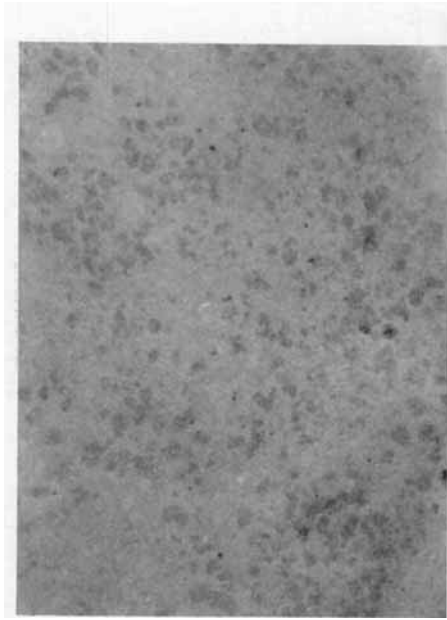


FIG. 4a.—Eight hours after 4000 rads.




FIG. 4b.—Normal lymph-node for comparison. Histiocytes are slightly darker staining than other lymphoid elements, particularly in follicles. No irradiation.

FIG. 4.—Lymph-nodes. Increase in enzyme activity in histiocytes after irradiation. Cytochrome oxidase. $\times 100$.

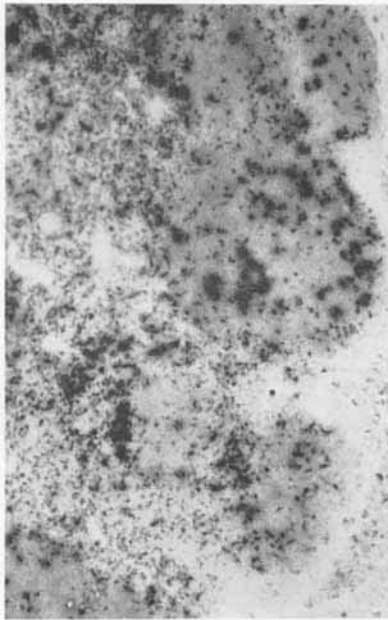


FIG. 5a.—Twenty-four hours after 4000 rads.

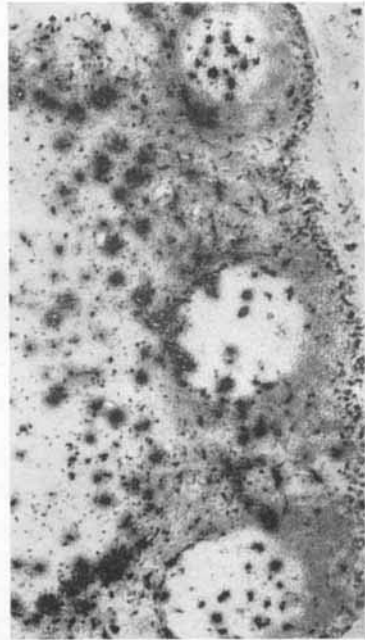


FIG. 5b.—Normal lymph-node for comparison. No irradiation.

FIG. 5.—Lymph-nodes showing increased acid phosphatase activity diffusely throughout the follicle after irradiation. Acid phosphatase. $\times 75$.

HISTOCHEMICAL EFFECTS OF RADIATION

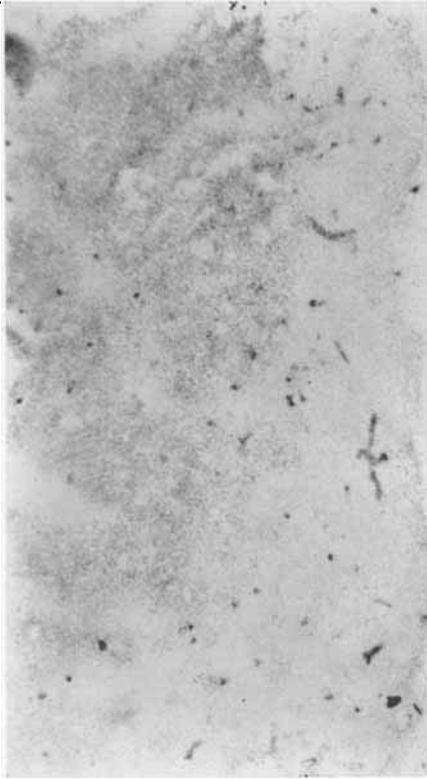


FIG. 6a.—Seventeen days after 4000 rads.

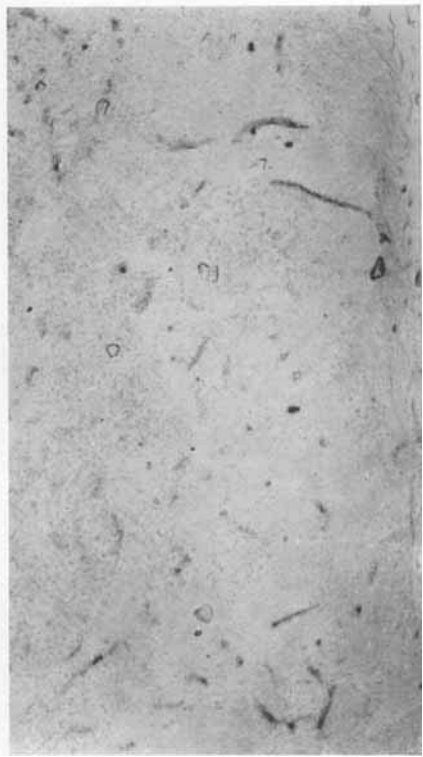


FIG. 6b.—Normal lymph-node for comparison. No irradiation.

FIG. 6.—Lymph-nodes showing increased alkaline phosphatase in the medulla as a relatively late change following irradiation. Alkaline phosphatase $\times 90$.

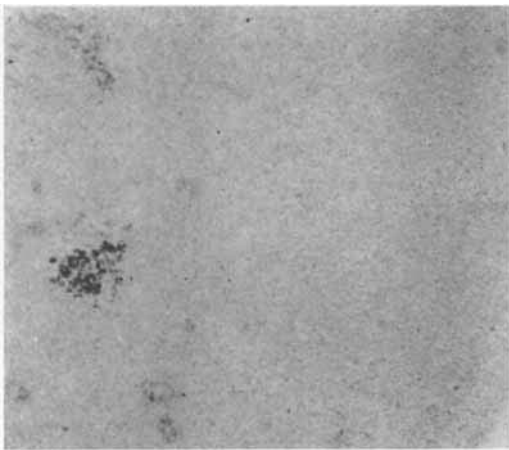


FIG. 7.—Eight days after 4000 rads. A cluster of necrotic cellular debris remaining within this lymph-node still shows activity of some enzymes. NAD diaphorase. $\times 100$.

HISTOCHEMICAL EFFECTS OF RADIATION

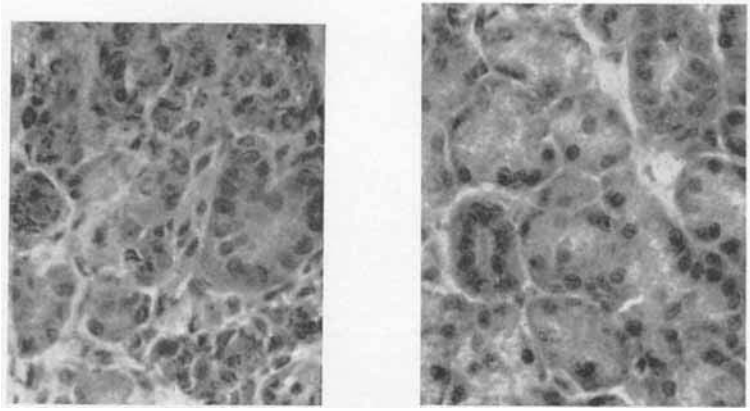


FIG. 8a. Twenty-four hours after 4000 rads.

FIG. 8b.—Normal parotid for comparison. No irradiation.

FIG. 8.—Focal necrosis within acinar cells of the parotid was the first morphological change seen in salivary glands following irradiation. Unfixed cryostat section. HE. $\times 370$.

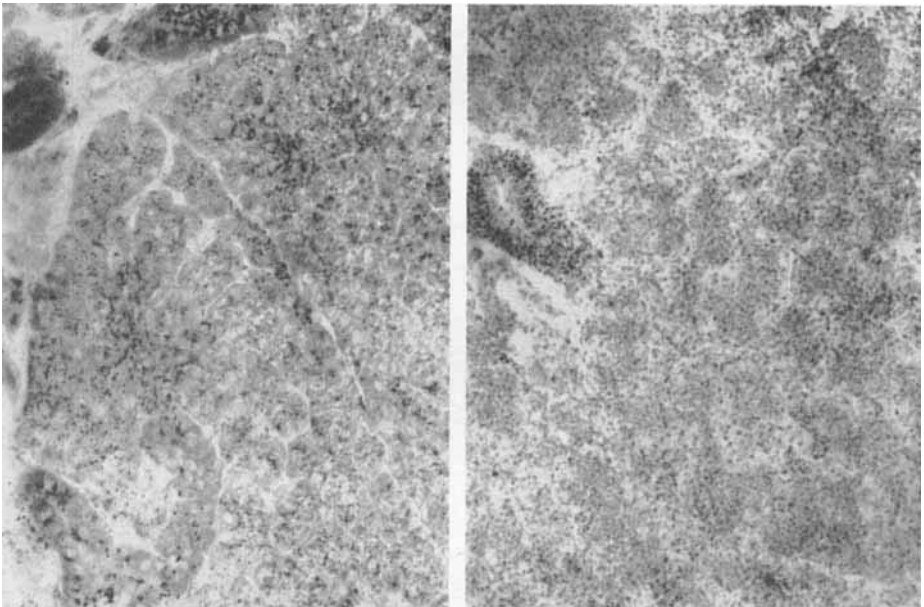


FIG. 9a.—Eight hours after 4000 rads.

FIG. 9b.—Normal parotid for comparison. No irradiation.

FIG. 9.—A striking loss of parotid acinar acid phosphatase preceded morphological changes after irradiation. Residual enzyme activity was very coarsely granular. Intra-lobular ducts also showed loss of enzyme activity and coarse granularity. Acid phosphatase. $\times 280$.

HISTOCHEMICAL EFFECTS OF RADIATION

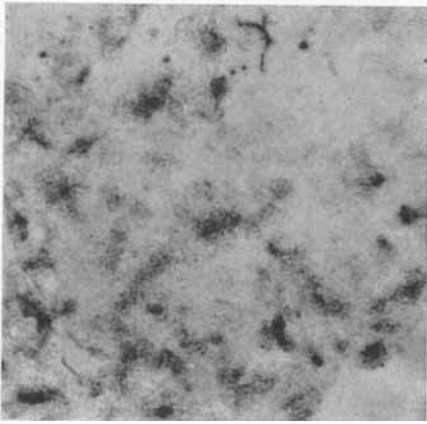


FIG. 10a.—Parotid gland 17 days after 4000 rads.

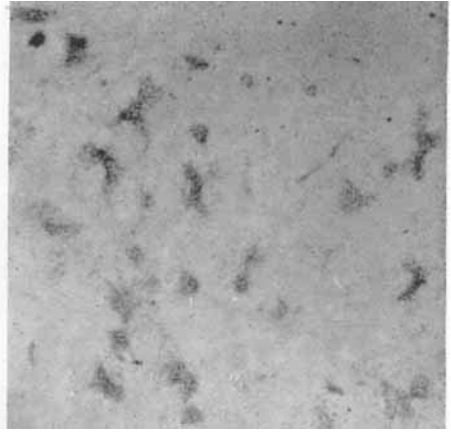


FIG. 10b.—Normal parotid gland for comparison. No irradiation.

FIG. 10.—Alkaline phosphatase is normally quite strong in parotid intercalated ducts and brings them out sharply. Following radiation there is a diffuse increase in the activity of this enzyme in surrounding structures also, and the ducts are then less sharply defined. This is a relatively late change and because of loss of acinar tissue the intercalated ducts are crowded together. Alkaline phosphatase. $\times 100$.

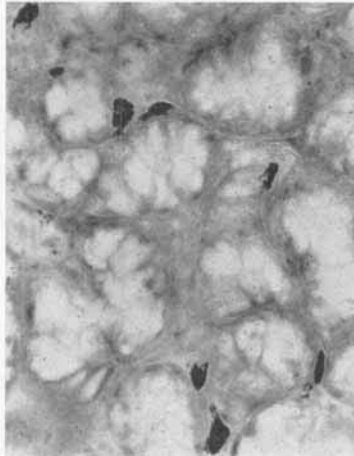


FIG. 11a.—Seventeen days after 4000 rads.

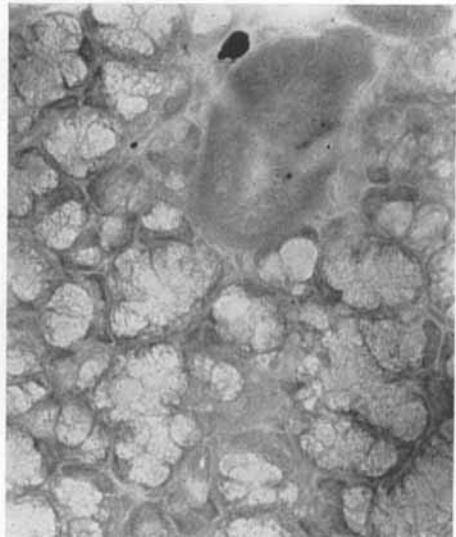


FIG. 11b.—Normal sublingual gland for comparison, showing one of the very few mast cells which may be present in periductal connective tissue. No irradiation.

FIG. 11.—Sublingual salivary gland showing mast cell infiltration, a relatively late response to irradiation. Unfixed cryostat section. Methyl green-pyronin. Orange filter. $\times 280$.

HISTOCHEMICAL EFFECTS OF RADIATION

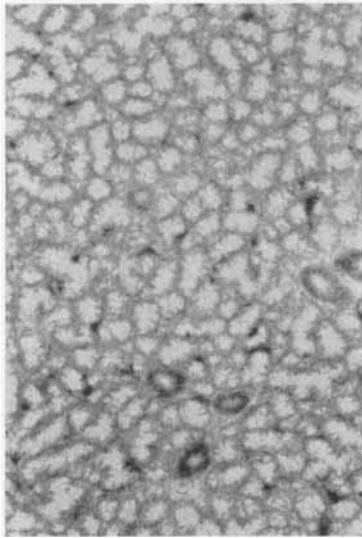


FIG. 12a.—Eight days after 4000 rads.

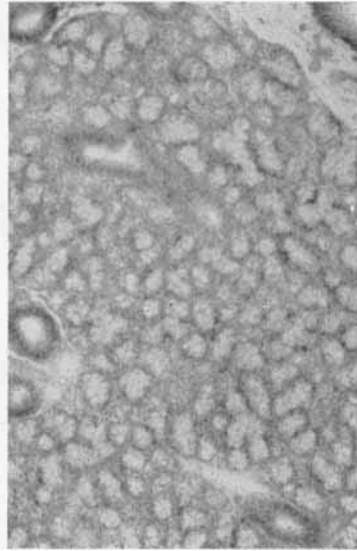


FIG. 12b.—Normal sublingual gland for comparison. No irradiation.

FIG. 12.—Sublingual salivary gland showing focal increase in acinar acid phosphatase after irradiation. Acid phosphatase. $\times 100$.

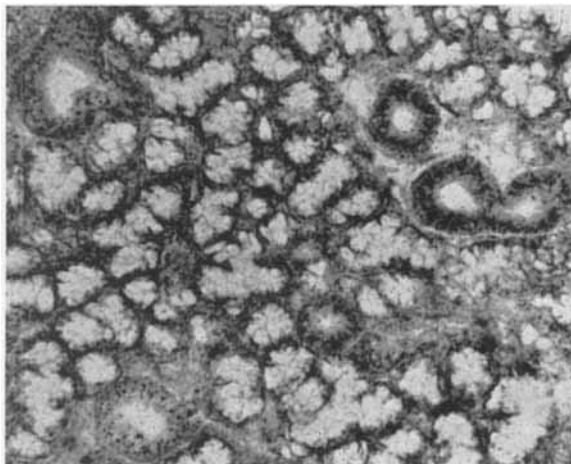


FIG. 13.—Very early after irradiation there was increased granularity in ducts of the sublingual gland stained for acid phosphatase. Here the two ducts on the left show this granularity, and there are minor changes in the branching duct on the right. 8 hours after 4000 rads. Acid phosphatase. $\times 170$.

HISTOCHEMICAL EFFECTS OF RADIATION

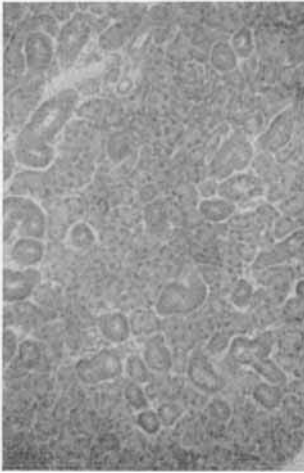


FIG. 14a.—Four days after 4000 rads the intercalated ducts show only very faint residual enzyme activity.

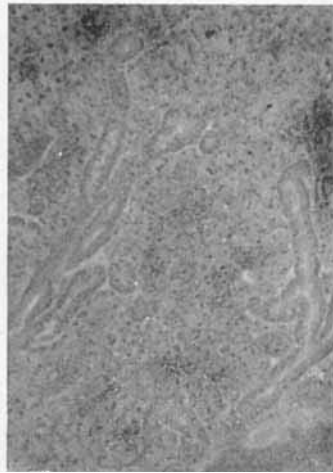


FIG. 14b.—Normal submandibular salivary gland for comparison. No irradiation.

FIG. 14.—Submandibular salivary gland showing loss of the normally strong aminopeptidase activity in intercalated ducts after irradiation. The "leucine aminopeptidase reaction".




FIG. 15.—Sublingual gland 22 days after 4000 rads. Numerous mast cells in the irradiated gland, showing very strong aminopeptidase activity. This illustrates the unique advantage of histochemistry in localising enzyme activity, and in this instance reminds us that apparent changes in homogenates of the entire gland can be produced by infiltration of extraneous cells. The "leucine aminopeptidase reaction". $\times 100$.

were mostly confined to the basal cytoplasm. Serous acinar cells contained higher concentrations of non-specific esterase, β -glucuronidase, and leucine aminopeptidase than were found in mucous acinar cells, and they were especially strong in α GP-DH. In contrast to the submandibular gland, the level of LAPase in the intercalated ducts

TABLE IV
Enzyme and staining reactions in normal lymph-nodes

Technique	Over-all intensity	Pulp lymphocytes	Lymphocytes in medullary cord	Follicles	Histiocytes	Other structures
NAD-D	light	+	+	± to +	++	...
NADP-D	light	+	+	+	++	...
S-DH	v. light	±	±	±	±	...
IC-DH	light	+	+	±	++	...
M-DH	v. light	±	±	±	+	...
L-DH	light	+	+	±	+ to ++	...
G6P-DH	light	+	+	±	++	...
α GP-DH	light	+	+	± to +	++	...
β OHB-DH	v. light	-	-	-	±	...
Ubq.	moderate	+	++ to +++	± to +	++	...
AlkPase	-	-	-	-	-	Capillaries ++ Neutrophils ++++
AcPase	moderate	++	++	± to +	++++	...
NSEase	moderate	+	+	±	++	...
Indoxyl est.	light	+	+ to ++	+	++	...
β -Gase	moderate	++	++ to +++	++	+++	...
Cyt. ox.	v. light	+	+	+	++	...
MAO	v. light	+	+	+	++	...
LAP	light	+	+++	±	+ to ++	...
Sudan B	light	+	++	+	+	...
AB	light	+	+	+	+	...
PAS	light	+	+	+	++ to +++	...
DNFB	moderate	+	+	+	+	...
DDD	light	++	++	++	++ to +++	...

See footnote to table I.

was no higher than in other parts of the duct system. Basket cells could not be distinguished as easily from acinar cells in L-DH preparations as in the submandibular gland.

The formazan deposits of the Ubq. reaction were blue-green and coarse in acini as well as ducts.

Parotid gland. In general the reaction products in parotid duct cells were coarser than in the other salivary glands. Interlobular ducts again tended to stain more strongly than their intralobular branches. Intense staining along the luminal surface of intralobular duct cells was quite striking with α -naphthyl esterase and more intense than in the ducts of the submandibular or sublingual glands where it was rather

patchy or globular. The intercalated ducts showed high concentrations of L-DH and AlkPase compared with acini and the other ducts. These two enzymes and β OHB-DH were also seen in spindle cells around acini, an appearance reminiscent of the spindle and basket cells seen in the submandibular gland. These have not to our knowledge been previously described. Parotid acinar cells were stronger in NADP-D and esterase than acinar cells of the other two salivary glands.

Acid phosphatase was present in acinar cells, almost entirely in the lumen half, giving a diffuse blue blush to the central part of the acini quite distinct from the fine granulations in the sublingual acinar cells.

Of interest was nuclear and nucleolar staining in acinar cells with the DDD reaction. This reaction is highly specific for sulphhydryl groups and would suggest their presence in the nuclei, if intracellular diffusion could be ruled out.

Lymph-node

In general the lymph-nodes were histochemically much less active than the salivary glands. Histiocytes were usually more reactive than other lymphoid elements, and in the case of acid phosphatase they stained intensely. Alkaline phosphatase was strong only in capillaries and neutrophils; there was a faint reaction in pulp lymphocytes, mostly in the medulla.

Irradiated structures

The rats withstood the procedures well, none dying before they were due to be killed. Those receiving 2000 rads showed erythema of the skin of the radiated area at 2 days, which proceeded to dry desquamation at 4 days, healed by 1 week and was never severe. The rat that was killed at 14 days showed epilation of the irradiated zone. All the animals in this group showed normal behaviour and activity. The skin changes in the 4000 rads group were more severe, proceeding to moist desquamation at 10 days and crusting over by 14 days. These were healing at 22 days when the experiment was terminated. Animals in this group were also otherwise well though their behaviour was somewhat subdued at about 10-14 days.

Histochemical and histological changes were comparable in the two groups of radiated animals. Alterations were generally more marked and appeared sooner after 4000 rads.

Lymph-nodes

The earliest morphological changes were seen at 1½ hr following 4000 rads. Nuclear fragmentation of lymphocytes and lymphoblasts was then evident focally within follicles as has been described by other workers (de Bruyn, 1948; Jacobson *et al.*, 1950). Cellular

necrosis became more obvious at 4 and 8 hr and affected pulp lymphocytes as well (fig. 3). By 24 hr the follicle pattern was lost and there was histiocytic phagocytosis of the nuclear debris, which was already accumulating in small clumps. By two days these clumps of nuclear debris were apparently partially removed, but some were still visible, particularly in the sinuses. At 4 days little evidence of necrosis remained. Follicles were reforming at one week and by 2 weeks the nodes were again comparable to those of the control animals.

The earliest histochemical change was a general increase in enzyme activity in histiocytes, first those within and about follicles, and then elsewhere in the pulp (figs. 4*a* and *b*). Most notable was an increase in aminopeptidase, which was striking at 4 hr and possibly present as early as 30 min. Also increased at 4 hr were esterase, cytochrome oxidase, monoamine oxidase and a number of dehydrogenases particularly S-DH and M-DH. Similar increases were also seen in Ubq., lipids, sulphhydryl groups and AB- and PAS-positive material. These increases in histiocytes were transient; they reached a peak at about 8 hr and had diminished or disappeared by 1-2 days.

The follicles themselves showed an equally impressive change, but only in the case of acid phosphatase. At 4 hr their normally negligible acid phosphatase activity was increased to varying degrees, and by 8 hr had reached the level of the surrounding lymphoid pulp (figs. 5*a* and *b*). This persisted until new follicle formation occurred at 8-12 days.

The only enzyme change initiated after these first few hours was in alkaline phosphatase. Normally this enzyme is strong only in blood vessels and neutrophils. At 13 days there was a slight but definite increase in staining of pulp lymphocytes, mostly in the medullary cords. This was more marked at 17 days and still present but diminished at 22 days (figs. 6*a* and *b*).

Follicle reformation was marked by the appearance at 4 days of more pyroninophilic lymphoid cells, singly or in clusters, within the cortex. These accumulated into larger groups or nodules by one week, and made up true follicles by 2 weeks.

Many of the enzymes, particularly the dehydrogenases, and ubiquinone persisted despite cell death and could even be identified in the clusters of cell debris (fig. 7).

After 2000 rads histochemical and histological changes were qualitatively identical. Cell necrosis was first seen at 2 hr and increased histiocyte enzyme activity was noted at 4 and 8 hr. Follicular acid phosphatase was first increased at 8 hr, reached maximum intensity at 2-4 days, and was returning to normal with follicle reformation at one and two weeks.

Salivary glands

Parotid. The parotid was the most radiosensitive of the three major salivary glands. The earliest histological changes were seen at 24 hr

after 4000 rads; there was focal acinar cell necrosis with karyorrhexis and marked cytoplasmic eosinophilia (figs. 8*a* and *b*). Acinar necrosis became more extensive and was quite striking for the first few days. From 4 days on there was progressive loss of acinar substance with interstitial oedema, fibroblastic proliferation and histiocytic infiltration. By 17 days many lobules consisted only of intralobular and intercalated ducts with almost no acinar tissue. Intercalated ducts were prominent because of enlargement of their cells. Very little parotid tissue remained at 22 days.

Mast cells were fairly numerous in connective tissue around and within the degenerating parotid from 13 days onwards.

The earliest histochemical change occurred long before the first histological evidence of injury. Most striking was a loss of acid phosphatase from parotid acini at 8 hr (figs. 9*a* and *b*); what stain remained was very coarsely granular. This acinar change was maximal at 24 hr, and diffuse in contrast to the necrosis, which was focal. Acinar acid-phosphatase staining did not begin to return until 4 days. It was then still diminished, and coarsely granular rather than fine and diffuse. Even earlier, in acid-phosphatase preparations, there were changes in intralobular ducts, which showed patchy loss of stain and coarse granular aggregates at 4 hr. This persisted for the duration of the experiment.

Aminopeptidase showed slight increases in ducts at 24 hr and possibly as early as 4 hr. By 4 days increased staining was quite distinct and also coarsely granular, involving acini as well as ducts.

With the focal acinar cell necrosis, which occurred at 24 hr, there was an apparent increase in staining intensity of affected cells with many of the histochemical techniques. This was heightened by the refractile granular appearance of the degenerating cytoplasm.

As in the lymph-nodes, the only enzyme change initiated late was in alkaline phosphatase. At 17 days this enzyme, which is normally very strong in intercalated ducts and brings them out quite sharply, was apparently increased and diffusely present also in surrounding structures (figs 10*a* and *b*).

Sublingual gland. Morphological changes were unimpressive. Only at 22 days after 4000 rads was there a suggestion of interacinar separation, possibly due to oedema. There was, however, an infiltration of mast cells throughout the substance of the sublingual gland, appearing at 13 days and quite striking by 17 days (figs. 11*a* and *b*).

The most obvious histochemical change was a focal increase in acid phosphatase in scattered acinar cells (figs. 12*a* and *b*). This was first distinguished at 2 days after 4000 rads and gradually became more marked until the termination of the experiment at 22 days. As in the parotid, with acid phosphatase, coarse granular aggregates were seen in intralobular ducts at 4 hr. This change was marked at one day and still present at 4 days, but was not seen at later stages (fig. 13). Similar coarse aggregates in ducts were seen with aminopeptidase.

but this change was not as marked, did not appear until one day, and persisted until the end of the experiment.

After 2000 rads the same focal increase in acinar cell acid phosphatase was found, and at approximately the same times. There was no change in duct staining. The mast cell infiltration first seen at 13 days after 4000 rads was not present at 14 days after 2000 rads.

Submandibular gland. No histological changes were seen in the submandibular gland. The most notable histochemical change was a rapid decrease in the normally high aminopeptidase activity of intercalated ducts at one day after 4000 rads. By 13 days no aminopeptidase activity remained in intercalated ducts and none returned at later stages (figs. 14*a* and *b*).

Minor changes in aminopeptidase and acid phosphatase were again seen in intralobular ducts. There was increased granularity, barely perceptible in aminopeptidase preparations at one day, but seen at 8 hr with acid phosphatase. From 4 days on these changes were more marked and were still present at 22 days. A subtle change in acinar acid phosphatase was seen at 8 hr and persisted thereafter. This was a loss of the diffuse stain normally present, with formation of granular aggregates. This change resembled that in parotid acini, but was minimal.

After 2000 rads, decreased intercalated duct aminopeptidase was first noticed at 2 days. There was minimal activity at 4 days and one week, with some return at 2 weeks. Other ducts and acini appeared unaffected.

DISCUSSION

If one accepts, as a working hypothesis, that the disruption of intracellular enzyme systems initiates cell damage after irradiation, histochemical changes would be expected before visible histological damage. This in fact was our finding. Quantitative and qualitative changes in aminopeptidase and acid phosphatase were present as early as 4-8 hr after irradiation, and long before there was histological evidence of cell damage. The fact that these two enzymes, of all that we studied, were selectively affected in different tissues suggests a common underlying mechanism.

de Duve (1958) showed that certain hydrolytic enzymes, including acid phosphatase, are confined within intracellular organelles which he termed "lysosomes". He also showed that release of these enzymes is effected by damage to the phospholipid "membrane" that confines them (Beaufay and de Duve, 1959). In a review of the biochemical and biophysical work on radiation cell damage Bacq and Alexander (1961) suggest that radiation could disrupt phospholipid membranes, releasing hydrolytic enzymes. It is tempting to believe that this is the mechanism that produced the early enzyme changes we observed. Against this theory is the lack of proof that aminopeptidase is a lysosomal enzyme. Furthermore recent work by Sylvén and Bois (1962-64) suggests

that the histochemical procedure for leucine aminopeptidase may be demonstrating a group of metal-dependent enzymes with affinity for aminoacyl-naphthylpeptides that are distinct from the leucine-amide-splitting aminopeptidases. The lack of appreciable change in cathepsin, as demonstrated by the non-specific esterase technique and in β -glucuronidase, both of which are lysosomal enzymes, may be due to lack of sensitivity of the techniques—or perhaps certain phospholipid membranes are more susceptible to radiation damage than others; but this is entirely speculative.

We found no alteration in other enzymes prior to morphological damage to suggest early mitochondrial disruption. Mitochondrial enzymes such as NAD diaphorase tended to persist after cell death, even in aggregates of necrotic cell debris within the lymph-nodes (fig. 7).

If one accepts that enzyme release initiates cell damage after radiation, it is necessary to explain why this sequence was not observed in the lymph-nodes. Nuclear damage is visible very early in lymphoid tissue and it is possible that another mechanism, such as direct chromosomal damage or damage to nuclear membranes is more important. This may distinguish radiosensitive from relatively radioresistant tissues and is possibly related to rate of cell turnover. Certainly lymphoblasts within the follicles, which have the highest mitotic rate, were the first to show necrosis. Alternatively it is possible that other enzymes, not studied by us, for example desoxyribonuclease, may be released from cytoplasmic structures and attack DNA (Bacq and Alexander, 1961).

The histochemical changes in histiocytes within lymph-nodes covered a wide range. In addition to a general increase in enzyme activity, there were increases in free sulphhydryl groups, lipids, carbohydrates and ubiquinone. This we interpreted as evidence of increased metabolism rather than cell damage. Similar changes in histiocytes have been noted in human hyperplastic lymph-nodes after a variety of stimuli, and we consider appropriate the term "active histiocytes" used to describe them (Braunstein *et al.*, 1962).

The only late enzyme change we found was in alkaline phosphatase, which was increased in lymph-nodes and parotid. The significance of this finding is not clear. It seems just as likely to be a reflection of increased metabolic activity with repair as of direct but delayed radiation damage.

In discussing possible mechanisms of cell damage radiation, we have thus far omitted any reference to endocrine or humoral factors. We feel that the technique used for selective irradiation of the salivary gland-lymph node complex effectively eliminated any possibility of radiating other vital structures. Much higher radiation doses were possible than could have been used with whole body exposure.

Morphological changes in the lymph-nodes and salivary glands were generally the same as those found by others (de Bruyn, 1948; Chang, 1960; and Jacobson *et al.*, 1950, in lymph-nodes; Shafer, 1953; English, 1955; and Cherry and Glücksmann, 1959, in salivary

glands). Minor differences are probably the result of variation in technique and species and strain of animal used.

The unique advantage of localisation which histochemical techniques offer is valuable not only in assigning enzyme changes that occur in an organ to specific cells or tissues but also in demonstrating that some changes may be adventitious—due to infiltration of extraneous cells. Mast cells seen in the sublingual gland, for example, are very high in aminopeptidase (fig. 15) whilst histiocytes, which were numerous in and around the degenerating parotid, are high in acid phosphatase. Biochemical measurements of these enzymes in homogenates would be misleading. Why the sublingual gland in particular was so heavily infiltrated with mast cells is not clear. It is tempting to develop the speculation of Riley (1959) on the possible role of mast cells in the storage of mucopolysaccharides, which are more abundant in the sublingual gland than in the other salivary glands.

We did not see changes in enzymes other than those mentioned. It is well to bear in mind that minor differences in enzyme activity are not easily assessed by the subjective grading system used here. This is particularly true when changes are entirely quantitative rather than qualitative and when they are diffuse. Possibly that is why we were unable to confirm the very slight increase in glucose-6-phosphate dehydrogenase that English found in salivary gland homogenates after irradiation (English, 1956). When changes are well localised, even slight variations are easily appreciated.

The qualitative changes described, particularly in salivary gland ducts where acid phosphatase and aminopeptidase assumed an abnormally coarse granular appearance after irradiation, suggest damage to cell organelles at the submicroscopic level. It would be exceedingly interesting to carry this study a stage further with investigations of acid phosphatase at the electron-microscope level, and this work is now in progress.

SUMMARY

To study the possible role of disrupted enzyme systems in effecting cell damage following irradiation, a survey of histochemical examinations was carried out on normal and on locally irradiated major salivary glands and lymph-nodes of the rat. Striking alterations in acid phosphatase and aminopeptidase appeared very early in all of the salivary glands and were found to precede morphological evidence of cell injury. In the lymph-nodes there was an equally prompt change in acid phosphatase in follicles, but this did not precede the rapidly developing focal cellular necrosis. Also, there was a transient, general, increased intensity of many histochemical reactions in histiocytes.

The only histochemical change initiated late was in alkaline phosphatase, which increased slightly in lymph-nodes and parotid salivary gland after about 2 weeks.

The significance of these changes is discussed, particularly in reference to the enzyme release theory of radiation injury and the lysosomal concept.

The authors would like to thank Miss T. Alper and Dr R. H. Thomlinson for advice and facilities, and in particular to thank Mr B. Dixon who performed the irradiation. The photomicrographs were taken by Mr W. Brackenbury.

One of us (M.R.M.) was supported by U.S. Public Health Service Special Research Fellowship no. 1-F3-CA19, 361-01 from the National Cancer Institute.

REFERENCES

- ALEXANDER, P., AND BACQ, Z. M. 1961. *In* The initial effects of ionizing radiations on cells, ed. by R. J. C. Harris, *London*, p. 10.
- BACQ, Z. M., AND ALEXANDER, P. 1961. *Fundamentals of radiobiology*, 2nd ed., *Oxford*, p. 272.
- BEAUFAY, H., AND DE DUVE, C. . . . 1959. *Biochem. J.*, **73**, 604.
- BRAUNSTEIN, H., FREIMAN, D. G., THOMAS, W., JR, AND GALL, E. A. 1962. *Cancer (Philad.)*, **15**, 130.
- CASSELMAN, W. G. B. 1959. *Histochemical technique*, *London*, p. 72.
- CHANG, J. T. 1960. *Sci. Sinica*, **9**, 671.
- CHERRY, CORA P., AND GLÜCKSMANN, A. 1959. *Brit. J. Radiol.*, **32**, 596.
- DE BRUYN, P. P. H. 1948. *In* *Histopathology of irradiation from external and internal sources*, ed. by W. Bloom, *New York*, p. 348.
- DE DUVE, C. 1958. *Bull. Acad. roy. Méd. Belg.*, **23**, 608.
- ENGLISH, J. A. 1955. *J. Dent. Res.*, **34**, 4.
- ” 1956. *Amer. J. Physiol.*, **186**, 245.
- GLENNER, G. G., BURTNER, HELEN J., AND BROWN, G. W., JR 1957. *J. Histochem. Cytochem.*, **5**, 591.
- GORDON, H., AND SWEETS, H. H., JR 1936. *Amer. J. Path.*, **12**, 545.
- GREENE, E. C. 1935. *Trans. Amer. Phil. Soc., N.S.*, **27**, 86.
- JACOBSON, L. O., SIMMONS, E. L. 1950. *J. Lab. Clin. Med.*, **35**, 745.
- MARKS, E. K., ROBSON, M. J., BETHARD, W. F., AND GASTON, E. O.
- JACOBY, F., AND LEESON, C. R. . 1959. *J. Anat.*, **93**, 201.
- KAWAKATSU, K., DEGUCHI, Y., OKA, R., AND TAKITA, Y. 1962. *J. Dent. Res.*, **41**, 104.
- NACHLAS, M. M., CRAWFORD, D. T., GOLDSTEIN, T. P., AND SELIGMAN, A. M. 1958. *J. Histochem. Cytochem.*, **6**, 445.
- NACHLAS, M. M., CRAWFORD, D. T., AND SELIGMAN, A. M. 1957. *Ibid.*, **5**, 264.
- PEARSE, A. G. E. 1960. *Histochemistry, theoretical and applied*, 2nd ed., *London*.
- RILEY, J. F. 1959. *The mast cells*, *Edinburgh*, p. 163.
- SELIGMAN, A. M., NACHLAS, M. M., MANHEIMER, L. H., FRIEDMAN, O. M., AND WOLF, G. 1949. *Ann. Surg.*, **130**, 333.

- SHAFFER, W. G. 1953. *J. Dent. Res.*, **32**, 796.
STORMONT, D. L. 1932. *In Special cytology*, ed. by E. V. Cowdry, *New York*, vol. 1, p. 151.
SYLVÉN, B., AND BOIS, I. 1962-64. *Histochemie*, **3**, 341.
THOMLINSON, R. H. 1960. *Brit. J. Cancer*, **14**, 555.
TRANZER, J. P., AND PEARSE, A. G. E. 1963. *Nature (Lond.)*, **199**, 1063.
" " " " 1964. *J. Histochem. Cytochem.*, **12**, 325.