

UC Irvine

UC Irvine Previously Published Works

Title

Acute Respiratory Distress Syndrome as an Organ Phenotype of Vascular Microthrombotic Disease: Based on Hemostatic Theory and Endothelial Molecular Pathogenesis

Permalink

<https://escholarship.org/uc/item/8wn3v51t>

Author

Chang, Jae C

Publication Date

2019-11-28

DOI

10.1177/1076029619887437

Peer reviewed

Acute Respiratory Distress Syndrome as an Organ Phenotype of Vascular Microthrombotic Disease: Based on Hemostatic Theory and Endothelial Molecular Pathogenesis

Clinical and Applied
Thrombosis/Hemostasis
Volume 25: 1-20
© The Author(s) 2019
Article reuse guidelines:
sagepub.com/journals-permissions
DOI: 10.1177/1076029619887437
journals.sagepub.com/home/cat



Jae C. Chang, MD¹

Abstract

Acute respiratory distress syndrome (ARDS) is a life-threatening noncardiogenic circulatory disorder of the lungs associated with critical illnesses such as sepsis, trauma, and immune and collagen vascular disease. Its mortality rate is marginally improved with the best supportive care. The demise occurs due to progressive pulmonary hypoxia and multi-organ dysfunction syndrome (MODS) with severe inflammation. Complement activation is a part of immune response against pathogen or insult in which membrane attack complex (MAC) is formed and eliminates microbes. If complement regulatory protein such as endothelial CD59 is underexpressed, MAC may also cause pulmonary vascular injury to the innocent bystander endothelial cell of host and provokes endotheliopathy that causes inflammation and pulmonary vascular microthrombosis, leading to ARDS. Its pathogenesis is based on a novel “two-path unifying theory” of hemostasis and “two-activation theory of the endothelium” promoting molecular pathogenesis. Endotheliopathy activates two independent molecular pathways: inflammatory and microthrombotic. The former triggers the release inflammatory cytokines and the latter promotes exocytosis of unusually large von Willebrand factor multimers (ULVWF) and platelet activation. Inflammatory pathway initiates inflammation, but microthrombotic pathway more seriously produces “microthrombi strings” composed of platelet-ULVWF complexes, which become anchored on the injured endothelial cells, and causes disseminated intravascular microthrombosis (DIT). DIT is a hemostatic disease due to lone activation of ULVWF path without activated tissue factor path. It leads to endotheliopathy-associated vascular microthrombotic disease (EA-VMTD), which orchestrates consumptive thrombocytopenia, microangiopathic hemolytic anemia, and MODS. Thrombotic thrombocytopenic purpura (TTP)-like syndrome is the hematologic phenotype of EA-VMTD. ARDS is one of organ phenotypes among MODS associated with TTP-like syndrome. The most effective treatment of ARDS can be achieved by counteracting the activated microthrombotic pathway based on two novel hemostatic theories.

Keywords

acute respiratory distress syndrome (ARDS), complement activation, disseminated intravascular coagulation (DIC), disseminated intravascular microthrombosis (DIT), endotheliopathy, endotheliopathy-associated vascular microthrombotic disease (EA-VMTD), hemostatic disorder, microthrombogenesis, multi-organ dysfunction syndrome (MODS), TTP-like syndrome, vascular microthrombotic disease (VMTD)

Date received: 27 June 2019; revised: 11 September 2019; accepted: 5 October 2019.

Background

Acute respiratory distress syndrome (ARDS) is caused by severe pulmonary vascular dysfunction characterized by acute onset of dyspnea, tachycardia, hypoxemia associated with noncardiogenic pulmonary edema, and systemic inflammation. Although the exact pathophysiologic mechanism causing pulmonary vascular dysfunction has not been determined yet, it is a circulatory

¹ Department of Medicine, University of California, Irvine School of Medicine, Irvine, CA, USA

Corresponding Author:

Jae C. Chang, Department of Medicine, University of California Irvine School of Medicine, 33 Rose Trelis, Irvine, CA 92603, USA.
Email: jaec@uci.edu



Creative Commons Non Commercial CC BY-NC: This article is distributed under the terms of the Creative Commons Attribution-NonCommercial 4.0 License (<http://www.creativecommons.org/licenses/by-nc/4.0/>) which permits non-commercial use, reproduction and distribution of the work without further permission provided the original work is attributed as specified on the SAGE and Open Access pages (<https://us.sagepub.com/en-us/nam/open-access-at-sage>).

dysfunction often associated with moderate thrombocytopenia¹⁻³ and multi-organ dysfunction syndrome (MODS).⁴⁻⁶ Because its pathogenetic mechanism is not clearly recognized, no effective therapeutic agent targeting the underlying pathologic disease has been procured to date. Ventilator support, fluid and electrolyte balances, and cardiopulmonary monitoring with the best supportive care have marginally improved the outcome of ARDS in several decades. Mortality rate is still very high. It increases with disease severity. In a multicenter, international, prospective cohort study of 3022 patients with ARDS, unadjusted hospital mortality was reported to be 35% among those with mild ARDS, 40% for those with moderate disease, and 46% for patients with severe ARDS.⁷

Recently, two proposed hemostatic mechanisms have opened the door in the understanding of ARDS from molecular pathogenesis associated with endotheliopathy that promotes inflammation and coagulation disorder in sepsis and other critical illnesses⁸⁻¹¹; one is “two-activation theory of the endothelium” in which endothelial pathogenesis activates inflammatory pathway and microthrombotic pathway and the other is a novel “two-path unifying theory” of hemostasis in which hemostasis initiates thrombogenesis and promotes microthrombogenesis, leading to vascular microthrombotic disease (VMTD).^{8,10,12,13} These two theories are congruous each other since the endothelium contributes to initial hemostasis and triggers molecular mechanism for thrombogenesis. In endotheliopathy, the pathologic nature of inflammation promoting inflammatory response¹² is recognized and the character of “microthrombi” leading to multiple hematologic phenotypes is identified.⁹ In addition, the true mechanism of *in vivo* hemostasis in vascular injury and three different thrombogenic mechanisms within hemostasis are uncovered.^{8,10} Through the recognition of endothelial molecular pathogenesis, enough evidences have been accumulated that ARDS is one of the phenotypes of MODS occurring as a result of disseminated intravascular microthrombosis (DIT), which is the underlying pathology contributing to endotheliopathy-associated VMTD (EA-VMTD).^{1,9-11}

The objective of this article is to analyze the clinical, pathological, and hematopathological features of ARDS and to account for involved pathophysiological mechanisms associated with endothelial dysfunction based on two hemostatic theories. In the end, this author will look into potential therapeutic option for the treatment of ARDS according to “theory-based medicine” instead of “evidence-based medicine” since clinical trials for ARDS have completely failed to find an effective therapeutic regimen.

Clinical and Pathological Characteristics of ARDS

Clinical Settings and Characteristics

The most common underlying condition in ARDS is severe infection (eg, sepsis/septic shock with or without severe pneumonia) due to various microbial pathogens, which include bacteria, viruses, fungi, rickettsia, and parasites. ARDS also occurs

in association with trauma to the chest/lungs and head/brain,^{14,15} complications of surgery, pregnancy and transplant,¹⁶⁻²⁰ certain drug, toxin, chemicals and venom exposure,²¹ and thrombotic thrombocytopenic purpura (TTP)-like syndrome.^{9,22-24} In addition, it also has developed in association with disseminated intravascular coagulation (DIC).²⁵⁻²⁷ Some clinicians have interpreted DIC was the cause of ARDS, but others proposed it was the result of complication of ARDS. Regardless, enough evidences have been presented that ARDS is a clinical disorder of pathologic hemostasis associated with activated coagulation system such as DIC.^{1-5,8-12} However, this author has placed quotation marks on “DIC” because recent reinterpretation has identified the current concept of “DIC” was ill-founded because it was based on the hemostatic mechanism of activated tissue factor (TF) path,^{1,8,9,11,12,28} which will be discussed briefly later in this article. Nonetheless, ARDS is one of the major organ phenotypic disorders among MODS contributing to the death associated with microthrombosis in critically ill patients due to diseases such as sepsis, trauma, and immune disorders.

As shown in Table 1, although ARDS often occurs in association with a variety of sepsis, it can be preceded by pneumonia as seen in severe respiratory distress syndrome (SARS) due to SARS-CoV²⁹ and Middle East respiratory syndrome (MERS) due to MERS-CoV³⁰ as well as bacterial, fungal, and parasitic pneumonia, especially pneumococcal in particular. The clinical feature of developing pneumonia before sepsis suggests organotropism plays an important role in certain pathogen as shown by SARS virus possessing specific affinity to the lungs.^{29,30} Sometimes ARDS occurs following blood transfusion, which is called transfusion-related acute lung injury (TRALI) that is characterized by acute noncardiogenic circulatory disorder of the lungs following blood product transfusions.^{31,32} Sepsis-associated ARDS, notwithstanding the absence of pneumonia, not uncommonly develops with other organ dysfunction such as encephalopathy,³³ hepatic failure,³⁴ acute renal failure,³⁵ and acute necrotizing pancreatitis.^{36,37} This multi-organ involvement suggests ARDS may not be primary disease but is likely a part of ongoing systemic pathogenetic mechanism due to infection or other critical illnesses as illustrated in Table 2.^{5,12} Now, the underlying physiologic alteration of MODS in sepsis and other critical illnesses is identified as circulatory dysfunction occurring as a result of EA-VMTD.¹¹⁻¹³ This is an extremely important concept in the understanding for the pathogenesis of MODS as well as ARDS because we now know that the culprit of MODS is DIT,^{1,8-12} which pathogenesis based on “two-activation theory of the endothelium” as shown in Figure 1.^{12,13}

Clinical and pathological features. The clinical features of ARDS are characterized by (1) acute onset of noncardiogenic respiratory distress, (2) bilateral pulmonary infiltrates, and (3) evidence of diffuse circulatory obstruction of pulmonary vasculature. In addition to acute respiratory distress, hematologic features of ARDS include thrombocytopenia,^{2,3,38-40} MODS,^{1,4-6,9-12} DIT,^{1,3,9,11} “DIC,”^{25,26,41-43} and TTP-like syndrome,²²⁻²⁴ as presented in Tables 1 and 2. These

Table 1. Examples of ARDS Associated With Pathogens, and Clinical and Hematologic Syndromes.

	Microbic Pathogens	Infectious Diseases	Clinical Phenotypes	Hematologic Phenotypes
Bacteria	G (–) bacteria such as <i>Escherichia coli</i> , <i>E coli</i> O157: H7, <i>Klebsiella pneumoniae</i> G (+) bacteria such as <i>Streptococcus pneumoniae</i> , <i>Staphylococcus aureus</i> , <i>Legionella pneumophila</i>	Sepsis/septic shock Pneumonia Gastroenteritis Glomerulonephritis Waterhouse-Friderichsen syndrome		
Viruses	Hantavirus Ebola virus Corona viruses Dengue virus Influenza A (H1N1) virus HIV	Epidemic hemorrhagic fever and viral sepsis Ebola viral hemorrhagic fever and viral sepsis SARS, MERS and pneumonia and viral sepsis Dengue fever and viral sepsis Influenza A infection and viral sepsis AIDS and viral sepsis	Encephalopathy FHF/ALF ARF/HUS AAI/septic shock Acute pancreatitis Rhabdomyolysis MODS SIRS	TCIP “DIC”/DIC DIT EA-VMTD/DIT MAHA TTP-like syndrome
Rickettsia	<i>Rickettsia rickettsii</i>	Rocky Mountain spotted fever and rickettsial sepsis		
Fungi	<i>Candida albicans</i>	Candida sepsis		
Parasites	<i>Plasmodium falciparum</i>	Malarial sepsis		

Abbreviations: AAI, acute adrenal insufficiency; ALF, acute liver failure; ARF, acute renal failure; DIC, disseminated intravascular coagulation; “DIC”, false disseminated intravascular coagulation; DIT, disseminated intravascular microthrombosis; EA-VMTD/DIT, endotheliopathy-associated vascular microthrombotic disease; FHF, fulminant hepatic failure; HUS, hemolytic–uremic syndrome; MAHA, microangiopathic hemolytic anemia; MODS, multi-organ dysfunction syndrome; SIRS, severe inflammatory response syndrome; TCIP, thrombocytopenia in critically ill patients; TTP, thrombotic thrombocytopenic purpura.

Table 2. Examples of ARDS Associated With Noninfectious Conditions, and Clinical and Hematologic Syndromes.

	Clinical Events	Pathogenetic Mechanisms	Clinical Phenotypes	Hematologic Phenotypes
Trauma	Chest/lung injury (eg, motorcycle accident) Head/brain injury			
Surgery	Cardiac/vascular surgery Abdominal surgery Orthopedic surgery	Vascular trauma/injury ↓ Complement activation (C5b-9) ↓	Encephalopathy ARF Acute pancreatitis Rhabdomyolysis MODS SIRS	TCIP “DIC”/DIT EA-VMTD/DIT MAHA TTP-like syndrome
Pregnancy	Pregnancy complication (eg, preeclampsia)	Endotheliopathy		
Transplant	Transplant complication	↓ Inflammation and microthrombogenesis		
Drug/toxin	Drugs Chemical poisons Snake/bee envenomation			

Abbreviations: ARF, acute renal failure; “DIC”, disseminated intravascular coagulation; DIT, disseminated intravascular microthrombosis; EA-VMTD, endotheliopathy-associated vascular microthrombotic disease; MAHA, microangiopathic hemolytic anemia; MODS, multi-organ dysfunction syndrome; SIRS, severe inflammatory response syndrome; TCIP, thrombocytopenia in critically ill patients; TTP, thrombotic thrombocytopenic purpura.

manifestations seemed to be consistent with a hemostatic disorder, which is now recognized as EA-VMTD.^{9,10,12} Until recently, it was debated whether ARDS was the cause of thrombocytopenia, inflammation, MODS, and “DIC,” or was rather the result of another pathological condition producing those hematologic phenotypes. In later discussion, this dilemma will be further explored once the pathophysiological mechanism of ARDS is established.

The pathological features of ARDS are characterized by (1) diffuse alveolar damage associated with injury to alveolar lining and endothelial cells (ECs), (2) exudative pulmonary edema, and (3) hyaline membrane formation.⁴⁴⁻⁴⁶ These pathologic changes are very similar, if not identical, in each ARDS caused by different pathogens and insults, including pneumonia-initiated SARS and MERS.^{46,47} One unique abnormality is hyaline membrane formation/deposits. This pathologic feature appears to be

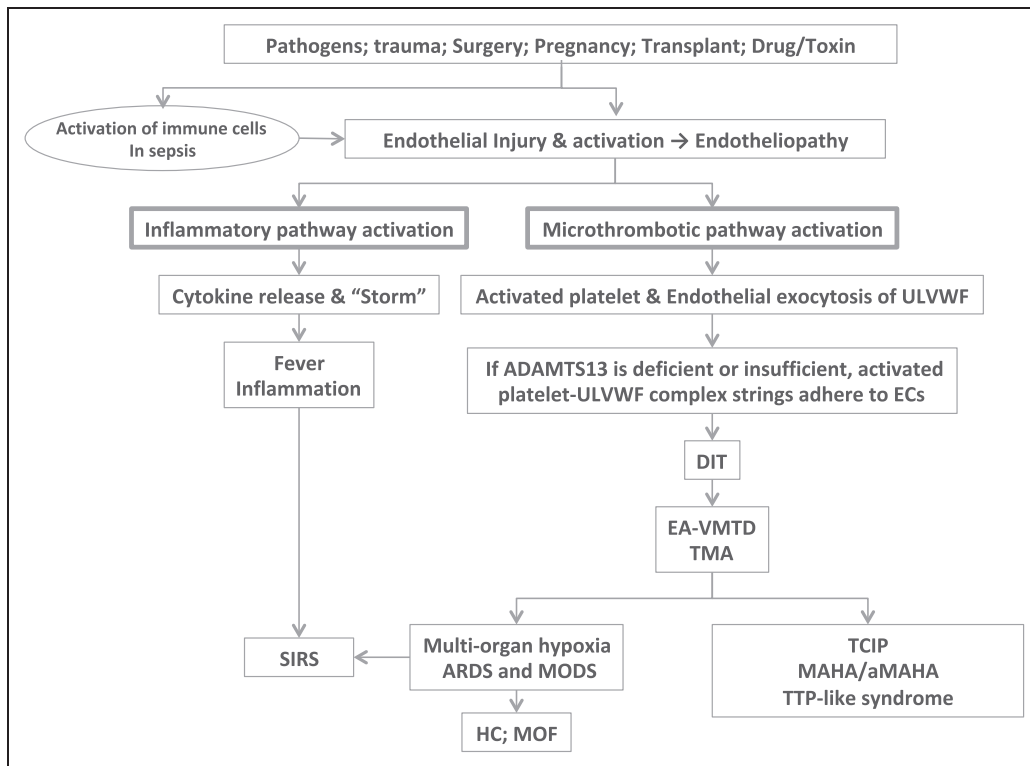


Figure 1. Endothelial molecular pathogenesis of ARDS and MODS in critically ill patients. Based on “two-activation theory of the endothelium. Reproduced and modified from Chang.¹² Endothelial molecular pathogenesis of ARDS as one organ phenotype among various MODS is succinctly illustrated. The underlying pathologic nature of ARDS is a hemostatic disease due to endotheliopathy that promotes activation of two molecular pathways. One is inflammatory pathway, which releases cytokines and provokes inflammation, including fever, malaise, and myalgia. The other is microthrombotic pathway, which causes exocytosis of ULVWF and platelet activation and triggers much more deadly DIT via microthrombogenesis, leading to EAVMTD/DIT. Disseminated intravascular thrombosis orchestrates consumptive thrombocytopenia, MAHA, MODS, and TTP-like syndrome. ARDS indicates acute respiratory distress syndrome; DIT, disseminated intravascular thrombosis; EA-VMTD, endotheliopathy-associated vascular microthrombotic disease; ECs, endothelial cells; HC, hepatic coagulopathy; MAHA/aMAHA, microangiopathic hemolytic anemia/atypical microangiopathic hemolytic anemia; MODS: multi-organ dysfunction syndrome; MOF, multi-organ failure; TMA, thrombotic microangiopathy; SIRS, systemic inflammatory response syndrome; TTP, thrombotic thrombocytopenic purpura; ULVWF, unusually large von Willebrand factor multimers

similar to that of VMTD associated with TTP and TTP-like syndrome, which microthrombi are characterized by hyaline thrombi composed of unusually large von Willebrand factor multimers (ULVWF) and platelets.⁴⁸

Even though ARDS develops in association with divergent etiologies from sepsis to envenomation,⁴⁹ its pathologic and clinical features are remarkably similar among different underlying diseases.⁵⁰⁻⁵² Diffuse alveolar damage was the histologic changes in most patients with ARDS and its progression included 3 phases of exudative, proliferative, and fibrotic changes that correlated with the time rather than its specific causes.⁵² These findings are consistent with the hypothesis that pathogenesis of ARDS is not due to multifactorial processes primarily involving the lungs, but is the result of one pathophysiological mechanism affecting the lungs and multiorgans.

Associated Hematologic and Clinical Syndromes

Consumptive thrombocytopenia in critically ill patients. As in other critical illnesses, thrombocytopenia commonly occurs in ARDS

during the course of the disease.¹⁻³ Even after the known causes of thrombocytopenia such as heparin-induced thrombocytopenia, transfusion and drug-related thrombocytopenia, bone marrow suppression, and other identifiable thrombocytopenia are excluded, the mechanism of undetermined thrombocytopenia cannot be clearly accounted for in most of the cases. Thus, this has been designated as thrombocytopenia in critically ill patients (TCIP).^{1,53,54} Recently, in critical illnesses such as sepsis and trauma, thrombocytopenia is suspected to be associated with endotheliopathy that initiates microthrombogenesis and forms microthrombi. The platelet consumption occurs when ULVWF released from endotheliopathy recruit platelets to form platelet-ULVWF complexes,^{1,9,12} which become microthrombi strings and platelets are consumed. This concept of TCIP is direct and unequivocal evidence that endotheliopathy promotes in vivo hemostasis. Thrombocytopenia in critically ill patient usually presents with mild to moderately decreased platelet count, and bleeding has not been a significant issue in the care of critically ill patients. According to hemostatic principles (Table 3), blood vessel damage limited to ECs in endotheliopathy

Table 3. Three Essentials in Normal Hemostasis.

(1) Hemostatic principles		
(1) Hemostasis can be activated only by vascular injury.		
(2) Hemostasis must be activated through ULVWF path and/or TF path.		
(3) Hemostasis is the same process in both hemorrhage and thrombosis.		
(4) Hemostasis is the same process in both arterial thrombosis and venous thrombosis.		
(5) Level of vascular damage (ECs/SET/EVT) determines different clinical phenotypes of hemorrhagic disease and thrombotic disorder.		
(2) Major participating components		
Components	Origin	Mechanism
(1) ECs/SET/EVT	Blood vessel wall/EVT	Protective barrier
(2) ULVWF	ECs	Endothelial exocytosis/anchoring and microthrombogenesis
(3) Platelets	Circulation	Adhesion to ULVWF strings and microthrombogenesis
(4) TF	SET and EVT	Release from tissue due to vascular injury and fibrinogenesis
(5) Coagulation factors	Circulation	Activation of coagulation factors and fibrinogenesis
(3) Vascular injury and hemostatic phenotypes		
Injury-induced damage	Involved hemostatic path	Level of vascular injury and examples
(1) ECs	ULVWF	Level 1 damage—Microthrombosis (eg, TIA [focal]; Heyde syndrome [local]; EA-VMTD/DIT[disseminated])
(2) ECs/SET	ULVWF + sTF	Level 2 damage—Macrothrombosis (eg, AIS; DVT; PE; AA)
(3) ECs/SET/EVT	ULVWF + eTF	Level 3 damage—Macrothrombosis with hemorrhage (eg, THS; THMI)
(4) EVT alone	eTF	Level e damage—Fibrin clot disease (eg, AHS [eg, SDH; EDH]; ICH; organ/tissue hematoma)
Hemostatic phenotypes	Causes	Genesis
(1) Hemorrhage	External bodily injury	Trauma-induced external bleeding (eg, accident; assault; self-inflicted injury)
(2) Hematoma	Internal EVT injury	Obtuse trauma-induced bleeding (eg, tissue and cavitary hematoma; hemarthrosis)
(3) Thrombosis	Intravascular injury	Intravascular injury (eg, atherosclerosis; diabetes; indwelling venous catheter; surgery; procedure)

Abbreviations: AA, aortic aneurysm; AIS, acute ischemic stroke; AHS, acute hemorrhagic syndrome; DVT, deep vein thrombosis; ECs, endothelial cells; EDH, epidural hematoma; EVT, extravascular tissue; ICH, intracerebral hemorrhage; PE, pulmonary embolism; SDH, subdural hematoma; SET, subendothelial tissue; TF, tissue factor; eTF, extravascular TF; sTF, subendothelial TF; THMI, thrombohemorrhagic myocardial infarction; THS, thrombohemorrhagic stroke; TIA, transient ischemic attack; ULVWF, unusually von Willebrand factor multimers; VMTD, vascular microthrombotic disease; EA-VMTD/DIT, endotheliopathy-associated vascular microthrombotic disease.

activates ULVWF path, but TF path is not activated if subendothelial tissue (SET)/extravascular tissue (EVT) illustrated in Figure 2 is not compromised.^{8,10,12} As the hemostatic nature of microthrombosis associated with critical illnesses has not been recognized to date, TCIP has been benignly neglected although Bone et al²² in late 70s had observed thrombocytopenia was a significant component when he described thrombocytopenia in ARDS. Now, TCIP is found to be consumptive thrombocytopenia caused by microthrombogenesis that leads to EA-VMTD/DIT.⁹

More recently, the significant role of the platelet has been recognized in the care of patients with critical illnesses and ARDS. The degree of thrombocytopenia in sepsis was associated with increased severity and higher mortality^{54,55} and thrombocytopenia was an increased risk and predictive for patient mortality in ARDS.²

Thrombotic thrombocytopenic purpura-like syndrome. When mild to moderate thrombocytopenia was present in ARDS, this author often found masked microangiopathic hemolytic anemia (MAHA) in hematologic evaluation.^{23,24} Microangiopathic hemolytic anemia was less prominent in ARDS with fewer

schistocytes than that in acquired immune TTP, and also with mild to moderate anemia. If, however, the evidence of hemolysis were evident with reticulocytosis, hypohaptoglobinemia, increased lactic acid dehydrogenase, and indirect hyperbilirubinemia,^{23,24,56} it was called atypical MAHA, which is more common in TTP-like syndrome (ie, EA-VMTD). In the literature, case reports described the association between ARDS and TTP-like syndrome.^{22-25,56-61} In this author's experience, ARDS with coexisting TTP-like syndrome responded dramatically when therapeutic plasma exchange (TPE) was employed in very early stage of ARDS.^{23,24}

The reasons why the diagnosis of TTP-like syndrome has been masked in ARDS were due to inconspicuous schistocytosis and unsuspected diagnosis as well as major attention for the patient care directed to respiratory distress in real-time clinical practice. More likely, it was also due to diametrically different pathogeneses between TTP and TTP-like syndrome, in which clear distinction has not been recognized until recently.⁹ It was also caused by the fact that ARDS has never been considered to be a hemostatic disease, and further TTP-like syndrome was unknown to be caused by endotheliopathy.⁹

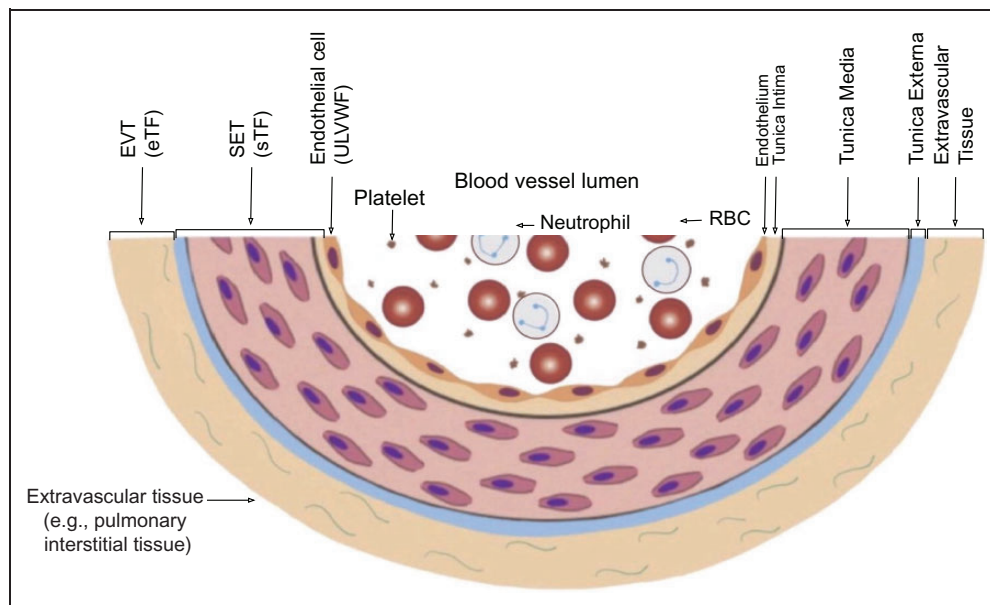


Figure 2. Schematic illustration of cross section of blood vessel histology and hemostatic components. The blood vessel wall is the site of hemostasis (coagulation) to produce hemostatic plug in vascular injury to stop hemorrhage from external vascular injury. It is also the site of hemostasis (thrombogenesis) to produce intravascular blood clots in intravascular injury to cause thrombosis. Its histologic components can be divided into the endothelium, tunica intima, tunica media, and tunica externa, and each component has different function contributing to molecular hemostasis. As shown in the illustration, endothelial injury triggers exocytosis of ULVWF from ECs, SET injury promotes the release of sTF from tunica intima, tunica media, or tunica externa, and EVT injury induces the release of eTF from the outside of blood vessel wall. These depths of blood vessel injury contribute to the genesis of different thrombotic disorders such as microthrombosis, macrothrombosis, and fibrin clot disease/hematoma. This concept is important in the understanding of endotheliopathy leading to ARDS, which leads to lone activation of ULVWF to produce microthrombi strings in ECs. ARDS indicates acute respiratory distress syndrome; ECs, endothelial cells; eTF, extravascular TF; EVT, extravascular tissue; RBC, red blood cell; SET, subendothelial tissue; sTF, subendothelial TF; TF, tissue factor; ULVWF, unusually large von Willebrand factor multimers.

In clinical medicine, all patients with ARDS should be evaluated with a high index of suspicion to look for atypical MAHA as well as thrombocytopenia. Unexplained thrombocytopenia and firm evidence of hemolysis even with minimal or no schistocytes in repeated blood film examination may still be consistent with TTP-like syndrome.¹³

Multi-organ dysfunction syndromes. In late 1980s, Vesconi et al⁶² suspected that ARDS was caused by pulmonary vascular microthrombosis following very elegant investigation demonstrating pulmonary microvascular occlusive lesions in balloon occlusive pulmonary angiography in 31 patients with severe adult respiratory distress. In the study, multiple pulmonary artery filling defects were detected, which findings were interpreted to be consistent with vascular microthrombosis. However, the concept of microthrombosis was not defined yet in coagulation community. Nonetheless, the thesis of microvascular thrombosis or vascular microthrombosis can explain the compromised vascular circulatory function of the lungs and occlusive lesions in pulmonary angiography better than any of other propositions. Proposed theories for the pathogenesis of ARDS have included pulmonary vascular endothelial injury leading to endothelial dysfunction due to inflammatory cytokines or activated immune cells,⁶³ upregulation of adhesion molecules such as soluble vascular adhesion molecule 1 and

E-selectin, underexpression of vascular endothelial cadherins,^{64,65} interactions between neutrophils and cytokines promoting transendothelial migration of cytokine-primed neutrophils,⁶⁶ and neutrophil extracellular traps (NETs) provoking coagulation and microcirculatory failure.⁶⁷⁻⁶⁹ However, these theories could not define how and what molecular changes occur to lead to ARDS and produce increased capillary permeability that was considered to be the hallmark of ARDS.⁷⁰ More importantly, these theories cannot answer why inflammation in ARDS is frequently associated with simultaneous hematologic syndromes and MODS.^{5,71,72}

The proposition of microthrombosis was a very important thesis because for the first time the potential hemostatic nature of ARDS was suggested.⁶² Vascular microthrombosis or microvascular thrombosis has been well recognized as the underlying disease of TTP and more recently as that of TTP-like syndrome, which occurs in EA-VMTD as well as "DIC." Although the molecular mechanism of ARDS has remained elusive, later Khadaroo and Marshall⁵ correctly understood that vascular microthrombosis could contribute its clinical expression not only as ARDS in the lungs but also as MODS in other vital organs. In addition to common association of ARDS and MODS, the similar, if not the same, pulmonary pathologic changes from different pathogens and noninfectious critical illnesses support the mechanism that each of clinical

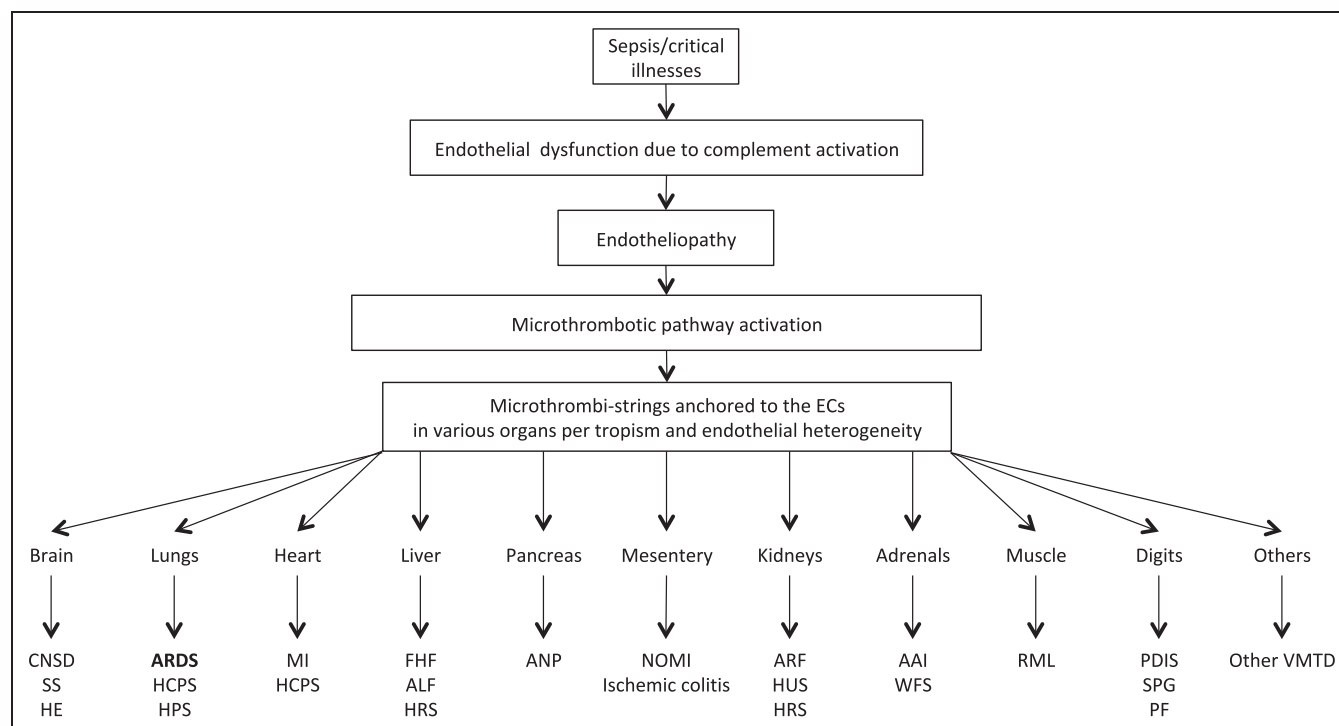


Figure 3. Pathogenesis of MODS in ARDS-associated EA-VMTD/DIT. Reproduced and modified from Chang.¹² The pathogenesis of MODS seen with ARDS is summarized. Any organ can be involved by VMTD in association with/without ARDS. However, MODS is much more common in vital organs, especially in the lungs with ARDS, the brain with CNSD, and the kidneys with acute renal failure. Please note that ARDS has shown to be associated with the every illustrated organ syndrome. AAI indicates acute adrenal insufficiency; ALF, acute liver failure; ANP, acute necrotizing pancreatitis; ARDS, acute respiratory distress syndrome; ARF, acute renal failure; CNSD, central nervous system dysfunction; DIT, disseminated intravascular microthrombosis; EA-VMTD, endotheliopathy-associated vascular microthrombotic disease; FHF, fulminant hepatic failure; HCPS, hantavirus cardiopulmonary syndrome; HE, hepatic encephalopathy; HPS, hantavirus pulmonary syndrome; HRS, hepatorenal syndrome; HUS, hemolytic uremic syndrome; MODS, multi-organ dysfunction syndrome; NOMI, nonocclusive mesenteric ischemia; PDIS, peripheral digit ischemic syndrome; RML, rhabdomyolysis; SPG, symmetrical peripheral gangrene; WFS, Waterhouse-Friderichsen syndrome.

phenotypes of MODS occurs as a result of the same systemic disease of VMTD,¹² as displayed in Figure 3. For example, similar to the organ phenotype of hemolytic uremic syndrome (HUS) in the kidneys, the organ phenotype of ARDS in the lungs is caused by microvascular thrombosis, which is also characteristic of TTP, TTP-like syndrome, “DIC,” and thrombotic microangiopathy. In this context, it can be concluded that ARDS, HUS, and every organ syndrome in MODS are also the manifestations of EA-VMTD/DIT, as illustrated in Figure 1 and further elaborated in Figure 3. Indeed, ARDS is just one phenotype among MODS associated with increased microvascular permeability due to VMTD involving multi-organs.^{5,9,12,24,34} This is also true for the current biorgan designation syndromes such as hepatorenal syndrome, cardiopulmonary syndrome, pulmonary–renal syndrome, hepatic encephalopathy, cardiorenal syndrome, and others.

It should be emphasized that ARDS is not the cause of MODS, but all the organ phenotypes of MODS as well as ARDS are collateral syndromes provoked by VMTD. Next important question is how clinical expression of VMTD can be so variable in the development of MODS among every individual patient as shown in Figure 3. This will be discussed in the heading of tropism and endothelial

heterogeneity within pathophysiological mechanisms involved in ARDS.

Systemic inflammatory response syndrome. The American College of Chest Physicians and the Society of Critical Care Medicine introduced definitions for systemic inflammatory response syndrome (SIRS), sepsis, severe sepsis, septic shock, and MODS in early 1990s.⁷³ The idea proposing the term SIRS was to recognize it as a clinical response to a nonspecific insult of either infectious or noninfectious origin. However, SIRS couldn't be defined as a disease entity and thus has remained to be just as a complex clinical syndrome associated with sepsis and noninfectious critical illnesses because the pathogenesis of SIRS has not been clearly established. It generally has been considered to be expression of self-defense mechanism against overwhelming pathologic insults.

Over the past decades, it has become evident that endotheliopathy plays a major role in sepsis with inflammation and coagulation. In generalized endotheliopathy, SIRS commonly occurs in association with ARDS, which is manifested by combined severe inflammation via cytokine release and microthrombosis via microthrombogenesis that often leads to MODS.⁸⁻¹² In severe ARDS, inflammation coexists with other

organ phenotypes such as encephalopathy, acute renal failure, myocardial infarction, pancreatitis, fulminant hepatic failure, adrenal insufficiency, and others.^{1,12,13} Thus, SIRS can be best defined as combined syndrome of severe inflammatory response from activated inflammatory pathway and organ dysfunction from activated microthrombotic pathway as a result of generalized systemic endotheliopathy.

However, we have to understand that inflammation and microthrombosis in endotheliopathy are two separate processes, although their crosstalk mechanism has been popularized. Their molecular pathogeneses are independent, which is illustrated in two-activation theory of the endothelium (Figure 1). This is the very reason why clinical trials based on anti-inflammatory regimens have had no impact on coagulation system and has failed to improve the outcome as demonstrated in the management of sepsis-associated coagulopathy. In clinical practice, inflammation alone is not the major factor causing poor outcome of the patient, but clinical severity of MODS caused by VMTD is the main culprit for the demise in severe sepsis.

Disseminated intravascular coagulation. “Disseminated intravascular coagulation” has occurred with ARDS with or without sepsis.^{26,27,41-43} It has been considered be the most serious coagulopathy not only in sepsis but also in other human diseases, which is estimated to occur in about 30% to 50% of patients with sepsis. A 1996 study in Japan found that a diagnosis of DIC complicated about 1.0% of admissions to university hospitals.⁷⁴

According to NIH National Heart, Lung, and Blood Institute, DIC is a condition in which blood clots form throughout the body’s small blood vessels. These blood clots can reduce or block blood flow through the blood vessels, which can damage the body’s organs.⁷⁵ Generally clinicians and pathologists defined DIC as a widespread hypercoagulable state that can lead to both microvascular and macrovascular clotting and compromise blood flow, ultimately resulting in multiple organ dysfunction and MODS.⁷⁴ The truth is the coagulopathy of “DIC” couldn’t be precisely defined because the concept of microthrombosis and its thrombogenesis had not been identified yet. It is because the physiological mechanism of in vivo hemostasis has been incompletely understood. For example, what is the role of von Willebrand factor (VWF) in the thrombogenesis and coagulation? Also, what is the role of the platelet in coagulation cascade?⁷⁶ What is the difference between fibrin clots of activated TF path and thrombosis of deep vein thrombosis (DVT)? What is the difference between microthrombi and macrothrombus? Why is microthrombosis disseminated, but is DVT localized? What is coagulation? and how is it different from thrombogenesis? All of these questions seem to be philosophical ones but are urgently needed practical questions in the patient care. There is no simple answer on the difference between DVT and DIC. The former responds to anticoagulation, but the latter does not. Why is it?

Current dilemma is that “DIC” is found to be incorrect in its character and also in accepted contemporary pathogenetic

mechanism according to this author’s interpretation.⁸⁻¹² The reinterpretation of “DIC” based on “two-path unifying theory” of hemostasis and the mechanism of thrombogenesis clearly support that it occurs as a result of activated ULVWF path.⁸⁻¹² The credibility of “DIC,” which coagulopathy has been blamed to microthrombi composed of platelet-ULVWF complexes via microthrombogenesis by some and to fibrin clots made of fibrin, platelet, and coagulation factors through uncontrolled activation of TF-initiated path by others, is seriously undermined because of the irreconcilable conflict between microthrombi and fibrin clots.⁸⁻¹² In in vivo hemostatic process, microthrombi and fibrin clots can be easily differentiated as illustrated in Figure 4A and B. The true character of blood clots in “DIC” is the same microthrombi occurring in VMTD as seen in TTP and TTP-like syndrome.⁹ Also, the pathophysiological mechanism of “DIC” is not TF/FVIIa complex-activated coagulation cascade but instead is partial hemostasis due to lone activation of ULVWF path.⁸ Since “DIC” (ie, microthrombosis) occurs as the result of endotheliopathy alone without the damage of SET/EVT,^{8,10,12} TF path is not activated. This author has derived two theories of “two-activation theory of the endothelium” and “two-path unifying theory” of hemostasis from the analysis and interpretation of pathological, clinical, laboratory, and molecular characteristics between “DIC” and “TTP-like syndrome” and elaborated these hypotheses in previous publications.⁸⁻¹² Therefore, I shall not repeat them again. In short, it can be affirmed that “DIC” is exactly the same to EA-VMTD/DIT, which hematologic phenotype is TTP-like syndrome.⁹

In summing up, the concept of “DIC” has been built on the following faulty pathophysiological mechanism of hemostasis. Comments are followed after each statement.

- “DIC” is uncontrolled “TF path” initiated coagulation disorder occurring in sepsis and other critical illnesses.
- (Instead, it is “ULVWF path” initiated microthrombotic disorder.)
- “DIC” is triggered by inflammation, leading to pathologic “fibrin clots” through “crosstalk” between inflammation and coagulation.
- (Instead, it is triggered by microthrombogenesis, leading to pathologic “microthrombi strings” and “no crosstalk” is involved.)
- “DIC” is caused by microvascular thrombosis initiated by “TF/FVIIa complex”.
- (Instead, it is caused by vascular microthrombosis initiated by “platelet-ULVWF complex.”)
- “DIC” “consumes coagulation factors and platelets in clotting process.”
- (Instead, it is the result of “released ULVWF from injured ECs that consume platelets in formation of microthrombi strings.”)
- Acute “DIC” is characterized by thrombocytopenia, MAHA, MODS, and severe hemorrhagic syndrome

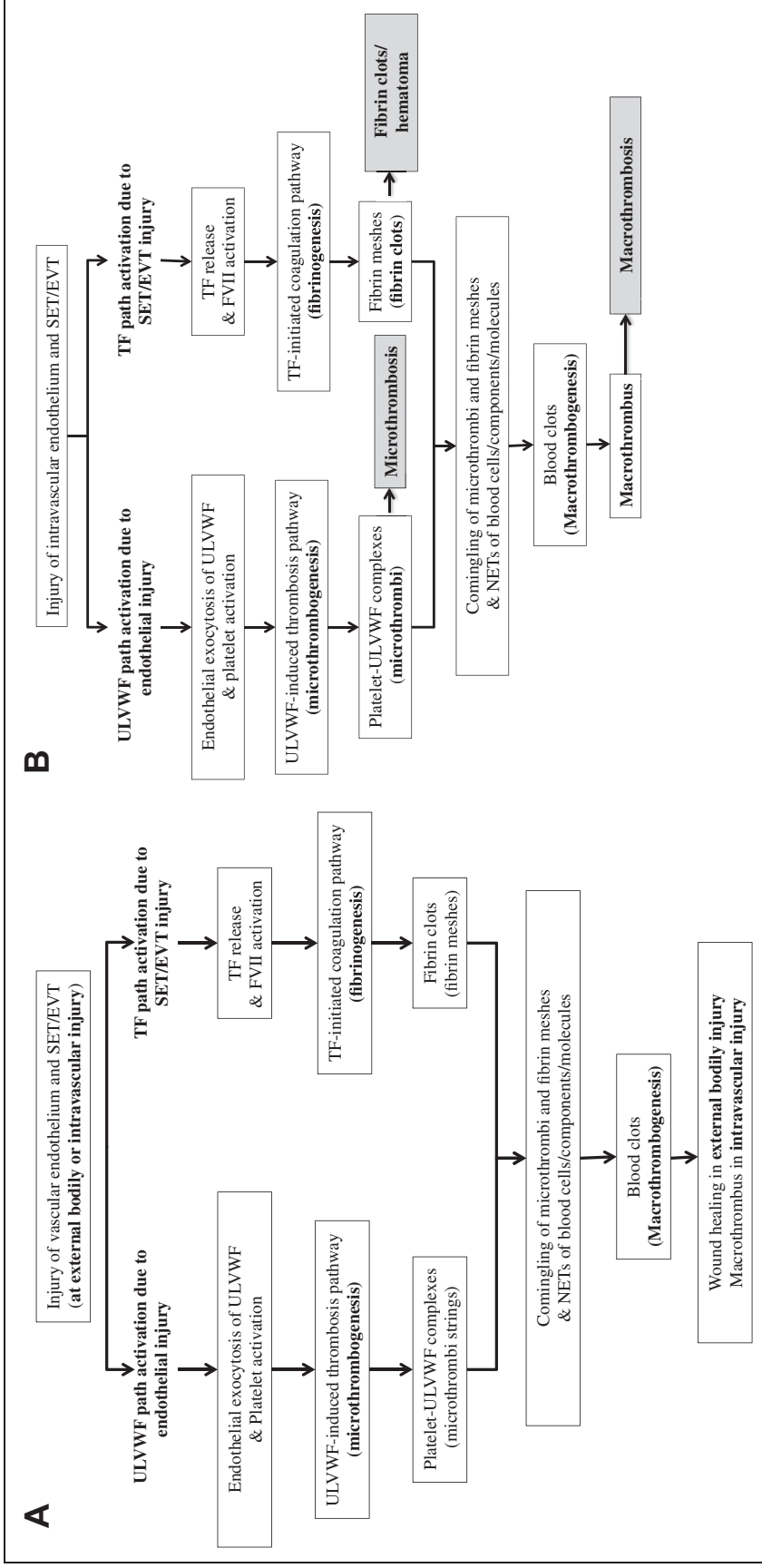


Figure 4. A, Normal hemostasis based on “two-path unifying theory.” Reproduced and updated with permission from Chang.¹² In normal hemostasis, two different thrombotic paths, microthrombotic (ULVWF) and fibrinogenetic (TF), are involved in normal hemostasis, but later the 2 paths must unify to conclude normal hemostasis with passive role of NETs; it stops the bleeding in external bodily injury and produces the thrombosis in intravascular injury. However, in the different level (depth) of intravascular injury, thrombogenesis takes two different paths. If the level of intravascular injury is confined to the endothelium, lone ULVWF path becomes activated and causes microthrombosis (ie, EA-VMTD) because TF path is not activated. On the other hand, if the level of intravascular injury extends from the endothelium to SET/EVT, TF path becomes also activated and causes macrothrombosis (eg, DVT). In another theoretical situation, if only SET/EVT is injured, available TF is supposed to activate lone TF path. However, in pathologic hemostasis, aberrant TF activation occurs and produces fibrin clots (ie, true DIC) in APL due to TF expression in intravascular space from leukemic promyelocytes. Acute promyelocytic leukemia causes consumption coagulopathy due to lone activation of TF path. This logic is based on “two-path unifying theory.” Please note 3 different thrombotic disorders via microthrombogenesis, fibrinogenesis, macrothrombogenesis) in the figure, which are annotated in bold face. Each pathogenesis occurs when ULVWF path, TF path, or combined paths are activated depending upon the levels of damage in intravascular injury (endothelium and SET/EVT). The characters of microthrombi, fibrin clots, and macrothrombus from different paths are very different and produce distinctly different clinical thrombotic disorders. B, Three paths in thrombogenesis based on “two-path unifying theory.” Reproduced and updated with permission from Chang.¹⁰ Traditionally accepted hemostasis has been based on the concept of primary hemostasis in a local vascular injury followed by secondary hemostasis forming fibrin clots. However, this concept cannot explain microthrombi and thrombus formation. Therefore, novel “two-path unifying theory” of hemostasis was derived from the vascular physiologic logic of hemostasis based on 5 hemostatic principles and 5 essential components participating in hemostasis and known works of many dedicated coagulation scientists. Please note that there are 3 different thrombogenic paths in “two-path unifying theory” (macrothrombogenesis, microthrombogenesis, and fibrinogenesis) as annotated in bold face. Each thrombogenic path occurs when ULVWF path, TF path, and/or combined paths are utilized depending upon the vascular levels of damage in intravascular injury, which include the endothelium, SET, and EVT. The characters of the thrombus/blood clot from different paths are unique and produce distinctly different clinical thrombotic disorders. The pathogenesis ARDS is via microthrombogenesis due to lone activation of ULVWF path, which promotes microthrombi strings made of platelet-ULVWF complexes in pulmonary vasculatures. APL indicates acute promyelocytic leukemia; DIC, disseminated intravascular coagulation; DVT, deep vein thrombosis; EA-VMTD, endotheliopathy-associated vascular microthrombotic disease; EVT, extravascular tissue; SET, subendothelial tissue; TF, tissue factor; ULVWF, unusually large von Willebrand factor multimers.

associated with “consumption coagulopathy” with depletion of FVIII and FV.

- (Instead, acute “DIC” is characterized by “hepatic coagulopathy” with markedly increased FVIII, markedly decreased FVII, and decreased FII, FV, FIX and FX.)
- Chronic “DIC” is characterized by thrombocytopenia, MAHA, and MODS without coagulopathy.
- (Yes, the statement is true, but then it is the same picture to “TTP-like syndrome.”)
- “DIC”, TTP, HUS, TTP-like syndrome, and thrombotic microangiopathy are similar but “different diseases.”⁷⁷⁻⁸²
- (Instead, all of them are the same disease called “TTP-like syndrome” except TTP [GA-VMTD and AA-VMTD].⁹)
- “DIC” did not respond to any therapeutic agent utilized in clinical trials. But the reason is unexplained.
- (Yes, the statement is true. The reason was the clinical trials were designed based on incorrect pathogenetic mechanism. But it is expected to respond to antimicrothrombotic therapy.)

On the other hand, EA-VMTD/DIT occurs due to microthrombogenesis as a result of lone activation of ULVWF path of hemostasis.

From these statements, we can conclude as follows:

- “DIC” is incorrect in its concept but is consistent with EA-VMTD/DIT.^{8,10-12}
- Chronic “DIC” is incorrect term, which should be EA-VMTD/DIT without hepatic coagulopathy.
- Acute “DIC” is incorrect term but is consistent with EA-VMTD/DIT with hepatic coagulopathy.

Traditionally, DIC has included (1) “DIC” that is associated with sepsis, trauma, and other critical illnesses and (2) true DIC that occurs in acute promyelocytic leukemia (APL) and rare cases of certain snake venom bite.⁸³ The former is microthrombotic disease due to microthrombi strings (TTP-like syndrome) and the latter is hemorrhagic disorder due to fibrin clots (fibrin clot disease). Since “DIC” has been reappraised as TTP-like syndrome (ie, EA-VMTD/DIT), once we move “DIC” to the column of DIT, the leftover is true DIC that occurs in APL in which fibrin clots are formed by fibrinogenesis via extrinsic coagulation cascade from activated aberrant TF path.^{8,10} Finally, sepsis-associated coagulopathy (ie, microthrombopathy) seen in ARDS can be readily understood as EA-VMTD/DIT, which clinical phenotype is TTP-like syndrome with or without hepatic coagulopathy. On the other hand, APL-associated coagulopathy via fibrinogenesis can be understood as true DIC (disseminated fibrin clot disease).

This brief note on DIC and “DIC” seems to be a very complex conceptual issue at this time for readers, but the comprehension would become simple and clear once two theories (Figures 1 and 4A and B) are understood with the help of Figure 2. It is no wonder why we could not unmask the true identity of “DIC” term used more than 60 years to date.

Succinctly speaking, ARDS is an organ phenotype of hemostatic disease occurring as a result of generalized endotheliopathy (ie, EA-VMTD/DIT), leading to lone activation of ULVWF path that promotes microthrombotic pathway (ie, microthrombogenesis) and orchestrates consumptive thrombocytopenia, MAHA, MODS, and TTP-like syndrome.^{8,11,12} Generalized endotheliopathy also activates inflammatory pathway independent of microthrombotic pathway. The pathophysiological mechanisms involved in ARDS can be summarized as follows.

Pathophysiologic Mechanisms Involved in ARDS

Complement Activation

Complement activation in ARDS has been well recognized more than 3 decades.⁸⁴⁻⁸⁶ However, its relationship between ARDS and complement activation has not been explored even though the role of C5b-9 was suspected to contribute to its pathogenesis⁸⁶ and C5a in highly pathogenic viral infections was also implicated in acute lung injury.⁸⁷

The activation of complement system is one of the key events in defense mechanism against sepsis. Its protective function for host rapidly identifies and eliminates invading pathogen. Opsonization of foreign surfaces by covalently attached C3b fulfills 3 major functions: cell clearance by phagocytosis, amplification of complement activation by the formation of a surface-bound C3 convertase, and assembly of C5 convertases. Cleavage of C5 induces the formation of a multiprotein pore complex C5b-9 (ie, membrane attack complex [MAC]), which leads to cell lysis.⁸⁸

Even though its major role is protective function for host through innate immune defense, complement activation could promote destructive action to innocent bystander of the endothelium of the host, leading to endotheliopathy and neutrophil extracellular traps (NETosis),⁸⁹ which may impact the course of sepsis and other critical illnesses. Membrane attack complex exerts deleterious effects to host’s ECs⁹⁰ unless CD59 glycoprotein is adequately expressed in ECs and protects them by inhibiting C9 polymerization from MAC.^{91,92}

If CD59 is downregulated due to either gene mutation or acquired disease,⁹³ perhaps activated complement could more readily exert destructive effect to the host’s ECs causing endotheliopathy in critical illnesses. When MAC attacks the membrane of ECs, channel (transmembrane pores) formation develops on the endothelial membrane⁹⁰ and triggers endotheliopathy.⁸⁻¹¹ Considering the role of the complement in ARDS as well as in sepsis, endothelial dysfunction via activation of complement cascade is suspected to be the major component contributing to pathologic hemostasis of ARDS.

Endotheliopathy and MODS

The endotheliopathy in ARDS activates 2 major molecular mechanisms; one is severe inflammation caused by inflammatory cytokines released from the endothelium and the other is hypoxic organ dysfunction caused by partial hemostasis via

microthrombogenesis as illustrated in Figure 4B. Endothelial dysfunction has long been known to be the key modulator in the pathogenesis of ARDS as well as sepsis and critical illnesses.^{69,94-97} The markers such as various cytokines and coagulation participants indicating endothelial damage were significantly altered in patients with critical illnesses compared with controls, which included VWF, FVIII and endothelial procoagulants.⁹⁴ Recently, in view of the role of endotheliopathy and concept of VMTD based on novel in vivo “two-path unifying theory” of hemostasis, ARDS pathogenesis has been assured to be the result of pathologic hemostasis.^{8-10,12,69,96}

In ARDS, heterogeneous expression of cell adhesion molecules by ECs was also noted in human pulmonary vasculatures. Although E-selectin and vascular cell adhesion molecule were not expressed on ECs of normal lungs, immunochemical studies showed strong expression of both molecules on the larger vessels of the lungs supporting induction or upregulation in ARDS.^{64,98} Perhaps adhesion molecules could play a secondary role through endothelial heterogeneity and NETosis in the phenotypes of ARDS-associated MODS.

It is now confirmed that ARDS is not the primary disease causing various organ dysfunction syndromes but is the secondary syndrome due to one of hypoxic organ dysfunction resulting from microthrombosis caused by endotheliopathy just like other MODS as illustrated in Figure 3. This concept of MODS promoted by one pathogenetic mechanism (ie, microthrombogenesis) provoked by generalized endotheliopathy bespeaks of the following 4 important implications in the understanding of ARDS and MODS:

- Acute respiratory distress syndrome is not the primary disease but is secondary clinical syndrome associated with one of different underlying causes (eg, sepsis, trauma, complication of pregnancy, surgery and transplant, cancer, drug/toxin, autoimmune disease, and others).
- Both ARDS and other MODS occur as a result of the same underlying pathophysiological mechanism, which is now identified to be microthrombogenesis due to generalized endotheliopathy, leading to VMTD.
- Both ARDS and other MODS are the phenotypes of EA-VMTD/DIT.
- Both ARDS and other MODS would respond to the same treatment based on the same pathophysiological mechanism.

Certainly, the conceptual relationship between ARDS and MODS guides us to the better understanding of endothelial molecular pathogenesis because the endothelium is distributed to the entire organ system and tissue of human body and protects from internal disease and external bodily injury through hemostasis and circulatory homeostasis.⁸

Endothelial Heterogeneity and Tropism

In endothelial pathogenesis of VMTD, the organ phenotype expression is variable among different hosts by the same

pathogen or toxin as well as different pathogens or toxins, which variable expression in turn produces unusual exotic manifestations of MODS. These phenotypes are likely to develop due to two main endowed biological mechanisms: endothelial heterogeneity of host⁹⁷⁻¹⁰³ and organotropism of pathogen or toxin.¹⁰⁴⁻¹⁰⁷ Variable clinical organ phenotypic syndromes occur as seen in the same type of the pathogen. Examples are hanta virus, causing cardiopulmonary syndrome in the heart and lungs, Shiga toxin-producing *Escherichia coli*, presenting with encephalopathy and HUS in the brain and kidneys, and *Neisseria meningitidis*, inciting Waterhouse-Friderichsen syndrome and meningitis in the adrenals and meninges. Of course, a same organ phenotype can occur due to different types of pathogen.

One of the interesting observations in ARDS is the common occurrence of combined syndrome of ARDS and acute necrotizing pancreatitis.^{37,108-110} The character of this biorgan attraction of VMTD in a particular patient is similar as seen in combined syndromes of hepatic encephalopathy, cardiopulmonary syndrome, hepatorenal syndrome, pulmonary–renal syndrome, and others. The circulatory dysfunction and pathologic findings of diffuse alveolar damage in ARDS and necrotizing pancreatic damage in acute pancreatitis certainly support that biorgan syndromes are caused by the same pathogenetic mechanism associated with vascular microthrombosis. Endothelial heterogeneity and/or tropism select the organ localization of microthrombi, but vascular microthrombosis inflicts physical damage to the organs.

In clinical practice, oversimplified designation of organ phenotypes such as encephalopathy and rhabdomyolysis as well as ARDS might have interfered detecting the underlying etiology and mechanism of multi-organ syndromes as well as VMTD. Some authors have claimed one organ phenotypic syndrome such as ARDS has caused several other organ dysfunctions, including pancreatitis, encephalopathy, renal failure, or hepatic failure. However, it should be understood that ARDS and additional organ syndromes begin with an equal footing in systemic VMTD, but the severity of selective organ damage is determined by the localization through selectivity of endothelial heterogeneity and tropism. Since ARDS is not the primary disease, the term extrapulmonary manifestations or extrapulmonary phenotypes of ARDS are misrepresentation. It is this author’s opinion that this conceptual misunderstanding has contributed to the delay in recognizing the pathophysiological mechanisms of ARDS as well as that of other MODS such as HUS, fulminant hepatic failure, acute pancreatitis, biorgan syndromes, and others.

Microthrombogenesis

Although ARDS was suspected to be associated with pulmonary vascular microthrombosis,⁶² it has taken several decades to recognize microthrombosis is a distinctly different disease from macrothrombosis seen in DVT and pulmonary embolism (PE). Even though ARDS is different from DVT and PE, clinicians still might equate the character of microthrombosis in ARDS to that of DVT because we have known only one

mechanism for thrombosis, which is the “blood clot” due to activated TF/FVIIa path. It is about time we accept the microthrombosis of ARDS is the product of different hemostasis from macrothrombosis of DVT or PE. This distinction certainly support new concept of MODS, including encephalopathy, HUS, acute necrotizing pancreatitis, diffuse myocardial ischemia, fulminant hepatic failure from DVT and PE. Multiorgan dysfunction syndrome is caused by microthrombosis the same as in ARDS as a result of microthrombogenesis.^{9,12}

The term of microthrombogenesis is defined in previously mentioned two hemostatic theories. Both theories are congruent to each other, although the “two-activation theory of the endothelium” represents endothelial molecular pathogenesis following exocytosis of ULVWF in endotheliopathy (Figure 1) and the “two-path unifying theory” elaborates in vivo hemostatic process following intravascular injury via the release of ULVWF (Figure 4B). In essence, microthrombogenesis in endothelial molecular pathogenesis and in vivo hemostasis is identical, but the former is the expanded version of ULVWF path illustrating how VMTD orchestrates clinical and pathological phenotypes via endotheliopathy.

Hemostasis based on “two-path unifying theory”. Both TTP and TTP-like syndrome are characterized by DIT involving the vital organs. So is true with “DIC,” thrombotic microangiopathy, HUS, and ARDS. Therefore, all of them should be classified as VMTD. As discussed earlier in the reinterpretation of “DIC,” “DIC” is the same disorder as EA-VMTD/DIT, which hematologic phenotype is TTP-like syndrome. Contemporary theory of TF/FVIIa-initiated coagulation cascade or cell-based coagulation theory cannot explain how microthrombi strings composed of platelet-ULVWF complexes is the same as fibrin clots within intravascular space. This conceptual conflict between activated TF path and activated ULVWF path has alerted this author with the insights that there must be at least two different paths of hemostasis.

The existence of two utterly different characters of blood clots—microthrombi and fibrin clots—have contributed to the redrawing of the framework on two different thrombogenic mechanisms: microthrombogenesis of ULVWF path and fibrinogenesis of TF path. The former assembles microthrombi strings as seen in VMTD such as TTP, TTP-like syndrome, “DIC,” HUS, ARDS, and the latter generates fibrin clots as seen in APL and certain envenomation. Then, next question is what is the character DVT and arterial thrombus seen in aortic aneurysm since they are neither microthrombi nor fibrin clots. Instead, they are obviously macrothrombus, containing fibrin clots and platelets.¹¹ Therefore, it has to be concluded that both ULVWF path and TF path must be involved in the formation of macrothrombosis such as DVT and arterial thrombosis. Through this elucidation, two-path unifying theory is borne out to explain not only “two-path unifying theory” of hemostasis but also three paths of thrombogenesis, which includes microthrombogenesis, fibrinogenesis, and macrothrombogenesis (Figure 4A and B).⁸ Finally, in vivo hemostatic mechanism, including the additional role of NETosis at the

unifying stage of activated ULVWF path and activated TF path, has been indirectly discovered.¹²

The present hallmark of ARDS is vascular microthrombosis (ie, VMTD) as seen with sepsis. Sepsis is characterized by generalized endotheliopathy without compromise of SET/EVT, which is also the same in ARDS. Hemostatic involvement in sepsis is lone activation of ULVWF path on ECs, leading to formation of microthrombi, but bleeding does not develop because SET and EVT damage do not occur and TF path is not activated. Unlike localized macrothrombosis (eg, thrombus of aortic aneurysm, acute ischemic stroke, and DVT), disseminated microthrombosis (ie, DIT) presents with many intriguing features such as ARDS and HUS as well as a variety of hematologic syndromes, including thrombocytopenia, MAHA, TTP-like syndrome, and “DIC.”^{23-25,57,60,61}

According to “two-path unifying theory” of hemostasis,^{8,10} two thrombotic/coagulation pathways, which are ULVWF and TF paths, are initiated in normal hemostasis but later the two paths must unify to conclude normal hemostasis with passive role of NETs. Hemostasis stops bleeding in external bodily injury but produce thrombosis in intravascular injury. In the different level (depth) of intravascular injury as presented in Tables 3 and 4, different paths of thrombogenesis take place depending upon what component(s) of vascular wall is damaged (Figure 2). If the intravascular damage is confined to the ECs (level 1), lone ULVWF path becomes activated and causes microthrombosis (ie, VMTD such as TIA, TTP-like syndrome, ARDS, and MODS) because TF path is not activated. On the other hand, if the intravascular damage extends from the ECs to SET (level 2), both ULVWF path and TF path become activated and cause macrothrombosis (eg, DVT; acute ischemic stroke) as illustrated in hemostatic theory (Figure 4A and B).^{10,12} In addition, if the damage extends from the ECs to beyond vessel wall including SET and EVT (level 3), both ULVWF path and TF path become activated and form macrothrombosis with additional EVT bleeding (eg, thrombohemorrhagic stroke), which is summarized in Tables 3 and 4. For example, for stroke, this concept is very important in the understanding of thrombogenesis, not only in making the diagnosis but also in planning for the treatment. Also, in another situation, if the ECs, SET- and EVT are damaged by obtuse external trauma, bleeding occur into EVT in smaller vessels, but without bleeding into the damaged vascular lumen. Tissue factor is released and mixed with blood in EVT to activate FVII to trigger the activation of TF/VII path. It causes only “hematoma” without significantly breached ECs because ULVWF path is not activated. This logic is based on “two-path unifying theory.” Please see Figure 4B, showing three different thrombogenic processes: microthrombogenesis, fibrinogenesis, and macrothrombogenesis, which are annotated in bold/shaded face. Each thrombogenesis occurs when ULVWF path, TF path, or combined paths are activated depending upon the levels (depth) of damage in intravascular injury. The characters of microthrombi, fibrin clots, and macrothrombus from different paths are very different and produce distinctly different clinical thrombotic disorders.¹⁰

Table 4. Mechanisms of Thrombogenesis in Intravascular Injury and in Extravascular Tissue Damage: Microthrombogenesis, Fibrinogenesis, Macrothrombogenesis, and Hemorrhage.

	Involved Component of Vessel	Activated Hemostatic Path	Character of Thrombosis	Pathologic Disorder	Examples of Clinical Disorder
Intravascular injury with different level of damage					
Level 1	Endothelium	ULVWF path	Microthrombi	Endotheliopathy	EA-VMTD/DIT, "DIC" TIA, ARDS, MODS
Level 2	Endothelium + SET	ULVWF and TF paths	Macrothrombus	Macrothrombosis	DVT, PE, AIS, AA
Level 3	Endothelium + SET + EVT	ULVWF and TF paths	Macrothrombosis and hemorrhage	Macrothrombosis	THS
Extravascular tissue damage from obtuse trauma	Tissue damage with EVT bleeding	TF path	Fibrin clots and hemorrhage	Internal bleeding	AHS, tissue hematoma, hemarthrosis

Abbreviations: AA, aortic aneurysm; AHS, acute hemorrhagic stroke; AIS, acute ischemic stroke; DVT, deep vein thrombosis; EA-VMTD, endotheliopathy-associated vascular microthrombotic disease; MODS, multi-organ dysfunction syndrome; EVT, extravascular tissue; PE, pulmonary embolism; SET, subendothelial tissue; TF, tissue factor; THS, thrombohemorrhagic stroke; TIA, transient ischemic attack; ULVWF, unusually large von Willebrand factor multimers.

Among these characters, ARDS is a hemostatic disease made of "microthrombi strings."

Molecular pathogenesis based on "two-activation theory of the endothelium". The endothelial molecular pathogenesis triggering inflammation has been well known and documented in medical literature, but its molecular pathogenesis promoting microthrombogenesis has not been understood until recently. Although the underlying pathology of ARDS is VMTD, the pathophysiological mechanism of endotheliopathy causing VMTD has remained in mystery, which is the very reason why progress has not been made in the treatment for ARDS. Nor is the comprehensible pathogenesis of microthrombosis orchestrating hematologic expressions, including thrombocytopenia, MAHA, MODS, and TTP-like syndrome. Since sepsis is the initiating cause of microthrombosis and ARDS is the manifestation of organ phenotype of microthrombosis, sepsis and ARDS often coexist. Further, thrombocytopenia, MAHA, MODS, TTP-like syndrome, and SIRS may occur simultaneously in both sepsis and ARDS. The "two-activation theory of the endothelium"^{12,13} succinctly explains this pathogenesis of EA-VMTD/DIT and identifies DIT as a disease promoting all the clinical and hematologic syndromes.

The proposed thesis of endothelial molecular pathogenesis in ARDS is endotheliopathy that initiates two important molecular events: (1) release of inflammatory cytokines (eg, interleukin (IL)-1, IL-6, tumor necrosis factor α , adhesion molecules, and others)^{94,95,112-114} and (2) activation of the platelet³ and exocytosis of ULVWF.¹¹⁵⁻¹²¹ The former triggers inflammation, which process is called "activation of inflammatory pathway," and the latter mediates microthrombogenesis, which triggers "activation of microthrombotic pathway." These two independent pathways are the essence of the "two-activation theory of the endothelium." The manifestation of activated inflammatory pathway is fever, myalgia, arthralgia, and malaise, but that

of activated microthrombotic pathway produces microthrombi strings composed of platelet-ULVWF complexes leading to VMTD.

The activation of endothelial inflammatory pathway occurs due to cytokines in both septic and nonseptic critical illnesses. In sepsis-associated ARDS, the inflammation is accentuated, perhaps through additional loop of activated circulating immune cell pathway (eg, macrophages, monocytes, neutrophils, and lymphocytes) interacting with activated ECs.¹²² This pathway further upregulates the expression of inflammatory response, sometimes causing "cytokine storm." This additional mechanism may explain why more severe inflammation occurs in sepsis than in trauma. On the other hand, the activation of the microthrombotic pathway is promoted by excessively exocytosed ULVWF from injured ECs. Following the endothelial release, ULVWF become anchored to injured ECs as long elongated strings.¹¹⁹⁻¹²¹ If in addition to the excess of ULVWF, the protease ADAMTS13, which cleaves ULVWF to smaller molecular weight VWFs, is underexpressed due to additional underlying heterozygous gene mutation,¹²³⁻¹²⁵ it is more likely to promote EA-VMTD/DIT. This endothelial molecular pathogenesis through activation of inflammatory pathway and microthrombotic pathway clearly explains every hematologic feature and organ phenotypic syndrome occurring in ARDS.

Redefinition of ARDS

In the past several decades, many proposals for redefinition of ARDS have been forwarded to identify the pathophysiological mechanism and to improve the outcome of the disease with better classification and therapeutic design.¹²⁶⁻¹³¹ However, medical community's task finding the answer on the pathogenesis of ARDS has been far from over.

Now, the recognition of ARDS as an expression of hemostatic disease that is characterized by VMTD has widely

opened the door not only in the understanding of this life-threatening phenotype organ syndrome but also in redefining other clinical MODS. Additionally, with the identification of different thrombogenic mechanisms of microthrombosis, fibrin clot disease, and macrothrombosis, various thrombotic disorders could be more precisely defined through the submechanisms of *in vivo* hemostasis.^{8,10} Acute respiratory distress syndrome is the most prominent organ phenotype syndromes developing in sepsis and other critical illnesses among MODS. Thus, once we understand ARDS as an organ phenotype syndrome of the lungs in VMTD, we should be able to understand the organ syndromes due to VMTD occurring in the brain, heart, liver, pancreas, muscles, adrenals, and others. It also affirms generalized EA-VMTD/DIT is the underlying disease, and ARDS and other organ syndromes are the manifestations of each specific organ phenotype in EA-VMTD/DIT. To make the matters simpler, the diagnostic evaluation and therapeutic approach are the same in every phenotype of MODS. Finally, we should be able to treat all the patients with every organ phenotype syndrome, combined biorgan syndrome and MODS due to EA-VMTD/DIT with the same regimen focused on microthrombogenesis.

Table 5 summarizes the identity of ARDS defined through clinical, etiologic, pathogenetic and phenotypic features of EA-VMTD. The pulmonary physiologic alteration of hypoxemia, increased capillary permeability and circulatory failure, pathologic changes of diffuse alveolar damage, exudative pulmonary edema, and hyaline membrane formation are the result of pulmonary vascular microthrombosis. Thus, the therapy for ARDS should directly target the pathogenesis producing VMTD.

Practical Hematologic Evaluation and Potential Therapy for ARDS

The Berlin definition of ARDS addressed limitations of the American-European Consensus Conference definition, but poor reliability of some criteria may have contributed to under-recognition and antipathy by clinicians. No pharmacologic treatments aimed at the underlying pathology have been shown to be effective to date, and management remains supportive with lung-protective mechanical ventilation.¹³¹

Diagnostic Evaluation

In addition to cardiopulmonary evaluation for physiological changes due to respiratory distress as well as assessment of the underlying disease, the proper diagnostic approach of ARDS should start with hematological evaluation.

First of all, every patient with ARDS should be evaluated for the potential of unrecognized TTP-like syndrome, which had been previously defined as “DIC”.^{9,11,12} Unexplained thrombocytopenia, after the exclusion of known causes of thrombocytopenia, should be an initial clue suggesting ongoing microthrombogenesis, leading to EA-VMTD/DIT. An additional finding of MAHA even with minimal degree of schistocytosis, if present, should confirm the diagnosis of TTP-like

Table 5. Clinical, Etiologic, Pathogenetic, and Phenotypic Features of ARDS, Based on EA-VMTD/DIT.

-
- Causes: pathogens, toxins, chemicals, drugs
 - Underlying pathology: sepsis or other critical illnesses
 - Initiating mechanism: complement activation
 - Vascular injury: endotheliopathy
 - Endotheliopathy: molecular dysfunction
 - Molecular dysfunction: activation of inflammation and microthrombotic pathways
 - Hemostatic disease: lone activation of ULVWF path
 - Character of thrombus: microthrombi strings made of platelet-ULVWF complexes
 - Microthrombi strings: anchored to the ECs of pulmonary vasculatures
 - Pulmonary vascular microthrombosis: EA-VMTD/DIT
 - Clinical phenotypes: inflammation and EA-VMTD/DIT
 - Inflammatory syndrome
 - Fever
 - Malaise
 - Arthralgia/myalgia
 - Microthrombotic syndrome
 - Consumptive thrombocytopenia in critically ill patients (TCIP)
 - MAHA
 - TTP-like syndrome (“DIC”)
 - MODS
 - Combined inflammatory and microthrombotic syndrome
 - Cytokine storm
 - SIRS
-

Abbreviations: EA-VMTD/DIT, endotheliopathy-associated vascular microthrombotic disease/disseminated intravascular microthrombosis; “DIC”, false disseminated intravascular coagulation; endotheliopathy-associated vascular microthrombotic disease; MAHA, microangiopathic hemolytic anemia; MODS, multi-organ dysfunction syndrome; SIRS, severe inflammatory response syndrome; TTP, thrombotic thrombocytopenic purpura.

syndrome.^{9,12} To look for schistocytes and evidence of hemolysis, blood films should be examined daily for several consecutive days by an experienced hematologist. Unlike antibody-associated TTP (AA-VMTD, acquired TTP), schistocytes are fewer in ARDS,^{23,24} perhaps due to difference in force of shear stress in the pulmonary vasculature. In critical care settings, in the past, its hemostatic nature could have been missed due to inattention to blood films and low index of suspicion even though an evaluation for unexplained thrombocytopenia and anemia could have been attempted.^{23,24,132} In ARDS, thrombocytopenia and intravascular hemolysis (ie, anemia, reticulocytosis, increased lactic acid dehydrogenase, indirect hyperbilirubinemia, and hypohaptoglobinemia with negative Coombs tests) might be the sufficient criteria to establish the diagnosis of TTP-like syndrome to begin life-saving TPE at the earliest possible time.

To solidify the concept that the underlying pathology of ARDS is EA-VMTD/DIC, this author recommends to determine (1) ADAMTS13 activity and its autoantibody status, (2) ADAMTS13 gene mutation study, and (3) fibrinogen quantitation, FVIII and VWF activity in circulation, and coagulation factor assay for liver-dependent factors (ie, FII, FV, FVII, FIX,

Table 6. Practical Diagnostic Criteria of ARDS With Underlying EA-VMTD/DIT**Clinical features**

- Acute respiratory distress
- Underlying critical illnesses such as sepsis/pneumonia, trauma, and others
- Inflammatory symptoms such as fever, malaise, arthralgia, and myalgia
- SIRS

Hematologic features

- TCIP (consumptive thrombocytopenia)
 - After exclusion of identifiable thrombocytopenia
- MAHA with evidence of hemolysis
 - With/without schistocytosis
 - Reticulocytosis
 - Hypohaptoglobinemia
 - Increased LDH
 - Indirect hyperbilirubinemia
 - After exclusion of identifiable hemolytic anemia
- Hypoxemia
- Coexisting MODS due to DIT and EA-VMTD

Specific laboratory features

- VWF and FVIII
 - If elevated, supports ongoing microthrombogenesis
 - If markedly elevated, may support associated HC in EA-VMTD/DIT
- ADAMTS13 antibody
 - If negative, consistent with EA-VMTD/DIT rather than AA-VMTD.
- ADAMTS13
 - If moderately decreased, suspect underlying ADAMTS13 gene mutation

Abbreviations: EA-VMTD, endotheliopathy-associated VMTD; DIT, disseminated intravascular microthrombosis; HC, hepatic coagulopathy; LDH, lactic acid dehydrogenase; MAHA, microangiopathic hemolytic anemia; MODS, multi-organ dysfunction syndrome; TCIP, thrombocytopenia in critically ill patients; VMTD, vascular microthrombotic disease; VWF, von Willebrand factor; SIRS, systemic inflammatory response syndrome.

and FX) to determine the cause of coagulopathy (ie, hepatic coagulopathy). The diagnostic assessments are summarized in Table 6. Since ARDS is one of MODS, clinicians should stay vigilant with close clinical monitoring for developing additional organ phenotypes of MODS as illustrated in Figure 3.

Therapeutic Approaches

Reflection on past clinical trials. More than a half century since the term ARDS coined, extensive controlled clinical trials have conducted for ARDS to evaluate the effects of pharmaceutical agents, such as statins, β_2 agonists, anti-inflammatory agents, and corticosteroids,¹³³⁻¹³⁶ nutritional supplementation, such as glutamine, selenium, omega-3 fatty acid,¹³⁷⁻¹³⁹ and antioxidant therapy such as N-acetyl cysteine^{140,141} in prevention and treatment. Unfortunately, all of the trials failed to significantly benefit the patient with ARDS.

The fact that the pathophysiologic mechanism of ARDS has not been clearly recognized and the failure of therapeutic

regimens to restore the physiologic alteration of ARDS from endotheliopathy certainly indicates that the pathogenesis of ARDS is yet to be discovered. This author is confident that novel hemostatic “two-path unifying theory” and “two-activation theory of the endothelium” uncover this long hidden mystery of the pathogenesis of ARDS and should yield effective therapeutic regimens sooner than later.

Therapeutic plasma exchange. In addition to the best supportive care with proper antibiotics, ventilator support, and appropriate fluid and electrolyte balance for ARDS, it is obvious that therapeutic approach should target the pathogenesis itself. Since this newly recognized concept of the pathogenesis is a hemostatic disease called pulmonary vascular microthrombosis (ie, TTP-like syndrome as a result of EA-VMTD/DIT) that is caused by the lone activation of ULVWF path, the therapeutic design should be utilizing the inhibition of vascular microthrombogenesis.

At present, the only available antimicrothrombotic regimen is TPE. The rationale is microthrombosis produced by excessive production of ULVWF from endotheliopathy and relative insufficiency of ADAMTS13 perhaps due to unsuspected gene mutation should respond to additional supply of ULVWF-cleaving ADAMTS13 from exchange of normal donor plasma. Indeed, TTP-like syndrome associated with ARDS has shown excellent response to TPE when employed in very early stage.^{23,24,56} Since the lungs are the very organ responsible for oxygen supply to other organs, ARDS is the most important organ phenotype among MODS that could hasten the demise of the patient due to severe hypoxemia. At this time, the earliest intervention utilizing TPE is the only potentially effective treatment to save lives. Otherwise, once the patient is entrenched in mechanical ventilation with volume overload following intravenous fluid and blood transfusions, the recovery from ARDS may become remote even with TPE.

Just as in sepsis and septic shock,¹² TPE has been used sporadically in ARDS even without understanding of the concept of microthrombogenesis and VMTD and has shown significant benefit with safety in case reports and limited clinical series.¹⁴²⁻¹⁴⁷

Antimicrothrombotic therapy. Both TTP and TTP syndrome, including “DIC,” have shown the beneficial effect with TPE,¹² which is a surrogate for replacement therapy of ADAMTS13 despite its technical limitations and inconvenience. Theoretically, the most efficient therapeutic regimen would be antimicrothrombotic agents, which could include recombinant ADAMTS13 and possibly N-acetyl cysteine.^{9,148-150} Both agents are neither approved nor utilized for human use as defined antimicrothrombotic agents, although ADAMTS13 is in clinical trials for GA-VMTD. If we can prove their benefit for ARDS, the therapeutic potential to save so many lives for patients with EA-VMTD/DIT in critical care medicine would be immeasurable.

The worsening thrombocytopenia (ie, TCIP) is the most important laboratory sign suggesting progression of ARDS.

In this situation, platelet transfusion might be tempting, but it is contraindicated in EA-VMTD/DIC because platelet transfusion would further promote microthrombogenesis and intensify MODS associated with DIT as well as MAHA and also may provoke TRALI syndrome. If hepatic coagulopathy coexist with ARDS, its coagulopathy could rapidly progress to combined microthrombo-hemorrhagic syndrome, which will demand a specialized care of coordination with a coagulation specialist.

Conclusion

At last, the pathogenesis of ARDS is identified to be a hemostatic disease occurring due to lone activation of ULVWF path of hemostasis as a result of endotheliopathy in critically ill patients. Its underlying pathology is EA-VMTD/DIT and clinical phenotype is TTP-like syndrome. Generalized endotheliopathy activates the inflammatory pathway and microthrombotic pathway, triggering EA-DIT/VMTD. The former provokes inflammation, and the latter promotes consumptive thrombocytopenia, TTP-like syndrome, and hypoxic MODS. Systemic inflammatory response syndrome is combined syndrome from two independently activated endothelial molecular pathogenesis. Acute respiratory distress syndrome is the pulmonary organ phenotype among various TTP-like syndromes. Acute respiratory distress syndrome responds to the TPE if initiated in very early stage of the disorder. Potentially effective targeted therapeutic strategy should be explored with antimicrothrombotic agents at the earliest possible time to save lives.

Acknowledgment

The author expresses sincere appreciation to Miss Emma Nichole Zebrowski for her insights on the structural function of the blood vessel wall in in vivo hemostasis and excellent illustrative art works of Figure 2.

Declaration of Conflicting Interests

The author(s) declared no potential conflicts of interest with respect to the research, authorship, and/or publication of this article.

Funding

The author(s) received no financial support for the research, authorship, and/or publication of this article.

ORCID iD

Jae C. Chang  <https://orcid.org/0000-0002-9401-7684>

References

- Chang JC. Thrombocytopenia in critically ill patients due to vascular microthrombotic disease: pathogenesis based on “two activation theory of the endothelium”. *Vascul Dis Ther*. 2017;2:1-7. doi:10.15761/VDT.1000132.
- Wang T, Liu Z, Wang Z, et al. Thrombocytopenia is associated with acute respiratory distress syndrome mortality: an international study. *PLoS One*. 2014;9(4):e94124.
- Yadav H, Kor DJ. Platelets in the pathogenesis of acute respiratory distress syndrome. *Am J Physiol Lung Cell Mol Physiol*. 2015;309(9):L915-L923.
- Del Sorbo L, Slutsky AS. Acute respiratory distress syndrome and multiple organ failure. *Curr Opin Crit Care*. 2011;17(1):1-6.
- Khadaroo RG, Marshall JC. ARDS and the multiple organ dysfunction syndrome. Common mechanisms of a common systemic process. *Crit Care Clin*. 2002;18(1):127-141.
- Estenssoro E. Acute respiratory distress syndrome and multiple organ dysfunction: a story of intricate relationship. *J Organ Dysfunction*. 2005;1(1):78-82.
- Bellani G, Laffey JG, Pham T, et al. Epidemiology, patterns of care, and mortality for patients with acute respiratory distress syndrome in intensive care units in 50 countries. *JAMA*. 2016;315(8):788-800.
- Chang JC. Hemostasis based on a novel “two-path unifying theory” and classification of hemostatic disorders. *Blood Coagul Fibrinolysis*. 2018;29(7):573-584.
- Chang JC. TTP-like syndrome: novel concept and molecular pathogenesis of endotheliopathy-associated vascular microthrombotic disease. *Thromb J*. 2018;16:20.
- Chang JC. Thrombogenesis and thrombotic disorders based on “two-path unifying theory of hemostasis”: philosophical, physiological and phenotypical interpretation. *Blood Coagul Fibrinolysis*. 2018;29(7):585-595.
- Chang JC. Disseminated intravascular coagulation: is it fact or fancy? *Blood Coagul Fibrinolysis*. 2018;29(3):330-337.
- Chang JC. Sepsis and septic shock: endothelial molecular pathogenesis associated with vascular microthrombotic disease. *Thrombo J*. 2019;17:10.
- Chang JC. A thought on possible pathogenesis of Ebola viral hemorrhagic disease and potential treatments: could it be thrombotic thrombocytopenic purpura-like syndrome? *Ther Apher Dial*. 2015;20(1):93-98.
- Bakowitz M, Bruns B, McCunn M. Acute lung injury and the acute respiratory distress syndrome in the injured patient. *Scand J Trauma Resusc Emerg Med*. 2012;20:54.
- Contant CF, Valadka AB, Gopinath SP, et al. Adult respiratory distress syndrome: a complication of induced hypertension after severe head injury. *J Neurosurg*. 2001; 95(4):560-568.
- Blum JM, Stentz MJ, Dechert R, et al. Preoperative and intraoperative predictors of postoperative acute respiratory distress syndrome in a general surgical population. *Anesthesiology*. 2013; 118(1):19-29.
- Duarte AG. ARDS in pregnancy. *Clin Obstet Gynecol*. 2014; 57(4):862-870.
- Cole DE, Taylor TL, McCullough DM, Shoff CT, Derdak S. Acute respiratory distress syndrome in pregnancy. *Crit Care Med*. 2005;33(10 suppl):S269-S278.
- Li GS, Ye QF, Xia SS, et al. Acute respiratory distress syndrome after liver transplantation: etiology, prevention and management. *Hepatobiliary Pancreat Dis Int*. 2002;1(3):330-334.
- Canet E, Osman D, Lambert J, et al. Acute respiratory failure in kidney transplant recipients: a multicenter study. *Crit Care*. 2011; 15(2):R91.

21. Parsons PE. Respiratory failure as a result of drugs, overdoses, and poisonings. *Clin Chest Med.* 1994;15(1):93-102.
22. Bone RC, Henry JE, Petterson J, et al. Respiratory dysfunction in thrombotic thrombocytopenic purpura. *Am J Med.* 1978;65(2):262-270.
23. Chang JC, Aly ES. Acute respiratory distress syndrome as a major clinical manifestation of thrombotic thrombocytopenic purpura. *Am J Med Sci.* 2001;321(12):124-128.
24. Chang JC, Kathula SK. Various clinical manifestations in patients with thrombotic microangiopathy. *J Investig Med.* 2002;50(3):201-206.
25. El Kassimi FA, Al Mashhadani S, Abdullah AK, Akhtar J. Adult respiratory distress syndrome and disseminated intravascular coagulation complicating heat stroke. *Chest.* 1986;90(4):571-574.
26. Ogawa R, Takano Y, Fujita T. Disseminated intravascular coagulation in the pathogenesis of adult respiratory distress syndrome: 2. Experimental study. *Jpn J Surg.* 1977;7(4):223-229.
27. Abraham E. Coagulation abnormalities in acute lung injury and sepsis. *Am J Respir Cell Mol Biol.* 2000;22(4):401-404.
28. Chang JC. Viral hemorrhagic fevers due to endotheliopathy-associated disseminated intravascular microthrombosis and hepatic coagulopathy: pathogenesis based on “two activation theory of the endothelium”. *Clin Microbiol Infect Dis.* 2017;2(2):1-6.
29. Li TS, Gomersall CD, Joynt GM, Chan DP, Leung P, Hui DS. Long-term outcome of acute respiratory distress syndrome caused by severe acute respiratory syndrome (SARS): an observational study. *Crit Care Resusc.* 2006;8(4):302-308.
30. Gralinski LE, Baric RS. Molecular pathology of emerging coronavirus infections. *J Pathol.* 2015;235(2):185-195.
31. Tariket S, Sut C, Hamzeh-Cognasse H, Laradi S, Garraud O, Cognasse F. Platelet and TRALI: from blood component to organism. *Transfus Clin Biol.* 2018;25(3):204-209.
32. Bux J. Transfusion-related acute lung injury (TRALI): a serious adverse event of blood transfusion. *Vox Sang.* 2005;89(1):1-10.
33. Gonzalvo R, Martí Sistac O, Blanch L, López Aguilar J. Bench-to bedside review: brain-lung interaction in the critically ill—a pending issue revisited. *Crit Care.* 2007;11(3):216.
34. Dizier S, Forel JM, Ayzac L, et al. Early hepatic dysfunction is associated with a worse outcome in patients presenting with acute respiratory distress syndrome: a post-hoc analysis of the ACURASYS and PROSEVA studies. *PLoS One.* 2015;10(12):e0144278.
35. Villacrés SM, Medar SS, Aydin SI. Acute kidney injury in children with acute respiratory failure. *Clin Pediatr (Phila).* 2018;57(11):1340-1348.
36. Atam V, Singh AS, Y athish BE, Das L. Acute pancreatitis and acute respiratory distress syndrome complicating plasmodium vivax malaria. *J Vector Borne Dis.* 2013;50(2):151-154.
37. Zhou MT, Chen CS, Chen BC, Zhang QY, Andersson R. Acute lung injury and ARDS in acute pancreatitis: mechanisms and potential intervention. *World J Gastroenterol.* 2010;16(17):2094-2099.
38. Fein AM, Lippmann M, Holtzman H, Eliraz A, Goldberg SK. The risk factors, incidence, and prognosis of ARDS following septicemia. *Chest.* 1983;83(1):40-42.
39. Williamson DR, Albert M, Heels Ansdell D, et al. Thrombocytopenia in critically ill patients receiving thromboprophylaxis: frequency, risk factors, and outcomes. *Chest.* 2013;144(4):1207-1215.
40. Wong RS, Wu A, To KF, et al. Haematological manifestations in patients with severe acute respiratory syndrome: retrospective analysis. *BMJ.* 2003;326(7403):1358-1362.
41. Semeraro N, Ammollo CT, Semeraro F, Colucci M. Sepsis-associated disseminated intravascular coagulation and thromboembolic disease. *Mediterr J Hematol Infect Dis.* 2010;2(3):e2010024.
42. Miyoshi S, Ito R, Katayama H, et al. Combination therapy with sivelestat and recombinant human soluble thrombomodulin for ARDS and DIC patients. *Drug Des Devel Ther.* 2014;8:1211-1219.
43. Gando S, Kameue T, Matsuda N, Sawamura A, Hayakawa M, Kato H. Systemic inflammation and disseminated intravascular coagulation in early stage of ALI and ARDS: role of neutrophil and endothelial activation. *Inflammation.* 2004;28(4):237-244.
44. Beasley MB. The pathologist’s approach to acute lung injury. *Arch Pathol Lab Med.* 2010;134(5):719-727.
45. Cardinal Fernández P, Lorente JA, Ballén Barragán A, Matute Bello G. Acute respiratory distress syndrome and diffuse alveolar damage. New insights on a complex relationship. *Ann Am Thorac Soc.* 2017;14(6):844-850.
46. Franks TJ, Chong PY, Chui P, et al. Lung pathology of severe acute respiratory syndrome (SARS): a study of 8 autopsy cases from Singapore. *Hum Pathol.* 2003;34(8):743-748.
47. Graham RL, Donaldson EF, Baric RS. A decade after SARS: strategies for controlling emerging coronaviruses. *Nat Rev Microbiol.* 2013;11(12):836-848.
48. Allford SL, Machin SJ. Current understanding of the pathophysiology of thrombotic thrombocytopenic purpura. *J Clin Pathol.* 2000;53(7):497-501.
49. Xie C, Xu S, Ding F, et al. Clinical features of severe wasp sting patients with dominantly toxic reaction: analysis of 1091 cases. *PLoS One.* 2013;8(12):e83164.
50. Thille AW, Esteban A, Fernández Segoviano P, et al. Chronology of histological lesions in acute respiratory distress syndrome with diffuse alveolar damage: a prospective cohort study of clinical autopsies. *Lancet Respir Med.* 2013;1(5):395-401.
51. Tomashefski JF Jr. Pulmonary pathology of acute respiratory distress syndrome. *Clin Chest Med.* 2000;21(3):435-466.
52. Castro CY. ARDS and diffuse alveolar damage: a pathologist’s perspective. *Semin Thorac Cardiovasc Surg.* 2006;18(1):131-139.
53. Khurana D, Deoke SA. Thrombocytopenia in critically ill patients: clinical and laboratorial behavior and its correlation with short-term outcome during hospitalization. *Indian J Crit Care Med.* 2017;21(12):861-864.
54. Thachil J, Warkentin TE. How do we approach thrombocytopenia in critically ill patients? *Br J Haematol.* 2017;177(1):27-38.
55. Levi M. Platelets in critical illness. *Semin Thromb Hemost.* 2016;42(3):252-257.
56. Chang JC, Gupta S. Acute respiratory distress syndrome and non-occlusive mesenteric ischemia as major clinical manifestations of thrombotic thrombocytopenic purpura: complete remission

- following exchange plasmapheresis. *J Clin Apher.* 1998;13(4):190-192.
57. Bautista MT, Steinbrub J, Sharma R. Thrombotic thrombocytopenic purpura (TTP) presenting as acute respiratory distress syndrome (ARDS). *Chest.* 2014;145(3Suppl):167A19.
 58. Noda M, Kitagawa M, Tomoda F, Iida H. Thrombotic thrombocytopenic purpura as a complicating factor in a case of polymyositis and Sjögren's syndrome. *Am J Clin Pathol.* 1990;94(2):217-221.
 59. Howard TP. Fulminant respiratory failure. A manifestation of thrombotic thrombocytopenic purpura. *JAMA.* 1979;242(4):350-351.
 60. Nokes T, Awab A, George J, Chen Q. Severe hypoxemic respiratory failure and thrombotic thrombocytopenic purpura. *Chest.* 2012;142(suppl 4):317A.
 61. Lisa T, Qi Shi, Nimesh P. Diffuse alveolar hemorrhage: a life-threatening condition in thrombotic thrombocytopenic purpura (TTP). *Blood.* 2013;122(21):4762.
 62. Vesconi S, Rossi GP, Pesenti A, et al. Pulmonary microthrombosis in severe adult respiratory distress syndrome. *Crit Care Med.* 1988;16(2):111-113.
 63. Puneet P, Moochhala S, Bhatia M. Chemokines in acute respiratory distress syndrome. *Am J Physiol Lung Cell Mol Physiol.* 2005;288(1):L3-L15.
 64. Attia EF, Jolley SE, Crothers K, Schnapp LM, Liles WC. Soluble vascular cell adhesion molecule-1 (sVCAM-1) is elevated in bronchoalveolar lavage fluid of patients with acute respiratory distress syndrome. *PLoS One.* 2016;11:e0149687.
 65. Herwig MC, Tsokos M, Hermanns MI, Kirkpatrick CJ, Müller AM. Vascular endothelial cadherin expression in lung specimens of patients with sepsis-induced acute respiratory distress syndrome and endothelial cell cultures. *Pathobiology.* 2013;80(5):245-251.
 66. Chollet Martin S, Jourdain B, Gibert C, Elbim C, Chastre J, Gougerot Pocidalo MA. Interactions between neutrophils and cytokines in blood and alveolar spaces during ARDS. *Am J Respir Crit Care Med.* 1996;154(3 pt 1):594-601.
 67. Mikacenic C, Moore R, Dmyterko V, et al. Neutrophil extracellular traps (NETs) are increased in the alveolar spaces of patients with ventilator-associated pneumonia. *Crit Care.* 2018;22(1):358.
 68. Müller Redetzky H. Targeting neutrophil extracellular traps in acute lung injury: a novel therapeutic approach in acute respiratory distress syndrome? *Anesthesiology.* 2015;122(4):725-727.
 69. Matthay MA, Zemans RL. The acute respiratory distress syndrome: pathogenesis and treatment. *Annu Rev Pathol.* 2011;6:147-163.
 70. Pierrakos C, Karanikolas M, Scolletta S, Karamouzou V, Velissaris D. Acute respiratory distress syndrome: pathophysiology and therapeutic options. *J Clin Med Res.* 2012;4(1):7-16.
 71. Matthay MA, Ware LB, Zimmerman GA. The acute respiratory distress syndrome. *J Clin Invest.* 2012;122(8):2731-2740.
 72. Vincent JL, Zambon M. Why do patients who have acute lung injury/acute respiratory distress syndrome die from multiple organ dysfunction syndrome? Implications for management. *Clin Chest Med.* 2006;27(4):725-731.
 73. Bone RC, Balk RA, Cerra FB, et al. Definitions for sepsis and organ failure and guidelines for the use of innovative therapies in sepsis. The ACCP/SCCM Consensus Conference Committee. American College of Chest Physicians/Society of Critical Care Medicine. *Chest.* 1992;101(6):1644-1655.
 74. Costello RA, Nehring SM. *Disseminated Intravascular Coagulation (DIC).* StatPearls [Internet]. Treasure Island, FL: StatPearls Publishing; 2019.
 75. NIH Heart, Lung, and Blood Institute. <https://www.nhlbi.nih.gov/health-topics/disseminated-intravascular-coagulation>. Bethesda, MD.
 76. Mackman N, Tilley RE, Key NS. Role of the extrinsic pathway of blood coagulation in hemostasis and thrombosis. *Arterioscler Thromb Vasc Biol.* 2007;27(8):1687-1693.
 77. Wada H, Matsumoto T, Suzuki K, et al. Differences and similarities between disseminated intravascular coagulation and thrombotic microangiopathy. *Thromb J.* 2018;16:14.
 78. Park YA, Waldrum MR, Marques MB. Platelet count and prothrombin time help distinguish thrombotic thrombocytopenic purpura-hemolytic uremic syndrome from disseminated intravascular coagulation in adults. *Am J Clin Pathol.* 2010;133(3):460-465.
 79. Wang Z, Yu Z, Su J, Cao L, Zhao X, Ruan C. Sepsis-induced disseminated intravascular coagulation with features of thrombotic thrombocytopenic purpura: a fatal fulminant syndrome. *Clin Appl Thromb Hemost.* 2011;17(3):251-253.
 80. Tonna J. Disseminated intravascular coagulation and thrombotic thrombocytopenic purpura/hemolytic uremic syndrome. In: Shah K, Lee J, Medlej K, Weingart S, eds. *Practical Emergency Resuscitation and Critical Care.* Cambridge, United Kingdom: Cambridge University Press. 2013:330-336.
 81. Vincent JL, Castro P, Hunt BJ, et al. Thrombocytopenia in the ICU: disseminated intravascular coagulation and thrombotic microangiopathies—what intensivists need to know. *Crit Crit.* 2018;22(1):158.
 82. Pannu AK, Saroch A. Thrombotic thrombocytopenic purpura or disseminated intravascular coagulation? *Indian J Crit Care Med.* 2017;21(8):539.
 83. Isbister GK, Maduwage K, Scorgie FE, et al. Venom concentrations and clotting factor levels in a prospective cohort of Russell's viper bites with coagulopathy. *PLoS Negl Trop Dis.* 2015;9(8):e0003968.
 84. Hammerschmidt DE, Weaver LJ, Hudson LD, Craddock PR, Jacob HS. Association of complement activation and elevated plasma-C5a with adult respiratory distress syndrome. Pathophysiological relevance and possible prognostic value. *Lancet.* 1980;1(8175):947-949.
 85. Robbins RA, Russ WD, Rasmussen JK, Clayton MM. Activation of the complement system in the adult respiratory distress syndrome. *Am Rev Respir Dis.* 1987;135(3):651-658.
 86. Langlois PF, Gawryl MS. Accentuated formation of the terminal C5b-9 complement complex in patient plasma precedes development of the adult respiratory distress syndrome. *Am Rev Respir Dis.* 1988;138(2):368-375.

87. Wang R, Xiao H, Guo R, Li Y, Shen B. The role of C5a in acute lung injury induced by highly pathogenic viral infections. *Emerg Microbes Infect.* 2015;4(5):e28.
88. Lambris JD, Ricklin D, Geisbrecht BV. Complement evasion by human pathogens. *Nat Rev Microbiol.* 2008;6(2):132-142.
89. De Bont CM, Boelens WC, Pruijn GJM. NETosis, complement, and coagulation: a triangular relationship. *Cell Mol Immunol.* 2019;16(1):19-27.
90. Kerr H, Richards A. Complement-mediated injury and protection of endothelium: lessons from atypical haemolytic uraemic syndrome. *Immunobiol.* 2012;217(2):195-203.
91. Lehto T, Meri S. Interactions of soluble CD59 with the terminal complement complexes. CD59 and C9 compete for a nascent epitope on C8. *J Immunol.* 1993;151(9):4941-4949.
92. Brooimans RA, Van der Ark AA, Tomita M, Van Es LA, Daha MR. CD59 expressed by human endothelial cells functions as a protective molecule against complement-mediated lysis. *Eur J Immunol.* 1992;22(3):791-797.
93. Sugita Y, Masuho Y. CD59: its role in complement regulation and potential for therapeutic use. *Immunotechnol.* 1995;1(3-4):157-168.
94. Aird WC. The role of the endothelium in severe sepsis and multiple organ dysfunction syndrome. *Blood.* 2003;101(10):3765-3777.
95. Maniatis NA, Kotanidou A, Catravas JD, et al. Endothelial pathomechanisms in acute lung injury. *Vascul Pharmacol.* 2008;49(4-6):119-133.
96. Wenzel C, Kofler J, Locker GJ, et al. Endothelial cell activation and blood coagulation in critically ill patients with lung injury. *Wien Klin Wochenschr.* 2002;114(19-20):853-858.
97. Millar FR, Summers C, Griffiths MJ, Toshner MR, Proudfoot AG. The pulmonary endothelium in acute respiratory distress syndrome: insights and therapeutic opportunities. *Thorax.* 2016;71(5):462-473.
98. Müller AM, Cronen C, Müller KM, Kirkpatrick CJ. Heterogeneous expression of cell adhesion molecules by endothelial cells in ARDS. *J Pathol.* 2002;198(2):270-275.
99. Shaver CM, Bastarache JA. Clinical and biological heterogeneity in acute respiratory distress syndrome: direct versus indirect lung injury. *Clin Chest Med.* 2014;35(4):639-653.
100. Aman J, Weijers EM, Van Nieuw Amerongen GP, Malik AB, Van Hinsbergh VW. Using cultured endothelial cells to study endothelial barrier dysfunction: challenges and opportunities. *Am J Physiol Lung Cell Mol Physiol.* 2016;311(2):L453-L466.
101. Maniatis NA, Orfanos SE. The endothelium in acute lung injury/acute respiratory distress syndrome. *Curr Opin Crit Care.* 2008;14(1):22-30.
102. Aird WC. Endothelial cell heterogeneity. *Cold Spring Harb Perspect Med.* 2012;2(1):a006429.
103. Nolan DJ, Ginsberg M, Israely E, et al. Molecular signatures of tissue-specific microvascular endothelial cell heterogeneity in organ maintenance and regeneration. *Dev Cell.* 2013;26(2):204-219.
104. McCall LI, Siqueira Neto JL, McKerrow JH. Location, location, location: five facts about tissue tropism and pathogenesis. *PLoS Pathog.* 2016;12(5):e1005519.
105. Chan RW, Hemida MG, Kayali G, et al. Tropism and replication of Middle East respiratory syndrome coronavirus from dromedary camels in the human respiratory tract: an in-vitro and ex-vivo study. *Lancet Respir Med.* 2014;2(10):813-822.
106. Millet JK, Whittaker GR. Host cell proteases: critical determinants of coronavirus tropism and pathogenesis. *Virus Res.* 2015;202:120-134.
107. Zeng H, Goldsmith CS, Kumar A, et al. Tropism and infectivity of a seasonal A (H1N1) and a highly pathogenic avian A (H5N1) influenza virus in primary differentiated ferret nasal epithelial cell cultures. *J Virol.* 2019;93(10):pii: e00080-e00819.
108. Browne GW, Pitchumoni CS. Pathophysiology of pulmonary complications of acute pancreatitis. *World J Gastroenterol.* 2006;12(44):7087-7096.
109. Pastor CM, Matthay MA, Frossard JL. Pancreatitis-associated acute lung injury: new insights. *Chest.* 2003;124:2341-2351.
110. Interiano B, Stuard ID, Hyde RW. Acute respiratory distress syndrome in pancreatitis. *Ann Intern Med.* 1972;77(6):923-926.
111. Koupenova M, Kehrel BE, Corkrey HA, Freedman JE. Thrombosis and platelets: an update. *Eur Heart J.* 2017;38(11):785-791.
112. Hendrickson CM, Matthay MA. Endothelial biomarkers in human sepsis: pathogenesis and prognosis for ARDS. *Pulm Circ.* 2018;8(2):2045894018769876.
113. Capelozzi VL, Allen TC, Beasley MB, et al. Molecular and immune biomarkers in acute respiratory distress syndrome: a perspective from members of the pulmonary pathology society. *Arch Pathol Lab Med.* 2017;141(12):1719-1727.
114. Blondonnet R, Constantin JM, Sapin V, Jabaudon M. A pathophysiologic approach to biomarkers in acute respiratory distress syndrome. *Dis Markers.* 2016;2016:3501373.
115. Valentijn KM, Sadler JE, Valentijn JA, Voorberg J, Eikenboom J. Functional architecture of Weibel-Palade bodies. *Blood.* 2011;117(19):5033-5043.
116. Holthenrich A, Gerke V. Regulation of von Willebrand factor secretion from endothelial cells by the annexin A2-S100A10 complex. *Int J Mol Sci.* 2018;19(6):pii: E1752.
117. Mourik MJ, Valentijn JA, Voorberg J, Koster AJ, Valentijn KM, Eikenboom J. Von Willebrand factor remodeling during exocytosis from vascular endothelial cells. *J Thromb Haemost.* 2013;11(11):2009-2019.
118. Romani de Wit T, Rondaj MG, Van Mourik JA. Weibel-Palade bodies: unique secretory organelles within endothelial cells. *Ned Tijdschr Geneesk.* 2004;148(32):1572-1577.
119. De Ceunynck K, De Meyer SF, Vanhoorelbeke K. Unwinding the von Willebrand factor strings puzzle. *Blood.* 2013;121(2):270-277.
120. Dong JF. Cleavage of ultra-large von Willebrand factor by ADAMTS-13 under flow conditions. *J Thromb Haemost.* 2005;3(8):1710-1716.
121. Turner N, Nolasco L, Moake J. Generation and breakdown of soluble ultralarge von Willebrand factor multimers. *Semin Thromb Hemost.* 2012;38(1):38-46.
122. Danese S, Dejana E, Fiocchi C. Immune regulation by microvascular endothelial cells: directing innate and adaptive

- immunity, coagulation, and inflammation. *J Immunol.* 2007;178:6017-6222.
123. Bongers TN, Emonts M, De Maat MP, et al. Reduced ADAMTS13 in children with severe meningococcal sepsis is associated with severity and outcome. *Thromb Haemost.* 2010;103(2):1181-1187.
 124. Pourrat O, Coudroy R, Pierre F. ADAMTS13 deficiency in severe postpartum HELLP syndrome. *Br J Haematol.* 2013;163(3):409-410.
 125. Karim F, Adil SN, Afaq B, Ul Haq A. Deficiency of ADAMTS-13 in pediatric patients with severe sepsis and impact on in-hospital mortality. *BMC Pediatr.* 2013;13:44.
 126. Bernard GR, Artigas A, Brigham KL, et al. The American-European consensus conference on ARDS. definitions, mechanisms, relevant outcomes, and clinical trial coordination. *Am J Respir Crit Care Med.* 1994;149(3 Pt 1):818-824.
 127. Definition Task Force ARDS, Ranieri VM, Rubenfeld GD, et al. Acute respiratory distress syndrome: the Berlin Definition. *JAMA.* 2012;307(23):2526-2533.
 128. Villar J, et al. A universal definition of ARDS. *Intensive Care Med* 2013, 39:583-592.
 129. Hernu R, Wallet F, Thiollière F, et al. An attempt to validate the modification of the American-European consensus definition of acute lung injury/acute respiratory distress syndrome by the Berlin definition in a university hospital. *Intensive Care Med.* 2013;39(23):2161-2170.
 130. Villar J, Fernández RL, Ambrós A, et al; Acute lung injury epidemiology and natural history network. A clinical classification of the acute respiratory distress syndrome for predicting outcome and guiding medical therapy. *Crit Care Med.* 2015;43(2):346-353.
 131. Fan E, Brodie D, Slutsky AS. Acute respiratory distress syndrome: advances in diagnosis and treatment. *JAMA.* 2018;319(7):698-710.
 132. Chang JC, Shipstone A, Llenado-Lee MA. Postoperative thrombotic thrombocytopenic purpura following cardiovascular surgeries. *Am J Hematol.* 1996;53(1):11-17.
 133. Nagendran M, McAuley DF, Kruger PS, et al. Statin therapy for acute respiratory distress syndrome: an individual patient data meta-analysis of randomised clinical trials. *Intensive Care Med.* 2017;43(5):663-671.
 134. National Heart, Lung, Blood Institute Acute Respiratory Distress Syndrome (ARDS) Clinical Trials Network Matthey MA, Brower RG, Carson S, et al. Randomized, placebo-controlled clinical trial of an aerosolized β_2 -agonist for treatment of acute lung injury. *Am J Respir Crit Care Med.* 2011;184(5):561-568.
 135. Hough CL. Steroids for acute respiratory distress syndrome? *Clin Chest Med.* 2014;35(4):781-795.
 136. Gebistorf F, Karam O, Wetterslev J, Afshari A. Inhaled nitric oxide for acute respiratory distress syndrome (ARDS) in children and adults. *Cochrane Database Syst Rev.* 2016;6:CD002787.
 137. Tao KM, Li XQ, Yang LQ, et al. Glutamine supplementation for critically ill adults. *Cochrane Database Syst Rev.* 2014;9:CD010050.
 138. Allingstrup M, Afshari A. Selenium supplementation for critically ill adults. *Cochrane Database Syst Rev.* 2015;7:CD003703.
 139. Zhu D, Zhang Y, Li S, Gan L, Feng H, Nie W. Enteral omega-3 fatty acid supplementation in adult patients with acute respiratory distress syndrome: a systematic review of randomized controlled trials with meta-analysis and trial sequential analysis. *Intensive Care Med.* 2014;40(4):504-512.
 140. Zhang Y, Ding S, Li C, Wang Y, Chen Z, Wang Z. Effects of N-acetylcysteine treatment in acute respiratory distress syndrome: a meta-analysis. *Exp Ther Med.* 2017;14:2863-2868.
 141. Jepsen S, Herlevsen P, Knudsen P, Bud MI, Klausen NO. Antioxidant treatment with N-acetylcysteine during adult respiratory distress syndrome: a prospective, randomized, placebo-controlled study. *Crit Care Med.* 1992;20(7):918-923.
 142. Patel P, Nandwani V, Vanchiere J, Conrad SA, Scott LK. Use of therapeutic plasma exchange as a rescue therapy in 2009 pH1N1 influenza A—an associated respiratory failure and hemodynamic shock. *Pediatr Crit Care Med.* 2011;12(2):e87-e89.
 143. Fakhree MBA, Aghdam AM, Mahdavi F, Azhough R, Omidi A. Plasmapheresis in severe acute pancreatitis, a phase I study. *J Pancreas (Online).* 2017;18:475-478.
 144. Kohli RS, Bleibel W, Shetty A, Dhanjal U. Plasmapheresis in the treatment of hypertriglyceridemic pancreatitis with ARDS. *Dig Dis Sci.* 2006;51(12):2287-2291.
 145. Szczeklik W, Jankowski M, Wegrzyn W, et al. Acute respiratory failure in patients with Guillain-Barré syndrome and myasthenic crisis treated with plasmapheresis in the intensive care unit. *Pol Arch Med Wewn.* 2008;118(4):239-242.
 146. Geri G, Terrier B, Heshmati F, et al. Effect of plasma exchange in acute respiratory failure due to anti-neutrophil cytoplasmic antibody-associated vasculitis. *Crit Care.* 2018;22(3):328.
 147. Angchaisuksiri P. Coagulopathy in malaria. *Thromb Res.* 2014;133(1):5-9.
 148. Kraisin S, Verhenne S, Pham TT, et al. von Willebrand factor in experimental malaria-associated acute respiratory distress syndrome. *J Thromb Haemost.* 2019;17(8):1372-1383.
 149. Dane K, Chaturvedi S. Beyond plasma exchange: novel therapies for thrombotic thrombocytopenic purpura. *Hematol Am Soc Hematol Educ Program.* 2018;2018(1):539-547.
 150. Chen J, Reheman A, Gushiken FC, et al. N-acetylcysteine reduces the size and activity of von Willebrand factor in human plasma and mice. *J Clin Invest.* 2011;121(2):593-603.