

# UC Davis

## Dermatology Online Journal

### Title

Pachydermoperiostosis, a unique entity with distinctive clinical features

### Permalink

<https://escholarship.org/uc/item/8wp6s7x3>

### Journal

Dermatology Online Journal, 21(5)

### Authors

Tinoco-Fragoso, Fatima  
Mendez-Flores, Silvia  
Dominguez-Cherit, Judith

### Publication Date

2015

### DOI

10.5070/D3215027529

### Copyright Information

Copyright 2015 by the author(s). This work is made available under the terms of a Creative Commons Attribution-NonCommercial-NoDerivatives License, available at <https://creativecommons.org/licenses/by-nc-nd/4.0/>

Peer reviewed

**Photo vignette**

**Pachydermoperiostosis, a unique entity with distinctive clinical features**

**Fátima Tinoco-Fragoso MD, Silvia Méndez-Flores MD, Judith Domínguez-Cherit MD**

**Dermatology Online Journal 21 (5): 12**

**Dermatology Department, National Institute of Health Sciences and Nutrition, Salvador Zubirán, Mexico City, Mexico**

**Correspondence:**

Judith Domínguez-Cherit MD  
National Institute of Health Sciences and Nutrition  
Salvador Zubirán  
15 Vasco de Quiroga, Seccion XVI, Tlalpan  
14000 Mexico City, Distrito Federal, Mexico  
judom59@hotmail.com

---

**Abstract**

Pachydermoperiostosis, which occurs more frequently in men, is a rare entity with distinctive clinical features and an insidious onset. We report the case of a 30-year-old man with a one-year history of acropachy, arthralgias, hiperhidrosis, and progressive skin thickening of the face and scalp.

The radiological findings were consistent with periostosis and the histopathological analysis from a facial skin biopsy showed a pandermal increase in the thickness and number of collagen bundles.

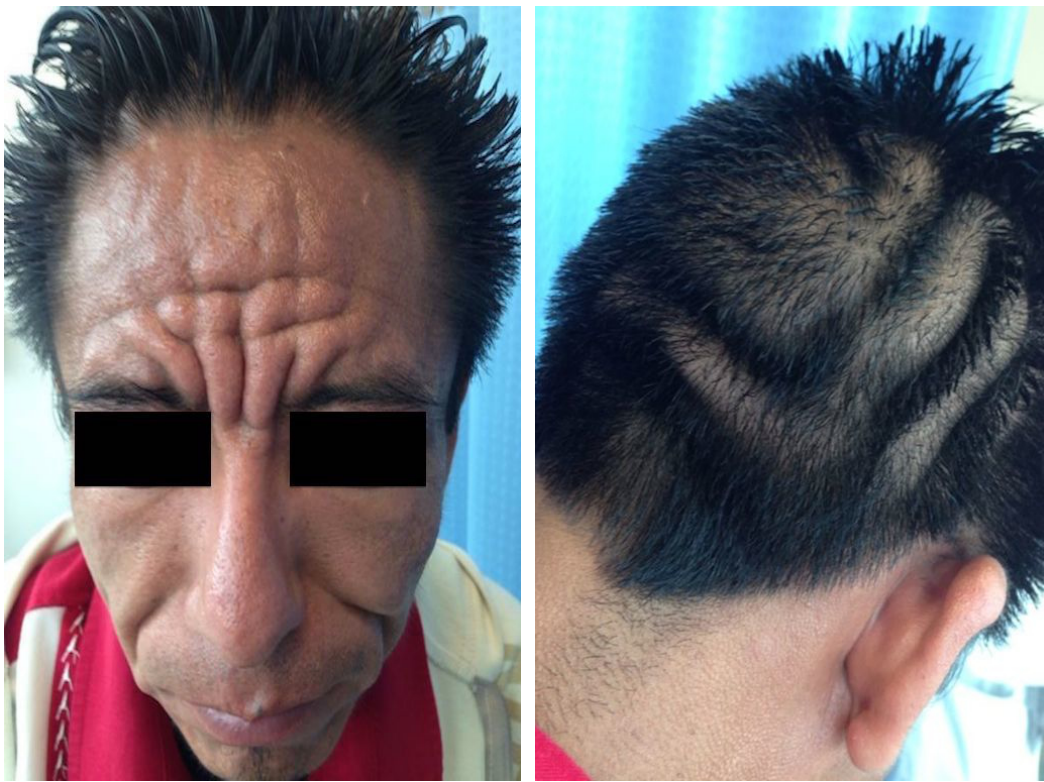The pathogenesis of PDP is currently unknown, although an increased secretion of prostaglandin E2 (PGE2), which stimulates the overexpression of vascular endothelial growth factor (VEGF), has been suggested as a major factor. No specific treatment exists; however, in most cases, the disease tends to stabilize over time.

**Keywords: Pachydermoperiostosis. Cutis verticis gyrata. Primary hypertrophic osteoarthropathy. Touraine-Soulente-Golé syndrome. Primary acropachy**

**Introduction**

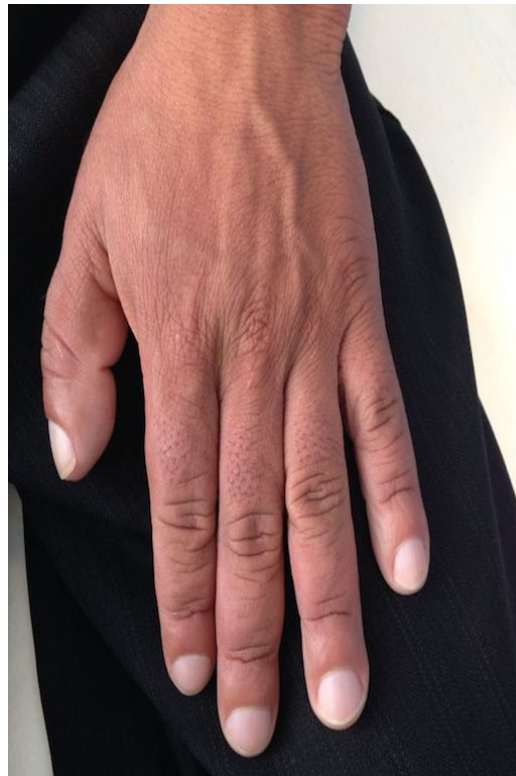In 1935, Touraine *et al* first described pachydermoperiostosis (PDP), also known as primary hypertrophic osteoarthropathy or Touraine-Soulente-Golé syndrome [1]. This genodermatosis is associated with proliferation of osseous and periarticular tissues and is characterized by progressive skin thickening of the face, scalp, and limbs, acropachy, limb overgrowths, and arthralgias. PDP occurs more frequently in men (male to female ratio 7:1) and characteristically follows an insidious course with exacerbations and remissions. Eventually, the disease tends to stabilize over time.

**Case synopsis**



**Figure 1.** Clinical appearance of the patient with an increase in skinfolds and furrows limited to the head. **Figure 2.** Skinfold increase and furrows were also observed in the scalp.

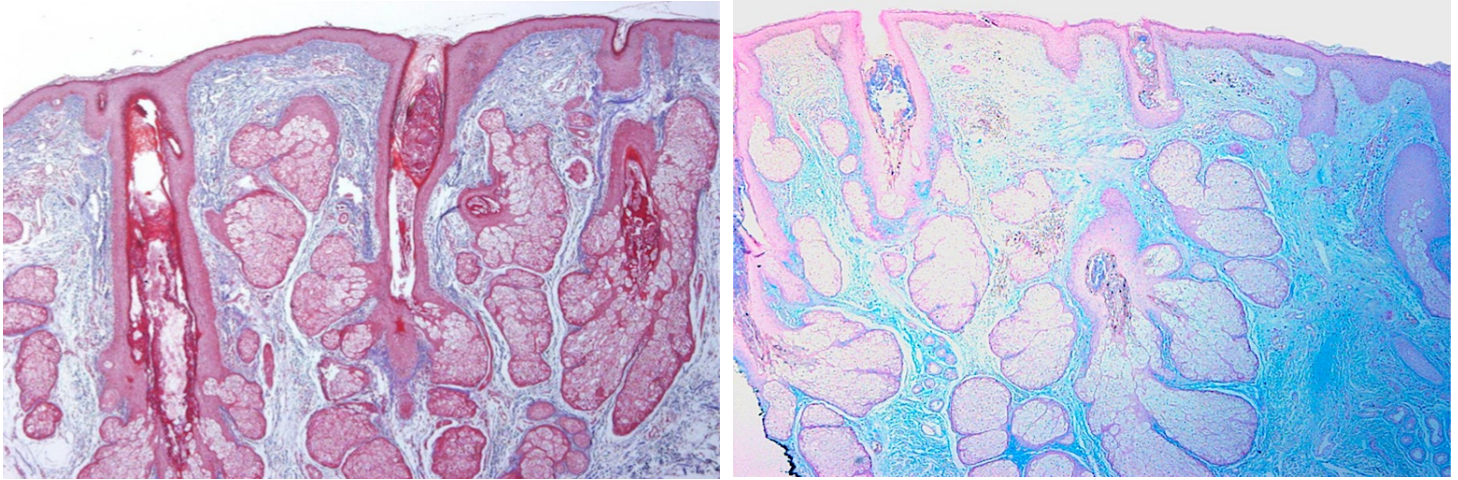
A 30-year-old man presented with a one-year history of progressive skin thickening of the scalp and face (predominantly along the frontal and nasogenian areas) that created a noticeable increase in furrows, in a manner akin to *cutis verticis gyrata*.



**Figure 3.** Skin thickening along the dorsum of the hands predominating overlying interphalangeal joints, with acropachy and pseudo-leukonychia.

Upon further examination, skin thickening was present in both dorsal and palmar surfaces of the hands, particularly around interphalangeal joints; acropachy and pseudo-leukonychia in all nail plates were notable. The patient showed pectus excavatum and a gynecoid pattern in his hair distribution, with male genitals in Tanner IV stage and reported frequent episodes of

hyperhidrosis occurring simultaneously in palms, soles, and axillae. The diagnostic work up included a normal-appearing echocardiogram and bone scans, which demonstrated multiple ripples and cortical thickening affecting long bones. The patient reported that he was the only affected person in his family and denied any consanguinity history.



**Figure 4.** Skin biopsy specimen stained with Masson's trichrome (40x) shows an increase in the thickness and number of collagen bundles. Sebaceous glands are prominent. **Figure 5.** Skin biopsy specimen stained with Alcian blue (40x) that demonstrates an increase in mucin deposits.

A 4-mm punch biopsy of the affected frontal scalp showed a diffuse and pandermal increase in the number and thickness of collagen fibers, which were also present along the fibrous septa of the subcutis. The epidermis overlying such changes was uneven; a mild perivascular and periadnexal inflammatory infiltrate was noted and sebaceous glands were prominent and unaltered. Histochemical examination with an Alcian blue staining revealed an increase in mucin deposits between collagen fibers throughout the dermis. These histopathological features were interpreted as compatible with *cutis verticis gyrata*.

## Discussion

Pachydermoperiostosis is a rare entity, with a prevalence estimate of 0.16% [4]. It has an autosomal dominant inheritance pattern with variable expressivity and incomplete penetrance. However, cases of autosomal recessive inheritance and mutations related to the X chromosome, with variability in the severity of the clinical characteristics, have also been described [5].

Pachydermoperiostosis predominates in males (80%). Touraine *et al* described three clinical forms of the syndrome: complete (with pachydermia and periostosis), incomplete (periostosis without pachydermia) and the “frustrated” form (pachydermia with absent or minimal periostosis) [1]. Independently of the clinical subtype however, all patients show acropachy, whereas 20 to 40% manifest arthralgias (with or without arthritis), mainly in the knees, ankles, and carpal bones [3,6]. A joint effusion, archetypically described as pauci-inflammatory, may be observed [7]. Moreover, X-ray studies demonstrate the presence of subperiosteal deposits in the metaphysis and epiphysis of long bones, formally known as periostosis. In some cases, ligament and interosseous membrane calcifications are found [6].

Cutaneous manifestations of PDP include the presence of scalp and facial skin thickenings, in the form of *cutis verticis gyrata* and palpebral ptosis, which are thought to result from the proliferation of dermal fibroblasts [1, 3]. Additionally, sebaceous and sweat glands hypertrophy are common and manifest clinically as seborrhea, acne, and palmo-plantar hyperhidrosis, respectively [3,6].

Other potential findings in this entity are compressive neuropathy, corneal leukoma, hypoplastic genitalia, gynecomastia, and periodontal and alveolar bone abnormalities [8]. In addition, patients usually develop complications such as myelofibrosis, anemia, hypoalbuminemia, and peptic ulcer. In some cases the presence of Ménétrier disease, gastric cancer, and Crohn disease have been described [6, 8, 11].

The histopathological findings in skin biopsies are non-specific and include a dermal proliferation of fibroblasts associated with redistribution and thickening of collagen fibers, superjacent epidermal hyperplasia, and an accompanying lymphohistiocytic infiltrate.

Although the pathogenesis of PDP remains unclear, some studies have demonstrated a circulating increase of modulators of connective tissue growth factors such as endothelin-1, osteocalcin,  $\beta$ -thromboglobulin, platelet-derived growth factor (PDGF),



Von Willebrand factor, vascular endothelial growth factor (VEGF), and dermal acid mucopolysaccharides [9]. Depending upon the affected gene, two types of PDP have been described. Type 1, involves a mutation in 4q33-q34, resulting in deficiency of 15-hydroxyprostaglandin dehydrogenase (HPGD), the main enzyme responsible for prostaglandin degradation [10]. These patients have high levels of prostaglandin E2 (PGE2) and clinical features usually manifest during the first year of life. Nevertheless, some cases may be identified at birth by the presence of patent *ductus arteriosus* and craniosynostosis [6, 11]. Type 2 PDP involves a *SLCO2A1* (3q22.1-q22.2) gene mutation, which codifies a solute carrier responsible for PGE2 uptake, thus predetermining an extracellular increase of PGE2 levels. PGE2 induces VEGF expression, which in turn promotes vascular hyperplasia, bone formation, and edema [10, 13]. Therefore, VEGF is considered as the main osteogenic and angiogenic factor of the pathogenesis of hypertrophic osteoarthropathy [10, 13]. Type 2 PDP usually manifests in the third decade of life, with a clear male predominance [6, 12].

There is no specific treatment for PDP. However, non-steroidal anti-inflammatory drugs (NSAIDs) are commonly prescribed. Through the inhibition of prostaglandin production, they are effective in relieving joint pain and swelling and reducing sebum and sweat secretion [6]. Nevertheless, adverse effects of NSAIDs (peptic ulcer disease) frequently limit their long-term use. New treatments proposed for the symptomatic relief of hypertrophic osteoarthropathy include bisphosphonates, which are potent inhibitors of bone resorption. The mechanism through which bisphosphonates alter the disease is not yet fully understood. However, there have been several case reports of symptomatic relief with the use of intravenous pamidronate or zoledronic acid [6]. Finally, only for cosmetic purposes, there is the option of performing aesthetic surgery in order to reduce the folds on the face and scalp [14].

In the literature, an insidious onset with exacerbations and asymptomatic periods has been described, along with spontaneous stabilization after some years, which may vary from 5 to 20 [9]. Yet, PDP usually does not interfere with the life expectancy of the patients [3].

## References

1. Touraine A, Solente G, Gole L. Un syndrome osteodermopathique: la pachydermie plicaturee avec pachyperiostose des extremités. *Presse Med* 1935;43:1820-1824.
2. Rastogi R, Suma GN, Prakash R, et al. Pachydermoperiostosis or primary hypertrophic osteoarthropathy: A rare clinicoradiologic case. *Indian J Radiol Imaging* 2009;19:123–126 [PMID:19881067]
3. Kumar S, Sidhu S, Mahajan BB. Touraine-Soulente-Golé Syndrome: A Rare Case Report and Review of the Literature. *Ann Dermatol*. 2013 Aug;25(3):352-5. [PMID:24003280]
4. Jajic I, Jajic Z. Prevalence of primary hypertrophic osteoarthropathy in selected population. *Clin Ex Rheum* 1992;10:73.
5. Castori M, Sinibaldi L, Mingarelli R, Lachman RS, Rimoin DL, Dallapiccola B. Pachydermoperiostosis: an update. *Clin Genet* 2005;68:477-486. [PMID:16283874]
6. Zhang Z, Zhang C, Zhang Z. Primary hypertrophic osteoarthropathy: an update. *Front Med*. 2013, 7(1): 60–64 [PMID:23345113]
7. Martinez-Lavin M. Miscellaneous non-inflammatory musculoskeletal conditions. Pachydermoperiostosis. *Best Pract Res Clin Rheumatol* 2011; 25(5): 727–734 [PMID:22142750]
8. Cantatore FP, Mancini L, Ingrosso AM, Carrozzo M. Pachydermoperiostosis: dermatological, neurological and radiological observations. *Clin Rheumatol* 1995; 14(6): 705–707. [PMID:8608693]
9. Silveira LH, Martínez-Lavín M, Pineda C, Fonseca MC, Navarro C, Nava A. Vascular endothelial growth factor and hypertrophic osteoarthropathy. *Clin Exp Rheumatol* 2000;18:57-62. [PMID:10728444]
10. Uppal S, Diggle CP, Carr IM, Fishwick CW, Ahmed M, Ibrahim GH, et al. Mutations in 15-hydroxyprostaglandin dehydrogenase cause primary hypertrophic osteoarthropathy. *Nat Genet* 2008;40:789-793. [PMID:18500342]
11. Jajic I, Jajic Z, Grazio S. Minor but important symptoms and signs in primary hypertrophic osteoarthropathy. *Clin Exp Rheumatol* 2001;19(3): 357–358. [PMID: 11407101]
12. Zhang Z, Xia W, He J, Zhang Z, Ke Y, Yue H, Wang C, Zhang H, Gu J, Hu W, Fu W, Hu Y, Li M, Liu Y. Exome sequencing identifies *SLCO2A1* mutations as a cause of primary hypertrophic osteoarthropathy. *Am J Hum Genet* 2012; 90(1): 125–132 [PMID:22197487]
13. Towler DA. Vascular biology and bone formation: hints from HIF. *J Clin Invest* 2007; 117(6): 1477–1480 [PMID:17549250]
14. Seyhan T, Ozerdem OR, Aliagaoglu C. Severe complete pachydermoperiostosis (Touraine-Solente-Gol. syndrome). *Dermatol Surg* 2005;31:1465-1467. [PMID:16416623]